e-ISSN: 0975-1556, p-ISSN:2820-2643

Available online on www.ijpcr.com

International Journal of Pharmaceutical and Clinical Research 2023; 15 (4); 334-339

Original Research Article

Fetal Meconium Peritonitis- Antenatal Diagnosis of a Rare of Rarest Clinical Entity and its Postnatal Outcome

Ruby Bhatia[1], Manisha Kumari[2*], Sukhbir Pal Kaur[3], Kiran Pandey[4], Tanisha[5]

[1]Professor, Head of Department of Obstetrics & Gynaecology, MMIMSR, Mullana, Ambala, Haryana.
[2]Third Year Post Graduate Student, Department of Obstetrics & Gynaecology, MMIMSR, Mullana, Ambala, Haryana
[3]Associate Professor, Department of Obstetrics & Gynaecology, MMIMSR, Mullana, Ambala, Haryana.
[4]Assistant Professor, Department of Obstetrics & Gynaecology, MMIMSR, Mullana, Ambala, Haryana.
[5]Third Year Post Graduate Student, Department of Obstetrics & Gynaecology, MMIMSR, Mullana, Ambala, Haryana.

Received: 05-01-2023 / Revised: 27-02-2023 / Accepted: 30-03-2023
Corresponding author: Dr. Manisha Kumari
Conflict of interest: Nil

Abstract

Objective: To present a rare case of fetal meconium peritonitis diagnosed during antenatal period and its postnatal outcome.

Background: Fetal meconium peritonitis (FMP) is a rare of rarest fetal complication with the incidence of 1 in 30,000 newborns. It is defined as sterile chemical peritonitis caused due to extravasation of meconium into the peritoneal cavity secondary to bowel perforation. Few causes which might result in perforation include ileal atresia, intussusception, Hirschsprung's disease, volvulus, Meckel diverticulitis and vascular insufficiency. Sonography with high precision is an effective tool for antenatal diagnosis of FMP. Management and the need for surgery depends on the clinical presentation and the overall condition and the gestational age at birth of the newborn. Timing and mode of delivery relies on combined decision of gynecologists, neonatologists, and neonatal pediatric surgeons. Favorable outcome have been seen when the condition was detected in antenatal period rather than when the neonatal diagnosis is made. Surgery performed within first 24 hours of life may improve perinatal outcome.

Keywords: Fetal meconium peritonitis (FMP), intussusception, Hirshsprung's disease, volvulus, Meckel diverticulitis.

Introduction

Fetal meconium peritonitis (FMP) is a rare of rarest fetal complication with the incidence of 1 in 30,000 newborns. It was first described by G.B. Morgagni in 1761, but the first corrective surgery was executed successfully in 1943 by Agerty. FMP is a sterile chemical peritonitis which occurs due to discharge of meconium into

the peritoneal cavity secondary to bowel perforation that may occur both during antenatal or postnatal period. [1,2,3] FMP may be secondary to meconium ileus, intestinal atresia/stenosis, intussusception, Hirschsprung's disease, volvulus, Meckel diverticulitis and vascular insufficiency or intestinal necrosis resulting from intrauterine ischemia. [4,5,6] Persistence of pathology after birth can be a good source of bacterial infection leading to fatal neonatal outcome.

X-ray of the abdomen is a simple best investigation which can help in making early diagnosis and can reduce morbidity and neonatal mortality. [7] Sonography with high precision is an effective tool for prenatal diagnosis of FMP. Many cases have been reported that have been diagnosed in the antenatal period by ultrasonography (USG) with favorable outcome. However, the main decision lies in when and how to deliver the baby that depends on combined decision of gynecologists, neonatologists, and neonatal pediatric surgeons. We present a case of fetal meconium peritonitis which was diagnosed in antenatal period by USG. Baby was delivered on emergency basis due to acute fetal distress followed by surgical exploration with good clinical outcomes.

Case Report

A 23 year, unbooked, Primigravida with gestational age 40 weeks 4 days complicated by gestational hypertension was referred from secondary care level and admitted at MMIMSR. Her ultrasonography depicted mildly prominent large bowel loops with loculated collection on right side. Antenatal USG of fetus was suggestive of peritoneal calcification -? meconium peritonitis. Review USG and paediatric surgery opinion also confirmed the diagnosis with poor fetal prognosis. An elective lower segment caesarean section was planned after shared informed high risk consent from patient and husband explaining need of surgery and poor fetal prognosis with availability of ventilatory support for baby. However, the baby was delivered on emergency basis due to acute fetal distress. The caesarean section allowed the extraction of a live male newborn with an apgar score of 07/10 at the first minute and 09/10 at the fifth minute and a birth weight of 3020 gm. Baby cried immediately after birth. Immediate intubation was done in view of respiratory distress and baby was shifted to neonatal intensive care unit (NICU). Post operatively baby was in shock with cold periphery (CFT >3 sec) and was kept on ventilatory and ionotrophic support. Abdomen was soft but distended at birth. Sausage shaped swelling was felt over right side of upper abdomen and epigastrium. Postnatal ultrasonography was suggestive of an irregular fluid collection with internal echoes and peripheral curvilinear collection seen in epigastrium and right pelvic region. The lesion was approximately of size 4.8x 3.8x 2.1 cm.

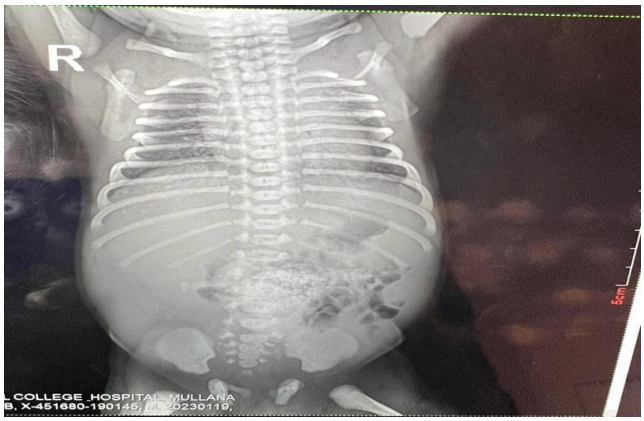

Figure 1: Chest and abdominal radiograph showing presence of intraabdominal calcification.

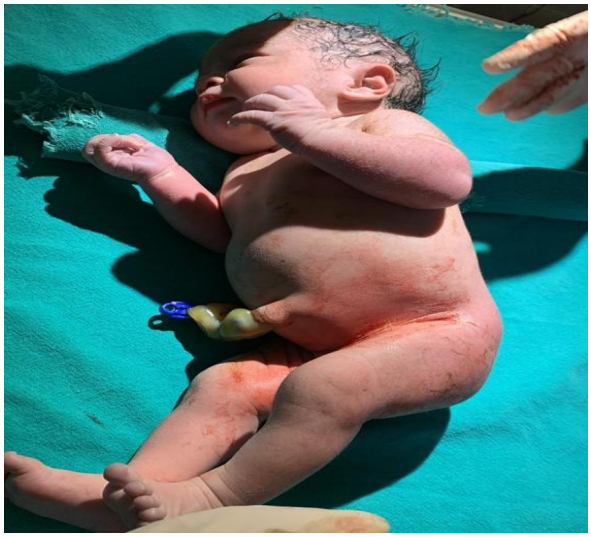

Figure 2: Immediate post-natal period picture of newborn with distended abdomen.

Baby was taken up for exploratory laparotomy on day 2 of life by paediatric surgery team. Intraoperatively free biliary fluid and meconium was seen in peritoneal cavity. Red edematous small bowel with dense adhesions between bowel segments and liver were seen. Meconium cyst of size 5x4x3 cm was seen in epigastric region. Approximately 2 x 1 cm perforation was detected in transverse colon. Cyst excision with primary repair of transverse colon perforation with loop ileostomy was done with peritoneal lavage. Postoperatively baby was on ventilatory and ionotropic support for 4 days. Platelet, packed red blood cells (PRBC) and fresh frozen plasma (FFP) were transfused in view of thrombocytopenia (platelet 84 x 1000/cumm) and anemia postoperatively. Baby was extubated on postoperative day 4 and was kept in neonatal intensive care unit (NICU). Regular dressing and stoma care was done. The remainder of his hospital stay was uneventful. Baby's weight on discharge was 2958 gm (birth weight 3020 gm) and was discharged with functional stoma. Baby is now on regular follow up visits with normal weight gain, tolerating feeds and meeting developmental milestones.

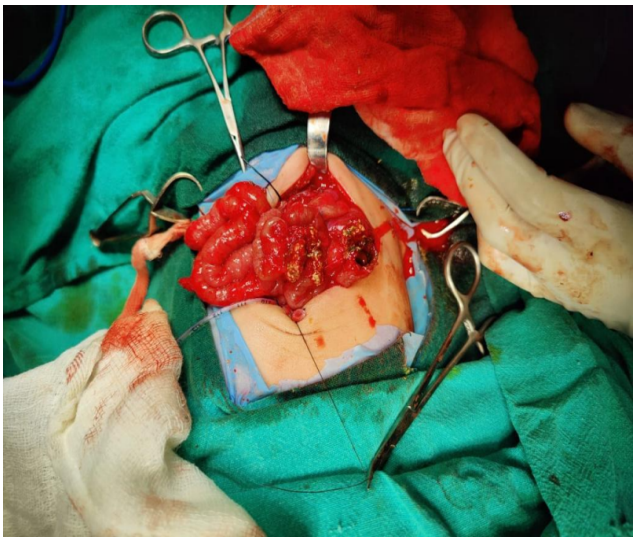

Figure 3: Red edematous small bowel with perforation seen in transverse colon.

Figure 4: Meconium cyst of size 5x4x3 cm sent for histopathological examination.

Discussion

Fetal Meconium Peritonitis (FMP) is defined as an aseptic chemical inflammation resulting from fetal bowel perforation and subsequent meconium leakage in uterus. This is a rare condition with slight male predominance and a survival rate of only 50% with high morbidity and mortality. [5,6,7,8] The identification of fetal meconium peritonitis in antenatal period can be diagnosed with good ultrasonography report and repeated x-ray abdomen postnatally at close intervals. Some studies have reported a low diagnostic yield of prenatal ultrasonography, [2,9] whereas others have emphasized the importance of detailed prenatal scans for early diagnosis and management of MP. [10,11]

Initiation of treatment within the first 24 hours of life with antibiotic therapy along with surgical intervention may be necessary in some cases such as active peritonitis, intestinal obstruction or pneumoperitoneum. [12] According to the study by **Uchida K et al** prenatal diagnosis was made in 73 % of patients. The ultrasound findings with suspected FMP were polyhydramnios (100%), bowel dilatation (53%), ascites (33%), and pseudocyst (13%) and also verified that early surgery is an effective way to reduce intra-abdominal and systemic inflammation, which helps to enhance the outcome of severely affected patients. [13] A study by **Caro-Dominguez et al** reported that postnatal imaging findings that are predictive of need for surgery include intestinal obstruction, ascites, pneumoperitoneum and volvulus; however, the presence or distribution of peritoneal calcification was not predictive of the need for surgery. [14] In another study by **Ping LM et al** fetal ascites (93.3%) was the most common prenatal ultrasound finding. The study also stated that antenatal ultrasound has high specificity (100%) but low sensitivity (22.2%) in detecting meconium pseudocyst. Prenatal magnetic resonance imaging can improve the low diagnostic yield of prenatal ultrasound scan. [15] Currently there is no consensus on the meconium peritonitis management in the antenatal period. Early recognition, antibiotics, surgical correction and meticulous postoperative care is the common practice to improve neonatal survival. [16]

Conclusion

Fetal meconium peritonitis is a rare of rarest condition which occurs due to an inflammatory reaction caused by accumulation of meconium in the peritoneal cavity. Prenatal diagnosis is

crucial for the first step of perinatal therapy for FMP. Sonography with high precision is an effective tool for antenatal diagnosis of FMP. Management and the need for surgery depends on the clinical presentation and the overall condition and the gestational age at birth of the newborn. Timing and mode of delivery relies on combined decision of gynecologists, neonatologists, and neonatal pediatric surgeons. Surgery performed within first 24 hours of life may be a critically important factor to improve perinatal outcome. Shared decision making, involving multidisciplinary team and parents should be practiced in such rare cases.

References

1. Lamrissi A, Madri FE, Wajih O, Mourabbih M, Jalal M, Bouhya S. Mecomium peritonitis: A case report. International Journal of Surgery Case Reports. 2022 Sep 1;98:107476.
2. Eckoldt F, Heling KS, Woderich R, Kraft S, Bollmann R, Mau H. Meconium peritonitis and pseudo-cyst formation: prenatal diagnosis and post-natal course. Prenatal Diagnosis: Published in Affiliation With the International Society for Prenatal Diagnosis. 2003 Nov; 23 (11):904-8.
3. Saleh N., Geipel A., Gembruch U., et al. Prenatal diagnosis and postnatal management of meconium peritonitis . *Journal of Perinatal Medicine.*2009 ;**37**(5):535–538. doi: 10.1515/JPM.2009.097.
4. Chandrasekaran N., Berbardete D., Cariello L., Meraz D. Prenatal sonographic diagnosis of meconium peritonitis from duodenal atresia. *BMJ Case Rep.* 2017
5. De Amorim M.M.R., Vilela P.C., Santos L.C., Neto G.H.F., Cursino O., et al. Peritonite meconial Como diagnóstico diferencial de ascite fetal: relato de Caso. *RBGO.* 1999;**21**:353.
6. Sharma D., Murki S., Pratap T. Meconium peritonitis: an interesting entity. *BMJ Case Reports.* 2014;**2014**
7. Dirkes K., Crombleholme T.M., Craigo S.D., Latchaw L.A., Jacir N.N., et al. The natural history of meconium peritonitis diagnosed in utero. *J. Pediatr. Surg.* 1995;**30**:979–982.
8. Casaccia G, Trucchi A, Nahom A, Aite L, Lucidi V, Giorlandino C, Bagolan P. The impact of cystic fibrosis on neonatal intestinal obstruction: the need for prenatal/neonatal screening. Pediatric surgery international. 2003 Apr;19:75 -8.
9. Chan KL, Tang MH, Tse HY, Tang RY, Tam PK. Meconiumperitonitis: prenatal diagnosis, postnatal management and outcome. Prenat Diagn 2005;25:676−82.
10. Tseng JJ, Chou MM, Ho ES. Meconium peritonitis in utero: renatal sonographic findings and clinical implications. J Chin Med Assoc 2003;66:355−9.
11. Shyu MK, Shih JC, Lee CN, Hwa HL, Chow SN, Hsieh FJ. Correlation of prenatal ultrasound and postnatal outcome in meconium peritonitis. Fetal diagnosis and therapy. 2003; 18 (4): 255-61.
12. Amorim MM, Vilela PC, Santos LC, Falbo Neto GH, Cursino O, Amaral F, Bitencourt KM. Peritonite meconial como diagnóstico diferencial de ascite fetal: relato de caso. Revista Brasileira de Ginecologia e Obstetrícia. 1999; 21:353-7.
13. Uchida K, Koike Y, Matsushita K, Nagano Y, Hashimoto K, Otake K, Inoue M, Kusunoki M. Meconium peritonitis: Prenatal diagnosis of a rare entity and postnatal management. Intractable & Rare Diseases Research. 2015;4(2):93-7.
14. Caro-Domínguez P, Zani A, Chitayat D, Daneman A. Meconium peritonitis: the role of postnatal radiographic and sonographic findings in predicting the need for surgery. Pediatric Radiology. 2018 Nov;48:1755-62.
15. Ping LM, Rajadurai VS, Saffari SE, Chandran S. Meconium peritonitis: correlation of antenatal diagnosis and

postnatal outcome-an institutional experience over 10 years. Fetal diagnosis and therapy. 2017;42(1):57-62.

16. Chola, J. M., Albert, M. T. ., Jules, N. . T. ., Manteka, K., Herman, T. K., Shombo, Mutangala, N. ., Prosper, K. L. ., Xavier, K. K. ., Prosper, K. M. K. ., & Baptiste, K. S. Z. J. . (2022). Profil Hématologique, Biochimique Et Hormonal Au Cours De La Grossesse : Cas Des Pre-Eclamptiques Versus Gestantes En Bonne Sante Apparente Dans La Ville De Lubumbashi, RDC. Journal of Medical Research and Health Sciences, 5(12), 2355–2367. https://doi.org/10.52845/JMRHS/2022-5-12-3