e-ISSN: 0975-1556, p-ISSN:2820-2643

Available online on www.ijpcr.com

International Journal of Pharmaceutical and Clinical Research 2023; 15(4); 697-703

Original Research Article

Clinical Evaluation of Uveitis in a Tertiary Care Hospital of Southern Odisha

Rajendra Kumar Behera[1], Deepak Choudhury[2]

[1]Associate Professor, Department of Ophthalmology, MKCG Medical College, Berhampur, Odisha

[2]Assistant Professor, Department of Ophthalmology, MKCG Medical College, Berhampur, Odisha

Received: 15-01-2023 / Revised: 09-03-2023 / Accepted: 05-04-2023

Corresponding author: Dr. Deepak Choudhury

Conflict of interest: Nil

Abstract

Aim: To determine the etiopathogenesis of uveitis as well as to compare and correlate the demographic profile of the study population.

Materials and Methods: 195 patients with signs and symptoms of uveitis attending the Ophthalmology department of a tertiary care health centre in southern Odisha from October 2018 to September 2020 were prospectively studied. Detail history was taken. Complete ophthalmic examination was done with slit lamp, gonioscopy and indirect ophthalmoscopy. Detail blood investigations were done. Radiological investigations were done whenever required. Results:- The female to male ratio was 1.26:1. Most affected age group was 21-40 years (47.2%). Bilateral involvement was seen in 33.8% of cases. Anterior uveitis was more common, found in 122 cases (62.6%) followed by posterior uveitis, found in 57 cases (29.2%). Acute uveitis was found in 106 cases (54.4%). Most cases (49.8%) had best corrected visual acuity of 6/12 or more. Non-granulomatous keratic precipitates were seen in 112 cases (57.4%). 57.6% cases had anterior chamber cells and 62.1% cases had anterior chamber flare. In 79 cases (40.5%), uveitis was idiopathic. Second most common etiology was herpetic i.e. 38 cases (19.5%). In posterior uveitis patients, tuberculosis was the leading cause (59.6%). Cataract was the most common complication (12.3%).

Conclusion: For a sizable proportion of patients, the cause of uveitis remains unknown despite the appropriate investigations. A thorough clinical evaluation and tailored investigation are needed for finding out the etiopathogenesis of uveitis.

Keywords: Uveitis, Keratic Precipitates, Tuberculosis, Cataract.

Introduction

The inflammatory process of the uvea is called uveitis and may cause sight threatening damage to the eye. The etiological factor in about 30% of the cases is unknown. Uveitis may be induced by infection, autoimmune disease, trauma, or malignancy. So the different forms of uveitis should be classified according to their anatomical localization i.e. anterior uveitis, intermediate uveitis, posterior uveitis, and panuveitis [1]. It has been estimated that uveitis accounts for about 10% of the visual handicap in the western world, and upto 35% of all uveitis patients have been reported to suffer significant visual impairment or legal blindness [2]. The presence in the eye of uveitogenic antigens raises the strong possibility of

autoimmune driven processes as well, similar to what is seen in the animal models. The better understanding of ocular inflammatory mechanisms has led to improved therapeutic strategies [3]. Causes of uveitis vary considerably by geographic location around the world. Awareness of such regional differences in the disease pattern is essential in deriving a region-specific list of differential diagnoses and also in understanding the predictive values of diagnostic tests which in turn facilitate the final diagnosis [4]. Hence this study was intended to determine the etiopathogenesis of uveitis as well as to compare and correlate the demographic profile of the study population.

Materials and Methods

Patients with signs and symptoms of uveitis attending the Ophthalmology Department of a tertiary care health centre in southern Odisha from October 2018 to September 2020 were prospectively studied after taking the informed consent of the patients and permission from the Ethical Committee of the institution. A total number of 195 patients with unilateral or bilateral uveitis of all ages and both sexes were studied.

Inclusion criteria: All patients who is diagnosed to have uveitis

Exclusion criteria:

1. Uncooperative patient.
2. Patients diagnosed with infective endophthalmitis.
3. Patients diagnosed with panophthalmitis.

Detail history was taken. Complete ophthalmic examination including visual status of the involved eye, ocular motility was done. Slit lamp examination was done to evaluate the anterior segment. Gonioscopy was done to see the angle of anterior chamber. Fundus examination with indirect ophthalmoscopy was performed. Intraocular tension was measured with applanation tonometer. Detail blood investigation was done. Complete blood count, erythrocyte sedimentation rate (ESR) was done. Serological tests for syphilis, HIV, rheumatoid factor was done in all cases. Urine and stool examination, Montoux test was also done. Radiological investigations like x-ray chest, lumbosacral and knee joint x-ray was also done. An anatomical diagnosis was made in all the cases as having anterior uveitis, posterior uveitis, intermediate uveitis, and panuveitis. Acute uveitis was defined as sudden onset of intraocular inflammation lasting less than 3 months. Chronic uveitis was defined as inflammation lasting more than 3 months. Recurrent uveitis was said if 2 or more episodes of inflammation were separated by a disease free period.

Results

In this present study 195 cases of uveitis were studied. 109 patients (55.9%) were females and 44.1% were males. The female to male ratio was 1.26:1. Most affected age group was 21-40 years (47.2%) followed by 41-60 years (36.9%). Bilateral involvement was seen in 33.8% of cases. Anterior uveitis was more common, found in 122 cases (62.6%) followed by posterior uveitis, found in 57 cases (29.2%). Intermediate uveitis was detected in 7 cases (3.6%) and panuveitis in 9 cases (4.6%). Acute uveitis was found in 106 cases (54.4%), Chronic in 77 cases (39.5%) and recurrent in 12 cases (6.2%).

Table 1: Correlation between onset and type of uveitis

Types	Acute	Chronic	Recurrent	Total
Anterior	92	19	11	122
Intermediate	3	3	1	7
Posterior	10	47	0	57
Pan	1	8	0	9
Total	106	77	12	195

As shown in Table 1, acute forms of uveitis was common in anterior i.e. 92 cases (75.4%). Chronic form was mostly seen in posterior uveitis i.e. 47 cases (82.4%).

Table 2: Best corrected visual acuity (BCVA) in uveitis

BCVA	Frequency	Percentage
< 1/60	5	2.6
1/60- 5/60	7	3.6
6/60	10	5.1
6/36	14	7.2
6/24	24	12.3
6/18	38	19.5
6/12	47	24.1
6/9	43	22.1
6/6	7	3.6
Total	195	100

Table 2 shows the best corrected visual acuity (BCVA) in uveitis patients at presentation. Most patients (49.8%) had BCVA of 6/12 or more. In this study non-granulomatous keratic precipitates (KP) were seen in 112 cases (57.4%). Granulomatous KP was found in 53 cases (27.2%) and stellate KP was found in 3 cases (1.5%).

Table 3: Anterior chamber cells (AC cells) grading according to SUN classification

AC cells	Frequency	Percentage
0	83	42.6
+0.5	8	4.1
+1	50	25.6
+2	39	20
+3	14	7.2
+4	1	0.5
Total	195	100

Table 4: Anterior chamber flare (AC flare) grading according to SUN classification

AC flare	Frequency	Percentage
0	74	37.9
+1	87	44.6
+2	22	11.3
+3	11	5.6
+4	1	0.5
Total	195	100

Table 5: Vitreous haze grading

Vitreous haze	Frequency	Percentage
0	171	87.7
1	17	8.7
2	4	2.1
3	2	1
4	1	0.5
Total	195	100

Table 3 shows anterior chamber cells grading. 57.6% cases had anterior chamber cells. 25.6% cases had grade +1 anterior chamber cells. Table 4 shows anterior chamber (AC) flare grading. 62.1% cases had AC flare. Grade +1 AC flare was seen in 44.6% cases. Table 5 shows grading of vitreous haze. 12.3% cases had vitreous haze. 8.1% cases had grade 1 vitreous haze. Figure 1 shows segmental posterior synechiae with festooned pupil. Figure 2 shows snowballs in intermediate uveitis.

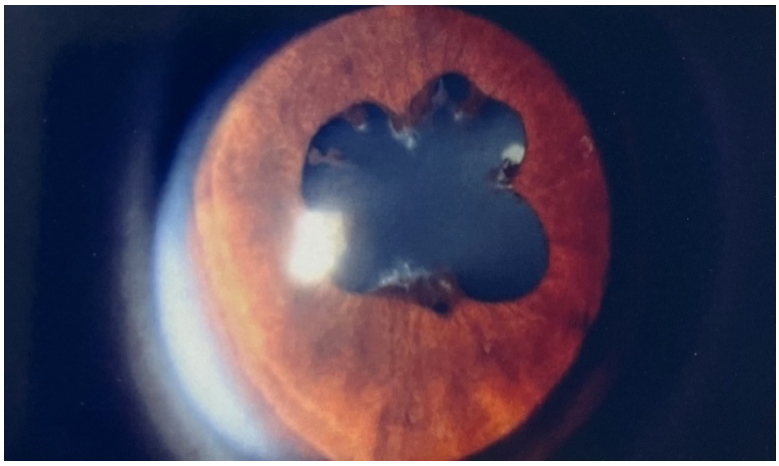

Figure 1: Segmental posterior synechiae with festooned pupil

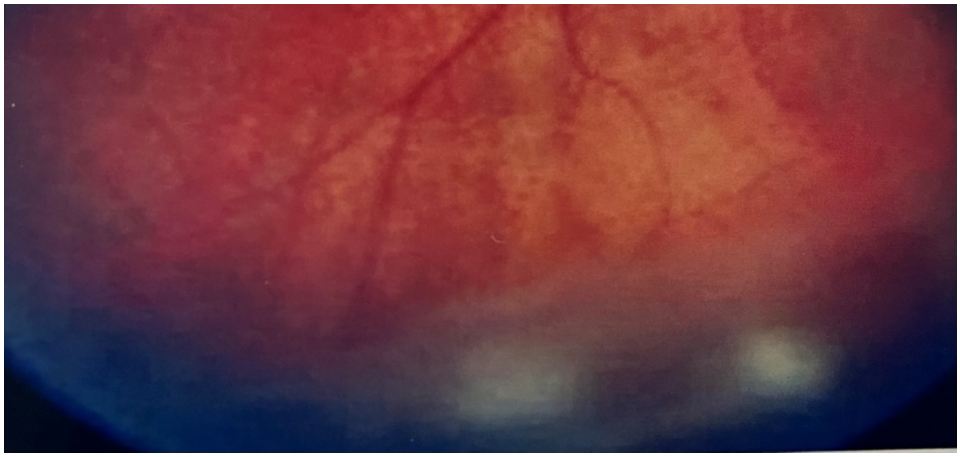

Figure 2: Snowballs in intermediate uveitis

Table 6: Etiology of uveitis

Etiology	Frequency	Percentage
HLA-B27	9	4.6
Herpes simplex virus	36	18.5
Herpes zoster virus	2	1
Idiopathic	79	40.5
Juvenile idiopathic arthitis	2	1
Posner-Schlossman syndrome	3	1.5
Rhematoid arthritis	5	2.6
Sarcoidosis	3	1.5
Syphilis	8	4.1
Tuberculosis	34	17.4
Toxoplasma	9	4.6
Vogt Koyanagi Harada syndrome	4	2.1
Total	195	100

Table 6 shows the various etiologies of uveitis. In 79 cases (40.5%), uveitis was idiopathic. Second most common etiology was herpetic i.e. 38 cases (19.5%), followed by tuberculosis i.e. 34 cases (17.4%). Most anterior uveitis cases (53.2%) and all 7 intermediate uveitis cases had idiopathic etiology. However, in posterior uveitis patients, tuberculosis was the leading cause (59.6%), followed by toxoplasmosis (15.7%). Among panuveitis patients, VKH was the leading cause i.e. 4 cases (44.4%), followed by sarcoidosis i.e. 3 cases (33.3%).

Table 7: Complications of uveitis

Complications	Frequency	Percentage
Band shaped keratopathy	2	1
Cataract	24	12.3
Cystoid macular edema	7	3.6
Choroidal neovascular membrane	2	1
Secondary glaucoma	9	4.6
Optic atrophy	3	1.5
Retinal detachment	6	3.1
Rubeosis iridis	2	1
Scleritis	8	4.1

Table 7 shows complications associated with uveitis. 58 cases (29.7%) had complications. Cataract was present in 24 cases (12.3%). Cystoid macular edema was the most common complication in posterior uveitis (5 cases). Figure 3 shows band shaped keratopathy.

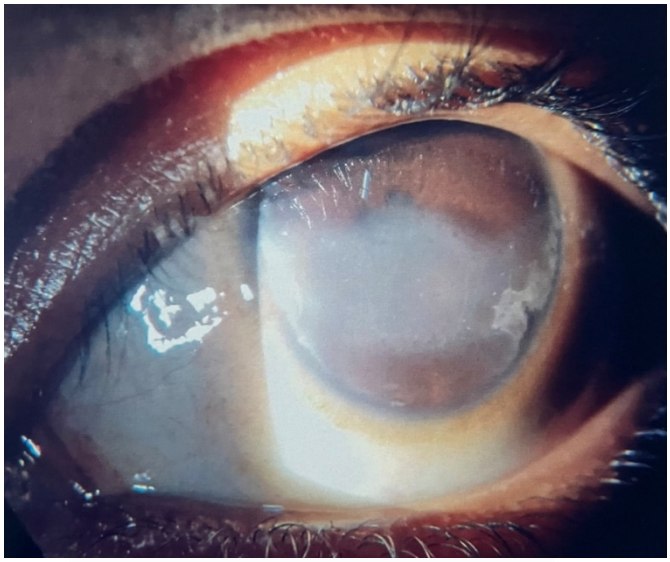

Figure 3: Band shaped keratopathy

Discussion

In our study 55.9% were females. Female to male ratio was 1.26:1. This is similar to study findings by Palsule et al [5]. In their study of 198 cases in western India, the female to male ratio was 1.25:1. However, Borde P et al in their 1 year prospective observational study in central India involving 210 patients with uveitis found that males (50.95%) were affected more than females. Most affected age group was 21-40 years (47.2%) in our study. Biswas et al in their study found maximum patients were in the age group of 20- 29 years (69.9%) [7]. Bilateral involvement was seen in 33.8% of cases in our study. Palsule et al found that 96 (51.5%) patients had bilateral disease.

Anterior uveitis was more common, seen in 122 cases (62.6%) in our study. Dipankar Das et al in their study found that anterior uveitis was most common form occurring in 47.07% cases followed by posterior uveitis of 29.87% [8]. In our study 54.4% cases presented with an acute onset. Palsule et al found that 63.1% cases had acute attack and 22.7% had chronic attack [5]. Acute forms of uveitis were common in anterior group in our study. But Borde et al found acute onset of disease was common in anterior and posterior uveitis. In intermediate and pan uveitis, most of the cases were of chronic nature [6].

Most patients (49.8%) had visual acuity of 6/12 or more in our study. Since most of the presented cases in our study were acute anterior uveitis, usually patients seek immediate medical help because of pain. In our study non-granulomatous KP was found in 57.4% cases and granulomatous in 27.2% cases. Henderly et al also reported that 51- 89% cases had non-granulomatous uveitis. In our study 40.5% cases had idiopathic etiology. Palsule et al found out that HLAB27 associated uveitis was the most common non-infectious entity and presumed ocular tuberculosis was leading cause of infectious entity in western India [5]. Rathinam et al in their study found out that among infectious uveitis, tuberculosis (30%), toxoplasmosis (7.2%) was common and among non-infectious uveitis, seronegative spondyloarthropathy was most common [4]. Biswas et al findings were quite similar to our study results. They stated the most common etiology of anterior uveitis was idiopathic (37.4%) and most common cause of posterior uveitis was tuberculosis (35%) [7]. In our study cataract was present in 12.3% uveitis cases. Cystoid macular edema was the most common complication in posterior uveitis. Our observations are consistent with Borde et al who found that 59 cases (28.09%) had complications.[9,10] Most common complication was cataract, followed by secondary glaucoma, cystoid macular edema, hypotony [6].

Conclusion

For a sizable proportion of patients, the cause of uveitis remains unknown despite the appropriate investigations. The most common anatomical type is still anterior. In general, anterior and intermediate uveitis are more idiopathic than posterior and diffuse forms of inflammation. A thorough clinical evaluation and tailored investigation are needed for finding out the etiopathogenesis of uveitis.

References

1. Suttorp-Schulten MS, Rothova A. The possible impact of uveitis in blindness: a literature survey. Br J Ophthalmol. 1996;80(9):844-8.
2. Wakefield D, Chang J. Epidemiology of Uveitis, International Ophthalmology Clinics. Spring 2005;45(2):1-13.
3. Nussenblatt, R.B. The natural history of uveitis. Int Ophthalmol. 1990;14: 303–8.
4. Rathinam S, Namperumalsamy P. Global variation and pattern changes in epidemiology of uveitis. Indian Journal of Ophthalmology. May–Jun 2007;55(3):173-83.
5. Palsule AC, Jande V, Kulkarni AA, Beke NN. Pattern of uveitis in a tertiary eye care center in Western India. J Clin Ophthalmol Res 2017;5: 127-31.
6. Borde P, Priyanka, Kumar K, Takkar B, Sharma B. Pattern of uveitis in a tertiary eye care center of central India. Indian Journal of Ophthalmology. March 2020;68(3):476-81.
7. Biswas J, Kharel R, Multani P. Changing uveitis patterns in South India - Comparison between two decades. Indian Journal of Ophthalm ology. April 2018;66(4):524-7.
8. Das D, Bhattacharjee H, Das K, Tahiliani PS, Bhattacharyya P, Bharali G, Das M. The changing patterns of uveitis in a tertiary institute of

Northeast India. Indian J Ophthalmol. 2015 Sep;63(9):735-7.

9. Henderly D, Genstler A, Smith R, Rao N. Changing patterns of uveitis. American Journal of Ophthalmology. February 1987;103(2):131-6.
10. Yadav S., Gupta D. K., Patil P. H., Tiwari A., & Soni P. To Study the Pharmacotherapy of Diabetes Mellitus Type 2 Patient in Echo Health Care & Research Centre, Indore". Journal of Medical Research and Health Sciences, 2023;6(2), 2389–2397.