

Deep Subfacial Approach for Temporomandibular Joint Ankylosis Patient with Evaluating Facial Nerve Injury by “Facial Nerve Grading System”

Santosh Mishra¹, Madhuri Shukla², Rahul Mishra³, Sushma Mishra⁴

^{1,2,3,4}Senior Dental Officer, JP Hospital, Nauvast Rewa, M.P. - 486001

Received: 23-03-2023 / Revised: 07-04-2023 / Accepted: 24-05-2023

Corresponding author: Dr Madhuri Shukla

Conflict of interest: Nil

Abstract

Background: Preservation of the functional integrity of the facial nerve (FN) is a critical measure of success in temporomandibular joint (TMJ) surgery. In spite of the development of a myriad of surgical approaches to the TMJ, FN remains at risk. The deep subfascial approach provides an additional layer of protection (the deep layer of the temporalis fascia and the superficial temporal fat pad) to the temporal and zygomatic branches of the FN and thus, is the safest method to avoid FN injury.

Objectives: To assess FN injury following TMJ surgery using deep subfascial approach and measuring it on House and Brackman facial nerve grading system (HBFNGS).

Materials and Methods: Twenty TMJs in 18 patients were operated for TMJ ankylosis, using “the deep subfascial approach.” FN function was assessed postoperatively at 24 h, 1 week, 1 month, 3 months, 6 months using HBFNGS. Statistical analysis was done using SPSS 16.0.

Results: Of 20 surgical sites 3 sites showed Grade III (moderate) FN injury and 17 sites showed Grade II (mild) FN injury at 24 h. The condition improved with time with full recovery of FN at all surgical sites at 6 months.

Conclusion: The deep subfascial approach has a distinct advantage over the conventional approaches when dissecting the temporal region and is the safest method to avoid injury to FN.

Keywords: Assessment using House and Brackman facial nerve grading system, deep subfascial approach, facial nerve, temporo mandibular joint ankylosis.

This is an Open Access article that uses a funding model which does not charge readers or their institutions for access and distributed under the terms of the Creative Commons Attribution License (<http://creativecommons.org/licenses/by/4.0>) and the Budapest Open Access Initiative (<http://www.budapestopenaccessinitiative.org/read>), which permit unrestricted use, distribution, and reproduction in any medium, provided original work is properly credited.

Introduction

The facial nerve (FN) is the main anatomical structure that the surgeon should consider in performing a surgical approach to the temporomandibular joint (TMJ). Injury to its branches during TMJ surgery is well documented. [1,2] Preservation of the functional integrity of the FN is a critical measure of success in TMJ surgery. Impairment of FN function interferes with emotional expression, causes functional deficits, and can create a cosmetic deformity. [3,4,5,6] Depending

upon the type of approach used for TMJ surgery, FN paresis has been found in 1.5–32% of patients, usually disappearing within 6 months. [7,8] The temporal branch is among the most vulnerable of the FN branches.

In cases of FN dysfunction after TMJ surgery, it is necessary to assess the degree and type of nerve injury. This will enable recovery to be evaluated thus allowing the surgeon to determine the optimum

management for each case. In spite of the development of a myriad of surgical approaches to the TMJ, FN remains at risk. The deep subfascial approach provides an additional layer of protection (the deep layer of the temporalis fascia and the superficial temporal fat pad) to the temporal and zygomatic branches of the FN and thus, is the safest method to avoid FN injury. [9] The present study was conducted to assess FN injuries with House and Brackmann facial nerve grading system (HBFNGS) in patients of TMJ ankylosis where surgery was performed using deep subfascial approach.

The Deep Subfascial Approach

Two preauricular dissection techniques are described in literature to expose the TMJ, one is the suprafascial approach described by Gosain *et al.*, [10] wherein the dissection is superficial to the superficial temporal fascia. The second is subfascial procedure proposed by Alkayat and Bramley [11] which involves dissection

between the 2 layers of the temporalis fascia. A modification of subfascial approach, the deep subfascial approach has been used by Rowe, [12] Toscano, [13] and Hochberg *et al.*, [14] wherein dissection is carried out in the plane beneath both layers of the temporalis fascia. Later the technique was used by Politi *et al.*, [9] Kenkere *et al.*, [15] Candirli and Celik, [16] Gokkulakrishnan *et al.*, [17] and this same technique is being advocated by us. The difference between the routine subfascial approach and the deep subfascial approach is explained in Figures 1 and 2. [1,9] In comparison with the traditional subfascial way described by Al-Kayat and Bramley, [11] present approach offers an additional protective layer for the FN (the deep layer of deep temporalis fascia and temporal fat pad). According to Politi *et al.* [9] the deep subfascial approach represents the safest method for TMJ surgery to avoid injury of FN [9,14,15,16,17] [Figures 1 and 2].

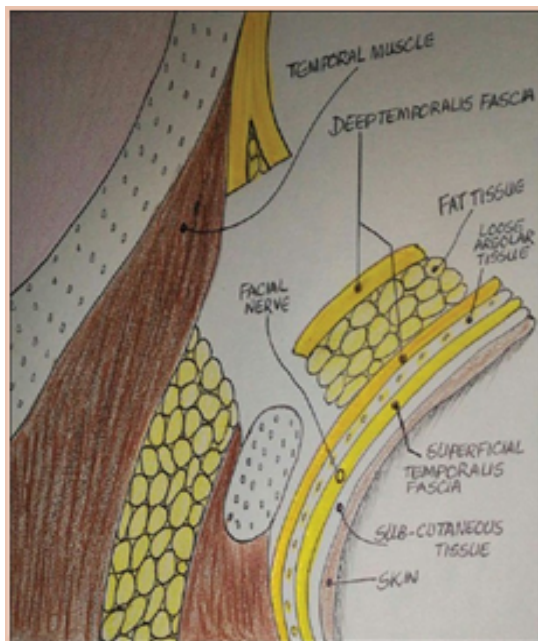


Figure 1: Dissection planes in subfascial region

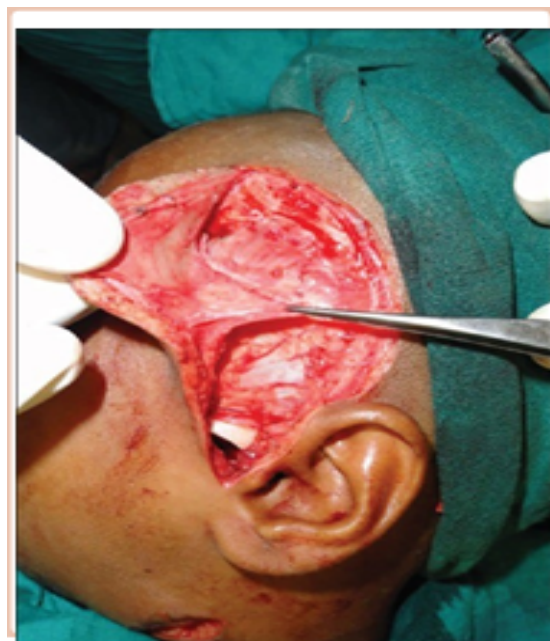

Figure 2: Clinical appearance of dissection layers

The House and Brackmann facial nerve grading system HBFNGS, [18,19,20] a clinical method of evaluating FN injury is quite

comprehensive and includes important items such as the appearance of the frontal, periorbital and peribuccal musculature, both at rest and in motion [Tables 1 and 2].

It was introduced in 1983 for clinical use and was modified by Brackmann in 1985. On the recommendation of the Facial Nerve Disorders Committee it was formally adopted as the universal standard for

reporting FN function by the American Academy of Otolaryngology Head and Neck Surgery in 1984. It has interobserver reliability of 93% among the different evaluators.

Table 1: Clinical examination of facial nerve

Movement	Nerve assessed
At rest [Figure 3a]	All the branches of facial nerve
Raising the eyebrow [Figure 3b]	Temporal branch of facial nerve
Closing the eyes with minimal and maximal effort [Figures 3c and d]	Zygomatic branch of facial nerve
Blowing the mouth [Figure 3e]	Buccal branch of facial nerve

Table 2: House-Brackmann facial nerve grading system

Grading	Description	Characteristics
1	Normal	Normal function in all areas of the facial nerve
2	Mild dysfunction	Clinical observation Slight muscular weakness observed on examination There may be disordered movements At rest, the face appears symmetrical and with tones Movements Forehead Moderate to good function Eye Complete closure with minimum Effort Mouth Slight asymmetry
3	Moderate dysfunction	Clinical observation Clear difference between the two hemifaces but not total asymmetry Nonserious disordered movements may be observed Contracture of the facial muscles or spasm in hemifaces Movements Forehead Moderate mobility Eye Total closure with effort Mouth Weakness of the muscle at maximum effort
4	Moderately severe	Clinical observation Clear weakness and/or almost total asymmetry At rest, normal symmetry and maintenance of muscle tone Movements Forehead No movement Eye Incomplete closure Mouth Asymmetry at maximum effort
5	Severe dysfunction	Clinical observation Hardly any mobility observed Asymmetry at rest Movements Forehead No movement Eyes Incomplete closure Mouth Hardly any mobility
6	Total palsy	No movement in any part of the facial nerve

This study was conducted in the Department of Oral and Maxillofacial Surgery, SS Medical College Rewa during the time period of January 2018 to November 2019. This study was approved by the ethical committee and all participants signed an informed consent agreement. A total of 18 patients were included. All patients were treated for TMJ

ankylosis (16 unilateral and 2 bilateral making total of 20 surgical sites) as confirmed using CBCT. Of 18 patients 17 were getting operated for the first time and 1 patient was a case of re-ankylosis. Of 20 surgical sites gap arthroplasty was performed in 17 surgical sites, interpositional arthroplasty was performed in 3 surgical sites using costochondral

grafting. The surgical approach used was deep subfascial approach as described by Politi *et al*^[9]. The mean age of the patients in the study was 22.80 years (6–45 years) with male to female ratio of 1:8. The mean maximal inter-incisal mouth opening in the preoperative period was 9.67 mm (range 0–12 mm).

Assessment of FN function was done pre- and post-operatively at 24 h, 1 week, 1 month, 3 months, and 6 months using HBFNGS. FN functions were assessed by the same surgeon, observation was made at rest, forehead wrinkling, raising the

eyebrows, eye closure, and smiling. The pre- and post-operative photographs were taken by the same photographer using the same camera and magnification. The patients were photographed facing the camera in the following positions: At rest, raising the eyebrows, closing the eyes with minimum effort and with maximal efforts, blowing the mouth [Figure 3]. The patients were assessed using HBFNGS and the data were statistically analyzed using SPSS Inc. released 2007. SPSS for windows, version 16.0 (SPSS Inc., Chicago).

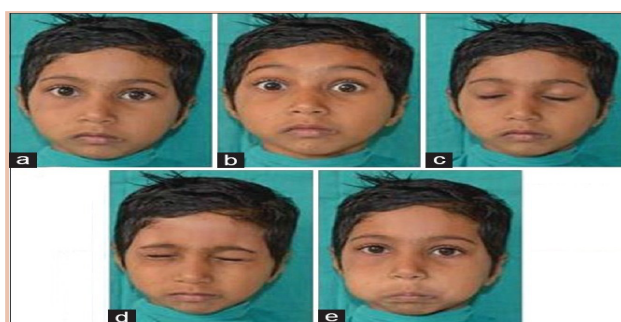

Figure 3: Clinical Examination of facial nerve function. (a) At rest. (b) Raising eyebrows. (c) Eye closure with minimum effort. (d) Eye closure with maximum effort. (e) Blowing the mouth

Of 20 surgical sites, at 24 h, the 17 sites had Grade II nerve injuries and 3 sites had Grade III nerve injury. After 1 week, all the 17 surgical sites showing Grade II injuries shifted to Grade I, i.e., No injury. After 3 months, the 3 surgical sites, which had Grade III injuries

converted to Grade II. At 6 months, all 20 surgical sites had normal FN function. Complete recovery at all surgical sites proves the point that the deep subfascial approach is the safest among the preauricular approaches as far as FN injury is concerned [Table 3].

Table 3: Results using House–Brackman facial nerve grading system

Grading	24 h	1 week	1 month	3 months	6 months
Grade I					
Normal facial nerve function	0	17	17	17	20
Grade II					
Mild facial nerve dis-function	17	0	0	3	0
Grade III					
Moderate facial nerve dis-function	3	3	3	0	0
Total surgical sites observed	20	20	20	20	20

The 3 surgical sites having grade 3 injury at 24 h were those where inter-positional arthroplasty was performed. This shows that the frequency of FN injury is related to

the degree of difficulty involved in the surgery.

No sign of infection was observed in any patient in the follow-up appointments.

Presence of Frey's syndrome defined as "perspiration of skin around the preauricular area while eating" was assessed on follow at 1 week, 1 month, 3 months, and 6 months postoperatively and was not evident in any of the patients.

In all the surgical sites, at 6 months follow-up, scar was imperceptible and esthetically acceptable.

Over the years, a number of surgical approaches to TMJ have been developed to attain the goal of successful removal of ankylosis mass, treating TMJ pathologies and condylar fracture. The most commonly used, safe and cosmetically acceptable surgical method is a preauricular approach [21,22,23,24,25,26, 27,28] which has been modified over the years by various authors.

The anatomy of the temporal region has been described by several authors, but the fascial layers are not always named with the same terminology. In our study, when we proceeded from skin toward the temporal muscle we found three of temporal region are described by Politi *et al.*, [9] Kenkere *et al.*, [15] Candirli and Celik, [16] Gokkulakrishnan *et al.* [17]

With the performance of "deep subfascial approach" we can minimize various complications associated with routine preauricular techniques such as injury to the FN, inadequate exposure of the joint, excessive hemorrhage, paresthesia of the auriculotemporal nerve, and auriculotemporal syndrome. [9,15,16,17]

In our study, 17 (85%) surgical sites out of 20 surgical sites showed mild dysfunction of the temporal branches of the FN at 24 h that recovered to normal at 1 week follow-up. FN function did not deteriorate on further follow-up at 1 month, 3 months, and 6 months. Moderate dysfunction of the branches of the FN was seen in 3 (15%) surgical sites out of 20 surgical sites at 24 h follow-up, 1 week, 1 month, at 3 months FN dysfunction recovered to mild and at the 6th month FN dysfunction recovered completely to the normal. Similar results

were obtained by Weinberg and Kryshtalskyj [29] who used preauricular approach and observed incidence of FN injury in 9 patients (10.84%) in which temporal and zygomatic branches were involved and normal FN function returned in 9–14 weeks except in 1 patient who showed a mild deficit in zygomatic branch recovered at 20 weeks. Bansal *et al.*

[30] also reported incidence of transient temporal nerve weakness in 46.67% joints operated by the preauricular approach and 13.33% in the postauricular approach, zygomatic nerve weakness was observed in 26.67% cases in preauricular and 0% cases of postauricular approaches. Vasconcelos *et al.* [31] used preauricular approach and concluded the most frequent complication was transient FN paralysis and it was encountered in two patients (25%) out of 8 and recovered in 3 months. do Egito Vasconcelos *et al.* [18] also observed FN injury in 12.5% patient by using preauricular approach. Narayanan *et al.* [32] observed the incidence of FN injury by using retromandibular approach in one patient (3%), which resolved within 2 weeks. Candirli and Celik [16] used deep sub fascial approach and found mild dysfunction of FN in 1 of the 18 patients, complete resolution was seen even in this particular patient after 4 months.

Gokkulakrishnan *et al.* [17] while using the deep subfascial approach observed that 78.9% patients had different grades of facial injury at 24 h, which gradually improved and came to normal limits in 1–3 months postoperatively. Politi *et al.* [9] and Kenkere *et al.* [15] while using the deep subfascial approach observed no permanent FN injury.

This high frequency of nerve injury in our study up to 1 week could have been either due to heavy retraction causing mild to moderate compression or stretching of nerve fibers resulting in neuropraxia. FN injury may also be caused by inadvertent suture ligation of FN branches. Thus care must be exercised particularly during

wound closure to prevent the injury and to avoid taking deep blind bites with the suture needle. The use of electrocautery in deep sites that are potentially close to FN branches should be avoided. Crushing or clamping tissue indiscriminately, particularly during episodes of brisk bleeding should be avoided. [16,29] Excessive swelling and or hematoma formation may result in transient FN injury and to prevent this surgical drains should be placed and anti-inflammatory drugs should be administered.

In our study, interpositional arthroplasty using costochondral graft was done in 3 (15%) surgical sites out of 20 surgical sites. We found all patients presented with moderate dysfunction of the temporal branch of the FN according to the HBFNGS on the follow-up at 24 h and recovered to mild at 3 months follow-up and normal at 6 months follow-up. This in fascial layers within the temporal region: The superficial temporalis fascia and the deep temporalis fascia, which consists of a superficial layer and a deep layer. This is in accordance with various studies where identification of the fascial layers of [17,33] which show that with interpositional arthroplasty and increased duration of surgery, the chances of FN injury also increases.

In our study, 1 (5%) patient out of 20 patients had a preoperative diagnosis of recurrent ankylosis. This patient presented mild dysfunction of the branches of FN at 24 h and recovered to normal at 1 week follow-up. FN function did not deteriorate on further follow-up at 1 month, 3 months, and 6 months. The increased incidence of FN injury in patients who have undergone previous TMJ surgery may be explained by the fact that surgical scarring leads to fibrosis and distortion of the fascial layers and increases the difficulty of establishing precise tissue planes during the dissection. Especially in secondary TMJ surgery, the planes of dissection can be obscured by scars. Weinberg and Kryshchuk [29] observed that incidence of FN injury by

using preauricular approach was greater in patients who had undergone previous TMJ surgery (17.64%) than in patients with previously unoperated joints (9%). Nogueira *et al.* [34] also used preauricular approach and observed that 75% of the patients with dysfunction of the FN had undergone at least one operation prior to the study. As only one patient of reankylosis was operated in our study so this sample size is not enough to come to any conclusion.

Thus the FN injury was transient in all the cases. Majority of patients recovered at 1 week follow-up and few patients recovered at 6 months follow-up. Although the study was done on smaller number of patients, further longitudinal interventional studies with larger sample size and long-term follow-up period are essential to determine better results and statistics.

On the basis of our study, we conclude that the “deep subfascial approach” to the TMJ represents the safest among the preauricular TMJ approaches to avoid injury of FN. The plane of dissection is distinctly identifiable and reliable, and the technique is simple to use with basic knowledge of the anatomy of the temporal region. The HBFNGS is a reliable tool for evaluating the degree of FN injury.

Declaration of patient consent

The authors certify that they have obtained all appropriate patient consent forms. In the form the patient(s) has/have given his/her/their consent for his/her/their images and other clinical information to be reported in the journal. The patients understand that their names and initials will not be published and due efforts will be made to conceal their identity, but anonymity cannot be guaranteed.

Reference

1. Hall MB, Brown RW, Lebowitz MS. Facial nerve injury during surgery of the temporomandibular joint: A comparison of two dissection

- techniques. *J Oral Maxillofac Surg.* 1985; 43:20–3.
2. Dolwick MF, Kretschmar DP. Morbidity associated with the preauricular and perimeatal approaches to the temporomandibular joint. *J Oral Maxillofac Surg.* 1982; 40:699–700.
 3. Evans RA, Harries ML, Baguley DM, Moffat DA. Reliability of the House and Brackmann grading system for facial palsy. *J Laryngol Otol.* 1989; 103:1045–6.
 4. Engström M, Jonsson L, Grindlund M, Stålberg E. House-Brackmann and Yanagihara grading scores in relation to electroneurographic results in the time course of Bell's palsy. *Acta Otolaryngol.* 1998; 118:783–9.
 5. Satoh Y, Kanzaki J, Yoshihara S. A comparison and conversion table of 'the House-Brackmann facial nerve grading system' and 'the Yanagihara grading system'. *Auris Nasus Larynx.* 2000; 27:207–12.
 6. Mackinnon SE, Dellon AL. 1st ed. New York: Thieme Medical; *Surgery of Peripheral Nerve*; 1988; 638.
 7. Nellestam P, Eriksson L. Preauricular approach to the temporomandibular joint: A postoperative follow-up on nerve function, haemorrhage and esthetics. *Swed Dent J.* 1997; 21: 19–24.
 8. Alsén B, Svensson B, Adell R. Facial nerve injuries in temporomandibular joint surgery. *Tandlakartidningen.* 1994; 18:1157.
 9. Politi M, Toro C, Cian R, Costa F, Robiony M. The deep subfascial approach to the temporomandibular joint. *J Oral Maxillofac Surg.* 2004; 62:1097–102.
 10. Gosain AK, Sewall SR, Yousif NJ. The temporal branch of the facial nerve: How reliably can we predict its path? *Plast Reconstr Surg.* 1997;99: 1224–33.
 11. Al-Kayat A, Bramley P. A modified pre-auricular approach to the temporomandibular joint and malar arch. *Br J Oral Surg.* 1979;17: 91–103.
 12. Rowe NL. Surgery of the temporomandibular joint. *Proc R Soc Med.* 1972; 65:383–8.
 13. Toscano P. The Temporo-frontal Fascio-cutaneous Flap in Orbitomalarzygomatic Surgical Approach. *Proceedings of the VIII Annual Meeting of the Italian Society of Maxillofacial Surgery.* 1993:4–9.
 14. Hochberg J, Kaufman H, Ardenghy M. Saving the frontal branch during a low front-orbital approach. *Aesthetic Plast Surg.* 1995; 19:161–3.
 15. Kenkere D, Srinath KS, Reddy M. Deep subfascial approach to the temporal area. *J Oral Maxillofac Surg.* 2013; 71: 382–8.
 16. Candirli C, Celik S. Efficacy of deep subfascial approach to the temporomandibular joint. *J Craniofac Surg.* 2012;23: e126–9.
 17. Gokkulakrishnan S, Singh S, Sharma A, Singh AK, Borah R. Facial nerve injury following surgery for temporomandibular joint ankylosis: A prospective clinical study. *Indian J Dent Res.* 2013; 24:521.
 18. do Egito Vasconcelos BC, Bessa-Nogueira RV, da Silva LC. Prospective study of facial nerve function after surgical procedures for the treatment of temporomandibular pathology. *J Oral Maxillofac Surg.* 2007; 65:972–8.
 19. House JW, Brackmann DE. Facial nerve grading system. *Otolaryngol Head Neck Surg.* 1985; 93:146–7.
 20. House JW. Facial nerve grading systems. *Laryngoscope.* 1983;93:1056–69.
 21. Risdon F. Ankylosis of temporomandibular joint. *J Am Dent Assoc.* 1934; 21:1933–7.
 22. Bellinger DH. Temporomandibular joint ankylosis and its surgical correction. *J Am Dent Assoc.* 1940;27:1563.[Google Scholar]
 23. Milch H. Bayonet incision for temporomandibular joint arthrotomy.

- Am J Orthodont Oral Surg. 1938;24: 287.
24. Mccann CF, Mallett SP, Houghton JD, Atwood DA. Bilateral subcondylar osteotomy: Report of case. J Oral Surg. 1965; 23:240–4.
 25. Rowe NL, Killey HC. Fracture of the Facial Skeleton. 2nd ed. Baltimore: William & Wilkins; 1968.
 26. Giles HV. A useful incision to the parotid gland and fractures of the mandible. Int Surg. 1969; 51:76–7.
 27. Thoma KH. Oral Surgery. I. St Louis: Mosby; 1969. p. 88. [Google Scholar]
 28. Benech A, Arcuri F, Baragiotta N, Nicolotti M, Brucoli M. Retroauricular transmeatal approach to manage mandibular condylar head fractures. J Craniofac Surg. 2011; 002022:641–7.
 29. Weinberg S, Kryshtalskyj B. Facial nerve function following temporomandibular joint surgery using the preauricular approach. J Oral Maxillofac Surg. 1992; 50:104 8–51.
 30. Bansal V, Kumar S, Mowar A, Yadav A, Khare G. The post-auricular approach for gap arthroplasty – A clinical investigation. J Craniofac Surg. 2012; 40:500–5.
 31. Vasconcelos BC, Bessa-Nogueira RV, Cypriano RV. Treatment of temporomandibular joint ankylosis by gap arthroplasty. Med Oral Patol Oral Cir Bucal. 2006;11: E66 –9.
 32. Narayanan V, Kannan R, Sreekumar K. Retromandibular approach for reduction and fixation of mandibular condylar fractures: A clinical experience. Int J Oral Maxillofac Surg. 2009; 38:835–9.
 33. Arcuri F, Brucoli M, Benech A. Analysis of the retroauricular transmeatal approach: A novel transfacial access to the mandibular skeleton. Br J Oral Surg. 2012; 50:22–6.
 34. Nogueira RV, Vasconcelos BC. Facial nerve injury following surgery for the treatment of ankylosis of the temporomandibular joint. Med Oral Patol Oral Cir Bucal. 2007 12: E160–5.