e-ISSN: 0975-1556, p-ISSN:2820-2643

Available online on www.ijpcr.com

International Journal of Pharmaceutical and Clinical Research 2023; 15(5); 1793-1800

Case Series

Parapharyngeal Tumours and its Management: A Study on 12 Cases

Perla Ambika[1], Maringanti Deepthi[2], Bhupender Singh Rathod Jatoh[3], Bhuvaneshwari Ganesan[4]

[1]Assistant Professor, Department of ENT, Gandhi Hospital / Medical College, Secunderabad, Telangana, India

[2]Assistant Professor, Department of ENT, Gandhi Hospital / Medical College, Secunderabad, Telangana, India

[3]Professor, Department of ENT, Gandhi Hospital / Medical College, Secunderabad, Telangana, India

[4]Junior Consultant, St. Thomas Hospital, Chennai, India

Received: 15-03-2023 / Revised: 30-03-2023 / Accepted: 30-04-2023

Corresponding author: Dr. Perla Ambika

Conflict of interest: Nil

Abstract

Background: The parapharyngeal space is an intriguing compartment of the head and neck. Pre-operative diagnostic accuracy has improved with the advent of CECT and MRI with fat suppression sequences and gadolinium for contrast. TORS has the approval of the US Government's Food and Drug Administration (FDA) for use in early oropharyngeal cancers and benign lesions of the head and neck since 2009. This study is to have a clinical overview of the tumors of parapharyngeal space and various approaches in managing them.

Methods: A prospective observational study was conducted over a period of 12 months in tertiary care centre, patients with parapharyngeal tumors of either age and sex of 10-60 years taken and patients unfit for surgery and who are not given consent were excluded.

Results: There were 3(25%) males and 9(75%) females in the study. Average ages are 30-50 years,: post operatively 10 patients out of 12 patients of our study did not develop any new symptoms after the surgery in the immediate postoperative period including patients with preoperative vagal nerve palsy. 2 patients developed postoperative complications.

Conclusion: No difference in surgical outcome with respect to patient age and sex. Age predilection was more among middle age group 30-50yrs,the risk of postoperative cranial nerve palsies are more with carotid body tumor Surgical resection may need to be extended to encompass the tumor by means of mandibulotomy .30% of these tumors are genetic in origin,3% are secretory,10% are multicentric.

Keywords: CT scan, MRI, tumors, TORS, FDA.

Introduction

One fascinating area of the head and neck is the parapharyngeal space. Only 0.5% of all head and neck masses are found there, but the atypical pathology and close proximity to important anatomical structures pique the

attention of surgeons, radiologists, and pathologists.[1]

A wide range of primary diseases may be present in lesions of the parapharyngeal space.5, 6 with the development of multi-planar radiological imaging, such as ne-sliced computerised tomography (CT) with contrast and magnetic resonance imaging (MRI) with fat suppression sequences and gadolinium for contrast, pre-operative diagnostic accuracy has increased. Histological diagnosis has been enhanced by image-guided fine-needle aspiration cytology. This enables a better comprehension of the nature of these lesions and a better strategy for treating them surgically.[2,3]

The use of transoral robotic surgery (TORS) for the treatment of benign and malignant oropharyngeal tumours has grown in popularity. Since 2009, the Food and Drug Administration (FDA) of the US Government has approved TORS for use in the treatment of benign head and neck lesions and early oropharyngeal cancer.[4]

The da Vinci surgical robotic system (Intuitive Surgical Inc., Sunnyvale, California) offers tremor filtration and motion scaling of robotic instruments, together with three-dimensional, high-resolution visual access with magnification.[5] This permits precise dissection and allays prior worries about controlled dissection around crucial neurovascular systems and tumour spillage raised against transoral approaches to the parapharyngeal area. This study aims to provide a clinical overview of parapharyngeal space tumours and different management options.[6,7]

Materials and Methods

A prospective study was conducted in tertiary care centre for a period of 12 months,

Study design: Prospective observational study.

Study place: Dept. of ENT and Head & Neck surgery.

Study period: 12 months,

Sample size: 12 patients, Follow up – for 6-12 months.

Inclusion criteria:

1. Patients With Parapharyngeal Tumors
2. Patients Belonging to Either Sex, Age Group 10-60 years.

Exclusion criteria:

1. Patients Not Willing to Participate
2. Patients Below10 Years and Above 60 Years
3. For Surgery: Patients with Poor General Condition and Comorbidities.

Methodology

Out of 12 patients who fulfilled the inclusion criteria for the study, all 12 patients taken consent, videolaryngoscopy, MRI, CT done to find any abutment of deep lobe of parotid gland, central cystic component, splaying and if any narrowing of carotid lumen by the tumour.

Results

Demography a total of 12 cases were randomly selected as per inclusion criteria and exclusion criteria

Table 1: Sex incidence

Sex	No. of Cases	Percentage
Male	3	25%
Female	9	75%

There were 3(25%) males and 9(75%) females in the study. FIG 7: Gender Distribution of patients in the present study.

Table 2: Age incidence

Age	0-30 yrs	30-50yrs	>50yrs
No of cases	3	8	1
Percentage	25%	67%	12%

The age of subjects ranged from 10 years to 60 years. The average of ages was 30-50 years.

Table 3: Distribution based on affected side and associated symptoms

Presenting Features	Number of Cases	Percentage (%)
Swelling	12	100
Pain	9	9
Eustachian tube obstruction	2	16
Ear symptoms	3	3

This table shows swelling: 12 cases (100%), pain: 9 cases (9%), Eustachian tube obstruction: 2 cases (16%), and ear symptoms: 3 cases (3%).

Table 4: Distribution of CECT and MRI significant findings

Findings	Number of Cases	Percentage (%)
Abutting the deep lobe of parotid gland	12	8
Central cystic component	9	8
Splaying of carotid	2	25
Narrowing of lumen	3	8

The results of the study can be summarized as follows: Among the cases studied, 8% (n=12) showed abutting of the deep lobe of the parotid gland, 8% (n=9) had a central cystic component, 25% (n=2) exhibited splaying of the carotid, and 8% (n=3) had narrowing of the lumen.

Table 5: Rate of complications in the study (pre-op)

Complications Cranial Nerves Involved	Number	Percentage
Vagus Nerve	2	16
Glossopharyngeal, Vagus, Hypoglossal	2	16

The complications related to cranial nerves involvement observed in the study can be summarized as follows: 16% (n=2) of cases experienced involvement of the vagus nerve, and 16% (n=2) of cases exhibited involvement of the glossopharyngeal, vagus, and hypoglossal nerves.

Table 6: Types of approaches

Type of Approach	Number	Percentage
Transoral Endoscopic Approach	2	16.6
Transcervical Approach	10	83.3

The types of approaches used in the study can be summarized as follows: 16.6% (n=2) of cases utilized the transoral endoscopic approach, while 83.3% (n=10) of cases employed the transcervical approach.

Table 7: Various histopathological diagnosis in the study

Diagnosis of Cases	Number Of Cases
Vagal schwannomas	6
Carotid body tumour	2
Malignancy	2
Pleomorphic adenoma of deep lobe of parotid	1
Miscellaneous (tuberous sclerosis) Unoperated	1

The diagnoses of the cases in the study included 6 cases of vagal schwannomas, 2 cases of carotid body tumors, 2 cases of malignancy, 1 case of pleomorphic adenoma of the deep lobe of the parotid, and 1 case of miscellaneous (tuberous sclerosis) that remained unoperated.

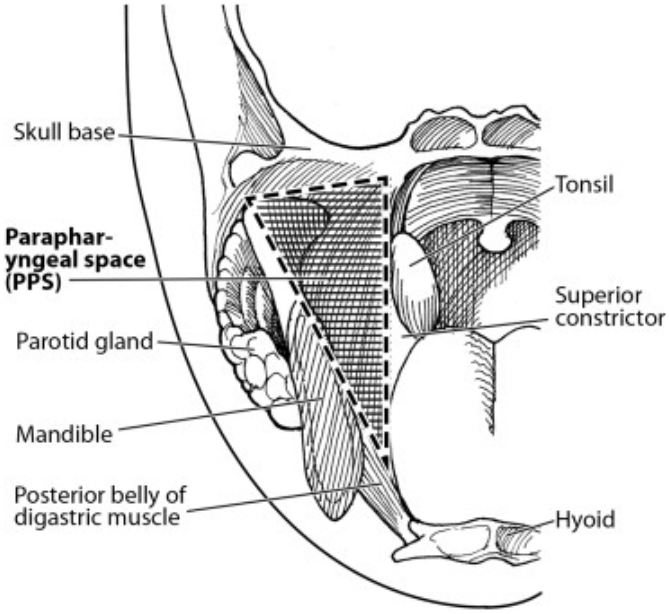

Figure 1: Parapharyngeal Space

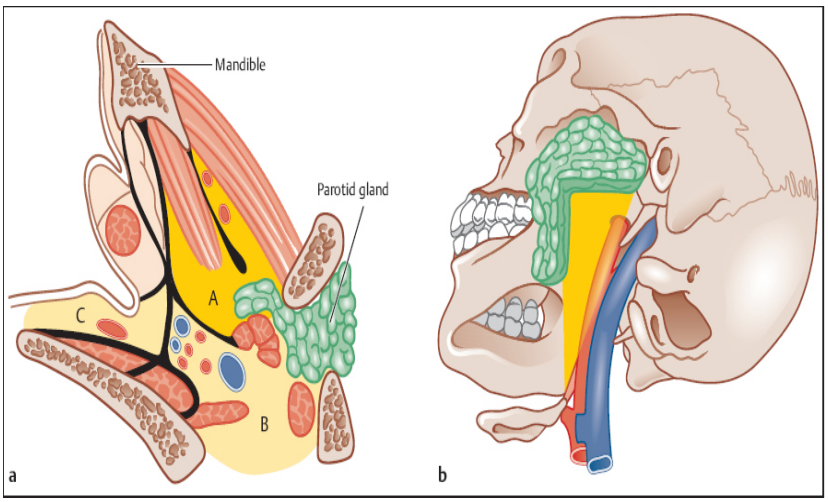

Figure 2: A- Prestyloid Compartment, B- Poststyloid Compartment C- Skull Base

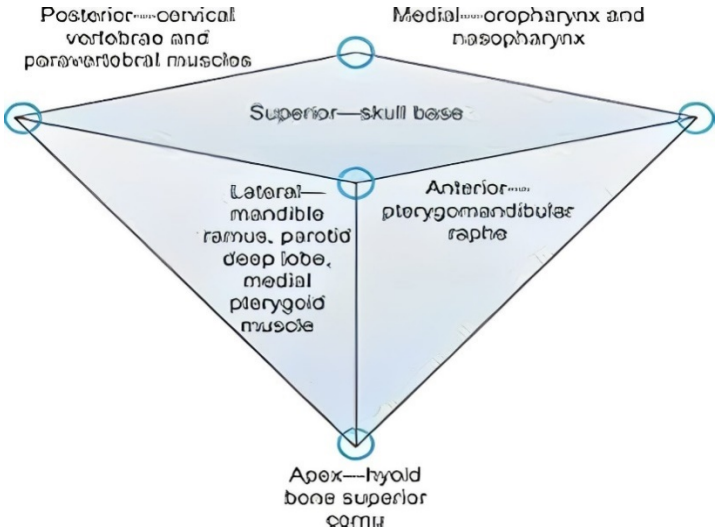

Figure 3: Inverted Pyramid Shape of Parapharyngeal Space

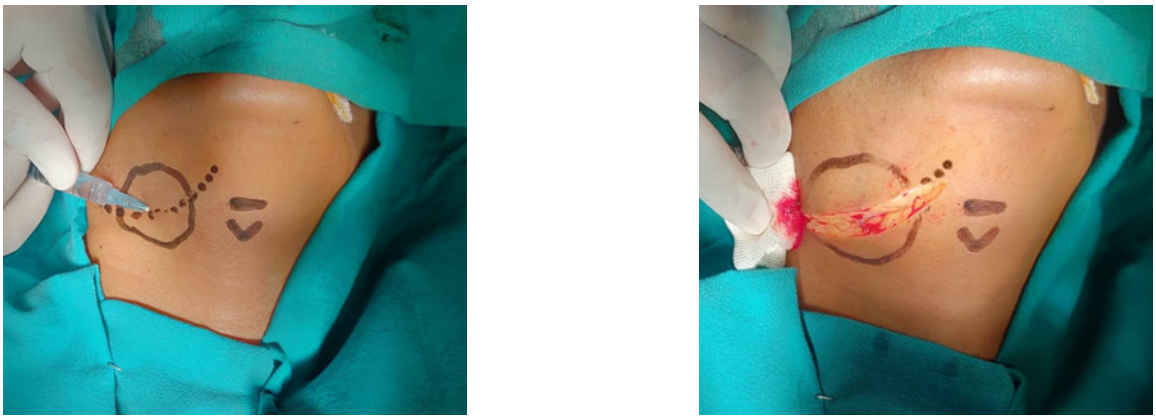

Figure 4: Incision in Case of Vagal Schwannoma

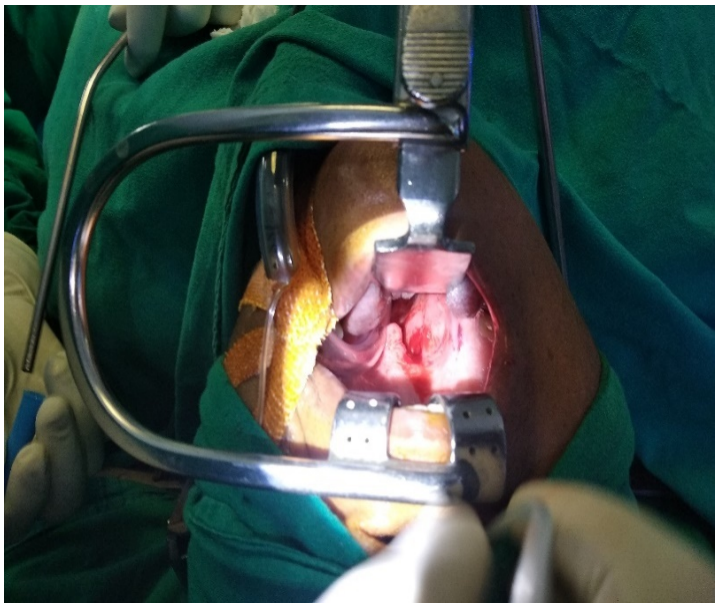

Figure 5: Transoral Incison

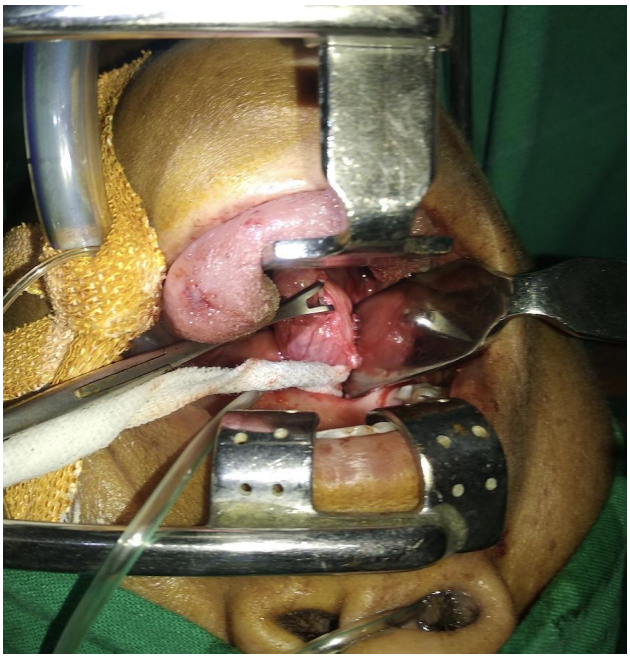

Figure 6: Blunt Dissection

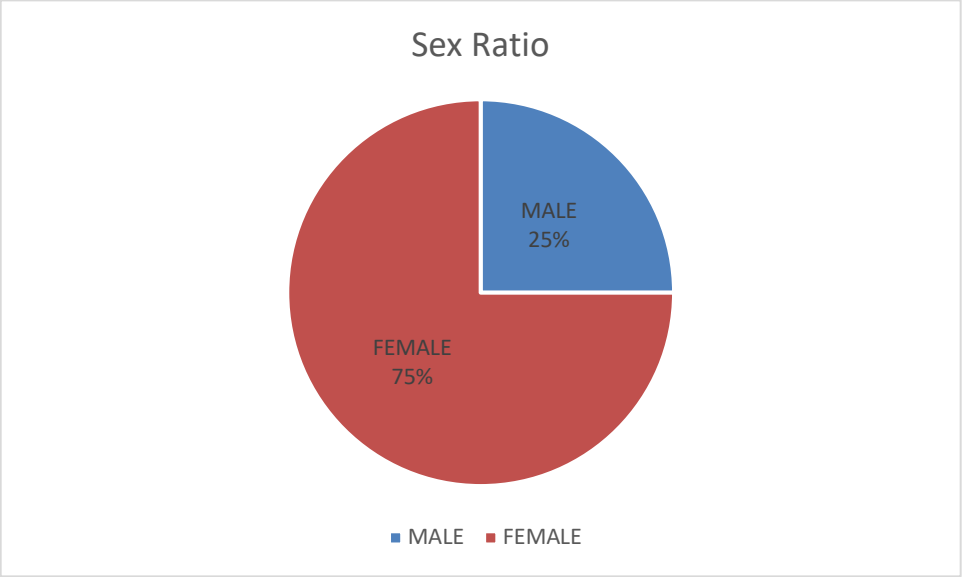

Figure 7: Sex Ratio

Discussion

The study was conducted in a tertiary care teaching institute, over a period of 12 months, The objective was to investigate the types of approaches used during parapharyngeal tumor excision. A total of 12 patients were selected and recruited based on inclusion criteria.

The study comprised 3 (25%) male and 9 (75%) female participants. Among them, 5 (41%) patients developed associated ear symptoms. Interestingly, 2 patients presented

with unilateral vagal palsy before the surgery. Furthermore, postoperative videolaryngoscopic examination revealed cranial nerve palsy in 2 patients. These findings highlight the importance of considering preoperative and postoperative cranial nerve function in patients with parapharyngeal tumors.[8]

The study findings were compared with previous research conducted on parapharyngeal space tumors. One study conducted in 2014 reviewed 44 cases and reported 3 patients with cranial nerve palsy on preoperative evaluation. Another study in 2016 documented a case of neurofibrosarcoma with preoperative vagal palsy. The occurrence of postoperative cranial nerve palsy during parapharyngeal tumor removal has been reported in several other studies as well.[9]

Postoperative cranial nerve palsy is not an uncommon occurrence during the removal of neuronal tumors in the parapharyngeal space. Several references, such as studies by Ricardo L. Carrau, Jonas T. Johnson, and Eugene N. Myers in 1997, Rajasekar MK and Vijaynivas A in 2015, and Praveen D Shivanandappa *et al*., have discussed the management and clinical approach to parapharyngeal tumors and highlighted the occurrence of postoperative cranial nerve palsy.[10-12]

The study also identified certain limitations. While the transcervical approach is commonly preferred for tumors involving the parapharyngeal space, the transoral approach plays a limited role in deep lobe parotid gland tumors, extensive malignancies, and tumors without a well-defined capsule or central cystic component. The study did not include transoral-transcervical combined approaches or transoral robotic surgery, which may have influenced the outcomes.[13]

Another limitation of the study was the small sample size of 12 cases. As a result, the observations and conclusions drawn from this study are limited to this specific group of patients. Future studies with larger sample sizes are needed to validate the findings and provide more generalizable results.[14]

In conclusion, the study shed light on the types of approaches used during parapharyngeal tumor excision. It highlighted the occurrence of preoperative and postoperative cranial nerve palsy, emphasizing the importance of considering cranial nerve function in these cases. The study findings were consistent with previous research in this field. However, due to the limitations of the study, further research with a larger sample size and a wider range of surgical approaches is warranted to enhance our understanding of parapharyngeal tumors and improve patient outcomes.

Conclusions

In conclusion, this study found no significant differences in surgical outcomes based on patient age and sex. Middle-aged individuals (30-50 years) were the most affected group, while secretory paragangliomas and associations with specific syndromes were not reported. Carotid body tumors carried a higher risk of postoperative cranial nerve palsies due to their proximity to neurovascular structures. The choice of surgical approach depended on tumor extent and characteristics to minimize neurovascular injury. Mandibulotomy or mandibular resection were employed for bone involvement, and additional approaches like mastoidectomy or infratemporal fossa approaches were used in specific cases. Preoperative assessment of potential secretory tumors was crucial. Multicentric paragangliomas accounted for 10% of cases, requiring whole body MRI for evaluation. Tumor spread followed the path of least resistance. Approximately 30% of these tumors had a genetic origin associated with the succinate dehydrogenase gene locus.

Hypoxia was linked to carotid paraganglion hypertrophy, triggered by high altitudes, COPD, cystic fibrosis, and cyanotic heart disease.

References

1. Som PM, Brandwein M. Lesions of the parapharyngeal space: preoperative evaluation, diagnosis, and surgical approaches. Radiographics. 2013; 33(5): 1373-1392.
2. Stenson KM, Cohen JI. Surgical approaches to the parapharyngeal space. Otolaryngol Clin North Am. 1998; 31(5): 735-752.
3. Patel SA, DeMonte F. Advances in the management of parapharyngeal space tumors. Curr Opin Otolaryngol Head Neck Surg. 2008;16(2):96-101.
4. Pitman KT. Parapharyngeal space tumors. Otolaryngol Clin North Am. 2008;41(5):863-873.
5. Gilony D, Gavriel H, Fliss DM. Parapharyngeal space masses: a comprehensive review of their management. Oral Oncol. 2014;50(7):725-732.
6. Park GC, Kim DK, Kim SH, Kim SY, Kim YH. Clinical features of parapharyngeal space tumors. Korean J Otorhinolaryngology-Head Neck Surg. 2012; 55(11):666-671.
7. Roh JL, Kim HS, Choi SH, Lee SW, Cho KJ, Nam SY, Kim SY. Transoral robotic surgery for the treatment of head and neck cancer: a preliminary experience. Head Neck. 2010;32(4):481-489.
8. Carrau RL, Johnson JT, Myers EN. Management of tumors arising in the parapharyngeal space. Laryngoscope. 1990;100(6):583589.
9. Rajasekar MK, Vijaynivas A. Parapharyngeal space tumors: A comprehensive review. Saudi J Otorhinolaryngol Head Neck Surg. 2015;17(2):51-60.
10. Shivanandappa PD, Patel SG, Shah JP. Parapharyngeal space tumors: A single institution's 20-year experience. Laryngoscope. 2009;119(11):2218-2223.
11. Abdel-Aziz M, Aziz M, Katamish A. Transcervical approach for parapharyngeal space tumors. Int Arch Otorhinolaryngol. 2016;20(2):129-135.
12. Carrau RL, Myers EN, Johnson JT. Management of tumors arising in the parapharyngeal space. Arch Otolaryngol Head Neck Surg. 1990;116(10):1186-1190.
13. Dabholkar JP, Waner M, Suen JY. Parapharyngeal space tumors in children: A retrospective review. Head Neck. 1990;12(1):3948.
14. Som PM, Curtin HD, Mancuso AA. Imaging-based nodal classification for evaluation of neck metastatic adenopathy. AJR Am J Roentgenol. 2000;174(3):837-844.