e-ISSN: 0975-1556, p-ISSN:2820-2643

Available online on www.ijpcr.com

International Journal of Pharmaceutical and Clinical Research 2023; 15 (5); 2093-2099

Case Series

Lesion Mimicking Malignancy: A Case Series

Sourabh Sharma[1], Vikesh Kumar[2], Swati Sharma[3], Konark Thakkar[4], Kavita Gupta[5], Panth Gheewala[6]

[1]Assistant Professor, Department of General Surgery, Pacific Medical College and Hospital, Udaipur, Rajasthan, India.
[2]Assistant Professor, Department of General Surgery, Pacific Medical College, and Hospital, Udaipur, Rajasthan, India.
[3]Assistant Professor, Department of Anesthesia, Pacific Medical College, and Hospital, Udaipur, Rajasthan, India.
*[4]General Surgery Registrar, Pacific Medical College, and Hospital, Udaipur, Rajasthan, India.
[5]Associate Professor, Department of Pathology, Pacific Medical College, and Hospital, Udaipur, Rajasthan, India.
[6]General Surgery Registrar, Pacific Medical College, and Hospital, Udaipur, Rajasthan, India.

Received: 25-03-2023 / Revised: 25-04-2023 / Accepted: 30-05-2023
Corresponding author: Dr. Konark Thakkar
Conflict of interest: Nil

Abstract

Background: Treatment of malignancy requires preoperative confirmation in most of the cases, to provide a definitive treatment. However, in some cases it's not possible to positively ascertain the diagnosis preoperatively and these patients are treated as malignancy. A few of them turns out to be benign lesion on histopathological examination despite of malignancy like radiological/ intra operative finding. So, benign diseases should also be kept in the differential diagnosis for doubtful cases.

Method: In this case series we are reporting ten cases of benign etiology, those were mimicking malignancy on preoperative evaluation and during intra operatively. All these cases were treated like malignancy and on histopathological examination found to be benign.

Results: Among those ten cases, four were found to have Xanthogranulomatous disease of the Gallbladder while two cases of Actinomycosis of the ovary and of Xanthogranumatous disease and tuberculous of the ovary each. One patient had Actinomycosis of the bone while the last remaining one showed kikuchi's disease.

Conclusion: There are few rare presentations that are difficult to differentiate from the malignancy pre-operatively, so while treating patients with doubtful diagnosis benign differential diagnosis should be kept in mind.

Keywords: Xanthogranulomatous cholecystitis, Xanthogranulomatous Oophoritis, Actinomycosis of the bone, Malignancy like lesion.

Introduction

Malignancy poses a different challenge to both patients and surgeons. The burden of surgery for malignant lesions on the human body is much higher when compared to

surgery for benign lesions, along with higher morbidity and sometimes mortality. Diagnosis of malignancy also causes significant psychological challenges to patients and caregivers also. So pre-operative evaluation and confirmation of diagnosis are essential for providing the best possible medical care with lower morbidity.

In oncology practice, we encounter some lesions those mimics malignancy. And despite best efforts sometimes it's not possible to confirm the diagnosis preoperatively and the patient is subjected to radical surgical treatment in view of suspicion of a malignant lesion, later on, found to be benign.

So benign diseases should also be kept in the differential diagnosis for doubtful cases.

Methodology:

In the patients recounted here, we operated on 10, each with a unique complaint of abdominal discomfort, bloating, decreased appetite, and weight loss. In light of this, we conducted all necessary regular examinations as well as more specialised ones, including organ dependent tumor markers, after the admission of all patients. The necessary radiological tests were also done on us. Several of the patients had elevated levels of CEA, CA19-9, CA125, and ALP, and CT and MRI revealed the potential for malignancy based on the images they discovered. As a result, we planned the surgical management, taking into account the patients' potential for malignancy, and removed the specimen in accordance with protocol before sending it for histopathological analysis.

Case Presentation:

Case 1 to 4:

Four patients came to our hospital with complaints of nausea, bloating, and upper abdominal discomfort, accompanied by a decrease in appetite and weight loss. The patients underwent abdominal USG, which showed widespread wall thickening, a heterogeneous gall bladder lumen composition, and hypoechoic nodules inside the thickened gall bladder wall. Following further testing for CEA, CA19-9, and ALP on the patient, it was discovered that all of them had slightly higher levels of both CEA and ALP. After that, the patients had MR and CT scans and showed the lesion which mimicked malignancy. All these specimens were sent for histopathological examination post-surgery, which showed the Xanthogranulomatous disease of the Gall Bladder.

Case 5 to 8:

There were 4 patients who complained of sporadic lower abdominal pain that was associated with weight loss and menstrual irregularities. Initially, an ultrasound of the whole abdomen was performed, which revealed that the ovary's echotexture was altered, there was mild fluid in the Douglas pouch, and the abdominal lymph nodes were enlarged. We then performed CT scans of the whole abdomen in which the lesions are indicative of the potential for malignant lesions in the ovary thus we went for some organ-specific tests, including CEA and CA 125, which revealed a marked rise in both markers' values in a short period of time, thus after surgical excision all the specimen sent for HPE, which concluded two cases of Actinomycosis of the ovary and of Xanthogranumatous disease and tuberculous of the ovary each.

Case 9:

This patient complained of a painful oral ulcer when he came to the hospital, considering the clinical appearance and history we postulated a malignant alteration, and a biopsy was performed, and diagnosed with carcinoma of the buccal mucosa. As a result, the patient underwent a CT scan of the head, neck, and chest. The scan revealed the potential for malignant cell extension into the maxilla, so we decided to perform a partial maxillectomy. We then sent the dissected specimen for

analysis, which showed the Actinomycosis of the bone.

Case 10:

This patient was having complaint of multiple enlarged lymph nodes in the neck, which were firm in consistency, and underwent FNAC, which came out to be inconclusive, after repeated inconclusive FNAC reports, an excisional biopsy was performed which showed kikuchi's disease.

Discussion

Xanthogranulomatous disease:

The gall bladder and kidney were the most often discovered affected organs in the xanthogranulomatous disease, a unique chronic inflammatory condition. Additionally, the fallopian tube, ovaries, appendix, eyes, bones, and more can all experience it [1]. The benign gallbladder pseudotumor known as Xanthogranulomatous Cholecystitis (XGC) was initially identified by Christensen and Ishak in 1970 [1]. It can resemble cancer and is characterized by the distribution of lipid-rich histiocytes throughout the body. A healthy mucosa, calculi in the gallbladder, and widespread thickening of the gallbladder wall with "nodules" caused by the concentration of macrophages are imaging findings that have been used to differentiate XGC from cancer [2]. Due to fibrosis, fistula, and inflammation, the clinical picture of XGC can be acute or chronic cholecystitis and present with a variety of symptoms [3]. Imaging tests performed prior to surgery may reveal signs of gallbladder malignancy or cholecystitis. To differentiate XGC from malignancy following cholecystectomy, an intraoperative frozen section examination may be necessary [3]. In all these cases the standard line of treatment is Radical cholecystectomy and an open approach is preferable instead of a laparoscopic one due to suspicious cancer or anticipation of significant difficulties.

The usual biologically aggressive tendency of XGC, which spreads beyond the gallbladder wall into surrounding structures, can cause a significant degree of morbidity. As a result, XGC is either thought of as a separate clinical entity or as an invasive kind of chronic cholecystitis. One of the non-specific clinical signs and symptoms of XGC is acute or chronic cholecystitis [4]. The right upper quadrant discomfort, epigastric pain, fever, jaundice, nausea, and vomiting are the most common symptoms. These ambiguous signs are the same as those of gallbladder cancer and are typically ineffective in distinguishing between the two diseases[5]. A propensity to touch nearby organs and a thickening of the gallbladder wall are two imaging characteristics of XGC that are comparable to those of gallbladder cancer.

On ultrasonography, it is possible to notice localized or widespread thickening of the gallbladder wall together with gallbladder stones and intramural hypoechoic nodules. Likewise, CT scans have revealed the same anomalies. Additionally, it has been proposed that CT can aid in separating XGC from gallbladder cancer [4]. Particularly widespread wall thickening, continuity of the mucosal line, intramural hypo-attenuated nodules, and lack of invasion to the adjacent liver parenchyma are among the CT criteria for the diagnosis of XGC [4]. The MRI feature of intramural T2 high signal intensity, which distinguishes XGC from gallbladder cancer, is essential for diagnosis. At present, no modality can definitely distinguish between XGC and cancer [5,6].

An uncommon instance of persistent ovarian inflammation is called xanthogranulomatous oophoritis. Neutrophils, lymphocytes, plasma cells, and macrophages that are lipid-laden are present in inflammation with xanthogranulomatous alterations [7]. There have been reports of this form of inflammation in the kidney, gallbladder, and anorectal region. Less than 15 instances

of xanthogranulomatous oophoritis have been reported. The third decade is the most prevalent age range for xanthogranulomatous inflammation; reported cases ranged in age from 18 to 72 years [7]. It is unclear what causes this condition's etiopathology, but Possible causes include pelvic endometriosis, intrinsic infertility, long-term intrauterine devices, chemotherapy for breast cancer, aberrant macrophage lipid metabolism, antibiotic usage, and inflammation related to pelvic inflammatory disease. Kunakemakorn discovered the inflammatory xanthogranulomatous syndrome for the first time in 1976. [8] The female genital tract region most usually affected by xanthogranulomatous inflammation is the endometrium, which is followed by the vagina, cervix, fallopian tube, and ovary. This kind of inflammation has been linked to Salmonella typhi, Escherichia coli, Bacteroides fragilis, and Staphylococcus aureus [9]. The clinical imaging and intraoperative findings may lead to misdiagnosis as malignancy, thus staging laparotomy is required to avoid radical surgeries.

Tuberculosis of the abdomen:

Tuberculosis of the abdomen is the 2nd most common after lung tuberculosis, the ileocecal junction is the most common site. it can also occur in various sites like ovaries, omentum, peritoneum, appendiceal, fallopian tubes, kidney, spleen, etc [9]. Diagnosis must take into account abdominal TB with ascites, which can mimic disseminated ovarian cancer [10]. India has the largest TB burden, with 2.8 million cases out of 10 million cases reported globally [11]. Abdominal TB can cause significant morbidity and mortality and is typically detected only after symptoms have developed. The four most common types of abdominal TB are lymph nodal, peritoneal, gastrointestinal, and visceral [12]. Tuberculous peritonitis is the most common cause, and both ovarian cancer and peritoneal tuberculosis can cause an increase in serum CA 125 [13]. Ovarian cancer has the seventh-highest incidence and fifth-highest cancer-related mortality rate among women globally [9]. The diagnostic difficulty is caused by similar clinical and imaging findings, and it is important to rule out malignancy and calm the patient's concern. Oriel Nissim et al [14], Peritoneal tuberculosis typically presents with signs, symptoms, and imaging findings that can mimic those of ovarian cancer. A very high CA-125 can result from peritoneal TB. In women who have epidemiological risk factors for TB infection, peritoneal tuberculosis should be included in the differential diagnosis while examining ovarian cancer. Staging laparotomy is the ideal choice for the treatment.

Actinomycosis:

Because Actinomyces have a low virulence potential in comparison to fimbriae [15], actinomycoses are opportunistic chronic infections. They, therefore, require modifications to the conventional mucosal barriers as a result of an accident, surgery, or infection. They do this by breaking through the mucous or epithelial barrier [16]. An intrauterine device (IUD), which can damage or perforate the uterus mucosal barrier and allow infection, can, for example, cause a pelvic infection [16]. The most prevalent cause of actinomycosis, a suppurative, and usually chronic bacterial condition, is Actinomyces israelii. A. naeslundii, A. viscosus, A. odontolyticus, A. pyogenes, A. urogenitalis, and A. turicensis are a few more species that have been isolated from human oral cavities15. According to Cope's 1938 suggestion, the infection can be classified morphologically as cervicofacial, thoracic, or abdominal. Any age group may have pelvic actinomycosis, which develops as a result of fistula or perforation [15]. The use of IUDs, the existence of tumors, and bacterial vaginosis are further potential causes [15]. Since these bacteria are a component of the oral cavity microbiome, oral sex has been

thought of as a potential method of dissemination [17]. The perineum is a different entry point where the germs might go from the anus up via the cervicovaginal zone [15]. An invasive infection called actinomycosis imitates cancerous processes in numerous anatomical regions. When it comes to pelvic actinomycosis, Crohn's disease, pelvic and tubo-ovarian abscesses, and malignant lesions, there is frequent confusion. As a result, to avoid a diagnostic mistake that might result in needless intrusive therapy, pelvic actinomycosis should be taken into consideration in the differential diagnosis for any chronic inflammatory lesion of the viscera located in the pelvic zone, according to Kayikcioglu et al. [18] and Moniruddin et al. [19]. Over half of reported cases are cervicofacial, making it the most prevalent. Only 0.5–9% of cases of actinomycosis in the head and neck involve the maxilla [20]. Only a few number of cases of primary actinomycosis that develop in the maxilla have been documented in the literature. The aggressive and locally damaging nature of actinomycosis of the oral cavity makes it a very significant disorder even though it is rarely seen in routine dental checkups. Human actinomycosis may pose a diagnostic problem at times and is often mistaken for a neoplasm [20]. Aggressive actinomycosis is an infection that frequently mimics malignant processes in several anatomical locations. The pelvis, which is impacted by pelvic actinomycosis, is one of the locations that lead to diagnostic uncertainty the most commonly.40 Thus after HPE-proven diagnosis we kept the patient on long-term antibiotics therapy.

Kikuchi's disease:

Histiocytic necrotizing lymphadenopathy, or Kikuchi's disease, is a rare benign (noncancerous, nonmalignant) illness of the lymph nodes that affect young adults, primarily young women. Due to the striking resemblance of the symptoms, particularly cervical adenopathy, this illness is frequently misdiagnosed as malignant lymphoma [21]. The lymph nodes of this condition grow (lymphadenopathy), become inflammatory, and are unpleasant due to the lesions, or tissue anomalies, that are present. It is unknown what specifically causes Kikuchi's condition. A false-positive diagnosis of a malignant lymphoma may represent the biggest danger [22]. The treatment of choice for this disease is immunosuppression therapy and supportive management.

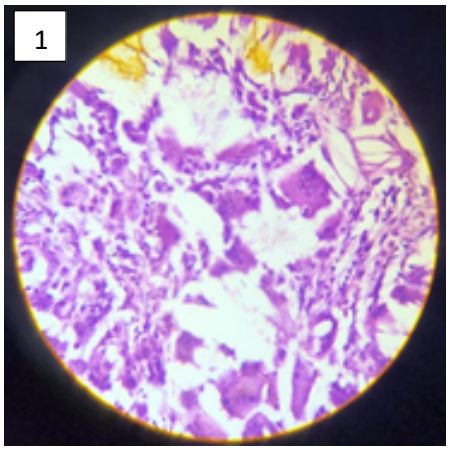

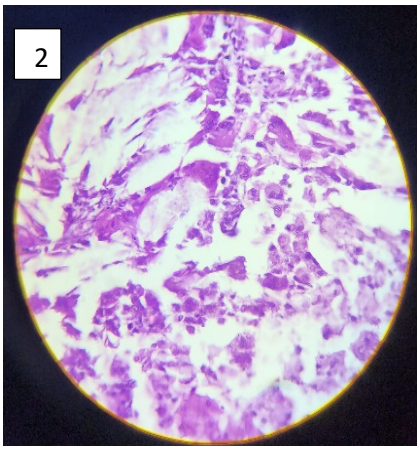

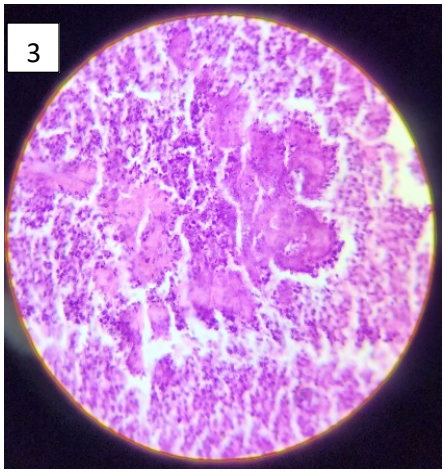

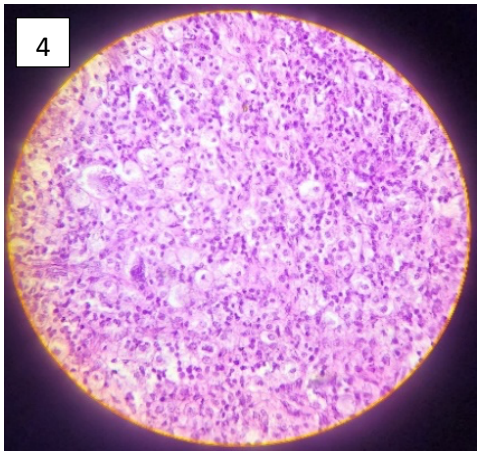

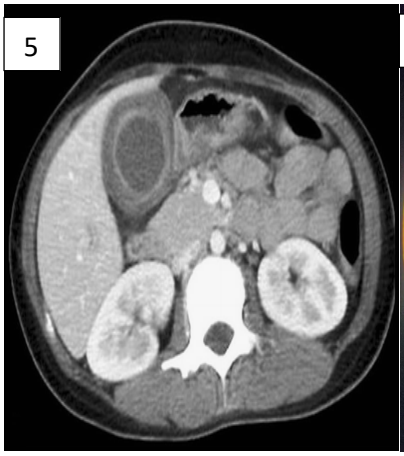

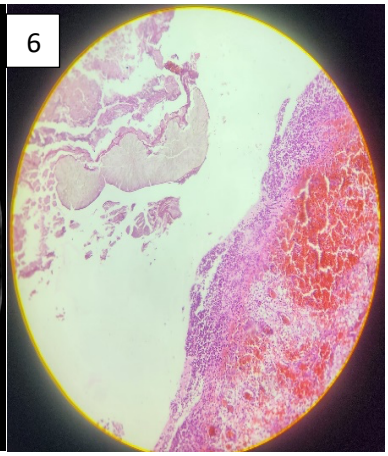

Image description:

1= XGC (400x)

2= XGC (400x)

3,4= Actinomycosis of the ovary (400x)

5= CT scan of XGC

6= Actinomycosis of

Conclusion

Few rare entities can present as a malignancy-like picture and the patient underwent radical surgery keeping malignancy in mind, which concludes that there are few rare presentations that are difficult to differentiate from the malignancy pre-operatively, so while treating patients with doubtful diagnosis benign differential diagnosis should be kept in mind.

Author's Contribution: All authors have read and approved the final manuscript for publication

Funding: No funding is required for the study.

References

1. Kansakar PB, Rodrigues G, Khan SA. Xanthogranulomatous cholecystitis:a clinicopathological study from a tertiary care health institution. Kathmandu Univ Med J (KUMJ). 2008; 6:472–5.
2. McCoy JJ, Vila R, Petrossian G, McCall RA, Reddy KS. Xanthogranulomatous cholecystitis. Report of two cases. J S C Med Assoc. 1976; 72: 78-79.
3. Amazon K, Rywlin AM. Ceroid granulomas of the gallbladder.Am J Clin Pathol. 1980; 73: 123-127.
4. Yucel O, Uzun MA, Tilki M, Alkan S, Kilicoglu ZG, Goret CC. Xanthogranulomatous Cholecystitis: analysis of 108 Patients. Indian J Surg. 2017; 79(6):510–514.
5. Deng YL, Cheng NS, Zhang SJ, Ma WJ, Shrestha A, Li FY, Xu FL, Zhao LS. Xanthogranulomatous cholecystitis mimicking gallbladder carcinoma: an analysis of 42 case. World J Gastroenterol. 2015.
6. Park JW, Kim KH, Kim SJ, Lee SK. Xanthogranulomatous cholecystitis: is

an initial laparoscopic approach feasible? Surg Endosc. 2017; 31: 5289–5294.
7. Zhang XS, Dong HY, Zhang LL, et al. Xanthogranulomatous inflammation of the female genital tract: report of three cases. J Cancer. 2012; 3:100–6.
8. Yener N, Ilter E, Midi A. Xanthogranulomatous salpingitis as a rare pathologic aspect of chronic active pelvic inflammatory disease. Indian J Pathol Microbiol. 2011; 54:141–3.
9. Bray F, Ferlay J, Soerjomataram I, et al. Global cancer statistics 2018: GLOBOCAN estimates of incidence and mortality worldwide for 36 cancers in 185 countries. CA Cancer J Clin. 2018;68(6):394–424.
10. Gosein MA, Narinesingh D, Narayansingh GV, et al. Peritoneal tuberculosis mimicking advanced ovarian carcinoma: an important differential diagnosis to consider. BMC Res Notes. 2013; 6:88.
11. Global tuberculosis report 2018 of the WHO.
12. Debi U, Ravisankar V, Prasad KK, et al. Abdominal tuberculosis of the gastrointestinal tract: revisited. World J Gastroenterol. 2014;20(40):14831–40.
13. Koc S, Beydilli G, Tulunay G, et al. Peritoneal tuberculosis mimicking advanced ovarian cancer: a retrospective review of 22 cases. Gynecol Oncol. 2006; 103:565–9.
14. Oriel Nissim et al. A Case of Peritoneal Tuberculosis Mimicking Ovarian Cancer in a Young Female, Hindawi Case Reports in Obstetrics and Gynecology. 2022; Article ID 4687139, 4.
15. J. A. S. Hern´andez, N. ´ A. M. Carrillo, F. Chilaca, and J. A. R.Tapia, Uso del DIU asociado a la infecci´on secundaria por actinomyces en tracto genital femenino, Revista Espa˜nola de Patolog´ıa, 2004; 37:383–390.
16. S. R. Paniagua and S. Victoria–Ortega, Estudio Comparativo del Aislamiento y Tipificaci´on del G´enero Actinomyces Entre Placa de Fosas y Fisuras y Placa Interproximal en Pacientes Que Concurren A la C´atedra de Pr´actica Cl´ınica PreventivaI de la F.O.U.N.N.E. - Informe de Avance, Resumen M-060, Comunicaciones Cient´ıficas y Tecnol´ogicas, Argentina, South America, 2006.
17. F. Valour, A. S´en´echal, C. Dupieux et al., Actinomycosis: etiology, clinical features, diagnosis, treatment, and management, Infection and Drug Resistance, 2014; 7:183–197.
18. L. A. Bergenhenegouwen, H. H. De Haan, E. S. Sijbrandij, andP. H. P. Groeneveld, Unavoidable surgical intervention in two women with severe actinomycosis during IUD use, Nederlands Tijdschrift voor Geneeskunde, 2003; 147(48):238 2–2385.
19. A. Moniruddin, H. Begum, and K. Nahar, Actinomycosis: an update, Medicine Today, 2010; 22(1): 43–47.
20. Bennhoff DF. Actinomycosis: Diagnostic and therapeutic considerations and a review of 32 cases. Laryngoscope. 1984; 94:1198-217.
21. Perry AM, Choi SM. Kikuchi-Fujimoto disease: a review. Archives of Pathology & Laboratory Medicine. 2018;142(11):1341-1346.
22. Susheelan V, Thambi R, Mathew S. Kikuchi′s disease: A study of 96 cases over a 12-year period. Saudi J Health Sci. 2016;5(3):134.