e-ISSN: 0975-1556, p-ISSN:2820-2643

Available online on www.ijpcr.com

International Journal of Pharmaceutical and Clinical Research 2023; 15(5); 604-613

Original Research Article

A Prospective Comparison of Fistulectomy and Ligation of Intersphincteric Fistula Tract (LIFT) in Fistula in Ano

Inuganti Gopal[1], Ambuja Satapathy[2], Nishirekha Behera[3], Sumita Tripathy[4], Soumya Ranjan Jena[5*]

[1]Associate Professor, Department of General Surgery, MKCG MCH, Berhampur, Odisha, India

[2]Associate Professor, Department of General Surgery, MKCG MCH, Berhampur, Odisha, India

[3]Post Graduate, Department of General Surgery, MKCG MCH, Berhampur, Odisha, India

[4]Associate Professor, Department of Pathology, DD Medical College, Keonjhar, Odisha, India

[5*]Assistant Professor, Department of General Surgery, MKCG MCH, Berhampur, Odisha, India

Received: 06-03-2023 / Revised: 30-03-2023 / Accepted: 30-04-2023

Corresponding author: Dr Soumya Ranjan Jena

Conflict of interest: Nil

Abstract

Background and Objectives: The most typical benign anal disease seen in routine surgical practise is fistula in Ano. The only available therapy for anal fistula is surgery. Numerous surgical procedures have been documented, such as the use of collagen plugs, seton, fibrin glue, rectal advancement flap, fistulotomy combined with sphincter reconstruction and rerouting the fistula tract. For optimal treatment and to lower the risk of relapse or incontinence, the correct method of choosing must be adjusted among the available surgical techniques. A straightforward, risk-free, and affordable therapeutic option was discovered to be ligation of the intersphincteric fistula tract. Due to the possibility of anal incontinence and the resulting morbidity, treating peri-anal fistulas is still difficult. A novel sphincter-saving treatment called LIFT has produced positive results in the therapy of anal fistulas.

Aims and Objectives: In cases of diagnosed fistula in Ano as well as admitted to our hospital for surgery in the previous two years, to compare the sphincter-saving surgery LIFT with fistulectomy with regard to of surgery time, post-operative wound healing time, post-operative wound-related infection rates, and faecal incontinence on follow-up.

Material and Methods: This prospective comparative study was carried out at the Government Medical College and Hospital of Northeastern India's General Surgery Department. After receiving approval from the institutional ethical committee and informed written consent, 80 patients who had been diagnosed with Fistula in Ano and been admitted for surgical treatment were evaluated. They were then split evenly and randomly into two groups: Group I, which consisted of 40 patients, underwent fistulectomy, and Group II, which consisted of 40 patients, underwent the LIFT procedure. Both Groups were then monitored for six months.

Results: 90% of the 40 patients in Group I who underwent a fistulectomy for a fistula in Ano were over 20 and under 50, with 57% of the patients being men and 43% being women. In Group II (LIFT), 88% of the participants were between the ages of 20 and 50, with 53% of men and 47% of women. In Group I, 77% of procedures take between 30 and 50 minutes on average, but in

Group II (LIFT), the average operation time was closer to 30 minutes. Fistulectomy recovery took an average of 7 weeks, whereas LIFT recovery took an average of 5 weeks. In the LIFT technique, the post-operative hospital stay was shorter. Wound infections affected 18 individuals in group I and 8 patients from group II. Incontinence was a complication that affected 4 individuals in Group I, while there were none in Group II.

Conclusion: In terms of maintaining sphincter function and preventing anal incontinence, LIFT is superior to fistulectomy. The likelihood of postoperative infection of the surgical site and recurrence is lower. Overall, LIFT delivers a higher quality of life and has superior post-operative results.

Keywords: Anal sphincter; Fistula in Ano; Fistulectomy; LIFT; Recurrence.

Introduction

Fistula in Ano is a persistent aberrant communication that extends from the anorectal channel (the intrinsic outlet) to an extrinsic outlet in the perianal skin. It is typically surrounded by granulation tissue. With a male to female ratio of 1.8: 1, the frequency of fistula in ano has been reported to be between 8.6 and 10/100,000. It is well known that Hippocrates employed lint-filled hair as a seton that was frequently tightened. A particular disorder, such as Crohn's disease, TB, lymphogranuloma venerum, actinomycosis, rectal duplication, foreign body, or cancer, may be associated with an anal fistula. [1]

90% of cases are due to cryptoglandular infection. An anorectal abscess is the result of an infection that originates in the anal gland and spreads to the musculature wall of the anal sphincters. In 50% of instances, a granulation tissue lined channel is left behind after operative procedure or spontaneous drainage of an abscess in the perianal skin, leading to the development of a chronic fistula. [2]

It affects the rectum & anal canal and is a benign, curable condition. Although it has been recognised as a prevalent surgical illness since Hippocrates' day, there is no systematic research on how to treat it. A combination of the recurrence of it and anal incontinence, it is a stressful illness for those suffering and can be difficult to treat surgically.

There are variable surgical procedures for the management of anal fistula with variable risk of incontinence and recurrence and success rates such as fibrin glue injection (38-41%), [3] fistula plug(54-85%),[4] LIFT (57-95%), [5] mucosal advancement flaps (59-78%), [6] video assisted anal fistula treatment (VAAFT) (66.7-87.5%), [7] laser closure of fistula tract (FiLAC) (67.3-69.7%). [8] fistulectomy / fistulotomy (93-100%) which includes fistulotomy, seton placement, endorectal advancement flap, ano-cutaneous advancement flap, excision and closure of the internal opening, insertion of fibrin or insertion of fistula plug, cyanoacrylate glue, video assisted anal fistula treatment and ligation of inter sphincteric fistula tract. [3]

The technique known as a fistulectomy involves coring out the fistula, typically using diathermy cautery; this surgery has a longer healing period and increased morbidity. According to the level of the tract, a different section of the sphincter can also sustain injury, which may or may not result in incontinence.Out of these methods; the LIFT is perhaps the most guaranteeing surgical procedure since it depends on the intersphincteric approach to remove the contaminated crypto glandular tissue while securely closing the internal aperture. The

surgery was created by Thai colorectal surgeon Arun Rojanasakul of the Chulalongkorn University Department of Surgery Colorectal Division in Bangkok, Thailand. It has a 94% success rate in treating fistula in Ano without causing any incontinence. Simple, risk-free, and minimally intrusive describe this technique. [9,10]

Aim and Objectives

The purpose of this study was to compare traditional fistulectomy with the sphincter-saving surgery LIFT (Ligation of Intersphincteric Fistulas Tract) in patients with fistula in Ano.

Given the large number of Fistula in Ano patients being diagnosed and treated in this hospital, including referrals from primary healthcare institutions, it has been regarded as beneficial considering the cost effectiveness and infrastructure currently available to us, to study & compare both these two techniques regarding: Surgery duration, post-operative wound healing time, post-operative wound infection rate, and faecal incontinence are among the factors to consider.

Material and Methods

Study population: The patients admitted in Department of General Surgery at the Government Medical College and Hospital of Northeastern India who are diagnosed with Fistula in Ano, from August 2020 to July 2022.

Inclusion criteria

1. Patients older than 18 of either gender who have given consent in writing for the surgery.
2. Patients without any co-morbid conditions.
3. Low fistula in Ano which is not linked to TB, cancer, or inflammatory bowel disease.

Exclusion criteria

1. Lack of consent
2. Patients under the age of 18.
3. Multiple, recurrent or high fistulas in Ano.
4. Patients with co-morbid illnesses, such as those with impaired immune systems, those receiving chemotherapy or immunotherapy for cancer, and those using long-term steroids.
5. Fistula in Ano linked to TB, cancer, and inflammatory bowel disease. Pre-existing incontinence.

Sample size

From August 2020 to July 2022, 80 patients were hospitalised, divided into two groups of 40 each in **Group I** (receiving Fistulectomy surgery) and **Group II** (receiving LIFT procedure).

Treatment

Before surgery, an MR fistulogram is utilised in both groups to detect the exact site of the fistula, along with other regular examinations for the illness and operational technique, including anaesthetic necessities.

In Group I

The fistulectomy was done as follows.

The procedure was performed under subarachnoid block in the lithotomy position.

In the extrinsic opening, a combination hydrogen peroxide & methylene blue was introduced.

A probe was put via the extrinsic entry of the ano fistula and exited the interior orifice.

The whole fistulous tract is removed, including all three sections of the fistula: 1. extrinsic opening, 2. intrinsic opening, and 3. the entire tract.

Figure 1: Showing fistulous tract being excised in fistulectomy

In Group II

Through the extrinsic opening, methylene blue dye was introduced.

The intersphincteric groove was incised, and dissection was performed along the intersphincteric plane until the intersphincteric tract became apparent and the fistula tract has been hooked out.

Suture ligation of both of the ends of the fistula tract is performed using absorbable suture material. The fistula tract was surgically removed.

Curette was traversed from the external orifice up to the ligature then curettage was performed.

The interspincteric wound was closed.

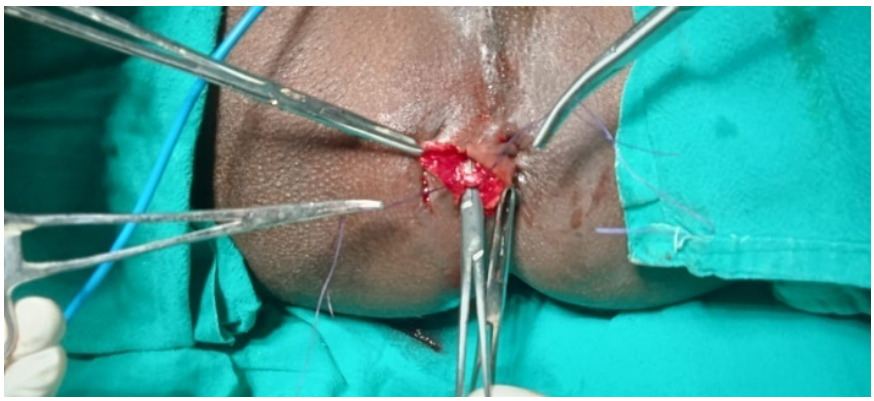

Figure 2: Fistulous tract is hooked out in LIFT

Methodology

Out of 287 patients who were diagnosed with fistula in Ano in the hospital's outpatient department, 80 patients who met the inclusion criteria were chosen for the study. The research was accepted by the Ethical Committee and complete informed written consent was acquired from the patients. Prior to surgery, all patients received intestinal pretreatment in the manner of an enema.

Group I (n=40) had Fistulectomy surgery.

Group II (n=40) were treated with the LIFT (Ligation of Intersphincteric Fistula Tract) surgery and were followed up on for 6 months. Patients who did not show up for their follow-up appointments were urged to inform about the occurrence of any wound complications through phone, mail, or Whatsapp.

All patients were given 1 gm of ceftriaxone intravenously prior to surgery. As antibiotics, all patients got Inj. Ceftriaxone 1 gm i.v bd and Inj. Metronidazole 500 mg i.v tds for 3 days. All patients were given anti-inflammatory analgesics.

All of the patients were operated on while under subarachnoid block.

A record of the time needed to perform the surgery was kept during the procedure.

Patients were asked to complete a questionnaire after surgery, and they were also evaluated for immediate post-operative problems such as post-operative infection of the wound and bleeding Per Rectum, as well as late post-operative complications such as anal incontinence or recurrence.

These patients were followed up on at 1, 3, and 6 months, and each time they were asked to complete a questionnaire form.

Each patient's data was collected in accordance with the Performa.

Based on data analysis, the advantages of Fistulectomy versus LIFT in the management of Fistula in Ano were compared.

1. Procedure duration.
2. Time required for post-operative wound healing.
3. Infection rate of post-operative wounds.
4. Urinary incontinence in the short term.
5. Prolonged incontinence and recurrence.

Result

Group I in present study consists of 40 individuals who had Fistulectomy. According to the following statistics, around 67% of the population is between the ages of 20 and 40. As seen in the table below, IN Group II, 33% of fistulas are in the 30-39 age range, while 27% are in the 20-29 age group and 30% in the 40-49 age group.

Table 1: Age distribution between groups

Age Distribution (In Years)	Group I		Group II	
	N	%	n	%
20-29	14	35	11	27
30-39	13	32	13	33
40-49	9	23	12	30
50-59	4	10	4	10
Total	40	100	40	100

Table 2: Gender distribution between groups

Gender	Group I		Group II	
	n	%	n	%
Male	23	57	21	53
Female	17	43	19	47

According to Table 3, the LIFT procedure is shorter in duration than the Fistulectomy procedure.

Table 3: Comparison of duration of procedure between groups

Duration Of Procedure (Minutes)	Group I		Group II	
	n	%	N	%
20-30	4	10%	12	30%
30-40	13	32.5%%	20	50%
40-50	18	45%	8	20%
50-60	5	12.5%	0	0%

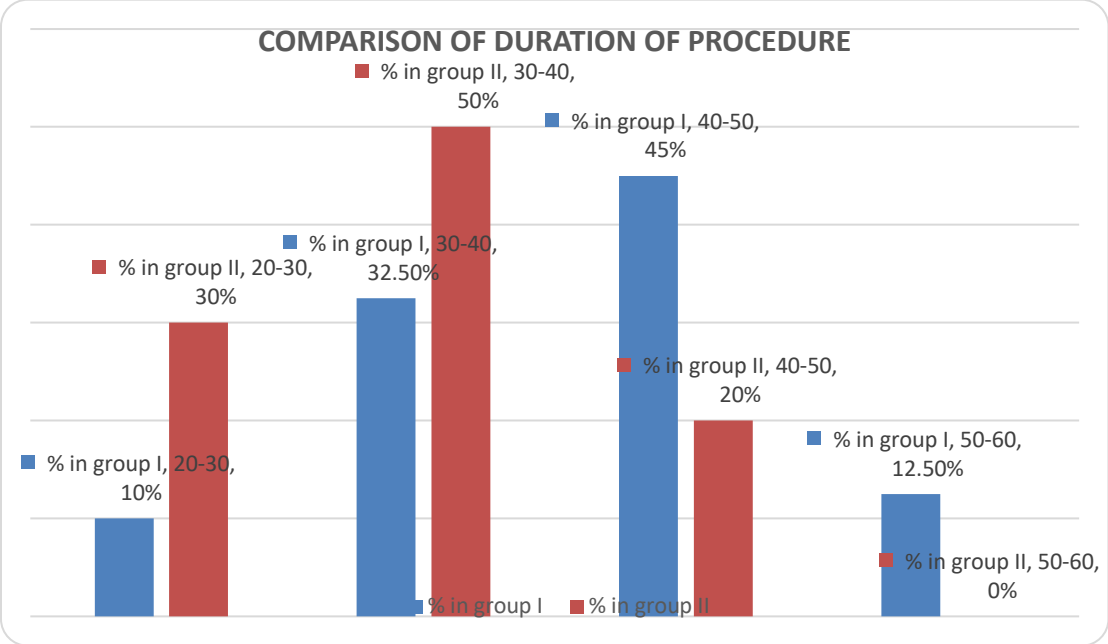

Figure 3

In our study, the mean postoperative wound healing interval for group I was approximately 7 weeks compared to 5 weeks for group II.

As a result, LIFT procedure patients had a reduced hospital stay as compared to Fistulectomy patients due to a shorter post-operative wound healing period.

Table 4: Comparison of post operative wound healing time between groups

Wound Healing Time (Weeks)	Group I		Group II	
	n	%	N	%
3-5	0	0%	21	42%
5-7	17	34%	21	42%
7-9	24	48%	8	16%
9-11	9	18%	0	0%

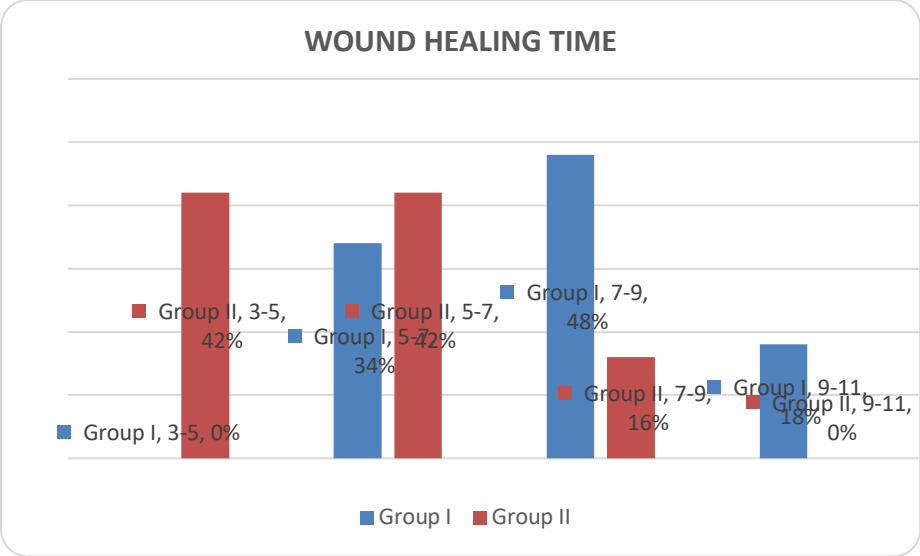

Figure 4

According to table 5, wound infection rate was found to be higher in fistulectomy group.

Table 5: Comparison of wound infection rate in both the groups

Types of Procedure	Wound Infection Rate				Chi Square Value	P Value
	Yes	%	No	%		
Fistulectomy (Group I)	18	45%	22	55%	5.698	0.0169 **(S)**
Lift (Group II)	8	20%	32	80%		

S- Significant

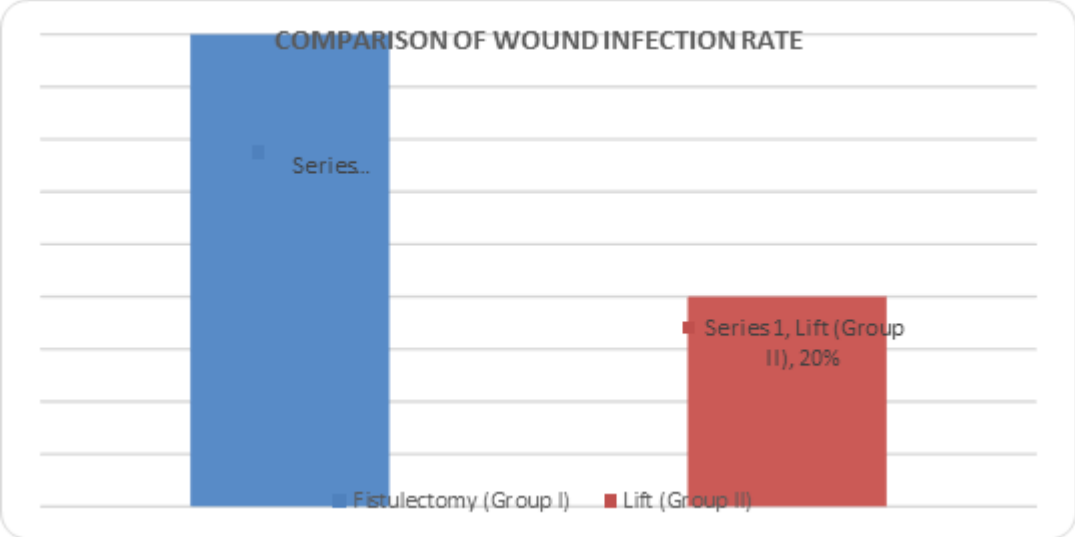

Figure 5

Discussion

Surgery is the only means for managing a fistula; [5] however; injury to the sphincter mechanism may compromise the outcomes. Numerous surgical procedures, such as the use of seton, fibrin adhesive, collagen plug, rectal advancement flap, fistulotomy along

with sphincter restoration, and rerouting the fistula tract, [10] have been described. For proper management and to minimise the probability of relapse or incontinence as well as post-operative morbidity, the right approach and selection, based on the specific pathological traits of the wound, among the available surgical procedures is of utmost importance. Rojanasakul *et al* [9,10] first described ligation of the intersphincteric fistula tract as a simple, safe, and economical treatment option, which preserves the anal sphincter, causes minimal tissue damage, and results in a reduced recovery time and a small scar.

The LIFT has the potential to transform a high fistula into an intersphincteric fistula, even in the case of failure, resulting in negligible impairment of continence (6%). [14-15,19]

Males had a greater likelihood of Perianal fistula when combining the two groups and analysing the resulting data.

In the present research, the Fistulectomy procedure lasts approximately 40 minutes, compared to 30 minutes for LIFT. When the two groups are summed together, the duration of the LIFT procedure was found to be faster than that of the Fistulectomy. Similarly, due to the LIFT procedure's minimised incision and raw region, the average post-operative recovery period is shorter than that of Fistulectomy.

Compared to Fistulectomy, patients who had the LIFT procedure have a shorter postoperative hospital stay. In accordance to the literature, the LIFT procedure possesses the benefits of preserving the anal sphincters, causing minimal tissue damage, requiring a brief recovery period, and incurring no additional costs. In the event of failure, the approach is easily repeatable. Yet there is just one prospective, randomised trial to date, and the majority of the evidence is based on small case series with varying follow-up and no standardised evaluation of incontinence.

In the present study, Fistulectomy had a statistically significant higher wound infection rate than the LIFT procedure (p=0.0169).

Comparing post-operative short-term incontinence between groups in the present study, it was determined that the LIFT procedure is superior to Fistulectomy in preventing incontinence among individuals operated for Fistula in Ano.

Shanwani *et al*., from Malaysia, studied the LIFT procedure with an 82% success rate and deemed it a safe, simple, and effective procedure.[11]

In the "Comparative Study on LIFT & Conventional Fistulotomy in the Treatment of Fistula in Ano at Hai Yai Hospital" published in the Thai Journal of Surgery, Alapach *et al*. concluded that LIFT is a successful procedure with reduced healing time and a decreased incidence of post-operative anal incontinence.[12]

The June 2015 conference paper "Comparison of LIFT and Fistulotomy in Treatment of Intersphincteric and Low Transsphincteric Anal Fistula- A Prospective Randomised Study" examined 30 patients and found that both procedures had similar success rates, but LIFT's wound healing time was quicker and Fistulotomy had an additional increase in anal incontinence incidence compared to LIFT.

A prospective observational research on "LIFT to Treat Anal Fistula- Early Results" by Sileri D, Franceschilli L, Angelucci GP *et al*., published in 2011 by Techcoloproctol, found that this innovative sphincter-saving method is efficient and secure for treating anal fistulas. [13]

A meta-analysis and systematic review of "LIFT to Treat Anal fistulas" was conducted

in 2014 by Hong K.D., Kalsarkar S., *et al*., and the results showed that LIFT appears to be an efficient and secure therapy for Transsphincteric and Complex anal fistula.[14]

None of the patients experienced post-operative incontinence, according to Nisar A. Chowdri, Salim Nazki, and colleagues; nevertheless, 6.4% of patients experienced post-operative infection, and 12.9% experienced wound dehiscence [15].

LIFT is a novel sphincter-sparing treatment for transspincteric fistula that was introduced in 2010 by Bleier JI, Moloo H, *et al*. After the operation, no patients experienced a subjective decline in continence.[16]

JiajiZhang, MM Hao, and colleagues carried out a research that will aid in the systematic evaluation of LIFT's effectiveness and safety in the management of anal fistula [17].

There were no intraoperative or postoperative complications in the research by Pasquale Cianci, Nicola Tartagila, and colleagues, and the total complete healing rate was 85.7%.[18]

Conclusion

In our study, the LIFT technique was found to be simple and straightforward to learn, making it an excellent option for treating simple as well as complex anal fistula.

This study demonstrates that the LIFT technique is superior to Fistulectomy for the management of perianal fistula. LIFT is a straightforward, easy-to-perform, and adaptable procedure that requires less time than Fistulectomy, thereby decreasing peri-operative time and reducing the risk of anaesthesia complications. The rate of post-operative infection of the surgical site is lower in LIFT than in Fistulectomy because the wound size is smaller, and the long-term probability of faecal incontinence or recurrence is much lower in LIFT patients than in fistulectomy patients. With additional research and data sharing, this can become the gold standard for this illness.

References

1. Maqbool J, Mehraj A, Shah ZA, Aziz G, Wani RA, Parray FQ, Chowdri NA. Fistulectomy and incontinence: do we really need to worry? Med Pharm Rep. 2022 Jan;95(1):59-64.
2. Jimenez M, Mandava N. Anorectal Fistula. 2022 Sep 19. In: StatPearls [Internet]. Treasure Island (FL): StatPearls Publishing; 2022 Jan.
3. .Yeung JM, Simpson JA, Tang SW, Armitage NC, Maxwell-Armstrong C. Fibrin glue for the treatment of fistulae in ano- a method worth sticking to? Colorectal Dis. 2010;12:363-366.
4. Schwandner, O., Stadler, F., Dietl, O. *et al*. Initial experience on efficacy in closure of cryptoglandular and Crohn's trans sphincteric fistulas by the use of the anal fistula plug. Int J Colorectal Dis. 2008; 23: 319–324.
5. Kontovounisios C, Tekkis P, Tan E, Rasheed S, Darzi A, Wexner SD. Adoption and success rates of perineal procedures for fistula-in-ano: a systematic review. Colorectal Dis. 2016; 18:441–458.
6. Mizrahi N, Wexner SD, Zmora O, Da Silva G, Efron J, Weiss EG, *et al*. Endorectal advancement flap: are there predictors of failure? Dis Colon Rectum. 2002;45:1616–1621.
7. Meinero P, Mori L, Gasloli G. Video-assisted anal fistula treatment: a new concept of treating anal fistulas. Dis Colon Rectum. 2014;57:354–359.
8. Elfeki H, Shalaby M, Emile SH, Sakr A, Mikael M, Lundby L. A systematic review and meta-analysis of the safety and efficacy of fistula laser closure. Tech Coloproctol. 2020;24:265–27.
9. Rojanasakul A. LIFT procedure: a simplified technique for fistula-inano.

Tech Coloproctol. 2009 Sep. 13(3):237-40.
10. Rojanasakul A, Pattanaarun J, Sahakitrungruang C, Tantiphlachiva K. Total anal sphincter saving technique for fistula-in-ano; the ligation of intersphincteric fistula tract. J Med Assoc Thai. 2007 Mar;90(3):581-6.
11. Shanwani A, Nor AM, Amri N. Ligation of the intersphincteric fistula tract (LIFT): a sphincter-saving technique for fistula-in-ano. Dis Colon Rectum. 2010 Jan; 53(1):39-42.
12. Alapach S, Khaimook A. Comparison between Ligation of Intersphincteric Fistula Tract (LIFT) Technique and Conventional Fistulotomy in the Treatment of Fistula-in-Ano at Hat Yai Regional Hospital. Thai J Surg. 2018 Mar. 31
13. Sileri P, Franceschilli L, Angelucci GP, D'Ugo S, Milito G, Cadeddu F, Selvaggio I, Lazzaro S, Gaspari AL. Ligation of the intersphincteric fistula tract (LIFT) to treat anal fistula: early results from a prospective observational study. Tech Coloproctol. 2011 Dec;15(4):413-6.
14. Hong KD, Kang S, Kalaskar S, Wexner SD. Ligation of intersphincteric fistula tract (LIFT) to treat anal fistula: systematic review and meta-analysis. Tech Coloproctol. 2014 Aug;18(8):685-91.
15. Chowdri NA, Nazki S, Shah ZA, Bhat GA. Ligation of Intersphincteric Fistula Tract (LIFT) For Fistula-in-Ano: Feasibility and Our Experience. World J Surg Surgical Res. 2020; 3: 1209.
16. Bleier JI, Moloo H, Goldberg SM. Ligation of the intersphincteric fistula tract: an effective new technique for complex fistulas. Dis Colon Rectum. 2010 Jan. 53(1):43-6.
17. Zhang J, Hao X, Zhu Y, Luan R. Efficacy and safety of ligation of intersphincteric fistula tract in the treatment of anal fistula: A protocol for systematic review and meta-analysis. Medicine (Baltimore). 2021 Jan 29; 100(4):e23700.
1. Cianci P, Tartaglia N, Fersini A, Giambavicchio LL, Neri V, Ambrosi A. The Ligation of Intersphincteric Fistula Tract Technique: A Preliminary Experience. Ann Coloproctol. 2019 Oct; 35(5):238-241.