e-ISSN: 0975-1556, p-ISSN:2820-2643

Available online on www.ijpcr.com

International Journal of Pharmaceutical and Clinical Research 2023; 15(6); 960-967

Original Research Article

Histopathological Pattern of Malignant Sinonasal Tumors

Ameet G[1], Zashank S Joshi[2], PK Rangappa[3]

[1]Assistant Professor, Department of Pathology, Belagavi Institute of Medical Sciences, Belagavi, Karnataka

[2]Senior Resident, Department of Pathology, Belagavi Institute of Medical Sciences, Belagavi, Karnataka

[3]Professor, Department of Pathology, Karnataka Institute of Medical Sciences, Hubli, Karnataka (†) Deceased on (16-04-2016)

Received: 22-04-2023 / Revised: 21-05-2023 / Accepted: 29-06-2023

Corresponding author: Dr Ameet G

Conflict of interest: Nil

Abstract:

Background: Malignant tumors of sinonasal tract constitutes less than 1% of all malignancies in the body and about 3% of all head and neck cancers. Malignant tumors of sinonasal tract are of different histological types and are usually seen between the 5th and7th decades of life. The initial symptoms of sinonasal tumors are similar hence histological examination is necessary to decide whether a particular tumor is malignant,

Objectives: Present study is undertaken to evaluate the histopathological pattern in sinonasal malignancies in a tertiary care centre.

Materials and methods: Prospective observational study was conducted for a period of 18 months and histologically proven primary sinonasal malignancies were included in the study and were classified according to the WHO classification immunohistochemistry was done whenever necessary.

Results: 28 cases of malignant tumors in nasal cavity and paranasal sinuses majority were squamous cell carcinoma accounting for 11 cases (39.28%), followed by olfactory neuroblastoma 4 cases (14.28%), and mucoepidermoid carcinoma 3 cases (10.71%) other cases observed were adenocarcinoma, adenoid cystic carcinoma, adenosquamous carcinoma malignant melanoma, plasmacytoma, lymphoma, chordoma, teratocarcinosarcoma, malignant mixed tumor and malignant ameloblastoma.

Conclusion: The time of presentation of sinonasal malignancies is very late with diverse symptoms, diverse histologies and diagnosis. A proper clinical, radiological and pathological data is needed for proper management of sinonasal malignancies.

Keywords: Sinonasal malignancies, histopathology, WHO.

Introduction

Malignant tumors of sinonasal tract constitutes less than 1% of all malignancies in the body and about 3% of all head and neck cancers.[1,2]

A wide variety of malignant tumors of different histological types are found in the nasal cavity and paranasal sinuses usually seen between the 5th and7th decades of life. [3,4]

Sinonasal malignancy is usually diagnosed late; therefore it is important to determine the most common signs and symptoms that

alert the clinician to suspect the possibility of this disease. [1,5]

The initial symptoms of sinonasal tumors are similar hence histological examination is necessary to decide whether a particular tumor is malignant. [2,6,7,8]As there is scarcity on sinonasal malignancy in literature, present study is undertaken to evaluate the histopathological pattern in sinonasal malignancy.

Materials and Methods

This prospective observational study was conducted at Karnataka Institute of Medical Sciences, Hubli in the department of Pathology for a period of 18 months. The study was approved by the institutional ethics committee.

All the cases with histologically proven primary sinonasal malignancy were included for the study.Metastatic lesions of nasal cavity and paranasal sinuses and previous definitive treatment for the lesions were excluded from the study.

Detailed clinical data, occupational and personal habits of all cases were compiled.Thorough gross examination of each specimen was carried out and several representative areas of tissue were processed and stained routinely by hematoxylin and eosin. Special ancillary techniques such as immunohistochemistry were used whenever required. The tumors were classified according to WHO and observations were compared with other studies.

Results: Out of 28 cases of malignant tumors in nasal cavity and paranasal sinuses majority were Squamous cell carcinoma accounting for 11 cases (39.28%), followed by Olfactory neuroblastoma 4 cases (14.28%), and Mucoepidermoid carcinoma 3 cases (10.71%) as shown in the table-1.

Table 1: Histological distribution of malignant tumors of the nasal cavity and paranasal sinuses

Histology	Nasal	%	Paranasal	%	Total	%
Squamous cell carcinoma	2	7.143	9	32.143	11	39.286
Olfactory neuroblastoma	4	14.286	-	-	4	14.286
Mucoepidermoid carcinoma	1	3.571	2	7.143	3	10.714
Adenocarcinoma	-	-	1	3.571	1	3.571
Adenoid cystic carcinoma	-	-	1	3.571	1	3.571
Adenosquamous carcinoma	-	-	1	3.571	1	3.571
Malignant melanoma	1	3.571	-	-	1	3.571
Plasmacytoma	1	3.571	-	-	1	3.571
Lymphoma	1	3.571	-	-	1	3.571
Chordoma	1	3.571	-	-	1	3.571
Teratocarcinosarcoma	1	3.571	-	-	1	3.571
Malignant mixed tumor	-	-	1	3.571	1	3.571
Malignant Ameloblastoma	-	-	1	3.571	1	3.571
TOTAL	12	42.857	16	57.143	28	100

Among 28 cases of malignant tumors, squamous cell carcinoma accounted for 11 cases (39.28%). 7 patients were male, and 4 patients were females. Ages ranged from 30 to 75 years, with maximum incidence in 51-60 years of age group. The mean age of presentation is 53.27 years shown in Table 2.

Out of 11 cases, 8 were well differentiated squamous cell carcinoma, 3 were moderately differentiated. (Table-2) (Figures 1, 2 and 3)

Table-2 Age and sex distribution of squamous cell carcinoma

Age in years	Male	Female	Total
0-10	-	-	-
11-20	-	-	-
21-30	1	-	1
31-40	-	1	1
41-50	1	1	2
51-60	3	1	4
61-70	2	1	3
Total	7	4	11

4 cases of olfactory neuroblastomas were diagnosed among 28 cases of malignant tumors, which accounted for 14.28%. 3 patients were males (75%) and one patient was female (25%). The age ranged from 18 to 60 years with a mean age of 40.75 yrs. All the patients were presented with the lesion arising from the nasal cavity. Two lesions arose from the left and two were from the right side of the nasal cavity. The patients presented with nasal obstruction, discharge and epistaxis. (Figures 4, 5 and 6) In the present study 3 cases of mucoepidermoid carcinoma were reported. Two patients were males and one patient was female, the age range is from 38 to 45 years, with the mean age being 41 years. All the patients presented with the right sided nasal obstruction, headache, mass in the nose and nasal discharge. One case of enteric type adenocarcinoma was diagnosed in a 35 year female patient, which was seen in the left maxilla with symptoms of epistaxis. One case of adenosquamous carcinoma was seen in a 40 years old male with right sided nasal obstruction, discharge & headache. One case of adenoid cystic carcinoma was diagnosed in a 28 year female patient, who presented with right sided nasal obstruction, headache and watering of the eyes. One case of plasmacytoma was diagnosed in a 22 year male patient, who presented with the left sided nasal obstruction. One case of malignant melanoma of the nasal cavity was diagnosed in a 48 year male patient, who presented with nasal obstruction, nasal discharge and mass in the nose, CT findings gross & microscopy as shown in Figures. One case of teratocarcinosarcoma was diagnosed in a 65 years male patient, who presented with left nasal obstruction, bleeding from nose. One case of high grade maxillary Non Hodgkins Lymphoma in a 40 year female patient was diagnosed, who came with complaints of cheek swelling and headache. Immunohistochemistry study was done which showed tumor cells being immunopositive for LCA and focally immunopositive for EMA while negative for CK, CD20, CD30 and ALK. One case of maxillary malignant ameloblastoma was diagnosed in a 55 year old female who presented with headache and tooth pain since 6 months.

Figures

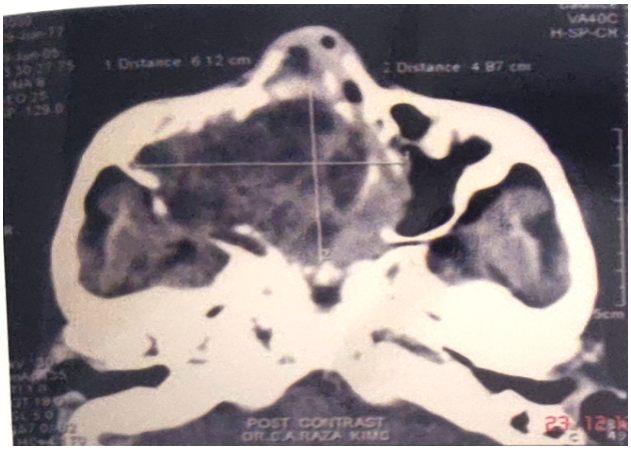

Figure1: CT scan showing mass in the right maxillary sinus extending into the nasal cavity.

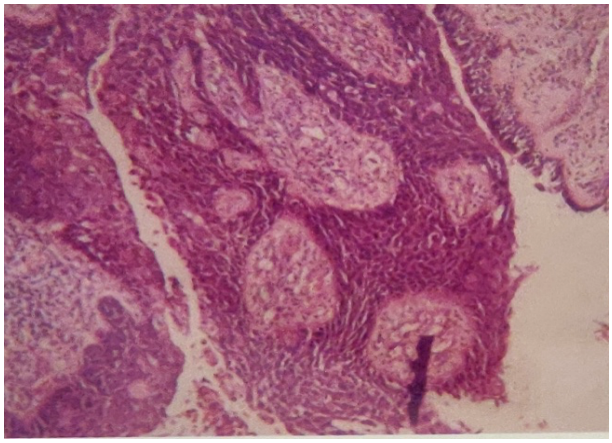

Figure 2: Microphotograph showing respiratory epithelium with subepithelium showing invasive squamous cell carcinoma (H&E 4x)

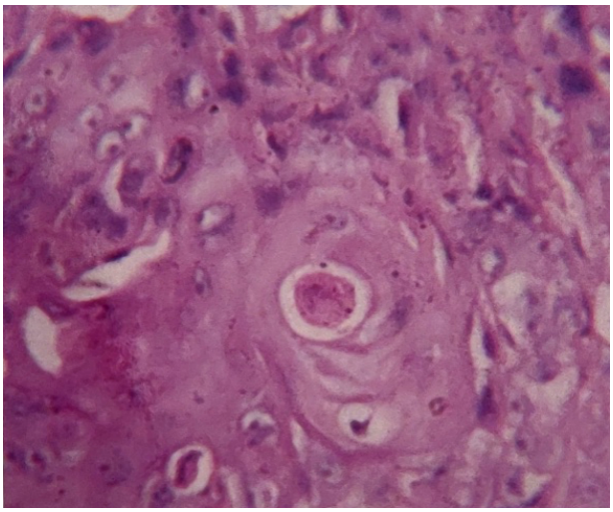

Figure 3: Microphotograph showing keratin pearl (H&E, 40x)

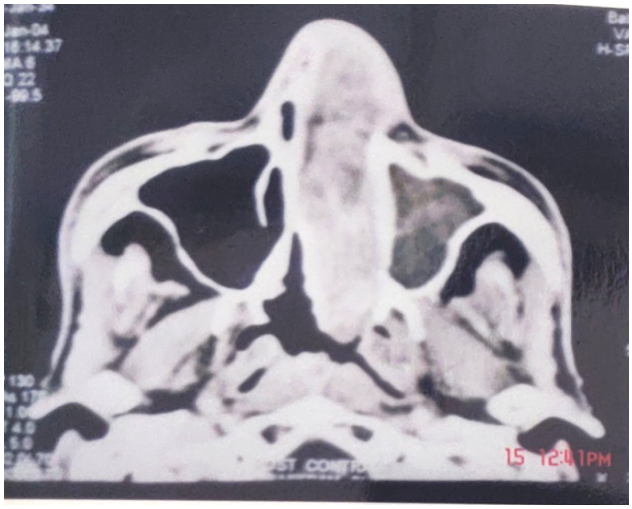

Figure 4: CT scan showing mass in the right nasal cavity.

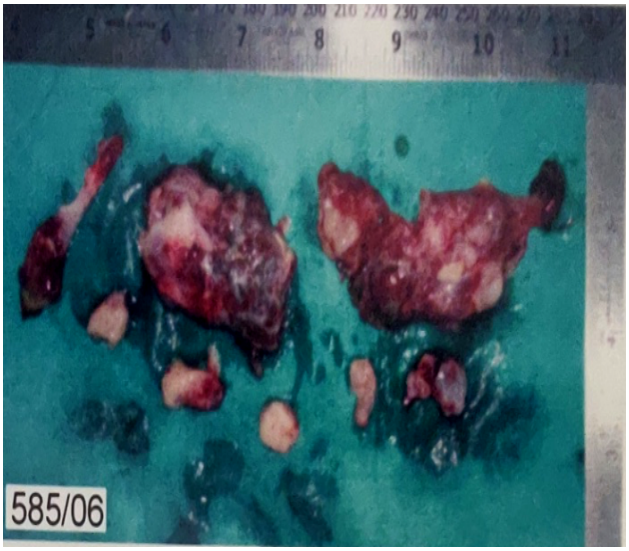

Figure 5: Gross: Glistening, soft, polypoidal mass with areas of hemorrhage.

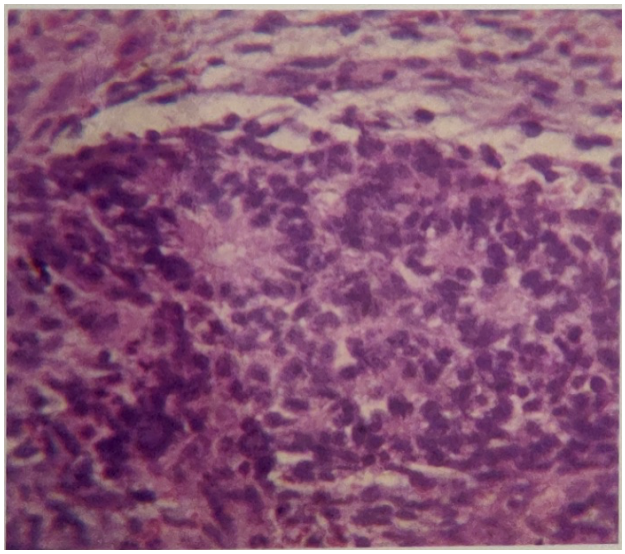

Figure 6: Microphotograph showing small round tumor cells with Homer Wright rosettes. (H&E 40x)

Discussion

In the present study out if 28 cases of malignant tumors most common was squamous cell carcinoma accounting for 11 cases (39.28%), followed by 4 cases (14.28%) of olfactory neuroblastoma, 3 cases (10.71%) of anaplastic carcinoma, one case (3.57%) of adenocarcinoma, one case (3.57%) of adenosquamous carcinoma, one case (3.57%) of adenoid cystic carcinoma, one case (3.57%) of malignant melanoma, one case (3.57%) of plasmacytoma, one case (3.57%) of lymphoma, one case (3.57%) chordoma, one case (3.57%) of teratocarcinosarcoma, one case (3.57%) of malignant ameloblastoma and one case (3.57%) of malignant mixed tumour.

Distribution of malignant tumors of the nose and paranasal sinuses were comparable to the studies by Dulguerov P et al[9], Grau C et al[10], Hopkin N et al[11], Katz TS et al[12], and Ironside P et al[13]. All the above studies including the present study showed that the most common malignant tumor observed in the nasal and paranasal sinuses was squamous cell carcinoma. In the present study squamous cell carcinoma accounted for 39.28% among malignant neoplasms of the nasal cavity and paranasal sinuses. In comparison with the study by Dulguerov P et al[9], Grau C et al[10], Hopkin N et al[11], Katz TS et al[12], and Ironside P et al[13], squamous cell carcinoma was the malignant tumour of the nasal cavity and paranasal sinuses in 57.27%, 40%, 35.29%, 32.05% and 32.32% respectively.

In the present study the age group of the patients ranged from 30 to 70 years, occurring most commonly in the 6th decade, whereas in study by Buchanan G et al[14], the age range was 42 to 76 years, occurring most commonly in the 7th decade. In comparison with a study conducted by Panchal et al[15] which reported 24 cases of squamous cell carcinoma, the age group ranged from 35 to 72 years, of which 20 patients were males and 4 patients were females.

In the present study, histologically 8 cases were well differentiated squamous cell carcinomas and 3 cases were moderately differentiated squamous cell carcinomas, whereas in study by Buchanan G et al[14] all cases were well differentiated squamous cell carcinomas with keratinization. In the present study olfactory neuroblastoma accounted for 14.28% among malignant neoplasms of the nasal cavity and paranasal

sinuses. Whereas the study by Grau C et al[10], Hopkin N et al[11], Katz TS et al[12], and Iron side P et al[13] olfactory neuroblastoma of the nasal cavity and paranasal sinuses accounted for 4%, 0.534%, 10.25%, and 1.01% respectively. The incidence of olfactory neuroblastoma in the studies by Grau C et al[10], Hopkin N et al[11], Katz TS et al[12], and Iron side P et al[13] is low compared to the present study.

In the present study, 4 cases of olfactory neuroblastoma were noticed of which three patients were males (75%) and I was female (25%). Age of patients ranged from 25 years to 60 years, with a mean age of 40.75 years, whereas in the study conducted by Kadish S et al[16], who reported 17 cases of olfactory neuroblastoma seven patients were males (41%) and 10 were females (59%). Ages ranged from 3 years to 77 years, with a mean age of 41.4 years. In the present study mucoepidermoid carcinoma accounted for 10.71 % among malignant neoplasms of the nasal cavity and paranasal sinuses. In comparison to study by Hopkin N et al[11], Katz TS et al[12], and Ironside P et al[13] mucoepidermoid carcinoma of the nasal cavity and paranasal sinuses were 0.71%, 2.5%, and 1.01% respectively. The incidence of mucoepidermoid carcinoma is more in the present study when compared to the other studies. In the present study adenocarcinoma accounted for 1.85% among the neoplasms of the nasal cavity and paranasal sinuses and 3.57% among malignant neoplasms of the nasal cavity and paranasal sinuses.

The study by Buchanan G et al[14] shows adenocarcinoma which accounted for 3.63% of all the tumors of the nasal cavity and paranasal sinuses. In comparison with the study by Dulguerov P et al[9], Grau C et al[10], Hopkin N et al[11], Katz TS et al[12], and Ironside P et al[13] which showed adenocarcinoma of the nose and paranasal sinuses in 11.36%, 13%, 7.1%, 17.94% and 19.19% cases respectively.

In present study, adenoid cystic carcinoma accounted for 1.85% among the neoplasms of the nasal cavity and paranasal sinuses and 3.57% among malignant neoplasms of the nasal cavity and paranasal sinuses. The study by Dulguerov P et al[9], Grau C et al[10], Hopkin N et al[11], Katz TS et al[12], and Ironside P et al[13] on adenoid cystic carcinoma of the nasal cavity and paranasal sinuses were 17.72% 7% 5.34% 17.94% and 5.08% respectively. In present study, malignant melanoma accounted for 1.85% among the neoplasms of the nasal cavity and paranasal sinuses and 3.57% among malignant neoplasms of the nasal cavity and paranasal sinuses. The study by Grau C et al[10], Hopkin N et al[11], and Ironside P et al[13] malignant melanoma of the nasal cavity and paranasal sinuses accounted for 12% 6.9% and 1.01% respectively.

In the present study plasmacytoma accounted for 1.85% among the neoplasms of the nasal cavity and paranasal sinuses and 3.57% among malignant neoplasms of the nasal cavity and paranasal sinuses whereas in the studies conducted by Hopkin N et al[11], and Ironside P et al[13] on plasmacytoma of the nasal cavity and paranasal sinuses were 1.4% and 1.01% respectively. In present study chordoma accounted for 1.85% among the neoplasms of the nasal cavity and paranasal sinuses.

The patient was a 55 year male patient who complained of left sided nasal obstruction and watering of the eyes since 10 months. The study by Perzin HK et al[17], reported twenty cases of chordoma involving the nasal cavity, paranasal sinuses, and nasopharynx. The principle patient complaints were diplopia, localized headache and nasal obstruction.

In the present study, 65 years male patient presented with left nasal obstruction, bleeding from nose since 4 months and watering of left eye since 2 months CT scan revealed large left nasal mass extending into left ethmoid and sphenoid sinuses,

right anterior ethmoid sinus and bilateral frontal sinuses.

The study by Heffner DK et al[18] reported 20 cases of teratocarcinosarcoma of the nasal cavity and paranasal sinuses. 16 patients were males (80%), and 4 patients are females (20%).

Conclusion: Most of the patients of sinonasal malignancy presented late with multiple symptoms. The initial symptoms presented by the patients were diverse. The rarity of these lesions in combination with the multiple histologies that are encountered have limited large scale studies. The study also highlights the need to integrate clinical, radiological and pathological data for proper evaluation of sinonasal malignancy. But, histopathology is still the cornerstone. This will optimize treatment planning and thus, favorably influence the final outcome.

References

1. Lewis JS, Castro EB. Cancer of the nasal cavity and paranasal sinuses. J Laryngol Otol. 1972 Mar;86(3):255-62.
2. McMonagle B. Nasal cavity and paranasal sinus malignancy. In Scott-Browns otolaryngology head and neck surgery, (7th edi), Gleeson. M., et al (eds), Hodder Arnold London 2008, p2417-36.
3. Salam, K. S., Choudhury, A. A., Hossain, M. D., Azim, M. A., Islam, M. S., Datta, P. G., & Alauddin, M. (2010). Clinicopathological study of sinonasal malignancy. Bangladesh Journal of Otorhinolaryngology, 15(2), 55–9.
4. Shidnia H, Hartsough AB, Weisberger E, Hornback NB. Epithelial carcinoma of the nasal fossa. Laryngoscope. 1987 Jun;97(6):717-23.
5. Majumder A, Paul D, Mondal T, Maity AK. Clinico-pathological spectrum of sino-nasal malignancy: our experience. J West Bengal Univ Health Sci. 2020; 1(1):24-30.
6. Haerle SK, Gullane PJ, Witterick IJ, Zweifel C, Gentili F. Sinonasal carcinomas: epidemiology, pathology, and management. Neurosurg Clin N Am. 2013 Jan;24(1):39-49.
7. Hafiz, M. A., Rahman, M. M., Huda, A. N., Manik, M. A. H., Islam, M. Z., & Hossen, M. I. (2022). Clinicopathological Study of Sinonasal Malignancy-Experience in a Tertiary Level Hospital in Bangladesh. Bangladesh Journal of Otorhinolaryngology, 28(1), 37–42.
8. Agarwal P, Panigrahi R. Sinonasal Mass-a Recent Study of Its Clinicopathological Profile. Indian J Surg Oncol. 2017 Jun;8(2):123-7.
9. Dulguerov P, Jacobsen MS, Allal ES, Lehmann W, Calcaterra T. nasal and paranasal sinus carcinoma: are we making progress? A series of 220 patients and a systematic review. Cancer 2001; 92:3012-29.
10. Grau C, Jakobsen MH, Harbo G, Svane-Knudsen V, Wedervang K, Larsen SK, Rytter C. Sino-nasal cancer in Denmark 1982-1991--a nationwide survey. Acta Oncol. 2001;40(1):19-23.
11. Hopkin N, McNicoll W, Dalley VM, Shaw HJ. Cancer of the paranasal sinuses and nasal cavities. Part I. Clinical features. J Laryngol Otol. 1984 Jun;98(6):585-95.
12. Katz TS, Mendenhall WM, Morris CG, Amdur RJ, Hinerman RW, Villaret DB. Malignant tumors of the nasal cavity and paranasal sinuses. Head Neck. 2002 Sep;24(9):821-9.
13. Ironside, P.; Matthews, J. Adenocarcinoma of the nose and paranasal sinuses in woodworkers in the state of Victoria, Australia. Cancer 1975, 36, 1115–24.
14. Buchanan G, Slavin G. Tumours of the nose and sinuses A clinico-pathological study. The J of Laryngol and Otol 1972:86(7), 685-96.
15. Panchal L, Vaideeswar P, Kathpal D, Madiwale CV, Prabhat DP. Sino-nasal epithelial tumours: a pathological study of 69 cases. J Postgrad Med. 2005 Jan-Mar;51(1):30-4.

16. Kadish S, Goodman M, Wang CC. Olfactory neuroblastoma. A clinical analysis of 17 cases. Cancer 1976;37:1571-6.
17. Perzin KH, Pushparaj N. Nonepithelial tumors of the nasal cavity, paranasal sinuses, and nasopharynx. A clinicopathologic study. XIV: Chordomas. Cancer. 1986 Feb 15;57(4):784-96.
18. Heffner DK, Hyams VJ. Teratocarcinosarcoma (malignant teratoma?) of the nasal cavity and paranasal sinuses A clinicopathologic study of 20 cases. Cancer. 1984 May 15;53(10):2140-54.