e-ISSN: 0975-1556, p-ISSN:2820-2643

Available online on www.ijpcr.com

International Journal of Pharmaceutical and Clinical Research 2023; 15 (6); 1034-1040

Original Research Article

The Diagnostic Utility of Myelofibrosis in Bone Marrow by Trephine Biopsy in Chronic Myeloid Leukemia

Meghavi Joshi[1], Kosha Panchal[2], Silky Patel[3]

[1]Assistant Professor, Department of Pathology, Nootan Medical College And Research Institute, Visnagar, Mehsana

[2]Consultant pathologist at Ahmedabad, Ex resident gujarat cancer research institute, Ahmedabad

[3]Assistant Professor Department of Pathology, Nootan Medical College and Research Institute, Visnagar, Mehsana

Received: 20-03-2023 / Revised: 11-04-2023 / Accepted: 05-05-2023

Corresponding author: Dr. Meghavi Joshi

Conflict of interest: Nil

Abstract

Introduction: The presence of myelofibrosis in bone marrow in CML is the important feature to be assessed. Trephine biopsy is done in CML to support the diagnosis when marrow cannot be aspirated in follow-up cases and primarily when marrow is dry.

Aim: This study aimed to document bone marrow findings with further evaluation by reticulin stain for grading of myelofibrosis in chronic myeloid leukemia.

Methods: Patients were diagnosed as CML over the period of 3 years at tertiary referral cancer center of Gujarat. All clinical and Hematological findings and bone marrow findings were correlated and reticulin stain applied on bone biopsy for evolution of grading of fibrosis.

Results: Among 100 CML patients, the mean age range of presentation was 40-50 years with Male predominance. CML chronic phase most commonly encounter 62%. The fibrosis was found highest in the chronic phase constituting 64%. The total number of cases which showed presence of fibrosis were 44 out of 100 on H&E section and reticulin stain was performed. Out of 44 cases showing fibrosis, 19 cases showed Grade-I fibrosis,16 cases showed Grade-II fibrosis, 8 cases showed Grade-III fibrosis,1case showed focal fibrosis.

Conclusions: Chronic myeloid leukemia - chronic phase is the most common presenting phase and variable grades of fibrosis was present in most of cases. Molecular evidence of the BCR-ABL fusion gene for confirmation of CML by FISH technique. The need for trephine biopsy is also important to recognize fibrosis at an early stage as extensive fibrosis may indicate therapy failure and worse prognosis.

Keywords: Myelofibrosis, Reticulin stain, BCR-ABL fusion gene.

Introduction

Myeloproliferative neoplasms are the clonal hematopoietic stem cells disorders characterized by proliferation of one or more of the myeloid lineage cells either the granulocytic, erythroid or the megakaryocytic and mast cells characterized by proliferation of white blood cells mainly of granulocytic cell lineages. The presence of myelofibrosis in bone marrow of CML is the important feature to be assessed. Trephine biopsy is done in CML to support the diagnosis when marrow cannot be aspirated in

follow-up cases and primarily when marrow is dry.[1,2,3]

Aim and Objectives

• To evaluate Trephine Biopsy findings and compare diagnostic utility of BMA and BMB.

• Evaluate Reticulin stain findings on bone biopsy and grade the fibrosis in CML

Materials and Method:

The study included the 100 cases diagnosed as chronic myeloid leukemia (CML) over the period of 3 years at tertiary referral cancer center of Gujarat. All cases of CML diagnosed clinically, morphologically on bone marrow aspirate findings and in correlation with the peripheral blood findings. Those cases were primarily included in which trephine biopsy was also performed either primarily or during the follow up. The treatment receiving cases who presented during this period were also included.

Complete blood counts, Peripheral smear examination, Bone marrow aspiration and biopsy, Cytogenetic analysis performed and Radiological investigation and the clinical details were retrieved from the case papers. Peripheral smear and Bone marrow aspiration is prepared and stained by Wright's stain. Bone biopsy kept in formalin has to be processed further in the form of decalcifying the tissue and further process and is stained with haematoxylin and Eosin stain and Reticulin stain. reticulin stain are further graded the degree of fibrosis.

Observations and Results

The age range of presentation was 41-50 years with the mean age of Presentation being 38 years. Only 2% of the cases were present below the age of 10 years that is in pediatric population with 7% cases in the age of 11-20 years. It was found majority of the affected patients were males constituting 64% whereas as females were affected relatively less constituting 36%.The Male to Female ratio was 1.7:1.

The mean Hb was 8.5 gm/dl with the range being 5.0 -12.5 gm/ dl. The mean total leukocyte count was 152x103 /cumm with the mean range being 4x103-700x103/cumm. The mean platelet count was 310x103/cumm with the, mean range being 10x103-1487x103/cumm.

The morphological presentation of the CML was in three forms: The CML presented in three phases the chronic, accelerated and the blast crisis phase.[table-1]

Table: 1 Morphological presentation of the CML

Phase of CML	Number of cases
CML-Chronic phase[CP]	62
CML-Accelarated phase[AP]	12
CML-Blast crisis[BC]	26
Total	100

The peripheral smear findings showed increased total leukocyte count with predominantly myeloid series hyperplasia of all ranges of maturation along with basophils, eosinophils and blast population. The Bone marrow aspirate along with bone biopsy was performed in 79% of the cases primarily whereas in remaining cases 21 % the biopsy was performed during the follow-up. The Bone marrow aspirate findings revealed: Hypercellular marrow with 90-95%cellularity**.** **[**Normocellular to hypocellular marrow in follow up cases]. Granulocytic series was significantly increased with all forms of maturation seen ranging from myelocytes, metamyelocytes ,band cells, polymorphs, eosinophils and basophils. Blast % varied according to the

phase of CML ranging from 2% to as high as 90% in case of blast crisis. Normal to increased megakaryocytes with presence of small, hypolobated forms occasionally reffered to as the micro megakaryocytes or Dwarf forms. The erythroid lineage was markedly suppressed in majority of the cases.

The bone biopsy findings were correlated with the aspiration findings as above in terms of cellularity, proliferation of the granulocytic series, megakaryocytic lineage.(Fig 1)The additional findings evaluated on the bone biopsy were above findings in case of dry aspirate, assess cellularity in cases of diluted marrow or unexplained peripheral cytopenias, and presence of fibrosis.(Fig.2,3) The presence of fibrosis in the Biopsy was further graded by Reticulin stain. The reticulin stain was done to demonstrate the extent of fibrosis and was graded from Grade-0 to Grade-III based on the WHO classification of Myelofibrosis grading. The total number of cases which showed presence of fibrosis were 44 out of 100 on H&E section on which further reticulin stain was performed. Out of 44 cases showing fibrosis, 19 cases showed Grade-I fibrosis(Fig.4), 16 cases showed Grade-II fibrosis(Fig.5), 8cases showed Grade-III fibrosis(Fig.6), 1 case showed focal fibrosis.[table 2]

Table 2: Grades of fibrosis

Grade of fibrosis	No. of cases	%
Grade-I	19	43
Grade-II	16	36
Grade-III	8	19
Focal	1	2
Total	44 cases	100%

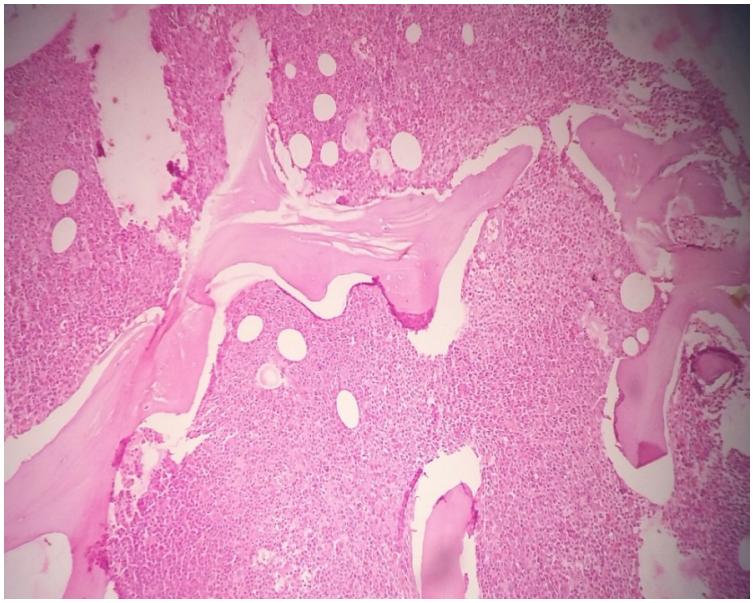

Figure 1: 10x Objective lens: CML-CP, Bone Biopsy

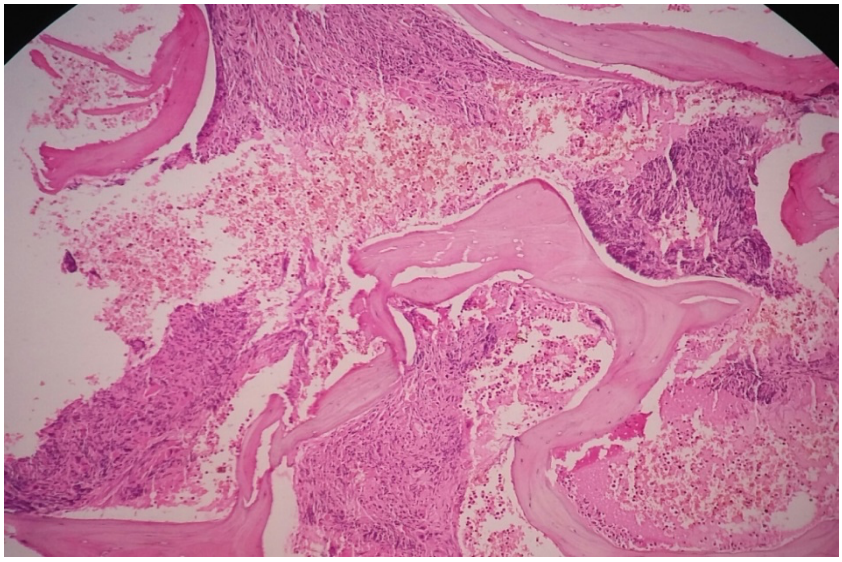

Figure 2: 20x Objective lens: Marrow fibrosis in Bone Biopsy

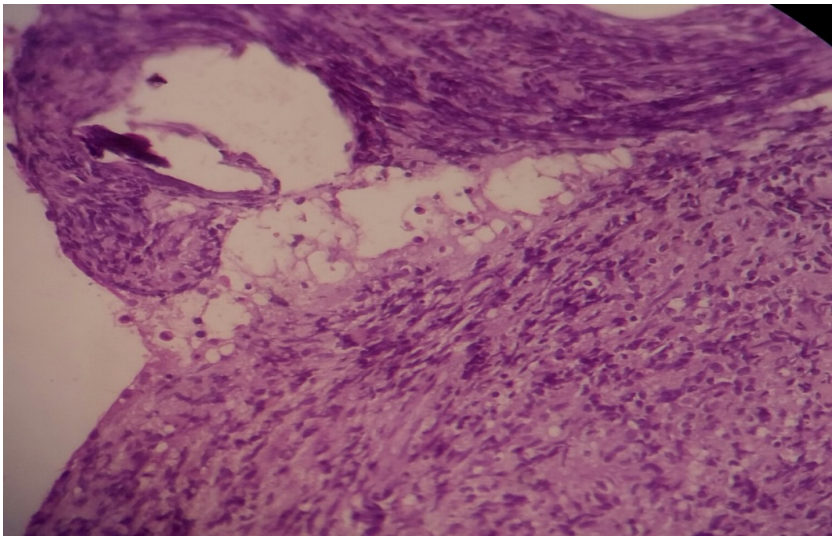

Figure 3: 40x Objective lens :Marrow fibrosis in BmBx

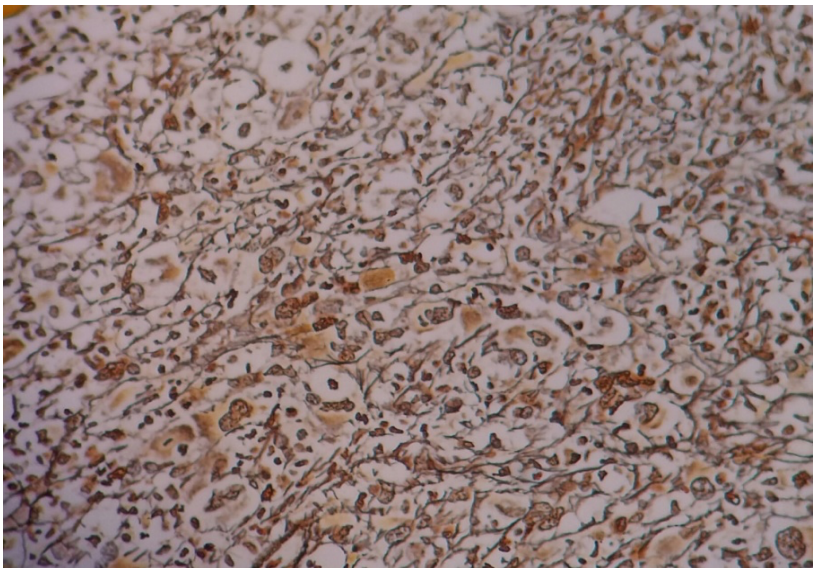

Figure 4: 40x Objective lens: Reticulin Grade-I fibrosis.

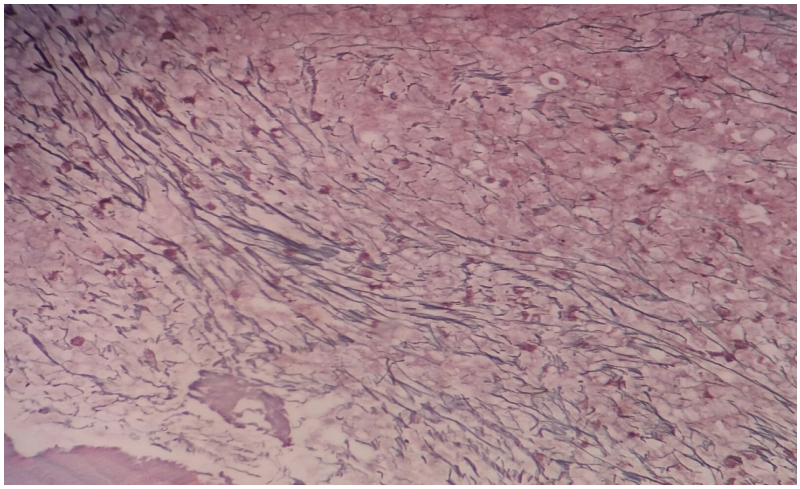

Figure 5: 40x Objective lens, Reticulin stain Grade-II fibrosis.

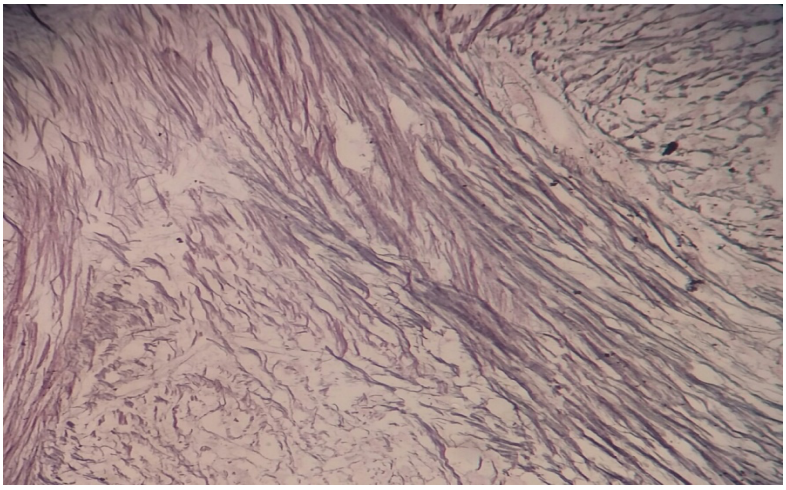

Figure 6: 40x Objective lens, Reticulin stain Grade-III fibrosis

The fibrosis was found highest in the chronic phase constituting 64%, 14% in accelerated phase and 22% in the blast crisis phase. About 8 cases out of 44 cases showing fibrosis were detected during the follow up and others had varying degree of fibrosis during presentation primarily. [Table-3]

Table 3: degrees of fibrosis (Grades I to III) were present in different phases of CML

Phase	Grades of fibrosis(No of cases)				
	Grade-I	Grade-II	Grade-III	Focal	Total
CML-CP	15	10	3		28
CML-AP	1	1	3	1	6
CML-BC	3	5	2		10
Total	19	16	8	1	44

The molecular findings in CML revealed the presence of the Ph chromosome which is classically found in CML. The findings showed the Ph chromosome in 88% of the total cases, while morphological diagnosis of CML wherein Ph was found to be negative was in 6% of cases. In 3% of the cases Ph was not done while the morphological diagnosis was CML. Other 3% cases showed Non-Informative karyotype on analysis. The FISH analysis was performed for the detection of the

BCR-ABL fusion genes demonstration which showed positivity for fusion in 98% of the cases. Only 2% of cases were negative. The cases which did not show Philadephia showed the presence of BCR-ABL fusion which is the basic molecular abnormality in CML. Thus, the FISH technique is more sensitive than the conventional karyotyping. The reporting of the BCR-ABL fusion gene was done in the forms of various signals that were recorded via dual colour fusion probes.

Discussion

On the basis of the above results and observations In this study ,The Mean age of presentation of CML in our study 38 years slight male predominance with 64% .The occurrence of CML is relatively less common in pediatric population and very elderly individuals beyond 70 years[4]

The mean number of blasts in our study is 9 varying from 2 to 91 depending on the various phases. In Ahmed et al study the mean blast% were 9% with range varying from 2 to 50%.In Motallib et al, the mean blast% were 10% with range ranging from 2 to 30%. Thus, mean values of hemoglobin, TLC, platelets and blast% were close to the other study findings. The phase distribution of CML in our study is the Chronic phase constituting 62%, Accelerated phase constituting 12% and Blast crisis phase constituting 26% which are comparable to other studies, Thus, it is found that majority of the patients of CML belong to the chronic phase followed by accelerated and blast crisis phase but in our study the blast crisis distribution was higher as compared to other studies either in primary diagnosis or during follow Up.[table 4.]

Table 4: Phases of CML in different studies

Study	Phases (%)		
	CML-CP	CML-AP	CML-BC
Present study	62	12	26
Mottalib et al[5]	82	11	5
Daley et al[6]	78	17	5
Ahmed et al[7]	77	15	8

In our study, about 44% cases showed varying degrees of fibrosis graded on the basis of reticulin staining, suggesting that the presence of fibrosis is relatively common. Among the cases presenting with fibrosis, 64% cases presented in the chronic phase, 14% in accelerated phase and 22% in blast crisis phase. Thus, fibrosis of grade-1 and grade-2 are relatively high in frequency whereas the grade-3 fibrosis is less compared to the above grades by correlating with other study.[table 5]

Table 5: Myelofibrosis Grades in other studies.

	MF GRADES			
Study		No of cases and %		
	MF-0	MF-1	MF-2	MF-3
Present study	56 cases	19(43%)	16(36%)	8(19%)
Dekmezian et al[8]	34(25%)	39(28%)	39(28%)	26(19%)
Pathobiojournal, Germany[9]	357(61%)	171(29%)	36(2%)	20(4%)
Ambareen hamid et al.10		53(65%)	22(27%)	07(8%)

The cytogenetic analysis of the cases in our study showed the presence of Philadelphia chromosome in 88% of the cases, which is classic abnormality of CML. The Ph

negative, non-informative karyotype and cases where the Investigation was not done constituted remaining 12%.In the Ahmed et al study[7], 86% cases were Philadelphia positive. In Lim T het al study, 87%cases were Philadephia positive.[11]The FISH technique was employed in the cases for the demonstration of the BCR-ABL fusion gene, molecular abnormality of CML via dual color fusion technique [12]The BCR-ABL fusion gene was recorded in form of yellow fusion signals with orange and green signals representing ABL and BCR gene. The characteristic pattern demonstrated was 1O1G2Y signals in 82% of the cases the classic positivity for fusion.

Conclusion

Chronic myeloid leukemia - chronic phase is the most common presenting phase in CML. The important need for aspirate is for the cytogenetic analysis of the CML and the diagnostic parameter is molecular evidence of the BCR-ABL fusion gene by FISH. The need for trephine biopsy is also there either primarily or during follow up because CML is a myeloproliferative neoplasm in which marrow fibrosis is not an uncommon event. Marrow fibrosis has been found in 30 to 40 % cases of CML may or may not be treatment related. Thus it is important to recognize this kind of fibrosis at an early stage as extensive fibrosis may indicate therapy failure and worse prognosis.

References:

1. Knox WF, Bhavnani M, Davson J and Geary CG. Histological classification of chronic granulocytic leukaemia. Clin Lab Haematol, 1984;6:171–175.
2. Lazzarino M, Morra E, Castello A, Inverardi D, Coci A, Pagnucco G et al. Myelofibrosis in chronic granulocytic leukaemia: clinicopathologic correlations and prognostic significance. Br J Haematol, 1986; 64: 227–240.
3. Kvasnicka HM, Theile J, Scmitt-Graef A, Diehl V, Zankovich R, Niederle N, Leder L, Scchaefer HE. Bone marrow features improve prognostic efficiency in multivariant risk classification of CML-chronic phase: a multicentre trial. J Clin Oncol. 2001; 19:2994-3009.
4. Hanchard B, Blake G, Wolff C, Samuels E, Waugh N, Simpson D et al. Age-specific incidence of cancer in Kingston and St Andrew, Jamaica, 1993-1997. West Indian Med J. 2001; 50: 123–9.
5. Mottalib et al. BMC Research Notes. 2014; 7:142
6. Riaz Ahmed, Naeem Naqi, Iftikhar Hussain, Badshah Khan Khattak, Muhammad Nadeem and Javed Iqbal. Presentation Phases of Chronic Myeloid Leukaemia: Journal of the College of Physicians and Surgeons Pakistan 2009;19(8): 469-472.
7. Chronic Myeloid Leukaemia at the University Hospital of the West Indies A 17-Year Review LM Buchner-Daley, DC Brady-West West Indian Med J. 2008; 57 (5): 493
8. Dekmezian et al. The Relevance of Reticulin Stain-Measured Fibrosis at Diagnosis in Chronic Myelogenous Leukemia; Cancer. 1987; 59:1739-1743.
9. Myelofibrosis – What's in a Name? Consensus on Definition and EUMNET Grading; Institute of Pathology, University of Cologne, Cologne, Germany. Pathobiology. 2007; 74:89–9.
10. Ambareen Hamid et al. J Coll Physician Surg pak. 2019 Nov;29(11)1096-1100.
11. TH Lim et al. The incidence and patterns of BCR-ABL rearrangements in CML using FISH. Ann Acad Med Singapore. 2005;34:533-8.
12. Jain PP, Parihar M, Ahmed R, Abraham A, Vishvabandya A et al. FISH patterns of BCR/ABL1 fusion in CML at diagnosis. Indian J Patho Microbio, 2012.