e-ISSN: 0975-1556, p-ISSN:2820-2643

Available online on www.ijpcr.com

International Journal of Pharmaceutical and Clinical Research 2023; 15(6); 1236-1250

Original Research Article

The Use of Fibular Fixation with Plating as Supplementary to Intramedullary Interlocking Nailing of Tibia for Distal Third Both Bones Fracture of Leg: A Prospective Study

Lokesh M[1], Kiran Kumar HV[2], Santosh Kumar K[3], Nayeemulla Baig[4]

[1]Associate Professor, Department of Orthopaedics, KIMS, Bengaluru
[2]Assistant Professor, Department of Orthopaedics, KIMS, Bengaluru
[3]Assistant Professor, Department of Orthopaedics, KIMS, Bengaluru
[4]Junior Resident, Department of Orthopaedics, KIMS, Bengaluru

Received: 20-04-2023 / Revised: 17-05-2023 / Accepted: 10-06-2023
Corresponding author: Dr. Nayeemulla Baig
Conflict of interest: Nil

Abstract

Introduction: Distal tibia extra-articular fractures are often a result of high energy trauma, fall from height or twisting injuries. They are commonly associated with fibular fractures and soft tissue injuries. Both bones fracture has been correlated with higher severity of injury than those with isolated tibia fractures. The goals of study are to include correction and maintenance of sagittal and coronal alignment, establishment of length and rotation and early functional range of movements of knee and ankle. As there is mismatch between the diameters of nail and the medullary cavity, with no nail-cortex contact, the nail may translate laterally along the coronally placed locking screws and increases stress in place on the locking holes to maintain fracture alignment post-surgery leading to varus or valgus deformity.

Methodology: The study was conducted in the department of orthopaedics at KIMSH Bangalore. All patients included in the study were assessed clinically and confirmed radiologically to avoid any other pathology. Plain radiographs of Knee, Leg and Ankle in AP and lateral view of affected site were taken. After diagnosis, the patients were selected for the study depending on inclusion and exclusion criteria. Surgery was performed under strict aseptic precautions. All the patients underwent same method of treatment and were assessed post operatively based on the Karlstorm-Olerud Performance Score. Regular OPD follow up done at 6, 12 and 24 weeks.

Results: Post-operative wound care was sought and physiotherapy started. By the end of 3 months, the affected limb had similar range of motion as the normal limb and out of 20 cases, the results were excellent in 13, Good in 5 and fair in 1 and Poor in 1 case. The alignment was well maintained in both sagittal and coronal plane.

Conclusion: Fixation of the fibula along with interlocking nailing of the tibia for distal third fractures both bones leg decreases the mal-alignment of the tibia and mal-rotation of the ankle as compared with only interlocking nailing.

Keywords: Fractures; Both Bones Leg; Distal third; Closed; IMIL nail; Plating to Fibula; Karlstorm-Olerud score.

Introduction

The leg is made of two bones. Medially tibia and laterally fibula. The tibia along with femur and patella form the Knee joint proximally. The Tibia along with fibula and the Talus form the ankle distally. Tibia is a commonly fractured long bone in the body due to its position and lack of adequate soft tissue protection. On the basis of the fracture location in the bone; distal tibial fractures have the second highest incidence of all tibia fractures after the mid-shaft fracture of tibia. Road traffic accidents cause most of the tibia fractures.[1]

The anteromedial surface of tibia being subcutaneous in location is prone for extensive bone and soft tissue injury and there is a high incidence of open fractures when compared with other long bones. Previously surgeons had adopted nonoperative management wherein the incidences of non-union, malunion, and joint stiffness were high. A severe fracture complicated by non-union or infection often results in employment loss or other social and places a financial strain on the patient and their families. Surgical stabilization of fractures and early mobilization of the patient provides best clinical outcome. Treatment planning for fracture fixation should be considered for individual patients separately.[2]

These areas of controversy are an excellent target for prospective clinical research. Fracture patterns are complex, diverse, and technically demanding and do not lend themselves well to random allocation. In addition, the factors that lead to good versus poor outcomes often depend on treatment techniques than other factors, which can be controlled. For these reasons, new treatment techniques may need to continue to be evaluated in case series and cohort studies. [3]

Fractures of the distal tibial shaft deserve special attention since they are common and the management is controversial [4,5]. Tibial shaft being subcutaneous throughout its length has a precarious blood supply, severe complications and major disability are thus common outcomes [6]. Fractures of the fibula and tibia can vary from undisplaced fractures with subtle soft tissue injury to traumatic amputations. The treatment modalities described for tibia and fibula fractures also vary from simple cast immobilization to complex surgical procedures.[7]

Distal tibia extra-articular fractures are often a result of high energy trauma, Fall from height or twisting injuries.[8] They are commonly associated with fibular fractures and soft tissue injuries.[6]Both bones fracture has been correlated with higher severity of injury than those with isolated tibia fractures. In case of distal third both bones fractures of leg treated only with intramedullary nail, there is mismatch between the diameters of nail and the medullary cavity, and with no nail-cortex contact, the nail may translate laterally along the coronally placed locking screws and increases stress in place on the locking holes to maintain fracture alignment, leading to varus or valgus deformity.[9]

Locked intramedullary nailing is the treatment of choice for closed fractures of the tibia shaft.[10] For proper alignment, the nail should be centrally placed in both the proximal and distal fragments[9,11] but many a times the nail does not fit properly into the distal fragment of the lower third of the tibia which leads to complications. This places additional stress on the distal locking bolts that may lead to breakage and thus the malalignment. Intramedullary nailing of more distal fractures is possible, but the ability to maintain a mechanically stable reduction becomes more difficult.[12] Stability can

be increased with usage of multiple locking options in the distal fragment.[13]

Concern exists that malalignment of a healed tibial shaft fracture may result in post-traumatic arthritis of the ankle or knee[14-20]. As the site of the deformity reaches the ankle or the knee, malalignment results in maldistribution of articular surface pressures that can predispose a patient to premature osteoarthritis [4,20-23].

The site of the mal-union is important, with distal deformities more likely to be symptomatic [14, 22, 23] The role of the fibula in the maintenance of sta ility after fixation of distal tibial fractures has not been well defined [18,24,25]. No study exists on the effect of fibular fixation in fractures of both bones of distal third leg treated with intramedullary nailing of the tibia. However, some cadaver study exists on the effect of fibular plate fixation on rotational stability of the two simulated lower tibial fractures treated with intramedullary nailing. Cadaver study showed increased initial rotational stability following fibular fixation with lower tibial fractures compared with intramedullary nailing of tibia alone [26].

Material and Methods

The present study "The Use Of Fibular Fixation With Plating As Supplementary To Intramedullary Interlocking Nailing Of Tibia For Distal Third Both Bones Fracture Of Leg- Prospective Study" was conducted in the department of orthopaedics of a tertiary care hospital between october 2020 and may 2022 after obtaining approval form the ethical committee of the institute.

Design of the Study:

Prospective study to evaluate the outcome of the fractures of both bones in the distal third of the leg.

Duration of study:

October 2020 to May 2022 (18 months)

Population of study:

Patients admitted in the department of orthopaedics with fracture distal third both bones Leg.

Sample Size:

Twenty cases in total. Patients with closed and open type 1&2 fracture distal third both bones leg with both males and females aged more than 16 years were included in the study. Cases with had compound type 3 fracture or ones with fracture with intraarticular extension or vascular injuries or with fracture of proximal of middle third of leg were excluded from the study.

Methodology:

Source of Data:

Patients admitted to the Department of Orthopaedics in Kempegowda Institute of Medical Sciences, Bengaluru

Ethical Consideration:

The study was conducted after obtaining permission from the Institutional Ethics Committee (IEC) at Kempegowda Institute Of Medical Sciences. All the data collected as a part of this study was kept confidential. Patients' identity will never be disclosed.

Method of collection of data and selection of cases:

Patients with fracture of distal third of leg involving both tibia and fibula and managed with intramedullary nailing to tibia and plating to fibula were included in the study after taking prior informed and written consent. Only the cases which fulfilled the inclusion criterion were taken in the study.

Inclusion Criteria

a) Distal 1/3rd fractures of both bones Leg
b) Acute Fractures
c) Age >16 years
d) Closed Fractures
e) Grade 1&2 Compound fractures

Exclusion Criteria

a) Grade 3 Compound Fractures
b) Proximal and Mid shaft Tibia/ Fibula
c) Age less than 16 years
d) Vascular Injuries
e) Articular extension
f) Pathological fractures
g) Patient not willing for surgery

All the patients were counselled verbally and thoroughly explained about the details of the procedure in their vernacular language. A written and an informed consent were taken from them in English and their understandable language. Only the consenting individuals were taken for the study and the identity was not disclosed.

All the cases were managed surgically with open reduction and internal fixation with plate and screws to the fibula followed by closed reduction and internal fixation of the tibia with Intramedullary interlocking nail (IMIL nail).

Standard post-operative protocol was followed. Intravenous antibiotics (one each for gram positive& negative) and analgesics were administered. Other medications such as oral analgesics, anti-inflammatory enzymes were given. Dressing was done on Post-operative Day 2 and was repeated only if there were any soakage or discharge. The sutures were removed on post- operative day 14. Non weight bearing mobilization was started soon after the surgery with the walker support. Patients were then advised to do active movements (ROM physiotherapy) of the affected knee and ankle and were subsequently reviewed at 6th, 12th and 24th week. Weight bearing was started slowly from 6th week post operatively.

Patient was followed up regularly. On the follow ups, the patient was evaluated clinically with range of movements of the knee, ankle. Any pain at the operative/ fracture site was noted. The wound was examined for any gaping/ discharge. Serial X-rays were taken and the outcome was evaluated. The functional activity of the ankle was assessed by the Karlstorm-Olerud Performance Score, AOFAS and FADI scores. Visual analogue (VAS) scale was used to see for pain from the pre op period to the final follow up.

Observations and Results

We conducted our study in tertiary care hospital after having obtained the approval of the institutional ethics committee. A total of 20 patients suffering from post-traumatic distal third tibia fibula fractures and meeting the selection criteria were enrolled in our study. They were managed with ORIF with plate and screws to fibula and CRIF with IMIL nail to tibia.

Age and sex distribution:

Table 1: Age and Sex distribution of study

Age	Males		Females		Total
Side	Right	Left	Right	Left	
20-35y	03	02	00	01	06
35-50y	02	02	01	03	08
50-70y	03	01	01	01	06
Total	08	05	02	05	20
Total	13		07		20
	42.38Years		43.8Years		
Average Age	42.9Years				

The Fracture was more commonly seen in men (65%) in the age between 35-50 years. Right side was more common in men (08 cases) and Left (05) in females. The average age in men was about 42.38years whereas in females it was 43.8years.

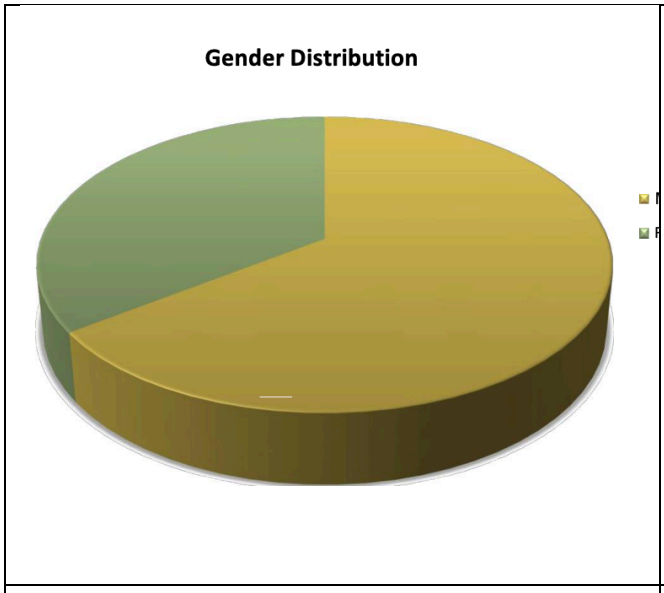

Graph 1: Gender distribution

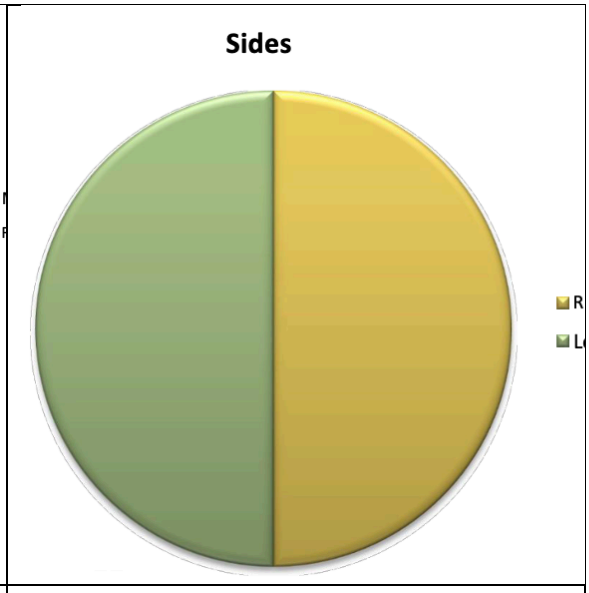

Graph 2: Side Of injury

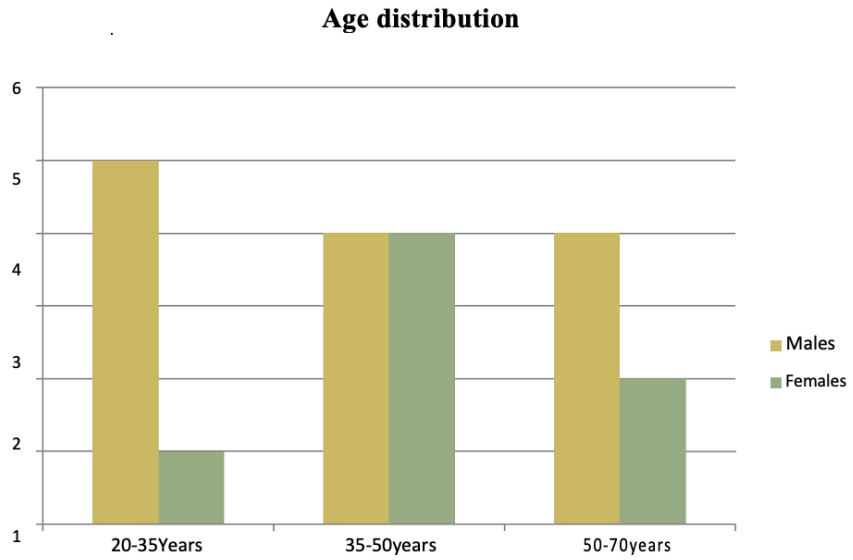

Graph 3: Age distribution

Mode of injury

The commonest mode of injury was due to road traffic accidents (RTA). Males were affected more than females. The second most type was due to twisting injuries and fall from height. We recorded 2 cases of assault which were seen in men

Table 2: Modes of Injury

Type	Number
Road traffic accident	14
Fall from height	04
Assault	02

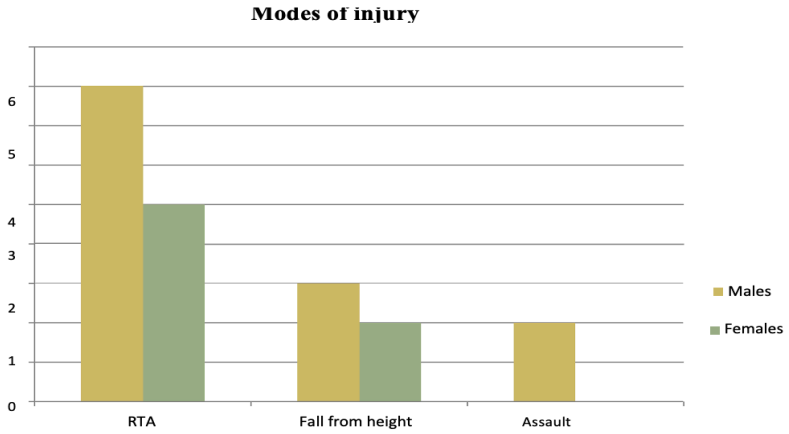

Graph 4: Modes of Injury

Results

All the fractures united in a mean period of 11.8 weeks. (LCL 10.19 weeks and UCL of 11.98 weeks) Karlstorm-Olerud scoring was excellent in 13 fractures (65%), good in 5(25%), fair in 1 (05%) and Poor in 1 (05%) Radiologically, the mean post-op coronal plane deformity was +/-1.7 degrees (95% LCL 0.6 and 95%UCL degrees) when compared to the mean pre-op varus/valgus alignment of +/-10.1 degrees (95% LCL8.1 degrees and 95% UCL 12.6 degrees). The alignment was maintained till union with similar mean in the coronal plane.

Table 3: Coronal plane alignments

	No. of cases	Mean (degrees)	SD
Pre-Op	20	10.1	4.4
Post-Op	20	1.7	2.6
At union	20	1.7	2.6

Repeated ANOVA tests showed an F test valur of 43.84 which is significant as the pvalue. The mean post-operative antecurvatum/recurvatum alignment was about +/-0.25degrees(95%LCL 0.2 degrees and 95% UCL 1.9 degrees) when compared to the mean operative antecurvatum /recurvatum alignment of +/-7.5 degrees (95% LCL 4.8 degrees and 95% UCL 11.1 degrees). F test values in repeated measures ANOVA is 21.40 witha p value of 0.01(<0.05) which is statistically significant. The mean antecurvatum/ recurvatum alignment at the time of union was +/-0.7degrees. The loss was not significant statically.

Table 4: antecurvatum/recurvatum alignment

	No. of cases	Mean (Degrees)	SD
Pre-Op	20	7.5	7.1
Post-Op	20	0.3	0.7
At Union	20	0.4	0.8

Complications:

The commonly encountered problems with fractures of distal third fractures both bones leg managed with intramedullary nailing to tibia and plating to fibula were. Delayed wound healing Infections Ankle stiffness Due the subcutaneous nature of tibia and the

fibula, the soft tissues around the fracture site undergo a lot of stress and necrosis hence the tissue healing tends to take longer than normal commonly. It was managed with minimal soft tissue handling and compression free closure and adequate limb elevation to avoid the oedema. The Infections were divided into superficial and deep ones. The Superficial ones were managed with adequate antibiotics without the need for secondary surgery.

Whereas the deep infections involved the implant, the surrounding soft tissues and bone which was managed with debridement and implant removal amongst the twenty cases, one case had superficial infection, which was managed with prolonged parenteral antibiotics and delayed suture removal.

Figure 1: Complication- Superficial wound discharge



Figure 2: Reconstruction plate

Figure 3: 1/3rd tubular plate

Figure 4: Locking Fibular plate

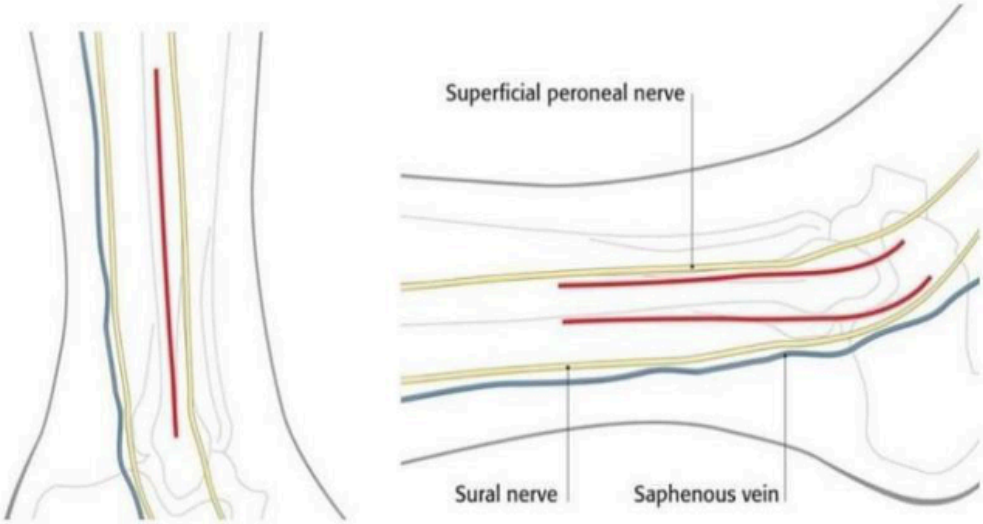

Picture 5: Incision for open reduction and internal fixation of fibula

Picture 6: Clinical image of Incision for ORIF of fibula

Picture 7: Stabilisation of the fibular fracture

Picture 8: Fibular Stabilisation with plate and screws in situ

Picture 9: Wound closure

Picture 10: Tibial Intramedullary interlocking nail set

Picture 11: IMIL nail assembly with sleeve, drill-bit and screws in-situ

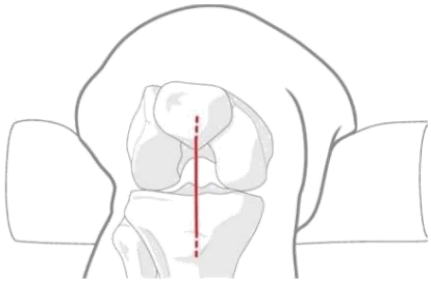

Picture 12: Incision for entry point of the IMIL nail for Tibia

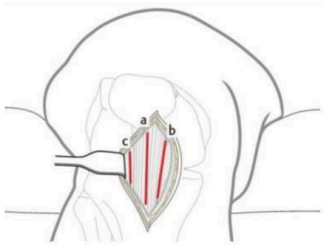

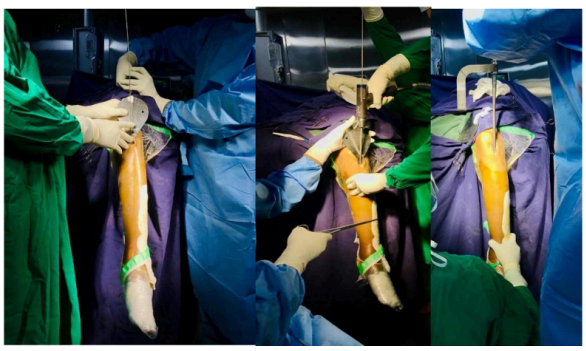

Picture 13: Clinical images showing passage of ball tipped guidewire, reaming using flexible reamer and passage of IMIL nail to the tibia

X-rays:

Figure 14: 4Pre-operative Xray with fracture distal third both bones leg

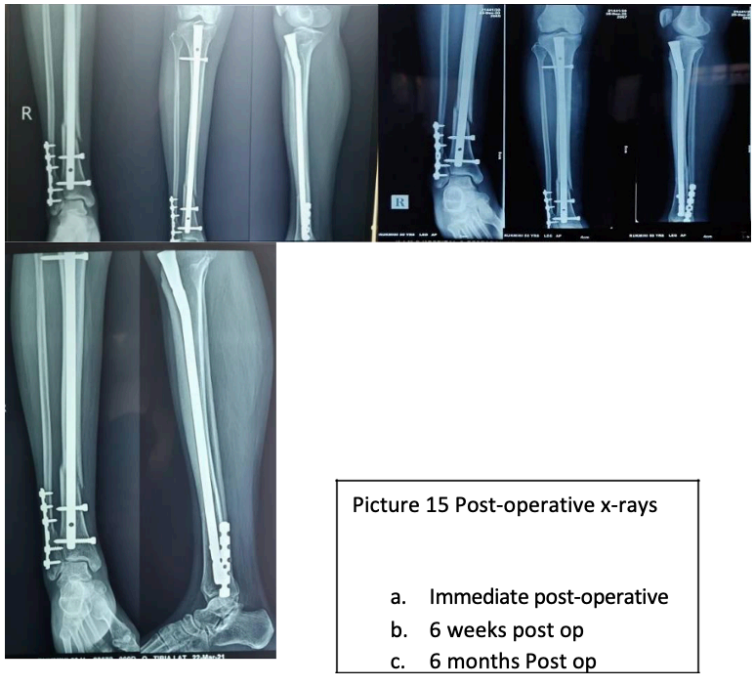

Picture 15 Post-operative x-rays

a. Immediate post-operative
b. 6 weeks post op
c. 6 months Post op

Picture 16: Clinical images of patient at 6 months post op

Case No 2:

Picture 17: Pre-operative Xray with fracture distal third both bones leg

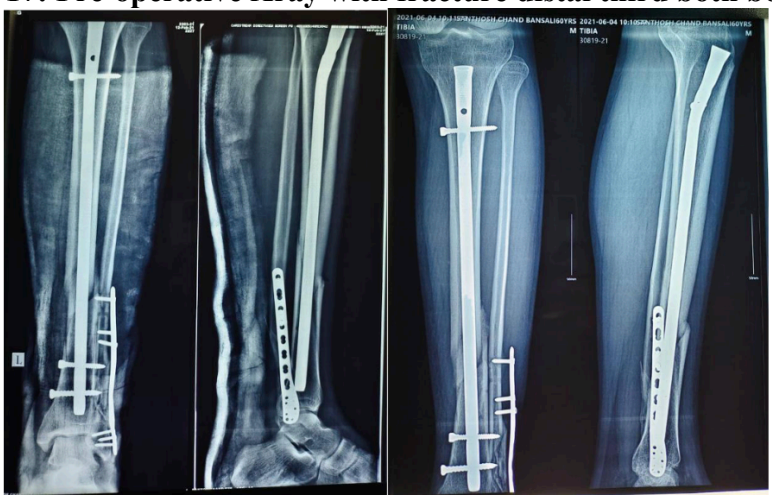

Picture 18 Post-operative x-rays

d. Immediate post-operative
e. 3 months post op
f. 6 months Post op

Picture 19: Clinical images of patient at 6 months post op

Case No 03:

Picture 20: Pre-operative Xray with fracture distal third both bones leg

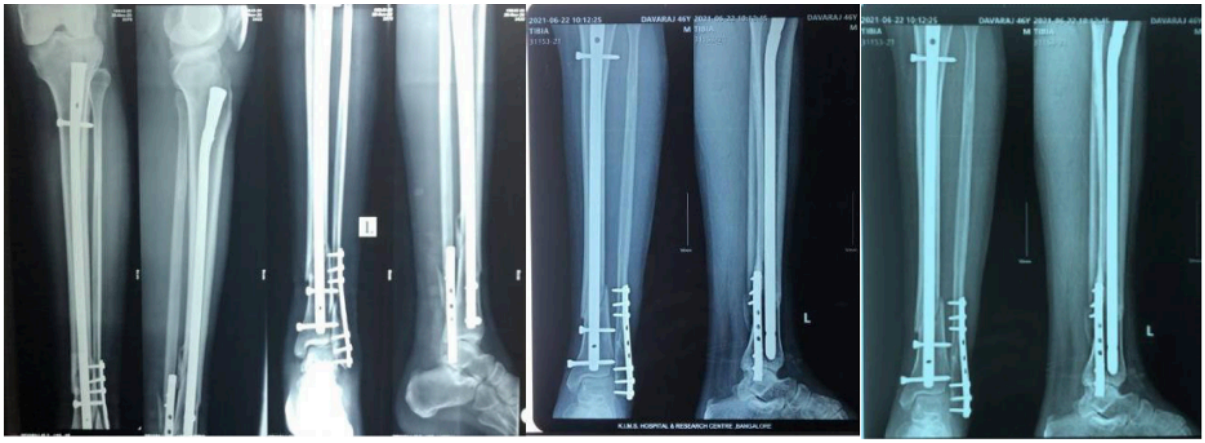

Figure 21: Postoperative x-rays
(g. immediate post-operative; h. 3 months post op; i. 6 months post op)

Ankle stiffness or reduced range of movements of ankle is commonly encountered with distal tibia fracture. Delayed ankle mobilization is one of the primary reasons for ankle stiffness. Delay in mobilizing the ankle for more than 3 weeks can give rise to stiffness. Early ankle range of motion should be started to avoid this problem which needs rigid and stable fixation as a prerequisite. In our study, 2 patients (10%) initially complained of ankle stiffness. They were managed with active and assisted physiotherapy to the ankle. They recovered by 6 weeks.

Conclusion and Summary:

We conclude that supplementation of fibular plating to intramedullary nailing of tibia in the fracture of distal third both bones leg that:

1. Limb Alignment was better achieved in fresh fractures.
2. Stabilized the angular and rotational deformities and maintained alignment till union
3. Avoids the initial loss of reduction.

The implants over the tibia being intramedullary, it avoids being palpable.

References

1. Pan RH, Chang NT, Chu D, Hsu KF, Hsu YN, Hsu JC, et al. Epidemiology of orthopedic fractures and other injuries among inpatients admitted due to traffic accidents: A 10-year nationwide survey in Taiwan. Scientific World Journal 2014. 2014; 637872
2. Costa ML, Achten J, Griffin J, et al. Effect of Locking Plate Fixation vs Intramedullary Nail Fixation on 6-Month Disability Among Adults with Displaced Fracture of the Distal Tibia: The UK FixDT Randomized Clinical Trial. JAMA. 2017; 318(18): 1767– 1776.
3. Dr. Lokesh Holagundi, Dr. Deepak S, Dr.Dayanad. Dr. Ramachandra. Functional Outcome with Surgical Management in Distal Tibia Fracture. IOSR Journal of Dental and Medical Sciences (IOSR-JDMS) Volume 13, Issue 5 Ver. V. (May. 2014), PP 83-90IOSR Journal of Dental and Medical Sciences (IOSR-JDMS). May 2014;13(5): 83-90
4. Rockwood and Greens Fractures in adults. 8th Ed, Wolters Kluwer Health; 2015;2: 2415-2468.
5. Nicoll E.A, A survey of 705 cases Fractures of the tibial shaft. J Bone Joint Surg Br. 1964; 46-B: 373-387
6. Varsalona R, Liu GT. Distal tibial metaphyseal fractures: the role of fibular fixation. Strategies in trauma and limb reconstruction. 2006 Dec 1;1(1):42-50
7. Chapman's orthopaedics.3 rd edition, vol 1. Philadelphia: Lippincott Williams and Wilkins; 2001; 755-810

8. Ramasamy T, Ruttala HB, Kaliraj K, Poudel K, Jin SG, Choi HG, Ku SK, Yong CS, Kim JO. Polypeptide derivative of metformin with the combined advantage of a gene carrier and anticancer activity. ACS Biomaterials Science & Engineering. 2019 Sep 23;5(10):5159-68
9. Singh SK, Manjhi LB, Ojha A. Role of fibular fixation in static intramedullary interlocking nailing for distal third tibia and fibula fractures. International Journal of Orthopaedics. 2019;5(2):1126-8
10. Egol KA, Weisz R, Hiebert R, Tejwani NC, Koval KJ, Sanders RW. Does fibular plating improve alignment after intramedullary nailing of distal metaphyseal tibia fractures? Journal of orthopaedic trauma. 2006 Feb 1;20(2):94-103
11. Tyllianakis M, Megas P, Giannikas D, Lambiris E. Interlocking intramedullary nailing in distal tibial fractures. Orthopedics. 2000 Aug 1;23(8):805-8
12. Sathish M. Role of Fibular Plating in Management of Distal Bone Fracture of Leg Janssen KW, Biert J, Van KA. Treatment of distal tibial fractures: plate versus nail: a retrospective outcome analysis of matched pairs of patients. 2007; 31(5):709-714
13. Vallier HA, Bedi. Radiographic and clinical comparison of distal tibia fracture (4-11cm from plafond) nailing versus plating. J Orthop trauma. 2008may;22(5):307-11.
14. Browner BD, Jupiter JB, Levine AM, Trafton P G. Tibial shaft fractures In: Browner BD, Jupiter J B, Levine A M, Trafton G, editors. Skeletal trauma. Philadelphia: Saunders; 2003:3(2): 2131-2255.
15. Rolando Puno., Joseph T. Teynor, Nagano Junji., Gustilo R. Critical analysis of the treatment of 201 tibial shaft fractures. Clin Orthop. 1986; 212: 113-121.
16. Jeffrey R., Kevin C., Oliver B., Peter K., David H. Nonunions of the distal tibia treated by reamed intramedullary nailing. J. Orthop Trauma. 2004; 18: 603-610.
17. Dietz F.R, Merchant T.C. Long term follow up after fractures of the tibial and fibular shafts. J Bone Joint Surg Am. 1989; 71-A: 599-606.
18. Teitz C.C., Carter D.R., Frankel V.H., Washington S. Problems associated with tibial fractures with an intact fibula. J Bone Joint Surg Am. 1980; 62-A: 770-776.
19. Puno R.M., Vaughan J.J., Fraunhofer J.A., Stetten M.L., Johnson J.R. A method of determining the angular malalignments of the knee and ankle joints caused from a tibial mal union. Clin Orthop. 1987; 223: 213-219.
20. Tarr R.R., Resnick C.T., Wagner K.S., Sarmiento A. Changes in tibiotalar joint contact areas following experimentally induced tibial angular deformities. Clin Orthop. 1985; 199: 72-80.
21. Kettelkamp D.B., Hillberry B.M., Murrish D.E., Heck D.A. Degenerative arthritis of the knee secondary to fracture mal union. Clin Orthop 1988; 234: 159-169.
22. Schoot D.K.E., Outer A.J.D., Bode P. J., Obsermann W. R.,Vugt A.B Degenerative changes at the knee and ankle related to mal-union of tibial fractures– 15 years follow up of 88 patients. J Bone Joint Surg Br. 1996; 78-B: 722-725
23. McKellop H.A., Llinas A., Sarmiento A. Effects of tibial malalignment on the knee and ankle. Orthop. Clin. North Am. 1994; 25: 415-423
24. Weber T.G., Harrington R.M., Henley M.B., Tencer A.F. A biomechanical investigation: Theroler of fibularr fixation in combined fractures of the fibula and tibia: J. Orthop Trauma. 1997; 11(3): 206-211.
25. Todd W M., Lawrence M.J., James N.V., Thomas D.A., Shepard H.R. Susan B.B. External fixation of tibial plafond fractures; is routine plating

of the fibula necessary? J Orthop Trauma. 1998; 12: 16-20.
26. Kumar A., Charlebois S.J., Cain L.E., Smith R.A. Daniels A.U. Crates J.M. Effect of fibular plate fixation on rotational stability of simulated distal tibial fractures treated with intramedullary nailing. J Bone Joint Surg Am. 2003; 85-A: 604-608
27. James Kellam, MD Commentary and prospective on "Effect of fibular plate fixation on rotational stability simulated distal tibial fractures treated with intramedullary nailing by Anantkumar" eJBJS, 2003.
28. Richter D, Hahn MP, Laun RA, Ekkernkamp A, Muhr G, Ostermann PA. Ankle para-articular tibial fracture. Is osteosynthesis with the unreamed intramedullary nail adequate? Der Chirurg; Zeitschrift fur Alle Gebiete der Operativen Medizen. 1998 May 1;69(5):563-70.
29. Vallier HA, Le TT, Bedi A. Radiographic and clinical comparisons of distal tibia shaft fractures (4 to 11 cm proximal to the plafond): plating versus intramedullary nailing. Journal of orthopaedic trauma. 2008 May 1;22(5):307-11
30. Prasad M, Yadav S, Sud A, Arora N, Kumar N, Singh S. Assessment of the role of fibular fixation in distal-third tibia-fibula fractures and its significance in decreasing malrotation and malalignment. Injury, Int J Care Injured. 2014; 44:1885-91
31. Veluswamy V, Loganathan S, Shankar TU, Purushothaman PJ, Dhanarajan GR. Can isolated tibia intramedullary interlocking nailing in fracture distal 1/3 rd bone leg prevent fracture malalignment: will concurrent fibula fixation help? International Journal of Research in Orthopaedics. 2019 Nov;5(6):1050