e-ISSN: 0975-1556, p-ISSN:2820-2643

Available online on www.ijpcr.com

International Journal of Pharmaceutical and Clinical Research 2023; 15(6); 278-284

Original Research Article

A Study of the Dimensions of Pedicles in the Dried Human Typical Thoracic Vertebrae

Varghese P D[1], Rajad R[2], Veena Nair[3], Reshmi R[4]

[1]Associate Professor, Department of Anatomy, Government TD Medical College, Alappuzha, Kerala, India
[2]Associate Professor, Department of Anatomy, Government Medical College, Ernakulam, Kerala, India
[3]Assistant Professor, Department of Anatomy, Government TD Medical College, Alappuzha, Kerala, India
[4]Assistant Professor, Department of Anatomy, Government TD Medical College, Alappuzha, Kerala, India

Received: 20-03-2023 / Revised: 15-05-2023 / Accepted: 30-05-2023
Corresponding Author: Dr Reshmi R
Conflict of interest: Nil

Abstract

Knowledge of the morphometry of the pedicles of thoracic vertebrae is important for the placement of screws for treating various degenerative disorders of the spine. The morphometry varies considerably among different races and gender. The morphometric knowledge is necessary for designing specific screws and thereby minimizing operational hazards. The study was conducted on 100 dry human typical thoracic vertebrae obtained from the Department of Anatomy, Govt. T.D Medical College, Alappuzha. The measurements taken were pedicle width (PW) and pedicle height (PH). In our study, the mean pedicle width on the right side was found to be 4.2420 + 1.044 mm and on the left side was 4.2473+0.917mm. Mean pedicle heights on the right and left sides were 10.8495 +1.172mm and 10.8481+1.082mm respectively. The findings of the study are similar to the observations made by other Indian researchers. However, the measurements were lower when compared to those of the western population. These differences could be attributed to their larger physique.

Keywords: Morphometry, Pedicles, Thoracic Vertebrae, Bone Measurements, Pedicle Screw Fixation, Pedicle height, Pedicle Width

Introduction

The human vertebral column is essentially made up of thirty-three vertebrae with the intervertebral discs intervening between them. These include seven in the cervical, twelve in the thoracic, five in the lumbar, five in the sacral and four in the coccygeal region. The column thus formed protects the spinal cord and the nerve roots arising from them. The twelve thoracic vertebrae are recognized by the presence of costal facets on the body and the transverse processes except the last two thoracic vertebrae. Hence, the second to eighth thoracic vertebrae are typical as they bear common features while the first and ninth to twelfth are atypical and can be identified by specific distinguishing features. The mid-thoracic region because of its narrow vertebral canal diameter and a comparatively low blood supply is more

prone to various kinds of degenerative and traumatic conditions. [1]

Pedicles of the vertebrae are the short, thick, rounded dorsal projections from the superior part of the body at the junction of its lateral and dorsal surfaces. the concavity formed by the curved superior border of the pedicle is shallower than the inferior one. The dimensions and angles of thoracic pedicles change progressively from the upper thoracic spine distally. There is a successive caudal increase in thickness. These changing relationships have a significant bearing on the placement of pedicle screws in spinal surgery. [2]

The vertebral spine is involved in many conditions like scoliosis, traumatic injuries and vertebral degeneration due to infections. To limit the rotation and to achieve stability in such patients adjacent vertebrae are fixed using plates and rods. These plates are secured in position using pedicular screws. The screws are inserted through the pedicles preferably through a posterior approach and this is known as posterior transpedicular fixation. [3,4] This method of fixation requires comprehensive morphometric analysis of thoracic pedicles without which the surgeon cannot perform the procedure accurately. The use of pedicle screws in the thoracic spine poses a great challenge because the thoracic vertebral pedicles are smaller in size and more variable when compared to the standard lumbar vertebral pedicles [5]. The usage of bigger screws will result in the fracture of the pedicle with resultant injury to nerve roots. [6,7]

Racial and gender differences in pedicle morphometry among various ethnic groups are well documented and these factors may determine the course of surgical treatment [8,9,10]. For example, studies have found that Japanese and African Americans tend to have longer pedicle lengths than other ethnic groups. [11]

The standard pedicle screws available are from 4.5 mm to 8 mm in diameter and are based on the morphometric analysis of the Caucasian population [12]. Hence information on the dimensions of the pedicle is very important for the accurate manufacture of screws in specific populations for transpedicular fixation. For a safe passage through the pedicle, fixation screws require a minimum of 0.5mm clearance on each side to avoid perforation of the pedicle cortex [13]

There are only a handful of studies on the morphometric analysis of pedicles in human thoracic vertebrae in the Indian population. Therefore, the present study was conducted to gain more knowledge into the various dimensions of thoracic vertebral pedicles in our population to design and manufacture accurately sized screws during the procedure of transpedicular fixation. This will ensure a safe surgical procedure without any complications.

Methodology

Study Setting

The study was conducted on dry human typical thoracic vertebrae. The vertebrae were obtained from the department of Anatomy, Govt. T.D Medical College, Alappuzha. A total of 100 typical thoracic vertebrae (T2-T8) were selected for the study.

Method of measurement

Broken and damaged vertebrae with bony spurs were excluded from the study and only intact vertebrae in good condition were studied and photographed. The measurements were taken using a Digital Vernier caliper and the mean and standard deviation of the measurements were calculated.

Parameters

1. Pedicle width (PW): It is the maximum distance between medial and lateral surfaces of pedicle measured at right angles to the long axis of the pedicle. (Fig.1)
2. Pedicle height (PH): It is the maximum vertical distance between superior and

inferior border of pedicle at its midpoint. (Fig.2)

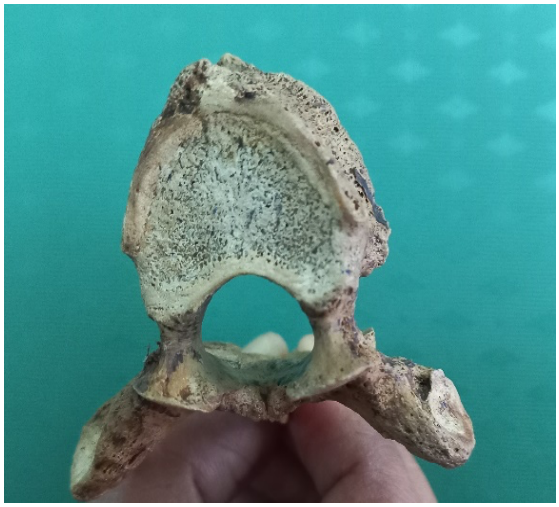

Figure 1: Showing pedicle width (PW)

Figure 2: Showing pedicle height (PH)

Statistical analysis

The mean, average and standard deviation of the measurements were analysed. The comparison of morphometric dimensions of the right and left sides was performed using independent Student's t-test and p-value was calculated. All the statistical calculations were performed using the software SPSS (Statistical Presentation System Software, SPSS) for windows version 16.

Ethical Clearance

Institutional ethics committee clearance was obtained before the start of the study from the Institutional Ethics Committee, Govt. T.D Medical College, Alappuzha.

Results

A total of 100 typical thoracic vertebrae were studied. The results obtained are shown in table1. The mean pedicle width on the right side was 4.2420mm with range varying from 2.07mm to 7.54mm. The mean pedicle width on left side was 4.2473mm with a range of 2.55mm - 7.55mm. The mean pedicle height on right side and left side were 10.8495mm and 10.8481mm respectively. The range on right varied from 8.30mm to 13.84mm whereas on left side it varied from 7.37mm to 13.41mm.

Table 1: PW and PH obtained in the present study in mm (RPW and RPH - PW and PH on right side, LPW and LPH – PW and PH on left side)

Measurements	N	Range	Minimum	Maximum	Mean	Std. Deviation	P value
RPW	100	5.47	2.07	7.54	4.2420	1.04485	P value =< 0.001
RPH	100	5.54	8.30	13.84	10.8495	1.17281	
LPW	100	5.00	2.55	7.55	4.2473	0.91797	P value = < 0.001
LPH	100	6.04	7.37	13.41	10.8481	1.08229	

Discussion

The present study was done to get a comprehensive knowledge of the morphometry of pedicles in typical thoracic vertebrae among the Indian population. The data obtained were analyzed and compared with the previous studies done in India, Western and other Asian countries. The vertebral body is formed of two columns, the anterior and posterior. The anterior

columns are constituted by the vertebral body and the intervertebral discs whereas the posterior columns are formed by the neural arches. The pedicles act as a beam that connects these two columns. Thus it helps in weight transmission from the anterior column to the posterior column [14].

The pedicles are the strongest part of a vertebra and are made up entirely of cortical bone with a small core of cancellous bone [14]. With an increase in spinal degenerative disorders following trauma and infections, transpedicular spinal fixation has become a popular method of surgical intervention. Although transpedicular fixation was first described by Boucher in the 1950s, it was popularized in the last four decades by the works of Louis, Roy-Camille, and Saillant [15,16]. The procedure of transpedicular fixation involves the insertion of screws through the pedicles and this requires a correct knowledge of pedicle morphometry. In case of any difference between the screw and pedicle length, the pedicle may be damaged during the process of instrumentation resulting in injury to neural structures. For achieving appropriate rigidity and rotational stability, it has been proposed that the screw diameter should fill more than 70% of the pedicle diameter, the wider the screw, the stronger will be the fixation. A good knowledge of the pedicle size is therefore essential for proper instrumentation. Numerous authors have studied the morphometry of thoracic spine and pedicle size using computed tomography (CT) scans, plain radiographs, direct specimen measurement and quantitative 3-dimensional anatomic techniques and have reported the values. [9,10,15,16,17,18,19]

Specific differences in the pedicle dimensions between males and females have been reported in the literature. Kim et al. reported differences in pedicle width between males and females at T10, L3, and L5 levels while Hou et al. reported differences only at T12 level, wherein the male pedicles were found to be larger. However, we did not study the sex differences. [11,20]

In our study, the mean pedicle width was found to be 4.24 mm which is comparable to a study done in India by Singh et al [1] and Patil DK et al [21] but less than the studies by Zindrick MR et al [22]and Mc Lain RF et al [23] based on western population. Mean pedicle height was found to be 10.84 mm which is comparable to the results done by Patil DK et al [21] and Garg S et al [24] on Indian subjects. It is more than the results obtained by Tan et al [25] on the Singaporean population but less than the results got by Singh R et al [1], Panjabi et al [26] Berry et al [27], Zindrick MR et al[22] and Datir SP et al[28]. The average pedicle width on the right side was 4.2420 mm whereas the average pedicle width on the left side was 4.2473 mm. This is similar to the findings of Patik et al and Tan et al. Thus the average pedicle width is more on the left side. This means that surgical procedures with screws of diameter 4 are safer to be performed on the left side. Likewise, the average pedicle height on the left side is 10.8481 mm and on the right side is 10.8495 mm. Thus pedicle height is more on the right side.

According to the literature available, it is known that the pedicle height is always greater than the pedicle width. The present study also agrees with this finding. However, the width of the pedicle is more important during the selection of pedicle screw diameter in comparison to pedicle height during spinal surgeries. It has also been found that the dimensions and angle of the thoracic pedicle change progressively as we move from the upper thoracic spine distally and there is a progressive increase in thickness caudally. Hence based on our study and with the findings of Datir and Mitra [28] we can note that even a 4-mm screw should be used carefully at the mid-thoracic level. Our findings are similar to that of Tan et al. [25] who pointed out that

except for T1 and T10-T12, the pedicle width was not wide enough to accommodate a 5-mm transpedicular screw.

Table 2: Comparison of Pedicle dimensions from previous studies (P.H=Pedicle height, PW=Pedicle width).

S. No.	Observer	Year	Country	P.W (mean) mm	P.H (mean) mm
1.	Berry JL etal	1987	USA	5.6(T2, T7)	11.9(T2, T7)
2.	Zindrick MR. et al	1987	USA	5.46	12.21
3.	Panjabi. et al	1991	USA	Left:6.43 Right:6.61	Left:11.93 Right:11.76
4.	McLain R Fet al	2002	USA	5.87	11.61(T2-T6)
5.	Datir.SP et al	2004	INDIA	5.26	12.16
6.	Tan et al	2004	SINGAPORE	Left:4.54 Right:4.56	Left:9.41 Right:9.53
7.	Pai BS et al	2010	INDIA	5.09	10.37
8.	Singh. R et al	2011	INDIA	4.88	11.12
9.	Patil DK et al	2014	INDIA	Left: 4.33 Right:4.29	Left: 10.54 Right:10.62
10.	Garg S et al	2019	INDIA	Left: 5.71±1.22 Right:5.18±1.28	Left: 10.38 ±1.26 Right:10.16±1.28
11.	Present study	2023	INDIA	Right 4.2420 ±_1.044 Left 4.2473 ±0.917	Right 10.8495 ±1.172 Left 10.8481 ±_1.082

Conclusion

We have obtained comprehensive data on the dimensions of pedicles in typical thoracic vertebrae. The findings of our study are similar to the observations made by other Indian researchers. However, our measurements were lower when compared to those of Caucasians [8,21,20,16]. These differences could be attributed to the larger physique of the Caucasians.

These findings can be used for the synthesis of appropriate pedicular screws and prostheses for various surgical procedures and instrumentation specific to the Indian population. This will help the surgeons to perform more precise and safe surgical procedures.

Limitations

There are a few limitations of the study. We were unable to study the sex and age-related differences as we studied only the dry vertebral bones whose age and sex were undetermined. Secondly, doing screw fixation on cadavers could have provided more accurate knowledge on the size of screws needed and the sizes that will lead to a breach in the cortex of pedicles. However, we could not perform the same due to the lack of availability of sufficient cadavers.

References

1. Singh R, Srivastva SK, Chittode S, et al. Morphometric measurements of cadaveric thoracic spine in Indian population and its clinical applications. Asian Spine J. 2011;5 (1):20–34.
2. Standring S. The Back. In: Newell RL, editor. Gray's Anatomy: Anatomical Basis of Clinical Practice. 42nd. Edinburgh: Elsevier Churchill Living stone; 2008:829.
3. Chaynes P, Sol JC, Vaysse P, Becue J, Lagarrigue J. Vertebral pedicle anatomy in relation to pedicle screw fixation: a cadaver study. Surg Radiol Anat. 2001; 23:85–90.
4. Cinotti G, Gumina S, Ripani M, Postacchini F. Pedicle instrumentation

in the thoracic spine. A morphometric and cadaveric study for placement of screws. Spine. 1999; 24:114–119. [7].

5. Shetty, A.; Avadhani, R.; Mahesha, B. & Shantaram, M. Pedicle morphometry: A radiological assessment using computerized tomographic (CT) scan. Int. J. Basic. Appl. Med. Sci., 1(1):23-5, 2011.
6. Suk SI, Kim WJ, Lee SM, Kim JH, Chung ER. Thoracic pedicle screw fixation in spinal deformities: are they really safe? Spine. 2001; 26:2049–2057.
7. Pai BS, Nirmala GS, Muralimohan S, Varsha SM. Morphometric analysis of the thoracic pedicle: an anatomic-radiological study. Neurol India. 2010; 58(2): 122–136.
8. Acharya S, Dorje T, Srivastava A: Lower dorsal and lumbar pedicle morphometry in Indian population: a study of four hundred fifty vertebrae. Spine. 2010 May 1,35:378384.
9. Chadha M, Balain B, Maini L, Dhaon BK: Pedicle morphology of the lower thoracic, lumbar, and S1 vertebrae: an Indian perspective. Spine. 2003 Apr; 15:744-9.
10. Nojiri K, Matsumoto M, Chiba K, Toyama Y: Morphometric analysis of the thoracic and lumbar spine in Japanese on the use of pedicle screws. Surg Radiol Anat SRA. 2005 Apr, 27:123-8.
11. Kim, N. H.; Lee, H. M., Chung, I. H.; Kim, H. J. & Kim, S. J. Morphometric Study of the pedicles of thoracic and lumbar vertebrae in Koreans. Spine (Phila Pa 1976). 19(12):1390-4, 1994.
12. Verma V, Santoshi J A, Jain V, et al. Thoracic Pedicle Morphometry of Dry Vertebral Columns in Relation to Trans-Pedicular Fixation: A Cross-Sectional Study from Central India. Cureus. May 16, 2020; 12(5).
13. Gokcen, H. B.; Erdogan, S.; Ozturk, S.; Gumussuyu, G.; Bayram, I. & Ozturk, C. Sagittal orientation and uniform entry for thoracic pedicle screw placement with free-hand technique: A retrospective study on 382 pedicle screws. Int. J. Surg., 51:83-8, 2018
14. Scoles PV, Linton AE, Latimer B, Levy ME, Digiovanni BF: Vertebral body and posterior element morphology: the normal spine in middle life. Spine. 1988 Oct; 13:1082-6.
15. West JL, Ogilvie JW, Bradford DS: Complications of the variable screw plate pedicle screw fixation. Spine. 1991 May; 16:576-9.
16. Puvanesarajah V, Liauw JA, Lo S-F, Lina IA, Witham TF: Techniques and accuracy of thoracolumbar pedicle screw placement. World J Orthop. 2014 Apr; 18:112-23.
17. Chaynes P, Sol JC, Vaysse P, Bécue J, Lagarrigue J: Vertebral pedicle anatomy in relation to pedicle screw fixation: a cadaver study. Surg Radiol Anat SRA. 2001; 23:85-90.
18. Kaur K, Singh R, Prasath V, Magu S, Tanwar M: Computed tomographic-based morphometric study of thoracic spine and its relevance to anaesthetic and spinal surgical procedures. J Clin Orthop Trauma. 2016 Jun; 7:101-8.
19. Pal GP, Routal RV: Transmission of weight through the lower thoracic and lumbar regions of the vertebral column in man. J Anat. 1987 Jun; 152:93-105.
20. Hou S, Hu R, Shi Y: Pedicle morphology of the lower thoracic and lumbar spine in a Chinese population. Spine. 1993 Oct 1; 18:1850-5.
21. Patil DK, Bhuiyan PS. A Morphometric Study of the Vertebral Body in Dry Human Typical Thoracic Vertebrae. International Journal of Anatomy Physiology and Biochemistry 2014; 1(1):24-28.
22. Zindrick MR, Knight GW, Sartori MJ, Carnevale TJ, Pat-wardhan AG, Lorenz MA. Pedicle morphology of the immature thoracolumbar spine. Spine (Phila Pa 1976). 2000; 25: 2726-35
23. McLain RF, Ferrara L, Kabins M. Pedicle morphometry in the upper thoracic spine: limits to safe screw

placement in older patients. Spine (Phila Pa 1976). 2002; 27:2467-71
24. Garg. S, Saha. S, Saxena. A. K, Aneja. P. morphometric analysis of typical thoracic vertebrae and its clinical relevance. int j anat res. 2020;8(1.3) :73 56-7359.
25. Tan SH, Teo EC, Chua HC. Quantitative three-dimensional anatomy of cervical, thoracic and lumbar vertebrae of Chinese Singaporeans. Eur Spine J. 2004; 13: 137-46
26. Panjabi MM, Takata K, Goel V et al. Thoracic human vertebrae: quantitative three-dimensional anatomy. Spine (Phila Pa 1976). 1991; 16: 888-90.
27. Berry JL, Moran JM, Berg WS et al. A morphometric study of human lumbar and selected thoracic vertebrae. Spine (Phila Pa 1976). 1987; 12: 362-7.
28. Datir SP, Mitra SR: Morphometric study of the thoracic vertebral pedicle in an Indian population. Spine (Phila Pa 1976). 2004; 29:1174-1181.