e-ISSN: 0975-1556, p-ISSN:2820-2643

Available online on www.ijpcr.com

International Journal of Pharmaceutical and Clinical Research 2023; 15(6); 285-291

Original Research Article

A Morphometric Study of the Glenoid Cavity in Dried Human Scapulae

Veena Nair[1], Reshmi R[2], Rajad R[3], Rani Raphael M[4]

[1]Assistant Professor, Department of Anatomy, Government TD Medical College, Alappuzha, Kerala, India

[2]Assistant Professor, Department of Anatomy, Government TD Medical College, Alappuzha, Kerala, India

[3]Associate Professor, Department of Anatomy, Government Medical College, Ernakulam, Kerala, India

[4]Associate Professor, Department of Anatomy, Government TD Medical College, Alappuzha, Kerala, India

Received: 10-04-2023 / Revised: 15-05-2023 / Accepted: 05-06-2023

Corresponding Author: Dr Rani Raphael M

Conflict of interest: Nil

Abstract

Knowledge regarding the morphometry of the glenoid fossa or glenoid cavity of scapula is of utmost importance while doing shoulder surgeries like total shoulder replacement. The morphometry of the glenoid fossa of the scapula can vary among different populations and obtaining data on the same for different populations is essential for designing and selecting the proper size of components used in such surgeries. The study was conducted on a sample of 70 scapulae obtained from the Department of Anatomy, Government T D Medical College, Alappuzha, Kerala. Parameters such as anteroposterior diameter 1 (AP 1), anteroposterior diameter 2 (AP 2), and supero inferior diameter (SI D) were measured by a digital Vernier caliper. Of the 70 scapulae studied, 34 were right and 36 were left. The mean SI D on the right side was found to be 33.20±3.31mm. The mean SI D on the left side was 32.86±2.78mm. The mean AP1 diameters were 23.21±2.35 and 23.19±2.36 mm respectively for the right and left sides. The mean AP2 diameters were 17.81 ±2.14 and 18.19 ±2.44 mm respectively for the right and left sides. 47 of the 70 scapulae studied had pear-shaped glenoid fossa. The next common shape was found to be an inverted comma (15 numbers) followed by an oval shape in the remaining 8 scapulae. The diameters of the glenoid fossa were found to be more or less similar to those obtained in previous Indian studies but showed marked differences from those obtained from the Egyptian population. In the case of different shapes of the glenoid fossa, in the present study, the pear shape was found in an increased frequency than what was recorded in previous studies.

Keywords: Glenoid Fossa, Glenoid Cavity, Morphometry, Scapula, Shoulder Joint, Glenohumeral Joint

Introduction

The scapula is a large, flat, triangular bone that lies on the posterolateral aspect of the chest wall, covering parts of the second to seventh ribs. It is one of the bones in the shoulder girdle. The lateral angle of the scapula is truncated and bears the glenoid

fossa for articulation with the head of the humerus. [1] The glenoid fossa represents the head of the scapula. It has a notch (glenoid notch) which affects its shape. The fossa has variable morphometry and knowing these will help in the better understanding of pathologies of shoulder joint like dislocation of the shoulder, dislocation with fracture of the glenoid or rotator cuff disease.

It is also important to know these measurements in shoulder surgeries, especially in total shoulder replacement (TSR) and reverse total shoulder replacement (RTSR) surgeries. In TSR, the damaged humeral head and glenoid fossa are replaced by artificial components and the success of the procedure mainly depends on the proper sizing and positioning of these components. Thus, the knowledge of the normal range of measurements of the glenoid fossa helps in the proper selection of prosthesis.

Evidence suggests that the race or ethnicity of a person may influence the morphometry of the glenoid fossa. A study done in 2016 by Hristo Ivanov Piponov et al found that Asians exhibited smaller glenoid AP diameters than African -Americans [2]. So it is important to measure and record the normal range of measurements in different populations. This study aimed to collect data on measurements of glenoid fossa in the Indian population and compare it with the data obtained from earlier studies.

Methodology

Study Setting

The study was conducted on a sample of 70 scapulae (34 right and 36 left) obtained from the Department of Anatomy, Government T D Medical College, Alappuzha, Kerala.

Method of Measurement

The following measurements were taken on all scapulae using a digital vernier caliper (DVC).

1. The supero inferior diameter (SI D) was recorded as the maximum distance from the inferior most point on the glenoid margin to the most prominent point of the supraglenoid tubercle, taken as the distance between points A and B as shown in Figure 1.
2. The two anteroposterior diameters of the glenoid cavities taken are the maximum anteroposterior diameter below the glenoid notch (AP1) and the anteroposterior diameter at the midpoint of the upper half of the fossa, above the glenoid notch (AP2). Both were measured using a digital Vernier caliper as the distance between C and D for AP1 and E and F for AP2, as shown in Figure 1.
3. The shape of the glenoid fossae was noted. Based on the presence or absence of the glenoid notch the fossa was classified into three morphological types; pear-shaped, inverted comma-shaped and oval–shaped. (Figure 2).

Inclusion and Exclusion criteria

Only intact adult scapulae were taken for study. Scapulae with any anatomical deformities or damages were excluded.



Figure 1: Photograph showing various points taken on glenoid fossa to take measurements.

Pear shaped **Inverted comma shaped** **Oval shaped**

Figure 2: photographs showing various shapes of glenoid fossa

Statistical analysis: Statistical analysis was done using SPSS v26.0.

Ethical Clearance

Institutional ethics committee clearance was obtained before the start of the study from the Institutional Ethics Committee, Govt. T.D Medical College, Alappuzha.

Results

Of the 70 scapulae studied, 34 were right and 36 were left. The following results were obtained. The mean SI D on the right side was found to be 33.20±3.31mm. The range was 28.14 mm-39.63 mm. The mean SI D on the left side was 32.86±2.78mm. The range was 27.33 mm-39.22 mm.

The mean AP1 diameters were 23.21±2.35 and 23.19±2.36 mm respectively for the right and left sides. The mean AP2 diameters were 17.81 ±2.14 and 18.19 ±2.44 mm respectively for the right and left sides. The range of AP1 and AP 2 diameters on the right side were 18.55-27.31 and 13.58-21.27 mm respectively. The range of AP1 and AP 2 diameters on the left side were 18.14-28.68 and 14.27-25.39 mm respectively.

47 of the 70 scapulae studied had pear-shaped glenoid fossa. The next common shape was found to be an inverted comma (15 numbers) followed by an oval shape in the remaining 8 scapulae.

Table 1: The SI D and AP1 and AP2 values obtained in the present study in mm

Side		SI D (mm)	AP1 (mm)	AP2 (mm)
Right	**N**	**34**	**34**	**34**
	Mean	33.2006	23.2153	17.8188
	Median	33.1050	23.5650	17.5550
	Minimum	28.14	18.55	13.58
	Maximum	39.63	27.31	21.27
	Range	11.49	8.76	7.69
	Std.Deviation	3.31037	2.35039	2.14090
Left	**N**	**36**	**36**	**36**
	Mean	32.8675	23.1925	18.1964
	Median	33.1500	22.8050	18.1850
	Minimum	27.33	18.14	14.27
	Maximum	39.22	28.68	25.39
	Range	11.89	10.54	11.12
	Std.Deviation	2.78244	2.36118	2.44221

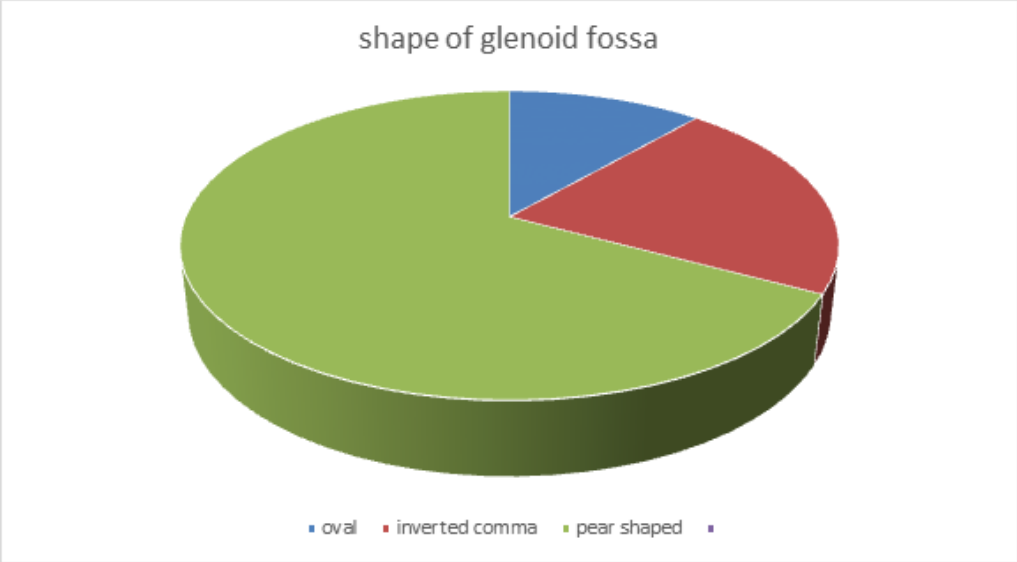

Figure 3: Showing the distribution of different shapes of glenoid fossa as obtained in the study

Discussion

In the present study, the mean SI D on the right side was found to be 33.20±3.31mm. The mean SI D on the left side was 32.86±2.78mm. In a study conducted by T Mamatha et al, the average Superior-Inferior diameter of the glenoid cavity on the right side was found to be 33.67 ± 2.82mm. On the left side, it was 33.92 ± 2.87mm [3]. In a study by Rajput et al, it was observed that the average Superior-Inferior diameter of the glenoid cavity was 34.76+3.00mm and 34.43+3.21mm on the right and left sides respectively [4]. All these values are comparable to those obtained in the present study. In another study done by Neeta Chhabra et al, the mean SI glenoid diameter observed was 38.78 mm with an SD of 3.03 mm. The SI diameter of the left glenoid varied from 31.46 mm to 47.7 mm with a mean of 39.03±3.18 mm while the right glenoid varied from 30.5 mm to 45.24 mm with a mean of 38.46±2.81 mm [5]. These measurements are higher than those obtained in the present study. In a study conducted by Gamal Hamed El-Sayed

Hassanein et al in Egyptian scapulae, the average supero - inferior (SI) diameter of the glenoid fossa on the right and left scapulae were 3.31 ± 0.39 (2.58 – 3.95) and 2.87 ± 0.41 (1.97 – 3.72) centimeters respectively [6]. In a study by Mahto AK et al, on the right side, the mean VGD which is taken similarly as SI D- was 3.62 cm. On the left side, the mean VGD was 3.32cm [7]. Another study conducted by El-Din WA et al in the Egyptian population found that the mean SI D on the right side was 38.88±2.63 and the left side was 39.01±2.49 mm which is higher than the values obtained in the present study [8].

In 2017, a study published by Akhtar et al found that the mean supero inferior glenoid diameter was 35.80±3.14mm [9]. In a study by Ankushrao SD et al, on scapulae in the Western Indian population, the mean SI diameter was obtained as 36.71±4.14 mm [10]. In a study by Mathews S et al, the Mean glenoid height was 36.6 mm ± 3.6 [11].

Table 2: comparison of SI D obtained from the present study and previous studies

Study	Mean SI D (right) mm	Mean SI D (left) mm
Present study	33.20±3.31	32.86±2.78
T Mamatha et al	33.67 ± 2.82	33.92 ± 2.87
Neeta Chhabra et al	38.46±2.81	39.03±3.18
El-Din WA et al	38.88±2.63	39.01±2.49

In the present study, the mean AP1 diameters were 23.21±2.35 and 23.19±2.36 mm respectively for the right and left sides. The mean AP2 diameters were 17.81 ±2.14 and 18.19 ±2.44 mm respectively for the right and left sides. In the study by T Mamatha et al, the average AP-1 diameter of the right glenoid was 23.35 ± 2.04mm and the average AP-1 diameter of the left glenoid was 23.02 ± 2.30mm. The mean for the AP-2 diameter of the right glenoid cavity was 16.27±2.01mm and for the left glenoid- 15.77±1.96mm [3]. Neeta Chhabra et al report the mean AP glenoid diameter 1 on the left, as 24.85±2.46 mm, and on the right side as 25.04±2.69 mm. AP 2 on the left side was noted as a mean and standard deviation of 18.6 mm and 2.07 mm respectively. On the right side, it was found as a mean and SD of 18.70± 2.22 mm. The results obtained in these studies were comparable to that of the present study. The study conducted by El-Din WA et al in the Egyptian population found that al the average AP-1 diameter of the right glenoid was 28.31±2.38 mm and the average AP-1 diameter of the left glenoid was 27.99±2.55 mm. The mean for the AP-2 diameter of the right glenoid cavity was 21.33±2.49 mm and for the left glenoid- 21.69±2.06mm [8]. These values were higher than that found in the present study.

In the present study, the most common shape of the glenoid fossa was pear shape (67.14%). The next common shape was found to be an inverted comma (21.42%). The glenoid fossa was found to be oval in 11.42%. In a study by Kusum Rajendra Gandhi et al, the most common shape observed was pear-shaped in 69 (56.09%) out of 123 scapulae. 43 (34.95%) were of inverted comma shape, 8 (6.5%) of oval shape and 3 (2.4%) were triangular [12]. According to Akthar et al, the most common shape of the glenoid cavity was a pear shape (50.44%) followed by an inverted comma shape (35.96%). The least common shape was oval (13.6%) [9].

In a study by Singh A et al, the most common shape of the glenoid fossa was a pear shape that is 44% followed by an oval shape in 34% and an inverted comma shape in 22% of scapulae [13]. In a study by R Singh et al, the most common shape of the glenoid cavity observed was a pear shape (50%), followed by an oval shape (29.65%). The least common shape was the

inverted comma shape (20.35%) [14]. In a study conducted by Thute PP et al in the central Indian population, the most common shape of the glenoid cavity

recorded was a pear shape (50.82%) followed by an inverted comma shape (36.89%). The least common shape was oval (12.30%). [15]

The present study is consistent with all these studies in that a pear shape is the most common shape of the glenoid fossa. But the incidence of pear shape obtained in the present study is considerably greater compared to the studies cited above.

Table 3: comparison of incidence of different shapes of glenoid fossa

Study	Pear Shape (%)	Inverted Comma (%)	Oval (%)	Others (%)
Present study	67.14	21.42	11.42	Nil
Kusum Rajendra Gandhi et al	56.09	34.95%)	6.5	2.4(triangular)
Akthar et al	50.44	35.96	13.6	Nil
Singh A et al	44	22	34	Nil
Thute PP et al	50.82	36.89	12.30	Nil

Conclusion

The knowledge of morphometry of the glenoid fossa is essential for the proper designing and selection of glenoid components in shoulder replacement surgeries. The study shows that there are significant differences in the measurements and shapes of glenoid fossa in different populations. In the present study, the pear shape was found in an increased frequency than what was recorded in previous studies. The diameters were more or less the same in the different Indian populations but showed marked differences from that of the Egyptian population.

Limitations

The study was conducted on dried human scapulae without determining the gender and age, hence the parameters were not correlated with gender and age. A limited number of scapulae are taken in the present study. Further studies on a larger sample size of dried human scapulae and of radiological images are recommended.

References

1. Standring S. Shoulder girdle and arm. Gray's Anatomy: Anatomical Basis of Clinical Practice. 41st. Elsevier Churchill Livingstone; 2016:802-803
2. Piponov HI, Savin D, Shah N, Esposito D, Schwartz B, Moretti V, Goldberg B. Glenoid version and size: does gender, ethnicity, or body size play a role? Int Orthop. 2016 Nov;40 (11):2347-2353.
3. Mamatha T, Pai SR, Murlimanju BV, Kalthur SG, Pai MM, Kumar B. Morphometry of Glenoid Cavity. Online J Health Allied Scs. 2011;10 (3):7
4. Rajput H. B., Vyas K. K., & Shroff B. D. A study of morphological patterns of glenoid cavity of scapula. National Journal of Medical Research, 2012; 2(04), 504–507.
5. Neeta Chhabra, Suraj Prakash, B K Mishra. An anatomical study of glenoid cavity: its importance in shoulder prosthesis. Int J Anat Res 2015; 3(3):1419-1424.
6. Gamal Hamed El-Sayed Hassanein. Morphometry of glenoid fossa in adult Egyptian scapulae. Int J Anat Res 2015; 3(2):1138-1142.
7. Mahto AK, Omar S. Dimensions of Glenoid Fossa of Scapula: Implications in the Biomechanics of an Implant Design. Int J Sci Stud. 2015;3(4):146-148.

8. El-Din WA, Ali MH. A Morphometric Study of the Patterns and Variations of the Acromion and Glenoid Cavity of the Scapulae in Egyptian Population. J Clin Diagn Res. 2015 Aug;9(8): AC08-11.
9. Akhtar M. J., Kumar B., Fatima N., & Kumar V. Morphometric analysis of glenoid cavity of dry scapulae and its role in shoulder prosthesis. International Journal of Research in Medical Sciences, 2017; 4(7): 2770–2776.
10. Ankushrao SD, Dombe DD. Morphological and Morphometrical study of scapulae in Western Indian Population. Ind J Clin Anat Physiol. 2017;4(3):298-303.
11. Mathews S, Burkhard M, Serrano N, Link K, Häusler M, Frater N, Franke I, Bischofberger H, Buck FM, Gascho D, Thali M, Serowy S, Müller-Gerbl M, Harper G, Qureshi F, Böni T, Bloch HR, Ullrich O, Rühli FJ, Eppler E. Glenoid morphology in light of anatomical and reverse total shoulder arthroplasty: a dissection- and 3D-CT-based study in male and female body donors. BMC Musculoskeletal Disord. 2017 Jan 10;18(1):9.
12. Kusum Rajendra Gandhi, Virendra Kumar Verma, Siddiqui Abu Ubbaida, Sonali Sachin Satpute (2015). The Glenoid Cavity: its morphology and clinical significance. Int. J. Curr. Res. Med. Sci. 1(6): 1–5.
13. Singh A, Singh A, Agarwal P, Gupta R. A morphological and morphometric study of glenoid fossa of scapula and its implication in shoulder arthroplasty. Int J Anat Radiol Surg. 2019;8(3):6-9.
14. Singh R. Surgical Anatomy of the Glenoid Cavity and Its Use in Shoulder Arthroplasty among the North Indian Population. Cureus. 2020 Dec 6;12 (12): e11940.
15. Thute PP, Keche HA, Fulmali DG. Morphometric study of glenoid cavity of human scapula in central India. J Evolution Med Dent Sci. 2020;9(33): 2340-2344.