e-ISSN: 0975-1556, p-ISSN:2820-2643

Available online on www.ijpcr.com

International Journal of Pharmaceutical and Clinical Research 2023; 15(6); 670-683

Original Research Article

Study of Histopathological Findings in Non-Infectious Erythematous Papulosquamous Lesions of the Skin

Talari Radhamadhavi[1], Hymavathi Bathina[2]

[1]Asst Professor, Department of Pathology, Mamata Medical College, Khammam, Telangana-507002

[2]Senior Resident, Department of Pathology, Mamata Medical College, Khammam, Telangana-507002

Received: 20-03-2023 / Revised: 11-04-2023 / Accepted: 30-05-2023

Corresponding author: Dr. Talari Radhamadhavi

Conflict of interest: Nil

Abstract

Background: Erythematous papulosquamous lesions are known to be of high frequency. It is reasonable to consider them in a group because all of them show similar morphological characteristics. Specific histopathological diagnosis isimportant to distinguish these lesions as the treatment and prognosis varies significantly.

Aims: To study the histopathological findings in noninfectious erythematous, papulosquamous lesions of the skin.

Materials and Methods: A cross sectional descriptive study conducted from August 2014 to July 2016. Biopsy of clinically diagnosed/suspected cases of noninfectious erythematous papulosquamous skin diseases were performed in the Department of Dermatology and were sent to the Department of Pathology for histopathological examination.

Results: A total of 100 cases were studied. Lichen planus was the most common disease (50%) followed by Psoriasis (30%), Pityriasis lichenoides (8%), Pityriasis rubra pilaris (4%), Pityriasis rosea (3%), Parapsoriasis (2%), Lichen striatus (2%), Lichen nitidus (1%). Lesions occurred in all age groups but were common in young and middle aged individuals. Males were commonly affected except in Lichen planus and Pityriasis rubra pilaris. 25 cases had 2 or more differential diagnosis clinically and definitive diagnosis was given by histopathological examination.

Conclusion: The contribution of histopathology to the final diagnosis was significant. Skin biopsy is thus valuable in daily dermatology practice.

Keywords: Erythematous Papulosquamous Lesions, Haematoxylin And Eosin, Lichen Planus, Psoriasis, Stratum Corneum, Pityriasis, Lichenoides Chronica.

Introduction

Erythematous papulosquamous lesions are known to be of high frequency. It is reasonable to consider them in a group because all of them show similar morphological characteristics.[1] All were characterized by scaling papules which may lead to confusion. Specific histopathological diagnosis is important to distinguish these lesions as the treatment and prognosis varies significantly.[2] Histopathologists should be provided with detailed clinical history because of the overlapping histopathological features of different clinical conditions.

This group includes skin diseases like Psoriasis, Lichen planus, Pityriasis rosea,

Pityriasis rubra pilaris, Prurigo nodularis, Lichen striatus, Lichen nitidus, Pityriasis lichenoides and many more.

The present study is an endeavour to analyze various histopathological patterns of non-infectious erythaematous, papulosquamous lesions of the skin based on the tissue reaction pattern.

Aim

Aim of the study is to identify the histopathological findings in noninfectious erythematous, papulosquamous lesions of the skin.

Materials and Methods

Study design: It is a cross sectional descriptive study with a minimal sample size of 87.

Source of data collection: The study includes clinically diagnosed / suspected and untreated cases of noninfectious erythematous papulosquamous lesions attending the Department of Dermatology.

Method of collection of data

Biopsy of clinically diagnosed/suspected cases of non-infectious erythematous papulosquamous lesions were performed in the Department of Dermatology and sent to the Department of Pathology in 10% neutral buffered formalin.

The specimen obtained were subjected for tissue processing after fixation. Tissue sections will be prepared from paraffin block and stained with Haematoxylin and Eosin (H&E) followed by microscopic examination.

Inclusion criteria: Cases with clinical features suggestive of non-infectious erythematous papulosquamous skin disorders are included.

Exclusion criteria: Skin disorders with infective etiology, skin lesions other than papulosquamous disorders and treated cases are excluded.

Results

Lichen planus consists 50 cases is the commonest group, followed by Psoriasis of 30 cases, Pityriasis lichenoides of 8 cases, Pityriasis rubra pilaris of 4 cases, Pityriasis rosea of 3 cases, Parapsoriasis of 2 cases, Lichen striatus of 2 cases, and Lichen nitidus of one case respectively.

Demographics: The age distribution pattern indicated a high prevalance in the 21-40 year age group with least number of cases in 1-10 years group. Lichen planus occurred in all age groups but was most commonly seen in young and middle aged. Psoriasis was most commonly seen in middle age group. Pityriasis lichenoides was seen in young and middle age groups. Pityriasis rubra pilaris was most commonly seen in children and young adults. Parapsoriasis, Lichen nitidus and Lichen striatus were seen in young adults and middle aged. Two cases of Pityriasis rosea were seen in middle age group and one case in elderly age group.

Males formed the larger group consists 52 cases. Male to female ratio was computed to be 1.08. High prevalence was observed in males for all diseases except Lichen planus and Pityriasis rubra pilaris. LP showed a female preponderance whereas PRP showed equal sex distribution.

Lichen Planus: Fifty out of 100 papulosquamous lesions were diagnosed as Lichen planus. Nineteen cases were noted in males and 31 cases in females. Most common age group affected is 21-40 years.

Table 1: Clinical presentation of Lichen planus

Clinical presentation	No. of cases	Percentage
Hyperpigmented lesion	23	46.0
Papule	36	72.0
Macule	3	6.0
Erythematous plaque	17	33.0
Flat topped papule / plaque	5	10.0
Patches	6	12.0
Verrucous nodule / plaque	3	6.0
Hyperkeratotic papule / plaque	1	2.0
Thin scales	2	4.0

Papules and hyperpigmented lesions were the commonest type of clinical presentations seen in LP in the present study.

Table 2: Histopathological changes in Lichen planus

Histopathological changes	No. of cases	Percentage
Epidermal changes		
Hyperkeratosis	24	48.0
Orthokeratosis	20	40.0
Focal parakeratosis	4	8.0
Irregular acanthosis with saw toothed rete ridges	23	46.0
Hypergranulosis	32	64.0
Vacuolar degeneration of basal cells	38	76.0
Max Joseph space	5	10.0
Civatte bodies	13	26.0
Dermal changes		
Band like dermal infiltrate	32	64.0
Diffuse dermal inflammatory infiltrate	15	30.0
Pigment incontinence	23	46.0
Perivascular inflammatory infiltrate	17	34.0
Focal thinning of epidermis	3	6.0

Most of the cases showed hyperkeratosis, orthokeratosis, irregular acanthosis with saw toothed rete ridges, hypergranulosis, vacuolar degeneration of basal cells, band like dermal infiltrate and pigment incontinence.

Psoriasis

Thirty cases of Psoriasis were studied. Nineteen cases were noted in males and 11 cases in females. Most common age group affected was 21-40 years.

Table 3: Clinical presentation of Psoriasis

Clinical presentation	No. of cases	Percentage
Hyperpigmented lesion	12	40.0
Papule	5	16.7
Scaly plaque	24	80.0
Scaly patches / macule	2	6.7
Pustules	1	3.3
Follicular papule	1	3.3
Hyperkeratotic papule / plaque	7	23.3
Thin scales	6	20.0

Scaly plaque and hyperpigmented lesions were the commonest type ofclinical presentations in Psoriasis.

Table 4: Histopathological changes in Psoriasis

Histopathological changes	No. of cases	Percentage
Epidermal changes		
Hyperkeratosis	13	43.3
Parakeratosis	22	73.3
Acanthosis	24	80.0
Suprapapillary thinning	22	73.3
Hypogranulosis	15	50.0
Spongioform pustule	6	20.0
Psoriasiform hyperplasia	18	60.0
Munro micro abscess	19	63.3
Dermal changes		
Papillary edema	6	20.0
Dilated capillaries	20	66.7
Perivascular inflammatory infiltrate	18	60.0
Dermal inflammation	6	20.0

Most prominent histological findings observed in epidermis were acanthosis, parakeratosis, suprapapillary thinning, psoriasiform hyperplasia and Munro micro abscess. Perivascular inflammatory infiltrate and dilated capillaries were the predominant dermal changes.

Pityriasis Lichenoides

Eight cases of Pityriasis lichenoides were studied which included two cases of Pityriasis lichenoides chronica and six cases of Pityriasis lichenoides et varioliformis acuta.

Table 5: Clinical presentation of Pityriasis lichenoides

Clinical presentation	No. of cases	Percentage
Hyperpigmented lesion	1	12.5
Papule	7	87.5
Erythematous plaque	3	37.5
Scaly patches	1	12.5
Verrucous nodule / plaque	1	12.5
Thin scales	3	37.5

Most common clinical presentation of Pityriasis lichenoides was papules anderythematous plaques. Thin scales and scaly patches were also seen.

Table 6: Histopathological changes in Pityriasis lichenoides

Histopathological changes	No. of cases	Percentage
Epidermal changes		
Spongiosis	7	87.5
Parakeratosis	5	62.5
Necrotic keratinocytes	4	50.0
Vacuolar alteration of basal layer	6	75.0
Lymphocyte exocytosis	3	37.5
Neutrophils in epidermis	3	37.5
Dermoepidermal junction - denselymphocytic infiltrate	3	37.5

Dermal changes		
Superficial perivascular infiltrate - lymphocytes extends into epidermis	8	100
Melanophages	1	12.5
Extravasated RBC	5	62.5

Most common histopathological features seen in epidermis were vacuolar alteration of basal layer, spongiosis, parakeratosis, and necrotic keratinocytes. Derrmis show perivascular inflammatory infiltrate in all cases and extravasated RBC in more than half of the cases. All 8 cases were diagnosed both clinically and histopathologically as Pityriaisis lichenoides.

Pityriasis Rubra Pilaris

Four cases of Pityriasis rubra pilaris were studied three of which were seen in males.

Table 7: Clinical presentation of Pityriasis rubra pilaris

Clinical presentation	No. of cases	Percentage
Hyperpigmented lesion	1	25.0
Hypopigmented lesion	1	25.0
Papule	3	75.0
Erythematous plaque	3	75.0
Hyperkeratotic papule / plaque	1	25.0

Most common clinical presentation was in the form of papules anderythematous plaque.

Table 8: Histopathological changes in Pityriasis rubra pilaris

Clinical presentation	No. of cases	Percentage
Epidermal changes		
Hyperkeratosis	2	50.0
Acanthosis	3	75.0
Thick suprapapillary plates	1	25.0
Alternating orthokeratosis and parakeratosis	2	50.0
Follicular plugging	1	25.0
Dermal changes		
Perivascular inflammation	4	100

Most common histopathological changes observed in epidermis were acanthosis, hyperkeratosis and alternating orthokeratosis and parakeratosis.

Dermis showed perivascular inflammation in all the cases. All four cases were diagnosed both clinically and histopathologically as Pityriaisis rubra pilaris. Two cases had PRP as one of the differential diagnosis. Other differential diagnosis provided were Erythroderma varioliformis, Pityriasis rotunda, Photodermatitis and Lichen planus.

Pityriasis Rosea: Three cases of Pityriasis rosea were studied of which two cases were seen in males. All three cases presented with multiple well-defined patches over hands, trunk and neck.

Table 8: Histopathological changes in Pityriasis rosea

Histopathological changes	No. of cases	Percentage
Epidermal changes		
Hyperkeratosis	3	100
Focal parakeratosis	1	33.3

Mild to moderate acanthosis	1	33.3
Intraepidermal spongiosis	3	100
Encrusted neutrophils and red cells in stratum corneum	3	100
Necrotic keratinocytes	3	100
Dermal changes		
Superficial perivascular inflammatoryinfiltrate	3	100
Extravasated erythrocytes	1	33.3

Parapsoriasis: Two cases of parapsoriasis were studied. Both the cases were noted in males. Most common age group is 21-40 years.

Table 9: Clinical presentation of Parapsoriasis

Clinical presentation	No. of cases	Percentage
Hyperpigmented lesion	2	100
Scaly plaque	2	100
Scaly patches	2	100

Both the cases presented with multiple well defined hyperpigmented scaly plaques and patches over both upper limbs and abdomen.

Table 10: Histopathological changes in Parapsoriasis

Histopathological changes	No. of cases	Percentage
Epidermal changes		
Hyperkeratosis	1	50
Focal mounds of parakeratosis	2	100
Acanthosis	2	100
Spongiosis	2	100
Exocytosis of lymphocytes	2	100
Collection of plasma above stratum corneum	2	100
Dermal changes		
Superficial perivascular inflammatory infiltrate	2	100
Edema of papillary dermis	1	50
Dilatation of blood vessels	1	50

Most common histopathologic changes in epidermis were hyperkeratosis, focal mounds of parakeratosis, acanthosis, spongiosis, exocytosis of lymphocytes, and collection of plasma above stratum corneum. Dermal changes noted were superficial perivascular inflammatory infiltrate, edema of papillary dermis and dilatation of blood vessels. Both the cases were diagnosed clinically and histologically as Parapsoriasis. Common differential diagnosis was Pityriasis versicolor.

Lichen Striatus: Two cases of Lichen striatus were studied. Both the cases were noted in females. Most common age group was 10-30 years. Multiple erythematous scaly plaques were seen in one case. Other case presented with well-defined multiple hypopigmented patches.

Table 11: Histopathological changes in Lichen striatus

Histopathological changes	No. of cases	Percentage
Epidermal changes		
Mild acanthosis	1	50.0
Spongiosis with exocytosis	1	50.0

Focal parakeratosis	2	100
Vacuolar alteration of basal layer	1	50.0
Necrotic keratinocytes	1	50.0
Dermal changes		
Perivascular chronic inflammatory infiltrate	2	100
Perifollicular inflammatory infiltrate	1	50.0
Pigment incontinence	1	50.0

Both the cases were diagnosed clinically and histologically as Lichen striatus. Differential diagnosis provided were adult blaschkitis, Lichen planus and early vitiligo.

Lichen Nitidus: Only one case of Lichen nitidus was encountered in a 13 years old male. It presented as multiple discrete skin coloured papules in groups over the trunk, upper and lower limbs. Koebners phenomenon was positive.

Table 12: Histopathological changes in Lichen Nitidus

Histopathological changes	**Present/ absent**
Epidermal changes	
Elongated rete (like claw clutching ball)	+
Epidermal flattening	+
Subepidermal clefting	+
Dermal changes	
Widened dermal papillae	+
Granuloma in upper dermis containing lymphocytes and histiocytes	+
Pigment incontinence	+

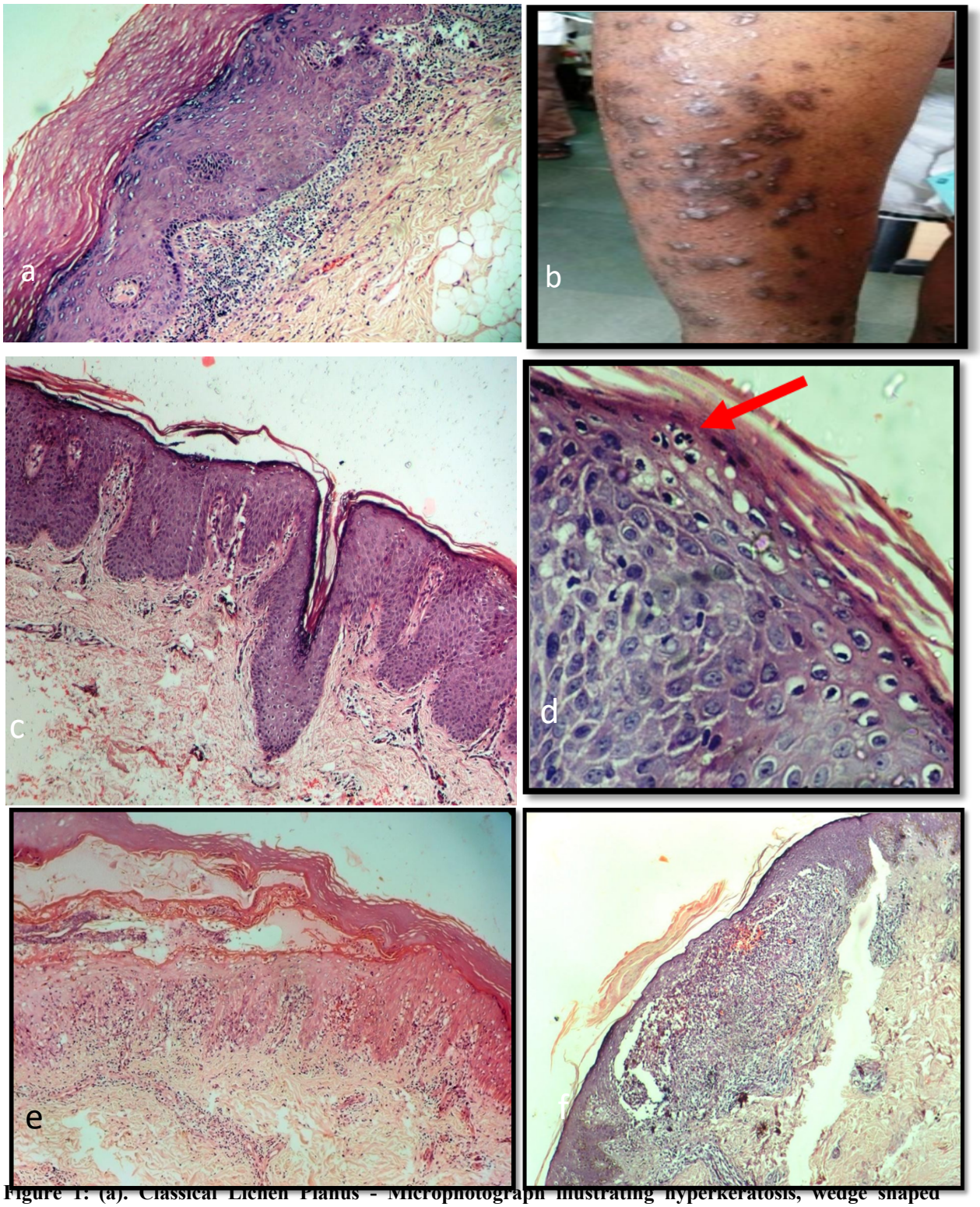

Figure 1: (a). Classical Lichen Planus - Microphotograph illustrating hyperkeratosis, wedge shaped hypergranulosis, vacuolar degeneration of basal cells and band like dermal infiltrate (H&E 10X). (b).Hypertrophic LP showing multiple hyperpigmented lesions over lower limbs. (c). Microphotograph illustrating acanthosis, parakeratosis, fused rete ridges, suprapapillary thinning, mild dermal edema with perivascular inflammatory infiltrate (H&E 10X). (d). Parakeratosis and Munro micro abscess (H&E 40X) €. Microphotograph illustrating parakeratosis spongiosis, neutrophils in keratin layer, dense lymphocytic infiltrate in dermoepidermal junction extravasated RBC (H&E 10X). (f). LICHEN NITIDUS- Microphotograph illustrating thinned out epidermis, subepidermal cleft, widened dermal papillae, and elongated rete ridges laterally – claw clutching a ball appearance (H&E 10X).

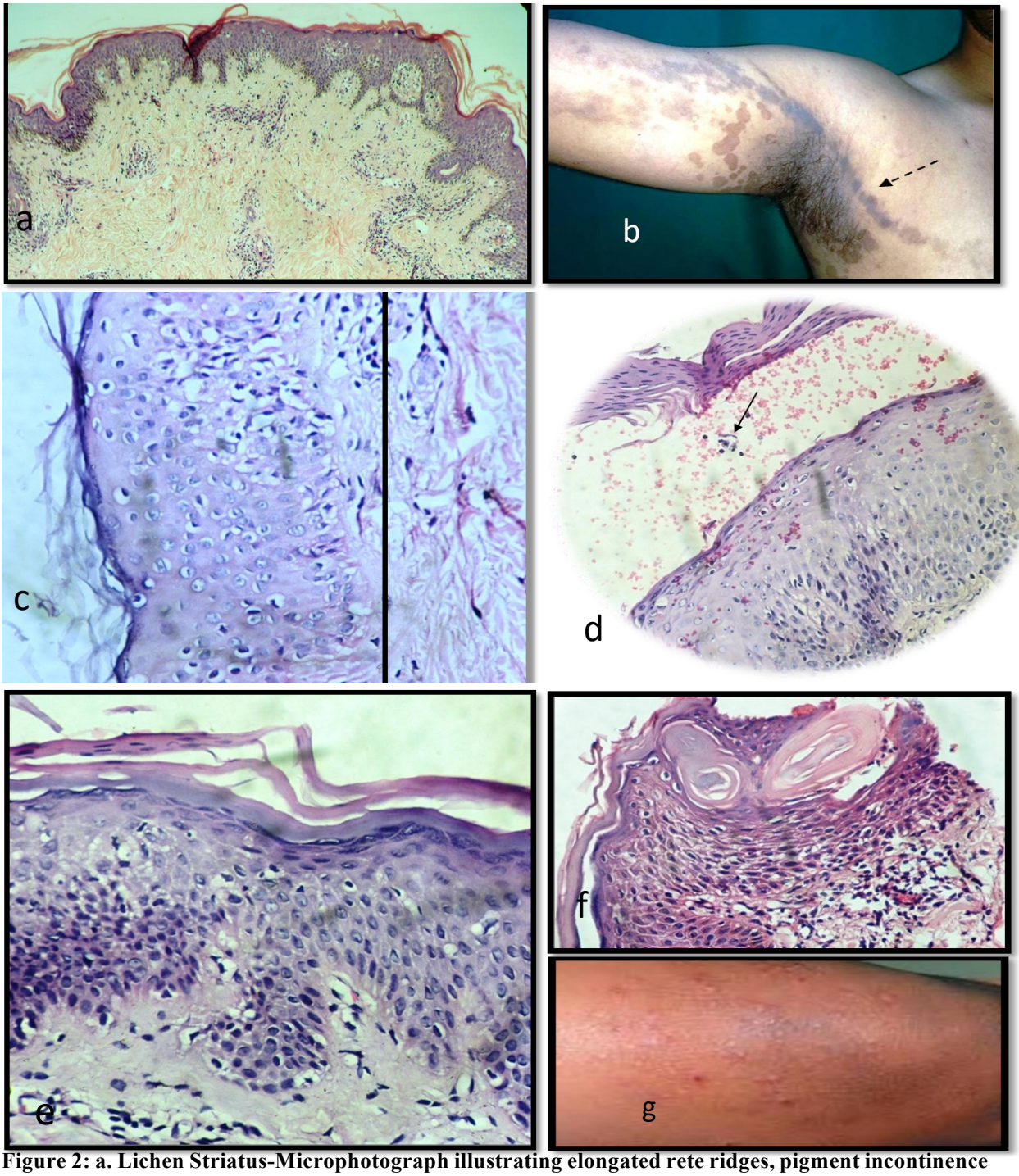

Figure 2: a. Lichen Striatus-Microphotograph illustrating elongated rete ridges, pigment incontinence and perifollicular inflammatory infiltrate (H&E 10X). b. Linear erythematous plaque and patches extending from trunk to arm. c. Parapsoriasis-Microphotograph illustrating spongiosis and perivascular inflammatory infiltrate (H&E 40X). d.Pityriasis ROSEA-Microphotograph illustrating hyperkeratosis, spongiosis, neutrophils and RBC in stratum corneum marked by arrow (H&E 10X).e. Pityriasis Rubra Pilaris-Microphotograph illustrating mild acanthosis, alternating orthokeratosis and parakeratosis (H&E 40X).f. Microphotograph illustrating follicular plugging and perivascular inflammatory infiltrate (H&E 10X). g.Multiple Papules over lower limbs.

Discussion

Papulosquamous skin disorders are characterized by scaly papules and plaques. These assume considerable importance because of their frequency of occurrence. Younas and Haque studied 38 cases of papulosquamous diseases. Out of 38 cases, 25 were males and 13 females. Age ranged from 8 to 64 years with maximum patients presenting in the age group of 21-30 years.[3] Reddy R and Krishna N studied 80 cases of papulosquamous lesions of which 62 were males and 18 females. Psoriasis is higher with 34 cases (42.5%) followed by Lichen planus with 24 cases (30%).[1] Hosamane et al studied skin biopsies from 150 clinically diagnosed/suspected cases of non-infectious erythematous, papulosquamous lesions in 2016.[4]Males (67%) were more commonly affected with a male to female ratio of 2:1. The age distribution pattern revealed that the maximum cases (24.66%) were in the age range of >60 years and the least number (0.66%) were in the youngest age range of 0-10 years. The most frequently encountered lesion was Psoriasis (42 cases, 28%), followed by Lichen planus (19 cases, 12.66%). Biopsy was inconclusive in 4.66% of the cases (7 cases).[4] In the present study 100 cases of noninfectious erythematous papulosquamous lesions were included. Lichen planus (50 cases) was the commonest, followed by Psoriasis (30 cases), Pityriasis lichenoides (8 cases), Pityriasis rubra pilaris (4 cases), Pityriasis rosea (3 cases), Parapsoriasis (2 cases), Lichen striatus (2 cases) and Lichen nitidus (1 case). The age distribution pattern indicated a high prevalance in the 21-40 year age group with least distribution of cases in 1-10 years group. In the present study slight male predominance with a male to female ratio of 1.08 was observed. High prevalence was observed in males for all diseases except Lichen planus and Pityriasis rubra pilaris. LP showed a female preponderance whereas PRP showed equal male to female ratio.

Lichen Planus

Fifty cases out of hundred cases studied were Lichen planus. Most common site involved was lower limbs followed by upper limbs and rest of the body. Most common clinical presentation was papules and hyper pigmented lesions. While atrophic LP showed hypopigmented lesions, pigmented LP showed hyperpigmented lesions. Fluid filled lesions were seen in bullous LP. The most common age group in the present study is 21 – 40 years, which was consistent with other studies. The youngest patient was eight years of age and the oldest patient was 80 years old. Eventhough Gorouhi et al found that there was no evidence of sexual predilection, there have been reports of slight female predominance up to a ratio of 2:1.5 Male predominance was noted in studies by Rajasekhar et al and Rahnama et al. But In the present study, Lichen planus was reported more commonly in females which showed consistency with sex incidence of Kumar et al[6], Parihar et al[7], and Chichani et al.[8] Fitzpatrick mentioned basal epidermal keratinocytes damage and lichenoid interface lymphocyte reaction as the two major pathologic findings of Lichen planus.[9] In the present study most common histopathological findings noted were vacuolar degeneration of basal cells in 38 cases (76%), hypergranulosis and band like inflammatory infiltrate in 32 cases (64%) which were comparable to the results of studies by Parihar et al, Reddy et al and Hosamane et al. Vacuolar change (liquefaction degeneration) is often an integral part of the basal damage in the lichenoid reaction. Sometimes it is more prominent than the cell death. It results from intracellular vacuole formation and edema, as well as from separation of the lamina densa from the plasma membrane of the basal cells. Pigmented LP showed scattered melanophages and pigment incontinence in papillary dermis. Bullous LP showed large space separating epidermis and

dermis. Hypertrophic LP showed mild papillomatosis. Lichen planopilaris showed follicular plugging, interfollicular epidermal atrophy. In the present study, 34 out of 50 cases were classical LP, which suggests that it is the most common subtype. 8 out of 50 cases were pigmented LP, which was the second common subtype. This finding was similar to study by Parihar et al, where 88 out of 145 were classic LP and 40 out of 145 were pigmented LP. Two cases each of actinic, bullous, atrophic LP and one case each of Lichen planopilaris, hypertrophic LP were noted. In the study by Reddy et al, hypertrophic lichen planus was the second commonest subtype. This can be attributed to low sample size of their study.

Psoriasis

Most common age group in the present study was 21 – 40 years, which is in agreement with other studies. Psoriasis is more common in males all over the world. Studies from different parts of the world including the present study showed a male preponderance. In the present study 63% (19/30 cases) were seen in males with male to female ratio being 1.72. In the present study 30 cases of Psoriasis were studied. The histopathological findings in the present study showed features consistent with psoriasis, but there is disparity between frequencies of these histologic findings when compared to other studies. Varying degrees of activity of the disease can explain this disparity. Most prominent histological findings observed were acanthosis in 24 cases (80.0%), parakeratosis in 22 cases (73.3%), suprapapillary thinning in 22 cases (73.3%). Perivascular inflammatory infiltrate and dilated capillaries were also noted in more than half of the cases.

Most common variant in the present study was Psoriasis vulgaris. Two cases of palmoplantar Psoriasis were seen. Other cases seen were guttate Psoriasis, spongiotic Psoriasis, and hypertrophic Psoriasis.

Pityriasis Lichenoides

Eight cases were diagnosed as pityriaisis lichenoides. Among the eight cases, six were diagnosed as PLEVA and two were diagnosed as PLC. Most common clinical presentation was papules, erythematous plaques followed by thin scales and scaly patches. One case showed both hyperpigmented and hypopigmented papules. Lesions were noted all over the body in 4 cases, predominantly over upper limbs and trunk. Overall incidence of pityriaisis lichenoides was more in males when compared to females. In the present study out of 6 cases of PLEVA, 4 were males and 2 were females. Although there was equal incidence reported in the literature of PLEVA in both sexes, in our study there was a male preponderance. Both cases of PLC were noted in males.

Perivascular infiltrate and basal cell degeneration were the histological hallmarks seen in this study. All the cases showed intense perivascular infiltrate and extension of lymphocytes into epidermis. These results are similar to the study by Nair PS. None of the cases in the present study had any atypical cells in the infiltrate. Other features noted were spongiosis, parakeratosis and necrotic keratinocytes.

Pityriasis Rubra Pilaris

Four cases of Pityriasis rubra pilaris were studied. Most common clinical presentation was papules and erythematous plaques. Predominant sites of involvement were upper limbs and trunk followed by all over the body. Most common age group in the present study was 11-20 years, which is in agreement with study by Chichani et al. The difference with other studies can be explained in view of low sample size in the present study. Male predominance was observed in the present study in conformity with the results of Chichani et al and Marrouche et al. [10] Four cases of

PRP were studied. Most common histopathological findings in the epidermis were acanthosis, alternating orthokeratosis and parakeratosis followed by epidermal hyperkeratosis, thick suprapapillary plates and follicular plugging. Dermis shows perivascular inflammation in all four cases. The histopathological findings in the present study are consistent with classical features of PRP.

Pityriasis Rosea

Three cases of Pityriasis rosea were studied. Most common site involved was trunk and upper limbs. All three cases presented with multiple well defined patches over hands, trunk and neck. The most common histopathological findings in the present study in epidermis were hyperkeratosis, intraepidermal spongiosis, encrusted neutrophils and red cells in stratum corneum, necrotic keratinocytes. Dermis showed superficial perivascular inflammation in all three cases and extravasated erythrocytes in one case.

Parapsoriasis

The peak incidence of Parapsoriasis has been reported to be 4th and 5th decades, with a few cases described in childhood.[11] In the present study, two cases of parapsoriasis were studied, one in 21-30 years and other in 31-40 years age group. In the present study both the cases of parapsoriasis were in males. All the studies were showing male predominance including the present study. Site of involvement in both the cases were upper limbs and trunk. Clinically both the cases showed scaly plaque and scaly patches which are hyperpigmented. Lesions were associated with itching. Both the cases were histopathologically diagnosed as small plaque parapsoriasis. Both of our cases showed histological features consistent with those described by Lever namely mild acanthosis, spongiosis, exocytosis of lymphocytes, focal mounds of parakeratosis and perivascular inflammation. The above mentioned classical features were seen in both the cases of parapsoriasis in the present study.

Lichen Striatus

Two cases of Lichen striatus were studied. Both were described in females, one in 13 years old and the other in 30 years old. Sites of involvement were back and thigh. One case presented with hypopigmented patches, other case with scaly plaques and erythematous plaques

Two cases of Lichen striatus were reported. Both the cases showed spongiosis with exocytosis, focal parakeratosis and perivascular chronic inflammatory infiltrate. One of the cases showed mild acanthosis, vacuolar alteration of basal layer, perifollicular inflammatory infiltrate, and pigment incontinence in superficial dermis. These findings are consistent with classical features of Lichen striatus.

Lichen Nitidus

This is a rare condition of unknown cause. There have been few studies worldwide about the clinical and histopathologic manifestations. Prevalence of Lichen nitidus is not established. [6] It commonly occurs in young adults and children, particularly in males.[9] Park JH et al studied 31 cases of LN for a period of 20 years. Age onset of skin lesions ranged from one year to 34 years and 17 cases (63%) were developed in the patients younger than 9 years old. Predilection sites were trunk, upper extremities and lower extremities. The ratio of male to female was 2.1:1. 12

In the present study one case of Lichen nitidus in a 13 year male was encountered. LN presented as multiple discrete skin coloured shiny papules in groups over trunk, upper and lower limbs with positive Koebners phenomenon.

Comparison of histopathological changes: The frequent histopathologic findings in study by Park JH were liquefaction degeneration of the basal

layer (100%), edema of the dermis within the areas of the infiltrate (100%), claw like rete ridges(96.8%), epidermal atrophy(87.1%), perivascular inflammatory cell infiltrate(87.1%) and absent or thinned granular layer(77.4%).12 In the present study histopathological features noted in epidermis were widened dermal papillae, thinned out epidermis over the widened papillae, subepidermal clefting. Dermis showed inflammatory cell infiltrate in lichenoid pattern comprising of lymphocytes, histiocytes, multinucleated giant cells in widened dermal papilla. Also noted was pigment incontinence. This case was diagnosed both clinically and histopathologically as Lichen nitidus. Differential diagnosis offered along with Lichen nitidus was Lichen spinulosus.

Conclusion

Noninfectious erythematous papulosquamous lesions are common clinical conditions in dermatology practice. Lichen planus was the commonest disease followed by Psoriasis. Some of the histopathological features overlap in lesions like Pityriasis rosea, Parapsoriasis and Lichen striatus. Some of the histological features were specific and characteristic, like Lichen planus, Psoriasis, Pityriasis rubra pilaris and PLEVA. The contribution of histopathology to the final diagnosis was significant. Skin biopsy is thus valuable in daily dermatology practice.

References

1. Reddy BR, Krishna NM. Histopathological spectrum of non-infectious erythematous, papulosquamous lesions. Asian Pac. J Health Sci 2014;1(4):28-34
2. Barman DD, Bhattacharyya P, Ray PS, Sarkar S, Sarkar R, Roy AK. Clinicopathological correlation of noninfectious erythematous papulosquamous cutaneous lesions in a tertiary care hospital. Indian Journal of Dermatopathology and Diagnostic Dermatology. 2018 Jul 1;5(2):101-5.
3. Younas M, Haque A. Spectrum of histopathological features in noninfectious erythaematous and papulosquamous diseases. International Journal of Pathology 2004;2(1):24-30.
4. Hosamane S, Pai M, Philipose TR, Nayarmoole U. Clinicopathological study of noninfectious erythaematous papulosquamous skin diseases. Journal of Clinical and Diagnostic Research 2016;10(6):19-22.
5. Gorouhi F, Davari P, Fazel N. Cutaneous and mucosal Lichen planus: a comprehensive review of clinical subtypes, risk factors, diagnosis, and prognosis. The Scientific World Journal 2014;1-22.
6. Kumar V, Nangia A, Logani K, Sharma RC. Lichen planus – A clinicohistopathological correlation. Indian J Dermatol Venerol 2000;66(4):193-5.
7. Parihar A, Sharma AS, Bhattacharya BSN, Singh UR. A clinicopathological study of cutaneous lichen planus. Journal of Dermatology & Dermatologic Surgery. 2015;19(1):21-26.
8. Chichani S, Negi SR, Kalla AR, Gaur S. Study of histopathology of papulosquamous lesion of skin a prospective and retrospective study. International Journal of Applied Research 2016;2(7):15-7.
9. Pittelkow MR, Mazen S, Daoud MS. Lichen planus. In: Wolff K, Goldsmith LA, Katz SI, Gilchrest BA, Paller AS, Leffell DJ, editors. Fitzpatrick's dermatology in general medicine. 7th ed. New York: McGraw Hill; 2008.P.244-54.
10. Marrouche N, Kurban M, Kibbi AG, Abbas O. Pityriasis rubra pilaris: clinicopathological study of 32 cases from Lebanon. International Journal of Dermatology 2014:53:434–39.
11. Gibson LE, Perry HO. Papulosquamous eruptions and exfoliative dermatitis. In: Moschella SL, Hurley HJ, editors. Dermatology.

3rd ed. Philadelphia: WB Saunders Company;1992; 607-51.
12. Park JH, Kye YC, Kim SN. A clinical and histopathologic study of Lichen nitidus. Korean J Dermatol 2003;41(7):857-68.