

Evaluation of Functional Outcome of Pre-Contoured Olecranon Locking Plate in Fractures of the OlecranonUpendra Kumar¹, Shiwendu Kumar Tiwari², Barun Golwara³, Rajeev Rajak⁴^{1,2}Senior Resident, Department of Orthopaedics, Govt. Medical College and Hospital, Bettiah, West Champaran, Bihar³Assistant Professor, Department of Orthopaedics, Govt. Medical College and Hospital, Bettiah, West Champaran, Bihar⁴Assistant Professor and Head of Department, Department of Orthopaedics, Govt. Medical College and Hospital, Bettiah, West Champaran, Bihar

Received: 28-05-2023 / Revised: 21-06-2023 / Accepted: 25-07-2023

Corresponding author: Dr. Shiwendu Kumar Tiwari

Conflict of interest: Nil

Abstract:**Background:** 'Pre-contoured Olecranon Locking Plate' provides rigid internal fixation allowing vigorous early mobilization at the elbow, especially in comminuted fractures of the olecranon. It shows an excellent rate of radiological union. Present study aims to evaluate the functional outcome of precontoured olecranon locking plate for fractures of the olecranon.**Methods:** This prospective study was done at Orthopedic emergency and the Out-Patient Department of Govt. Medical College and Hospital, Bettiah, Bihar from February 2019 to January 2020. The study was performed on thirty one skeletally mature patients with displaced fractures of the olecranon. Open reduction and internal fixation of displaced olecranon fracture of ulna with pre contoured olecranon locking plate. Patients were assessed by measuring the range of motion and Mayo Elbow Performance Score (MEPS) and index (MEPI). Serial radiographs were reviewed preoperatively for fracture classification and associated fractures, immediately postoperatively, and at the time of final review for adequacy and maintenance of reduction, evidence of union and arthritis.**Results:** At 1 year of follow up the mean flexion of elbow was 123.7⁰ (range 90-130⁰), while the mean extension was 5.64⁰ (range 0-30⁰). The MEPS index showed 1 patient having fair result, 6 patients having good results and 24 patients having excellent results. None of the patients had poor results. The mean MEPS were 90.65. All patients showed full radiological union.**Conclusions:** Pre-contoured olecranon locking plate to be more effective with a lower rate of symptomatic hardware and subsequent implant removal than tension band wiring.**Keywords:** Olecranon fracture; Pre contoured olecranon locking plate; Tension band wiring; Osteosynthesis.This is an Open Access article that uses a funding model which does not charge readers or their institutions for access and distributed under the terms of the Creative Commons Attribution License (<http://creativecommons.org/licenses/by/4.0>) and the Budapest Open Access Initiative (<http://www.budapestopenaccessinitiative.org/read>), which permit unrestricted use, distribution, and reproduction in any medium, provided original work is properly credited.**Introduction**

Olecranon fractures accounts for approximately 10% of fractures around the elbow and 2% of all fractures of the upper limb [1]. Olecranon fracture can be caused by direct trauma such as fall on the elbow or by indirect trauma such as falling on partially flexed elbow, with indirect forces by the triceps muscle avulsing the olecranon.[2] Olecranon fractures can occur at any age but are most common in the first three decades of life while fractures of the proximal ulna occur predominantly in older patients[2]. Nowadays, operative treatment is the management of choice for all displaced olecranon fractures. Fractures of the olecranon being intra-articular, and since the olecranon effectively functions as the fulcrum of the lever arm of the elbow, it is necessary to restore precise anatomical alignment and articular

congruity with rigid fixation, so that early movement can be encouraged.[5]

For long, tension band wiring was considered the gold standard for the treatment of minimally displaced and comminuted fractures of the olecranon with low levels of pain.[6] However in comminuted fractures with bone loss results are far from satisfactory such as initiating early movement and contraction of sigmoid notch. [9] Subchondral bone comminution opposite the tension-band construct may cause failure in compression.[10]

According to a biomechanical study, a significantly more stable fixation was achieved by plate fixation in comminuted osteotomies and hence allowing early mobilisation.[12] Moreover, locking compression plates provide superior mechanical

stability at the fracture line because they provide angular stability.[13] Further, locking screws have been shown to provide excellent stability even with unicortical purchase.[14]

Material and Methods

Thirty one skeletally mature patients with displaced fractures of the olecranon who presented to the orthopedic emergency and the Out-Patient Department of Govt. Medical College and Hospital, Bettiah, Bihar from February 2019 to January 2020 were included in the study. Undisplaced fractures of the olecranon, patients with local infection or soft tissue defects around the fracture site and patients with poor general condition were not included in our study.

The average age of the patients was 33.68 years (range, 22 to 56 years). Out of the 31 patients in the study, 21(68%) were male, and 10(32%) were female. The most common mode of injury was fall

from stairs/ height on their elbow or outstretched arm which amounted to 20 cases (64.5%). Road traffic accidents were responsible in 11(35.5%) cases. The dominant hand was involved in 19 out of the 31 patients. The Mayo Classification was used to classify the fracture pattern. Type I fractures are undisplaced and stable, type II are displaced and unstable fractures but with intact collateral ligaments preventing dislocation and in type III fractures the elbow joint is unstable. Type II and III fractures are further subdivided into A (non-comminuted) and B (comminuted). [22] Out of the 31 patients, 15(48.4%) had type IIA fractures while 13(42%) patients had type IIB fractures. Type III fractures were uncommon with 1(3.2%) patient having type IIIA and 2(6.4%) patients having type IIIB fractures. Patients having type I undisplaced fractures were not included in the study.

Mayo Classification

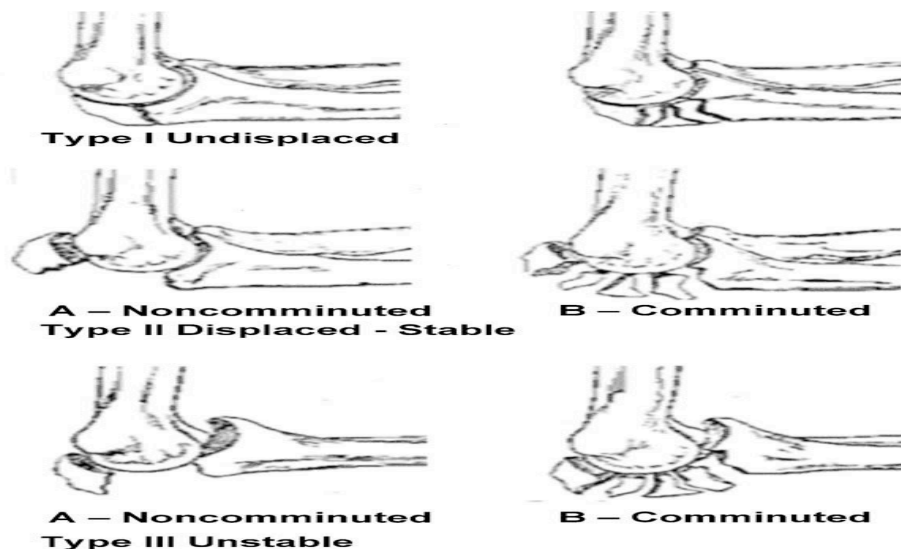


Figure 1:

The surgery was performed under regional anesthesia with sedation or general anesthesia. All patients were placed in lateral decubitus position. Under tourniquet control, a posterior midline incision was given with a slight lateral curve at the point of the elbow. The fracture was temporarily fixed with K-wires. Then, a longitudinal slit was made in the triceps tendon to allow for optimal positioning of the plate over the tip of the olecranon. The plate of appropriate size was placed in position and held with the help of clamps. The plate was then fixed with the help of bicortical locking/ non-locking screws in the distal fragment and unicortical screws in the proximal fragment. Finally, a 'home-run screw' was passed from the apex of the olecranon crossing the fracture towards the base of the coronoid. Additional K-wires were used for inter-fragmentary fixation in cases of

severe comminution. The stability of the fixation checked intra-operatively.

The elbow was splinted with an above-elbow plaster slab in the post-operative period. Guarded passive and assisted-active range of motion exercises were started on the 5th post-operative day. The plaster slab was removed at suture removal on the 14th post-operative day and range of motion exercises were continued. The patients were followed up serially at 3, 6, 12 weeks, 6 months and 1 year. All patients were followed up for a minimum of 1 year. Patients were assessed by measuring the range of motion and Mayo Elbow Performance Score (MEPS) and index (MEPI). The MEPS measures range of motion, pain, elbow stability and ability to do activities of daily living. Serial radiographs were reviewed preoperatively for fracture classification and associated

fractures, immediately postoperatively, and at the time of final review for adequacy and maintenance of reduction, evidence of union and arthritis.

Results

The mean duration of surgery was 64.5 minutes (range 45-90 min). It was found that with increasing grades of Mayo classification, the duration of surgery increased. At one year of follow up, the mean flexion at the elbow at final follow up of 1 year was 123.7° (range 90-130°), while the mean extension at the elbow at 1 year was 5.64° (range 0-30°). The MEPS index at one year of follow up showed 1(3.2%) patient having fair result, 6(19.4%) patients having good results and 24(77.4%) patients having excellent results. None of the patients had poor results. The mean MEPS at 1 year of final follow up was 90.65. A negative correlation was found between MEPS at 1 year and Mayo classification; that is higher grades of Mayo classification had lower MEPS scores compared and vice versa. A negative correlation was found between the day of surgery following injury and MEPS at 1 year; that is the later the day of surgery following injury, the lesser

the MEPS at 1 year. The mean MEPS of patients operated within 10 days was 93.2 compared the mean MEPS of patients operated after 10 days which was 82.5.

Reduction was maintained until union in all thirty one patients. The average time for radiological union ranged from 6 to 12 weeks with an average time of 10 weeks. Out of the 31 patients, 4(12.9%) patients had delayed union. Ultimately all patients showed full radiological union at follow up of 1 year and there was no case of non-union.

Out of the 31 patients, 1(3.2%) patient had superficial infection which was managed with wound debridement and intravenous antibiotics. The superficial infection healed uneventfully within a few days. 1(3.2%) of the patients had prominent implant causing skin impingement and may require implant removal at a later date. 1(3.2%) of the patients had chronic pain for over 6 months with restriction of motion at the elbow (ROM 30-90°). This patient had an open comminuted fracture of the olecranon and was operated 44 days after the injury.

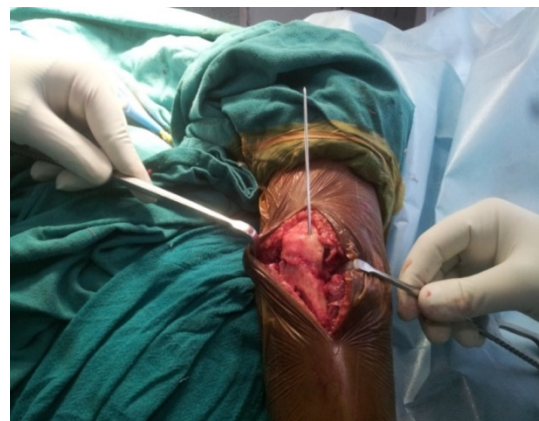
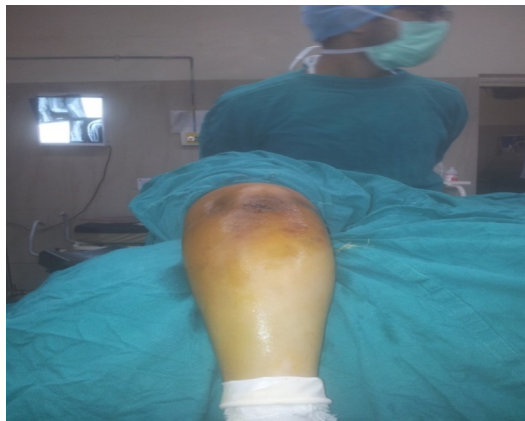
Figure 2: Position of the patient Fracture reduction and temporary fixation with k-wire

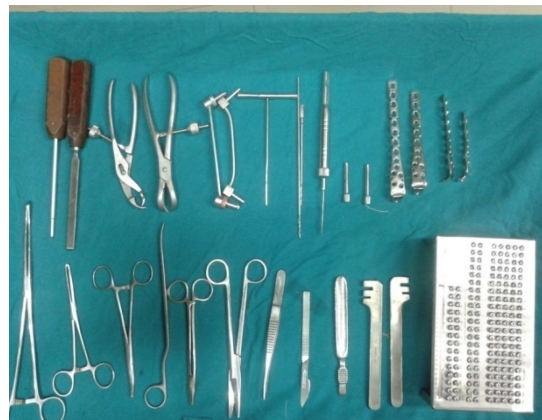
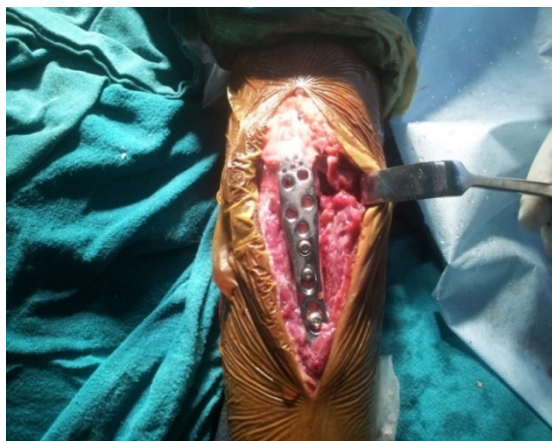
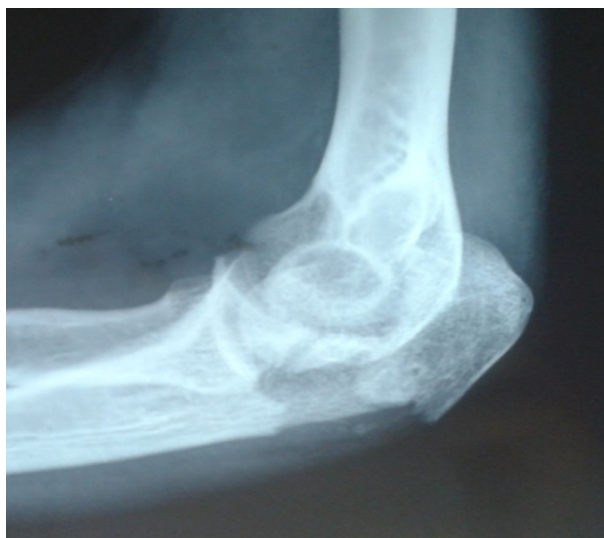Plate fixation

Instrumentations

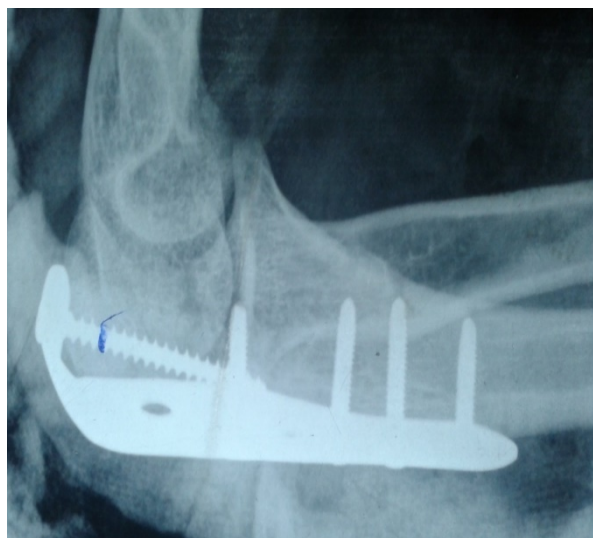
Radiological Photograph

Kumar et al.

Case I:

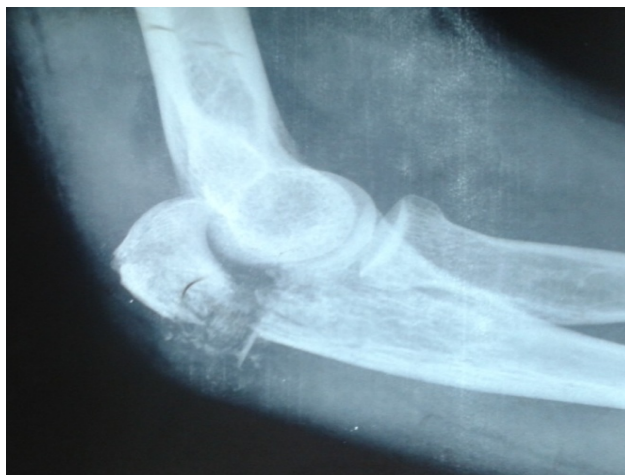

Post-operative X-Ray

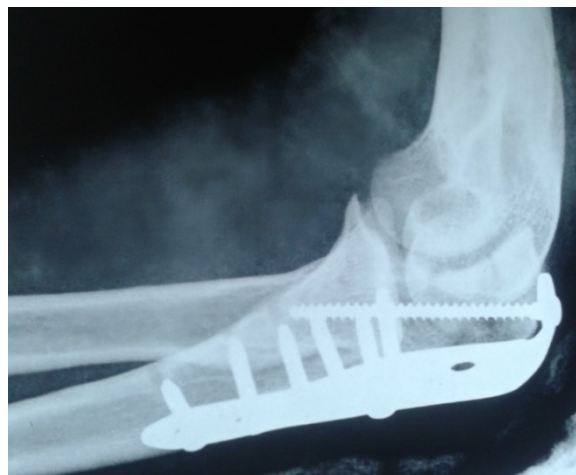

Pre-operative X-ray

Case-II:

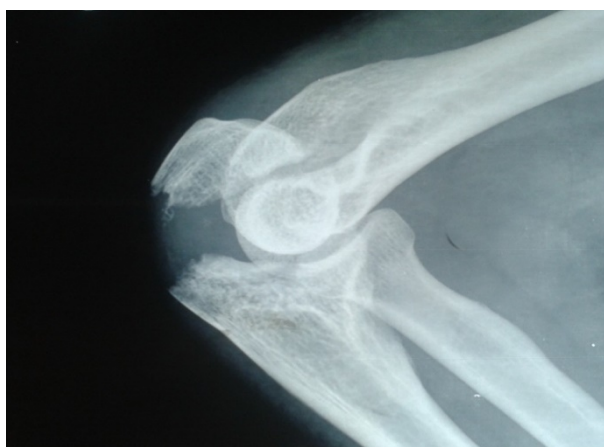

Pre-operative X-ray

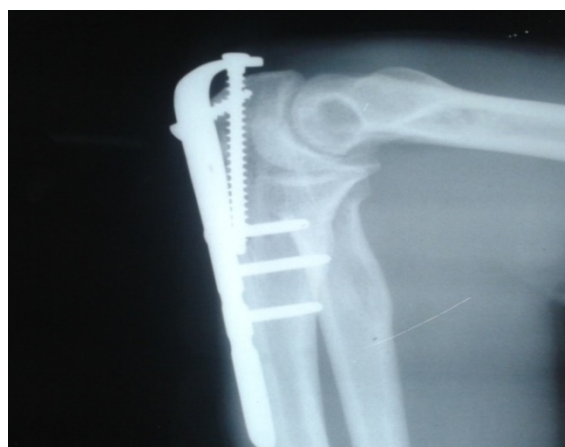

Post-operative X-Ray

Case-III:



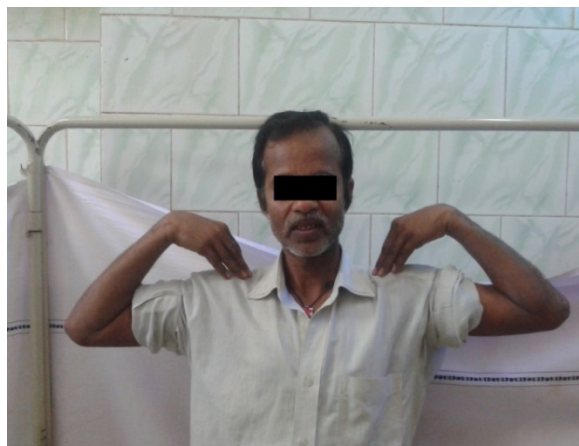Pre-operative X-ray



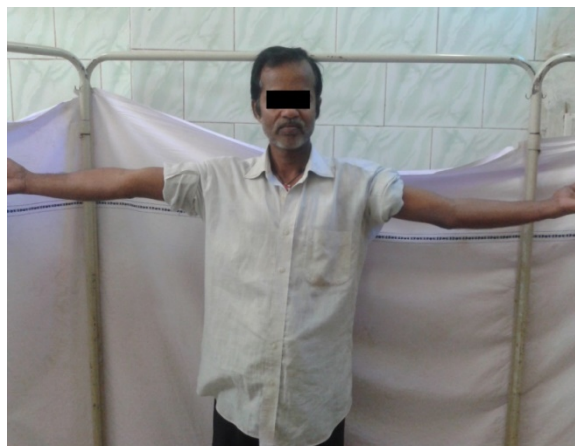Post-operative X-Ray

Clinical Photographs

Case I:



Elbow in Flexion



Elbow in Extension

Case-II:



Elbow in Flexion



Elbow in Extension

Case-III:



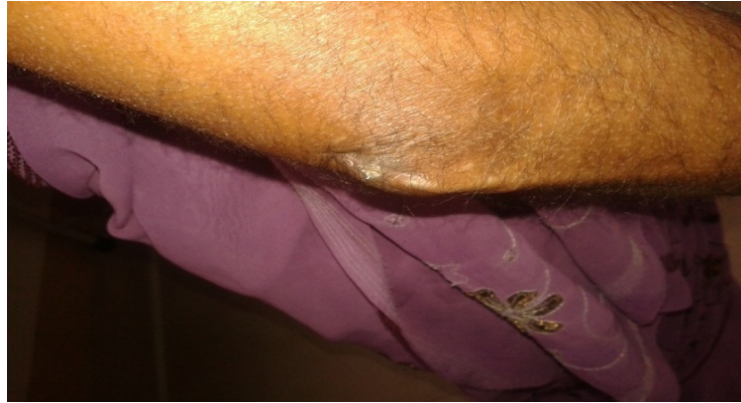Elbow in Flexion



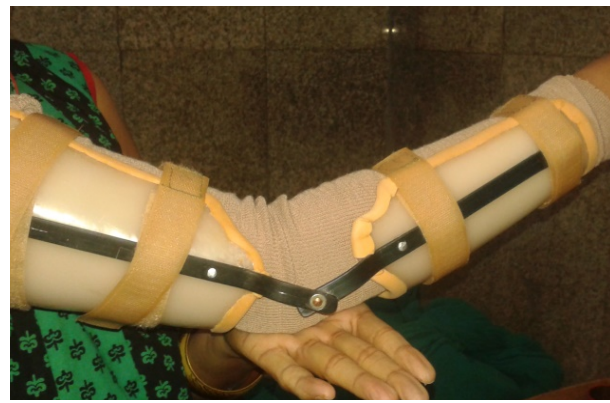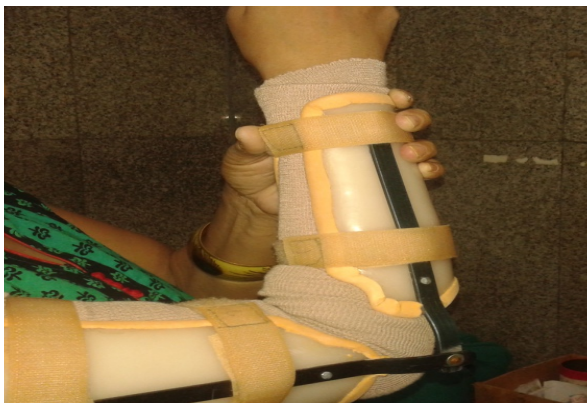Elbow in Extension

Complications

Kumar *et al.*



Hardware prominence



Restriction of movement

Discussion

The aim of operative treatment of fractures of the olecranon is restoration of the articular congruity of the ulno-humeral joint with rigid fixation, so that early mobilization of the elbow and rehabilitation can be initiated.[5] 31 patients with fractures of the olecranon were treated by open reduction and internal fixation with the 'Pre-contoured Olecranon Locking Plate'. Only closed fractures were included in the study.

All the 31 fractures in the study showed radiological union at follow up. The average time for radiological union was 10 weeks with a range from 6 to 12 weeks. At 12 weeks all fractures had united except in 4 patients. Ultimately all fractures united at 1 year of follow up. In a study by Meredith L. Anderson et al, of the 32 patients treated with congruent elbow plate fixation, 30 achieved radiographic union. The average time to radiological union was 11.6 weeks. In another Seibenlist S et al, in 15 patients with fractures of the olecranon who underwent locking plate osteosynthesis, the mean time to union was 11 weeks. [45] In a study by Donald Macko et al, in 20 patients treated with TBW, 60% of the fractures

healed by 12 weeks, 90% by 5 months and 95% by 7 months which was significantly later than our study.[30]

The average elbow range of motion at 1 year of follow up was from 5.640 (0-300) to 123.70 (90-1300). The average arc of motion was 118.060 at the end of 1 year of follow up. 26 of the 31 patients in our group had an extension deficit of 100 or lesser while only 5 patients had an extension deficit of more than 100. Similarly, only 5 patients had a flexion of lesser than 1200. In a study by Meredith L Anderson et al on 32 patients with olecranon fractures treated with Mayo Congruent Elbow Plating System, the mean range of motion at final follow up was 1200 which was similar to our study. The mean extension deficit was 13.60 in their study.[9]

In another study by Geert Buijze et al, the mean range of motion was 1230 with an extension deficit of 130.38 In another study by Ramazan Erden Erturer et al, the mean range of motion was 116°.7 In a study by Mary C Hume et al, comparing the results of fracture fixation by TBW and One-third Tubular Plating, the mean extension deficit in the TBW group was 100 and 70 in the plating

group.[38] The MEPS (Mayo Elbow Performance Score) was used because it emphasizes on the more important patient outcome factors such as pain, range of motion and whether the patient is able to do his activities of daily living. In our study, the mean MEPS at 1 year of follow up were 90.65. Of the 31 patients in our study, 24(77.4%) patients showed excellent results, 6(19.4%) patients showed good results and 1(3.2%) patient showed fair result. None of the patients had poor results at final follow up. In a study by Byron E Chalidis et al on treatment of olecranon fractures with TBW, 85.5% patients had good to excellent results compared to the 96.8% in our study, with 9.7% having fair result and 4.8% having poor results.[6]

In a study by Christopher S Bailey et al on the outcomes of plate fixation, 13(52%) patients had excellent results, 10(40%) good, (4%) fair and 1(4%) poor result.[34] Meredith L Anderson in his study reported an average MEPS of 89, with 92% having good or excellent results.[9] Seibenlist S in his study on pre-contoured locking plate osteosynthesis reported a mean MEPS of 97, with excellent results in 12 patients, good results in 2 patients and fair in 1 patient.[45] Hence, it appears that MEPS scores are better in patients who undergo plating than in patients who undergo TBW. This may be due to the more rigid fixation which permits more vigorous and early mobilization of the elbow.

Complications were observed in 3 of the 31 patients. One patient developed superficial infection which healed uneventfully with debridement and IV antibiotics. Symptomatic implant prominence was seen in 1 patient causing impingement of the overlying skin and is awaiting implant removal. Donald Macko in his study on the complications of TBW in olecranon fractures reported a high rate of hardware prominence in 16 of his 20 patients.[30] In a study by Byron E Chalidis on TBW in olecranon fractures, hardware removal was recorded in 82% of the patients.[6] Seibenlist S in his study on pre-contoured locking compression plates reported hardware prominence leading to implant removal in 1 of the 15 patients.[45] Meredith L Anderson in his study on 32 patients reported hardware prominence in 3 patients.[9] On the basis of the above mentioned results, it can be concluded that the Pre-contoured olecranon locking plate has a low rate of hardware prominence. Chronic pain was reported in 1 of our patients. This patient presented to us more than 1 month after the injury and was operated 44 days following the injury. The patient also had restriction of movement at the elbow with a mean range of 60° (30°-90°). In a study by Christopher S Bailey on 25 patients who underwent plate fixation, 3 patients reported of chronic pain at the elbow. [34] There were no other complications in our

study such as myositis ossificans, implant failure, ulnar neuropathy which have been reported in previous studies.

Conclusion

Thus, we can conclude that the 'Pre-contoured Olecranon Locking Plate' provides rigid internal fixation allowing vigorous early mobilization at the elbow, especially in comminuted fractures of the olecranon which is necessary to achieve a good and fully functional elbow. It shows an excellent rate of radiological union. There was no case of implant failure in our study, even in comminuted fractures, which can be attributed to the use of locking compression plates. There was a very minimal rate of complications in wound healing and due to implant prominence, in spite of the olecranon being a subcutaneous bone. We can conclude that, the 'Pre-contoured Olecranon Locking Plate' seems to be a viable alternative to other forms of fixation of olecranon fractures. We feel that it is a more versatile implant which can be used in all types of olecranon fractures with minimal complication rate.

References

1. Rommens PM, Kuchle R, Schnieder RU et al. Olecranon fracture in adults, factors influencing outcome. *Injury*. 2004, 35:1149-1157.
2. Ernest M Dalat. Fractures of the olecranon. Fracture Service of the Massachusetts General Hospital, 2004.
3. Duckworth AD, Clement ND, Atken SA et al. Epidemiology of fractures of the proximal ulna. *Injury*. 2012, March 43(3): 343-346.
4. Josselson PO, Johnell O, Gentz CF. Dislocations of the elbow and intraarticular fractures. *Clinical Orthopaedics*. 1989 Jun 246: 126-130.
5. M. Ikeda, Y. Fukushima, Y. Kobayashi, Y. Oka. Comminuted fractures of the olecranon. *Journal of Bone Joint Surgery [Br]*. 2001;83-B:805- 808.
6. Byron E Chalidis, Nick C Sachinis, Efthimios P Samoladas et al. Is tension band wiring technique the "gold standard" for the treatment of olecranon fractures? A long term functional outcome study. *Journal of Orthopaedic Surgery and Research*. 2008 Feb, 3: 9, 1.
7. Ramazan Erden Erturer, Cem Sever, Mehmet Mesut Sonmez et al. Results of open reduction and plate osteosynthesis comminuted fracture of the olecranon. *Journal of Shoulder Elbow Surgery*. 2011; 20: 449-454.
8. D.S. Newman, C. Mauffrey, S. Krikler et al. Olecranon Fractures. *Injury, Int. J. Care Injured*. 2009; 40: 575-581.
9. Meredith L Anderson, A Noelle Larson, Sheri M. Merten and Scott P. Steinmann. Congruent Elbow Plate Fixation of Olecranon Fractures.

- Journal of Orthopaedic Trauma. July 2007; 21(6):386-393
10. Bailey CS, MacDermid J, Patterson SD, King GJ. Outcome of plate fixation of olecranon fractures. *J Orthop Trauma*. 2001; 15:542-548.
 11. Boyer MI, Galatz LM, Borrelli J Jr, Axelrod TS, Ricci WM. Intra-articular fractures of the upper extremity: new concepts in surgical treatment. *Instr Course Lect*. 2003; 52:591-605.
 12. Fyfe IS, Mossad MM, Holdsworth BJ. Methods of fixation of olecranon fractures. An experimental mechanical study. *J Bone Joint Surg [Br]*. 1985; 67:367-72.
 13. Gardner MJ, Helfet DL, Lorch DG. Has locked plating completely replaced conventional plating? *Am J Orthop*. 2004; 33:439-46.
 14. Haidukewych GJ. Innovations in locking plate technology. *J Am Acad Orthop Surg*. 2004; 12:205-12.
 15. Wang A, Mara M, Hutchinson DT. The proximal ulna: an anatomic study with relevance to olecranon osteotomy and fracture fixation. *J Shoulder Elbow Surg*. 2003; 12(3):293-6.
 16. O. Ennis, D. Miller, C.P. Kelly. Fractures of the adult elbow. *Current Orthopaedics*. 2008; 22: 111-131.
 17. Woon Jae Yong, Jun Tan, Arnold Adikrishna, Hyun Joo Lee, Jin Woo Jung, Dong-Woo Cho, In-Ho Jeon. Morphometric analysis of the proximal ulna using three-dimensional computed tomography and computer-aided design: varus, dorsal, and torsion angulation. *Surg Radiol Anat*. 2007; 14:1260-3.
 18. Bucholz RW, Heckman JD, Court-Brown CM, Koval KJ, Tornetta III P, Wirth MA, editors. *Rockwood and Green's fractures in adults*. 6th Ed.
 19. Amis AA, Miller JH. The mechanism of elbow fractures: an investigation using impact tests in vitro. *Injury*. 1995; 26:163-8.
 20. Lavigne G, Baratz M. Fractures of the olecranon. *J Am Soc Surg Hand*. 2004; 4(2):94-102.
 21. Morrey BF. Current concepts in the treatment of fractures of the radial head, the olecranon, and the coronoid. *J Bone Joint Surg Am*. 1995; 77:316-27.
 22. Howard JL, Urist MR. Fracture-dislocation of the radius and ulna at the elbow joint. *Clinical Orthopaedics*. 1958; 12:276-278.
 23. McAusland WR. Treatment of olecranon fractures by longitudinal Screw or nail fixation. *Ann Surgery*. 1942; 116: 293.
 24. Adler SA, Fay GF, MacAusland WR. Treatment of olecranon fractures. Indications for excision of the olecranon fragment and repair of the triceps tendon. *J Trauma*. 1962 Nov; 2:597-602.
 25. Weber B and Vasey H. Osteosynthesis olecranon fracture. *Z Unfallt Med. Brufski*. 1963; 50: 90-96.
 26. Wesely MS, Barenfeld PA, Eisenstein AL. Use of a Zueler Hook plate for fixation of olecranon fractures. *Journal of Bone and Joint Surgery*. 1976; 88A: 859-863.
 27. Coughlin MJ, Stabaugh PB, Smith TK. Experience with McAtee Olecranon Device in Olecranon Fracture, *J of Bone and Joint Surgery*. 1979 61A: 385-388.
 28. Donald Macko and Robert M Szabo. Complications of TBW of Olecranon Fractures. *Journal of Bone and Joint Surgery*. Dec 1985; 67(9): 1396-1401.
 29. Johnson RP, Roetker A, Schwab JB. Olecranon fractures treated with AO screw and tension bands. *Orthopaedics*. 1986 Jan; 9(1):66-68.
 30. Hume MC, Wiss DA. Olecranon fractures. A clinical and radiographic comparison of tension band wiring and plate fixation. *Clin Orthop Relat Res*. 1992; 285:229-235.
 31. M. Ikeda, Y. Fukushima, Y. Kobayashi, Y. Oka. Comminuted fractures of the olecranon. Management by bone graft from the iliac crest and multiple tension band wiring. *J Bone Joint Surg [Br]*. 2001; 83-B: 805-8.
 32. Christopher S. Bailey, Joy MacDermid, Stuart D. Patterson and Graham J. W. King. Outcome of Plate Fixation of Olecranon Fractures. *Journal of Orthopaedic Trauma*. 2001; 15(8):542-548.
 33. Hak DJ, Golladay GJ. Treatment options of olecranon fractures. *Journal of the American Academy of Orthopaedic Surgeons*. 2000; July-Aug 8(4): 266-275.
 34. Geert Buijzeand Peter Kloen. Clinical Evaluation of Locking Compression Plate Fixation for Comminuted Olecranon Fractures. *J Bone Joint Surg Am*. 2009; 91:2416-20.
 35. Michael J. Gordon, Jeffrey E. Budoff, Ming Long Yeh, Zong-Ping Luo and Philip C. Noble. Comminuted olecranon fractures: A comparison of plating methods. *J Shoulder Elbow Surg*. 2006; 15:94-99.
 36. Joseph Izzian and George S. Athwal. An Off-Loading Triceps Suture for Augmentation of Plate Fixation in Comminuted Osteoporotic Fractures of the Olecranon. *J Orthop Trauma*. 2012; 26:59-61.
 37. Siebenlist S, Torsiglieri T, Kraus T, Burghardt RD et al. Anatomically Pre-shaped LCP olecranon plating is an effective fixation of comminuted fractures of the olecranon and proximal ulna. *Injury*. 2010 Dec; 41(12): 1306-1311.

38. Egol KA, Kubiak EN, Fulkerson E, Kummer FJ, Koval KJ. Biomechanics of locked plates and screws. *J Orthop Trauma*. 2004; 18:488–493.
39. Perren S. Point contact fixator: Part I. Scientific background, design and application. *Injury*. 1995; 22:1–10.
40. Geert A. Buijze, Leendert Blankevoort, Gabrielle J. M. Tuijthof, Inger N. Sierevelt, Peter Kloen. Biomechanical evaluation of fixation of comminuted olecranon fractures: one-third tubular versus locking compression plating. *Arch Orthop Trauma Surg*. 2010; 130:459–464.
41. Munoz Mahamud, Fernandez-Valencia JA and Riba J. Outcome of patients with plate osteosynthesis for severe olecranon fractures. *Journal of Orthopaedic Surgery*. 2010; 18(1): 80-84.
42. Wang YH, Tao R, Xu H et al. Mid-term outcomes of contoured plating for comminuted fractures of the olecranon. *Orthop Surg*. 2011 Aug; 3(3):176-80.
43. Evan Arginter, Mark Cohen, Andrew Eglseder, Scott Edwards. Clinical results of olecranon fractures treated with Multiplanar locked intramedullary nail. *Journal of Orthopaedic Trauma*. 2013; 27:140–144.
44. Liu QH1, Fu ZG, Zhou JL et al. Comparison of olecranon fracture fixation with CPS and TBW. *Journal of International Medical Research*. 2012; 40(3):1055-1066.
45. M.E. Cabanela, B.F. Morrey. Fractures of the proximal ulna and olecranon. B.F. The elbow and its disorders. WB Saunders, Philadelphia. 1993: 407–408.