

Paravertebral Block In Percutaneous Nephrolithotomy**Chetankumar Tikar^{1*}, Pradeep Jain², Sandesh Parab³, Priyank Kothari⁴**¹Senior Resident, Department of Urology, BYL Nair Hospital and TNMC Mumbai²Senior Resident, Department of Urology, BYL Nair Hospital and TNMC Mumbai³Assistant Professor, Department of Urology, BYL Nair Hospital and TNMC Mumbai⁴Assistant Professor, Department of Urology, BYL Nair Hospital and TNMC Mumbai

Received: 06-07-2023 Revised: 15-08-2023 / Accepted: 11-09-2023

Corresponding author: Dr Chetankumar Tikar

Conflict of interest: Nil

Abstract:

Paravertebral blocks (PVB) are in use to adequately manage pain arising from a variety of operations on the thorax, abdomen or pelvis. PVB is straightforward, efficacious in operations performed. This study was undertaken to evaluate how efficacious ultrasound-guided thoracic paravertebral block is when used in patients undergoing percutaneous nephrolithotomy (PCNL). In this study we have compared two groups of PCNL surgery comprising 125 patients each, one with TPVB and one without TPVB. TPVB is effective modality in controlling early postoperative pain after PCNL surgery. However, there is no effect in late postoperative pain control after PCNL surgery with TPVB.

Keywords: Percutaneous Nephrolithotomy, Paravertebral Blocks (PVB)

This is an Open Access article that uses a funding model which does not charge readers or their institutions for access and distributed under the terms of the Creative Commons Attribution License (<http://creativecommons.org/licenses/by/4.0>) and the Budapest Open Access Initiative (<http://www.budapestopenaccessinitiative.org/read>), which permit unrestricted use, distribution, and reproduction in any medium, provided original work is properly credited.

Introduction

PCNL (percutaneous nephrolithotomy) is a frequently employed, minimally invasive operative technique used to remove renal calculi [1]. The technique remains associated with significant demand for analgesic interventions post-surgically. The application of regional anaesthesia is known to possess the highest efficacy in managing pain following surgery of this sort [2]. There are a number of methods available which may potentially reduce postoperative pain associated with nephrostomy tube placement in PCNL, namely intercostal nervous blockade, epidural analgesia, peritubal infiltration of local anaesthetic and paravertebral blockade [3– 5]. Paravertebral blocks (PVB) are in use to adequately manage pain arising from a variety of operations on the thorax, abdomen or pelvis. PVB is straightforward, low risk and is efficacious in operations performed unilaterally. It rarely creates hypotension, urinary retention or nausea and vomiting following surgery [6]. PVB performed under ultrasonic guidance (PVB-US) targets the region of emergence of the spinal nerves through the foramina of the vertebrae. It blocks somatic and sympathetic fibres supplying several adjacent dermatomal segments both superior and inferior to where the injection is given [7]. Percutaneous nephrolithotomy (PCNL) has emerged as a highly effective and widely accepted approach for the treatment of complex and large renal stones. While PCNL offers numerous advantages, such as high stone clearance rates and minimal invasiveness,

postoperative pain management remains an important aspect to address for improved patient comfort and recovery. Post-operative pain after PCNL is due to dilatation of the renal capsule, the parenchymal tract and peritubal distressing of the nephrostomy tube. Traditionally, postoperative pain control in PCNL has been achieved using systemic analgesics, such as opioids. However, these medications are associated with various side effects and may not always provide optimal pain relief. In recent years, regional anesthesia techniques, such as paravertebral block, have gained attention as adjuncts to systemic analgesia for better pain control and reduced opioid consumption. The technique of combining PCNL with paravertebral block involves performing the block either preoperatively or intraoperatively, under ultrasound or fluoroscopic guidance. Thoracic paravertebral block has been shown to provide sufficient postoperative analgesia for a variety of thoracic and upper abdominal surgeries [8-13]. Percutaneous Nephrolithotomy can be safely performed under General Anesthesia and Neuraxial Anesthesia. However paravertebral block is used to provide effective postoperative analgesia after urological procedures. Thoracic paravertebral block is the technique of injecting local anesthetic alongside the thoracic vertebra close to where spinal nerve emerge from intervertebral foramen. This produces unilateral, segmental, somatic and sympathetic nerve block which is effective for postoperative pain control. We analyzed our

experience with TPVB in PCNL surgery and compared it with control group operated under General Anesthesia without TPVB.

Material and Methods

In this study we have compared two groups of PCNL surgery comprising 125 patients each, one with TPVB (Case) and one without TPVB (Control). The clinical data of the two group were analyzed. Patients scheduled to undergo PCNL surgery during two years were included in our study.

Patients who met the inclusion criteria were explained regarding the procedure and informed and written consent was obtained. The patients were randomized into two groups of 120 each, with one group receiving thoracic paravertebral block (Case) and one group which did not receive the block at the end of surgery (control).

Both groups received standard general anesthesia with propofol, atracurium and fentanyl and airway was secured with an appropriate-size ET tube. The patient was then turned into prone position and PCNL surgery was done. Intraoperatively both groups received injection paracetamol 1-gram IV. At the end of procedure, patients in group P received ultrasound guided thoracic paravertebral block at T9-T10 level.

With the patient still in prone position, the skin was cleaned with antiseptic solution and sterile drapes were applied. A high frequency (5-10 MHz) linear probe was selected in the ultrasound machine and

used to identify the superior costotransverse ligament and paravertebral space at the level of T9-T10 thoracic vertebra. After visualizing the landmarks on the USG machine, a 25G Quincke spinal needle was used to perform the block. After piercing the costotransverse ligament and entering the paravertebral space, 10 ml of 0.25% bupivacaine was given after negative aspiration to blood (Figure 1). The patients are then turned to supine position and extubated after complete reversal from neuromuscular blockade. The patients were assessed for: pain relief by using visual analogue scale (VAS) score. Number of patients who had Early post operative pain (<24 hours), Late post operative pain (>24-48 hours), duration of Hospital stay, Significant analgesic requirement were counted in both groups. The clinical data of the two group were analyzed. P value was calculated to check significance of difference in 2 groups. $p < 0.001$ – highly significant, $p < 0.01$ - significant and $p > 0.01$ - not significant.

The Visual Analogue Scale (VAS) measures pain intensity. The VAS consists of a 10cm line, with two end points representing 0 ('no pain') and 10 ('pain as bad as it could possibly be'). Ask the patient to rate their current level of pain by placing a mark on the line. Use a ruler to measure the distance in centimetres from the 'no pain marker' (or zero) to the current pain mark. This provides a pain intensity score out of 10; for example, 6 out of 10 (or 6/10).

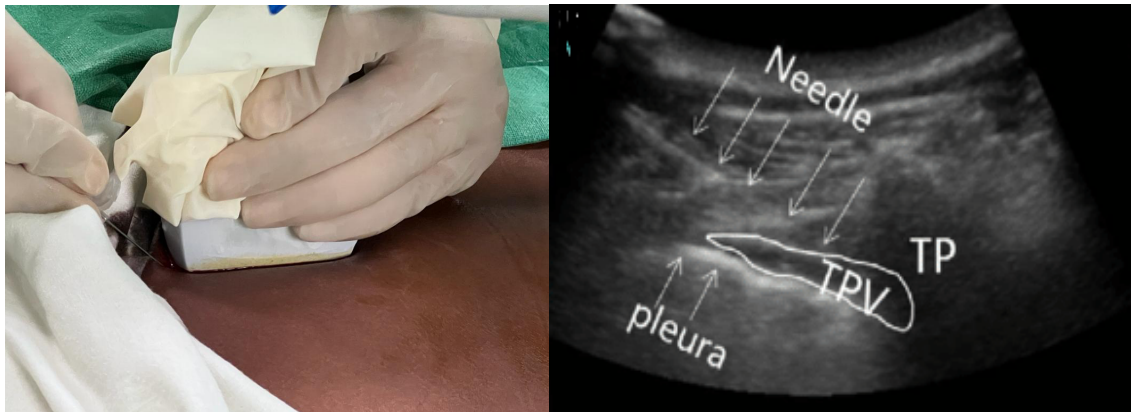


Figure 1: Ultrasound guided paravertebral block.

Results

Table 1: Number of Subjects with post operative pain

	Case Group (n=125) with TPVB Number of Subjects	Control group (n=125) without TPVB Number of Subjects	P value
Early postop pain (<24 hours)	35	90	<0.001
Late postop pain (>24-48 hours)	60	65	>0.01

Number of Subjects with Early postop pain were less in case group as compared to control group and this difference is highly significant. The difference in Number of Subjects with late postop pain in both groups was not significant.

Table 2: Duration of Hospital stay

	Case Group with TPVB Number of Days	Control group without TPVB Number of Days
Average duration of Hospital stay.	2 days	5 days

Average duration of Hospital stay in case group was less as compared to control group.

Table 3: Significant analgesic requirement

	Case Group with TPVB Number of subjects	Control group without TPVB Number of Subjects	P value
Significant analgesic requirement	20	102	<0.001

20 subjects in Case Group with TPVB needed Significant analgesic requirement and 102 subjects in Control group without TPVB needed Significant analgesic requirement

VAS scores

Table 4: Evaluation of the visual analog score at rest (Mean± SD)

VAS scores (Hours)	Case Group with TPVB (Mean± SD)	Control group without TPVB (Mean± SD)	P value
0	0.4±0.3	1.9±1.2	<0.001
2	1.6±0.7	3.8±0.8	<0.001
4	2.1±0.6	5.1±0.8	<0.001
8	4.5±0.7	5.7±0.8	<0.001
12	4.4±0.6	5.1±0.7	<0.001
24	4.8±0.2	4.9±0.3	>0.01

VAS scores at 0, 2, 4, 8 hours were found to be significantly lower in case group than group control (Table 4).

Discussion

In this study we have compared two groups of PCNL surgery comprising 125 patients each, one with TPVB and one without TPVB. Number of Subjects with Early postop pain were less in case group as compared to control group and this difference is highly significant. The difference in Number of Subjects with late postop pain in both groups was not significant. Average duration of Hospital stay in case group was less as compared to control group. 20 subjects in Case Group with TPVB needed Significant analgesic requirement and 102 subjects in Control group without TPVB needed Significant analgesic requirement. VAS scores at 0, 2, 4, 8 hours were found to be significantly lower in case group than group control (Table 4). Thoracic paravertebral block has been shown to be a proven technique to provide sufficient postoperative analgesia for a variety of thoracic and upper abdominal surgeries. Although PCNL can be done under spinal or epidural anesthesia, they carry their own drawbacks (which can be avoided by using PVB) that include, hypotension especially after positioning the patient prone (due to sympathetic blockade) which necessitates fluid administration added to the irrigation fluids with subsequent electrolyte imbalance and subsequent increased perioperative shivering, the surgeon may not feel comfortable in making skin punctures, especially those close to the 11th rib, patient discomfort increases with increased duration of the procedure and they carry the risks of

post-dural puncture headache (PDPH) and neurological complications [14]. The mechanism of action of anesthesia and analgesia produced by PVB is most probably due to direct penetration of LA into the spinal nerves contained within the PV space, where they lack their coverings, except of a thin layer which is easily and efficiently blocked [15]. Also, block of thoracic sympathetic ganglia relieves visceral pain arising from the kidney. The primary outcome measure, the VAS score, revealed a statistically significant difference between case group and control group. Patients in case group reported lower VAS scores throughout the postoperative period, indicating superior pain control compared to the standard pain management in control group. These results are consistent with previous studies that have demonstrated the analgesic efficacy of paravertebral block in various surgical procedures.[16,17] The targeted approach of para vertebral block likely contributed to its effectiveness in providing localized pain relief.

Conclusion

This research study demonstrated that para-vertebral block is a superior pain management technique compared to standard pain management in patients undergoing PCNL for kidney stone removal. TPVB is effective modality in controlling early postoperative pain after PCNL surgery. However there is no effect in late postoperative pain control after PCNL surgery with TPVB.

References

1. Preminger GM. Percutaneous nephrolithotomy: an extreme technical makeover for an old technique. *Arch Ital Urol Androl.* 2010; 82(1):23–5.
2. Rawal N. Current issues in postoperative pain management. *Eur J Anaesthesiol.* 2016;33 (3): 160–71.
3. Singh I, Yadav OK, Gupta S. Efficacy of intercostal nerve block with 0.25% bupivacaine in percutaneous nephrolithotomy: a prospective randomized clinical trial. *Urol Ann.* 2019;11(4):363–8.
4. Wang J, Zhang C, Tan D, et al. The effect of local anesthetic infiltration around nephrostomy tract on postoperative pain control after percutaneous nephrolithotomy: a systematic review and meta-analysis. *Urol Int.* 2016;97(2): 125–33.
5. Li C, Song C, Wang W, Song C, Kong X. Thoracic paravertebral block versus epidural anesthesia combined with moderate sedation for percutaneous nephrolithotomy. *Med Princ Pract.* 2016;25(5):417–22.
6. Davies RG, Myles PS, Graham JM. A comparison of the analgesic efficacy and side-effects of paravertebral vs epidural blockade for thoracotomy--a systematic review and meta-analysis of randomized trials [published correction appears in *Br J Anaesth.* 2007 Nov;99(5):768]. *Br J Anaesth.* 2006; 96(4):418–26.
7. Richardson J, Lönnqvist PA, Naja Z. Bilateral thoracic paravertebral block: potential and practice. *Br J Anaesth.* 2011;106(2):164–71.
8. Richardson J, Sabanathan S, Jones J, Shah RD, Cheema S, et al. A prospective, randomized comparison of preoperative and continuous balanced epidural or paravertebral bupivacaine on post-thoracotomy pain, pulmonary function and stress responses. *Br J Anaesth.* 1999; 83: 387-392.
9. Davies RG, Myles PS, Graham JM. A comparison of the analgesic efficacy and side-effects of paravertebral vs. epidural blockade for thoracotomy-a systematic review and meta-analysis of randomized trials. *Br J Anaesth.* 2006; 96: 418-426.
10. Baik JS, Oh AY, Cho CW, Shin HJ, Han SH, et al. Thoracic paravertebral block for nephrectomy: a randomized, controlled, observer blinded study. *Pain Med.* 2014; 15: 850-856.
11. Klein SM, Bergh A, Steele SM, Georgiade GS, Greengrass RA. Thoracic paravertebral block for breast surgery. *Anesth Analg.* 2000; 90: 1402-1405.
12. Saito T, Gallagher ET, Cutler S, Tanuma K, Yamada K, et al. Extended unilateral anesthesia. New technique or paravertebral anesthesia? *Reg Anesth.* 1996; 21: 304-307.
13. Cheema SP, Ilsley D, Richardson J, Sabanathan S. A thermographic study of paravertebral analgesia. *Anaesthesia.* 1995; 50: 118-121.
14. Gilbert J, Hultman J. Thoracic paravertebral block: a method of pain control. *Acta Anaesthesiol Scand.* 1995; 33: 142-145.
14. Mehrabi S, Karimzadeh Shirazi K. Results and complications of spinal anesthesia in percutaneous nephrolithotomy. *Urol J.* 2010; 7: 22-25.
15. Richardson J, Lönnqvist PA. Thoracic paravertebral block. *Br J Anaesth.* 1998; 81: 230-238.
16. Soto RG, Fu ES. Acute pain management for patients undergoing thoracotomy. *Ann Thorac Surg.* 2003;75(4):1349-57.
17. Marshall K, McLaughlin K. Pain Management in Thoracic Surgery. *Thorac Surg Clin.* 2020; 30(3):339-46.