

**Study of Appendicitis in Adult Population from Multiple Centres****Motupally Aravind Kumar**

Assistant Professor, Department of General Surgery, Sri Balaji Medical College, Renigunta, Andhra Pradesh

Received: 25-10-2023 / Revised: 23-11-2023 / Accepted: 26-12-2023

Corresponding Author: Dr. Motupally Aravind Kumar

Conflict of interest: Nil

**Abstract:**

**Background:** Appendicular disease is considered one of the major medical problems in adult population. Acute or chronic Appendicitis usually presents an emergency in terms of both diagnostic urgency and therapeutic intervention. Delay in diagnosis further delays treatment, which leads to emergency complications like Appendicular Perforation, Appendicular Abscess etc.

**Method:** 70 adult patients aged between 35 to 65 clinically diagnosed with Appendicitis were carried out by a standard three-port technique for laparoscopic appendicectomy or open appendicectomy. The operative time was calculated from skin incision to the skin closure and patient recovery from general anesthesia. The laparoscopic appendicectomy was done as and when deemed necessary.

**Results:** In the clinical manifestations, 70 (100%) had tenderness in the right iliac fossa, 49 (70%) had fever, 7 (10%) had vomitings, 14 (20%) had leucocytosis. 19 (27%) patients needed emergency treatment, 36 (51%) had elective therapy. Out of 70 patients 44(63%) had Open Appendicectomy, 11(16%) Laparoscopic Appendicectomy, 5 (7%) had complications and 10(14%) patients were treated conservatively. Out of 70 patients diagnosed as Appendicitis 49(70%) was Male patients and 21(30%) were Female patients. The organisms observed post-surgically were 33(47%) E. coli, and 6(9%) had Klebsella, 4 (6%) had Streptococcus 12 (17%) had no organism as patients had cultured due to early healing.

**Conclusion:** Early detection and early treatment of Appendicitis will prevent Emergency Operation morbidity and mortality in patients.

**Keywords:** Laparoscopic, Open Surgery, Appendicular Abscess, Appendicular Perforation, Acute Appendicitis.

This is an Open Access article that uses a funding model which does not charge readers or their institutions for access and distributed under the terms of the Creative Commons Attribution License (<http://creativecommons.org/licenses/by/4.0>) and the Budapest Open Access Initiative (<http://www.budapestopenaccessinitiative.org/read>), which permit unrestricted use, distribution, and reproduction in any medium, provided original work is properly credited.

**Introduction**

Acute appendicitis is a relatively common clinical entity characterised histopathologically by obstruction of the lumen of appendix due to oedema, stone, or fecolith. During the early stages of acute appendicitis, the connective tissue surrounding the appendix is edematous. The pain starts around the umbilicus and moves towards the right iliac fossa. The oedema during this initial stage facilitates the dissection of the structures surrounding the appendix.

After 72 hours of inflammation, adhesions, Hypervascularity, fibrosis, and necrosis develop. These changes prevent further dissection by forming appendicular mass and thus increase the chances for intra-operative complications. The sequence of these inflammation changes led to the belief in perforating surgery for acute appendicitis during the first 72 hours of the onset of symptoms. The patients should be admitted to the hospital and receive intravenous hydration, pain control, and intravenous antibiotics while awaiting surgery. To diagnose appendicitis apply gentle pressure on painful

area. When the pressure is suddenly released appendicitis pain will often feel worse. This is because of inflammation of the lining of the abdominal cavity, called the peritoneum.

These patients had a shorter hospital stay and a shorter operating time. There was no conversation about open appendicectomies, which can occur in some of patients with acute appendicitis and diminishes the potential medical, cosmetic, and economic advantages of the minimally invasive procedure. Hence, an attempt was made to evaluate the pros and cons of laparoscopic procedures in appendicectomy.

**Material and Methods**

70 (seventy) adult patients visited to surgery department at various multiple centres were studied.

**Inclusive Criteria:** Adult patients aged between 35 to 75 years with clinically confirmed appendicitis who gave written consent for surgery were selected for study.

**Exclusion Criteria:** Patients unwilling for early operation and having co-morbid conditions like uncontrolled hypertension, diabetes mellitus, hepatic, renal disease, etc., rendering them unfit for surgery on a semi-emergency basis, having cholelithiasis as on USG, pregnancy, or history of missed periods in premenopausal females, cholangitis, and subsequent histo-pathological findings of malignancy were excluded from the study.

### Method

All the patients with suspected symptoms of Appendicitis were subjected to clinical evaluation. Following appropriate confirmation using different imaging modalities, the patients underwent an open appendicectomy as per the hospital's protocol.

The relevant socio-demographic details, clinical presentation imaging, laboratory findings, intra-operative findings, and post-operative histopathological findings were recorded in every patient.

The duration of the study was from May 2021 to June 2023.

**Statistical analysis:** Various clinical management modes of presentation, types of pathology the organisms cultured post-surgically were classified by

percentage. The statistical analysis was carried out using SPSS software. The ratio of males and females was 2:1.

### Observation and results

**Table 1:** Clinical Manifestations of the Patients with Appendicitis

- A. Clinical presentation: 70 (100%) had tenderness in the right iliac fossa, 49 (70%) had fever, 7 (10%) had vomitings, 14 (20%) had leucocytosis.
- B. Mode of presentation: 19 (27%) patients needed emergency treatment, 36 (51%) had elective therapy.
- C. Types of pathology Out of 70 patients 44(63%) had open appendicectomy, 11(16%) laparoscopic appendicectomy, 5 (7%) had complications and 10(14%) patients were treated conservatively.

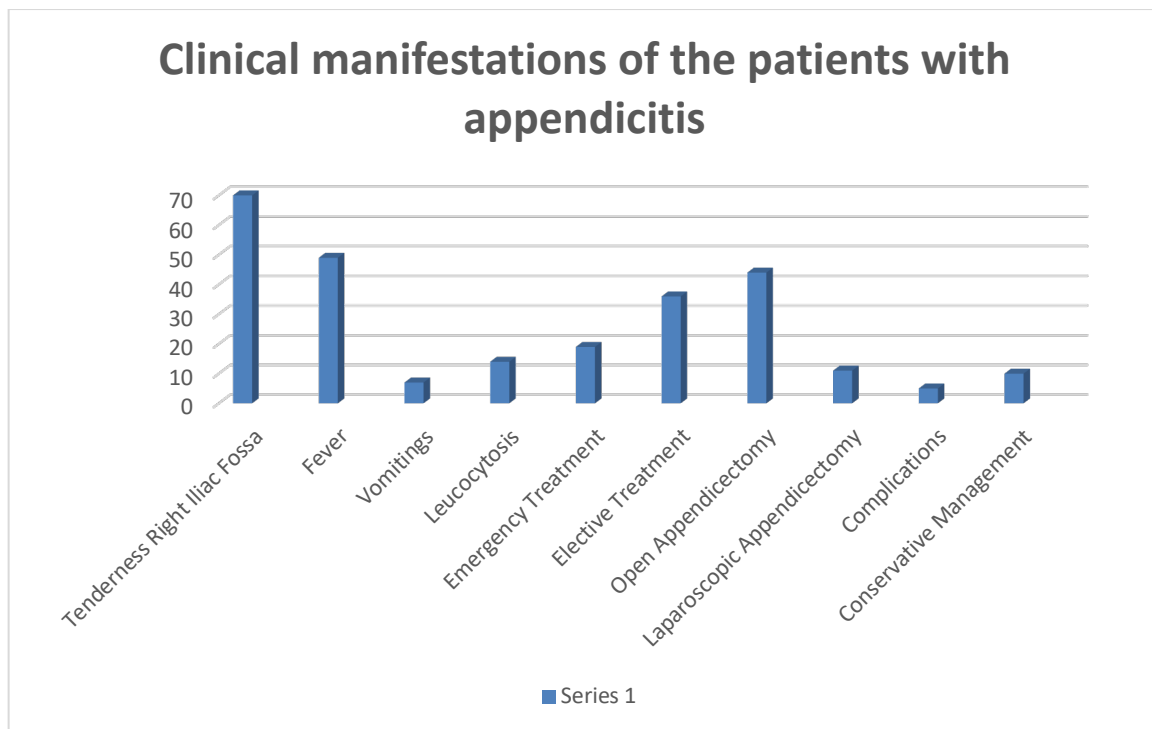
**Table 2:** Study of organism culture post-surgically in patients with Appendicitis. The organisms observed post-surgically were 33(47%) E. coli, and 6(9%) had Klebsella, 4 (6%) had Ktreptococcus 12 (17%) had no organism as patients had cultured due to early healing.

**Table1: Clinical manifestations of the patients with appendicitis (No of Patients: 70)**

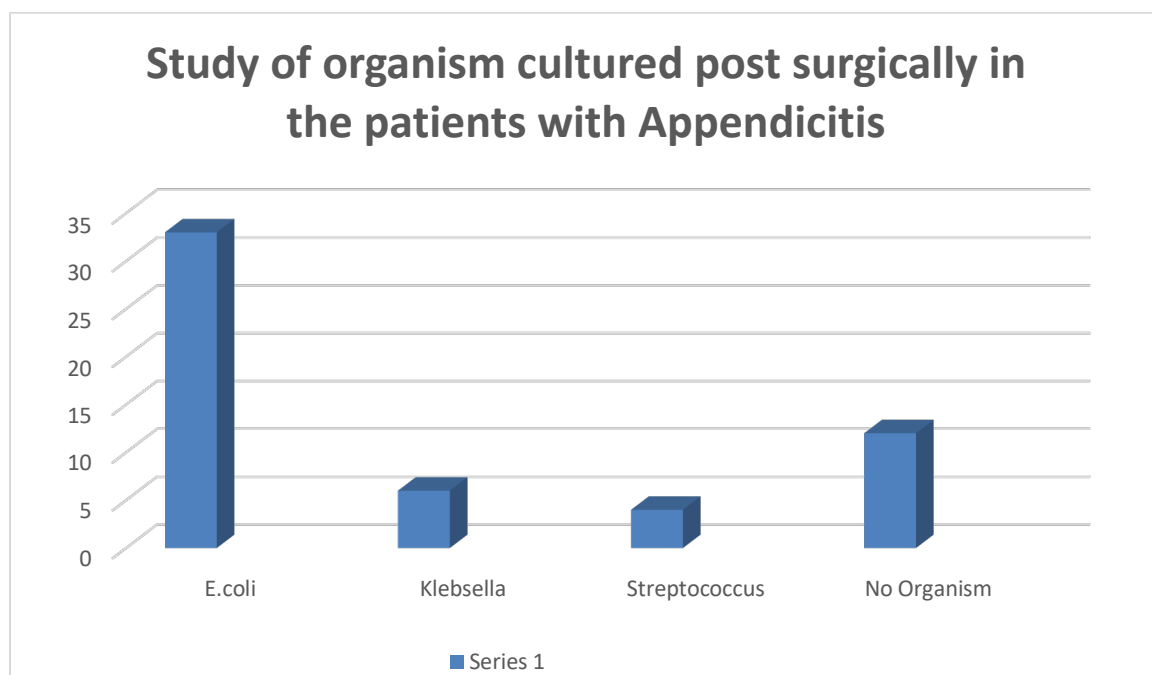
	Clinical manifestation	No of patients(70)	Percentage (%)
<b>A</b>	<b>Clinical presentations</b>		
<b>1</b>	<b>Tenderness right iliac fossa</b>	<b>70</b>	<b>100</b>
<b>2</b>	<b>fever</b>	<b>49</b>	<b>70</b>
<b>3</b>	<b>vomitings</b>	<b>7</b>	<b>10</b>
<b>4</b>	<b>leucocytosis</b>	<b>14</b>	<b>20</b>
<b>B</b>	<b>Mode of presentation</b>		
<b>1</b>	<b>Emergency Treatment</b>	<b>19</b>	<b>27</b>
<b>2</b>	<b>Elective treatment</b>	<b>36</b>	<b>51</b>
<b>C</b>	<b>Types of Pathology</b>		
<b>1</b>	<b>Open Appendicectomy</b>	<b>44</b>	<b>63</b>
<b>2</b>	<b>Laparoscopic Appendicectomy</b>	<b>11</b>	<b>16</b>
<b>3</b>	<b>complications</b>	<b>5</b>	<b>7</b>
<b>4</b>	<b>Conservative Management</b>	<b>10</b>	<b>14</b>

**Table 2: Study of organism cultured post surgically in the patients with Appendicitis**

Sl no	Cultured organisms	No of patients	Percentage (%)
<b>1</b>	<b>E.coli</b>	<b>33</b>	<b>47</b>
<b>2</b>	<b>Klebsella</b>	<b>6</b>	<b>9</b>
<b>3</b>	<b>Streptococcus</b>	<b>4</b>	<b>6</b>
<b>4</b>	<b>No organism</b>	<b>12</b>	<b>17</b>



**Graph 1: Clinical manifestations of the patients with appendicitis**



**Graph 2: Study of organism cultured post surgically in the patients with Appendicitis**

**Discussion**

Present study of Appendicitis in adult patients from multiple centres. The clinical manifestations were that 70 (100%) had tenderness in the right iliac fossa, 49 (70%) had fever, 7 (10%) had vomitings, 14 (20%) had leucocytosis.

Mode of presentation: 19 (27%) patients needed emergency treatment, 36 (51%) had elective therapy. Types of pathology Out of 70 patients

44(63%) had open appendicectomy, 11(16%) laparoscopic appendicectomy, 5 (7%) had complications and 10(14%) patients were treated conservatively. Study of organism culture post-surgically in patients with Appendicitis. The organisms observed post-surgically were 33(47%) E. coli, and 6(9%) had Klebsella, 4 (6%) had Streptococcus 12 (17%) had no organism as patients had cultured due to early healing. These findings were more or less in agreement with previous studies.

Proforma:		
1	Name of the patient:	
2	Age:	
3	Sex:	
4	Occupation:	
5	Address:	
6	IP number:	
7	DOA:	
8	DOS:	
9	DOD:	
10	Chief complaints:	
11	History of Present illness:	
12	Site:	
13	Duration:	
14	Mode of onset:	
15	Pain in the Right Iliac Fossa:	
16	Vomitings:	
17	Fever:	
18	Others:	
19	Past history:	
20	History of Diabetes Milletus:	
21	History of Hypertension:	
22	Tuberculosis:	
23	Asthma:	
24	Epilepsy:	
25	Personal History:	
26	History of alcohol consumption:	
27	Bladder and bowel complaints:	
28	History of drug allergy	
29	Family history:	
30	General Examination:	
31	CVS:	
32	RS:	
33	P/A:	
34	CNS:	
35	Local Examination:	
36	Inspection:	
37	Palpation:	
38	Percussion:	
39	Auscultation:	
40	Clinical Diagnosis:	
41	Investigations:	
42	Laboratory investigations:	
43	Complete Blood Picture: Leucocytosis	
44	Special investigations:	
45	Ultrasound abdomen:	
46	CT Scan abdomen plain and contrast:	

A thorough clinical assessment and a high index of suspicion of acute appendicitis are essential in any patient who presents with acute right iliac fossa pain and fever. Other clinical conditions that mimic Appendicitis include cholecystitis, gastritis, pancreatitis, right lower lobe pneumonia, and right renal colic. Fever, right iliac fossa pain with rebound tenderness is a well-established sign and symptom of Appendicitis. Ultrasonography has been used to detect appendicitis these days because

the echogenic features of Appendicitis, appendicular abscess can be differentiated from those in GB stones, in cholecystitis or silent (asymptomatic) GB stones.

Deep probe tenderness is sometimes used as evidence of Appendicitis. However, wall odema is not specific to appendicitis and lumen of appendix is found in patients of about at least ten millimetres. Early open appendicectomy surgery was recommended in appendicitis to prevent wound infection

and shorten the stay in the hospital. But there are no differences in morbidity in cases of appendicular abscess or appendicular perforation in open surgery. Before the introduction of ultrasonography, symptomatic appendicitis was treated with open appendectomy. Most of the negative appendectomy were found at autopsy, and a few positive appendectomy were found by surgeons while doing an abdominal surgical procedure for some other illness. Many surgeons feel that it is good reason for doing appendectomy to all patients with open abdominal surgery.

With the ever-increasing frequency of application of abdominal ultrasonography, almost all of the appendicitis can be discovered in vivo, but ultrasonography does not establish the Carcinoma of appendix, the salient histopathological feature of Appendicitis.

### Summary and Conclusion

The present study of Appendicitis in the Adult population will be useful for surgeons for a proper approach. Clinicians at various levels need to have a good understanding of the varied clinical presentations of acute appendicitis, silent (chronic) appendicitis, and different management options, their pros and cons, to be able to treat the conditions effectively. Moreover, this present study demands further histo-pathological, nutritional, environmental, genetic, and embryological studies because the exact mechanism and duration of the appendicitis (fecolith formation) are still unclear.

**Limitation of Study:** Owing to the tertiary location of the hospital, the limited number of patients, and the lack of the latest instruments, we have limited findings and results.

This research paper was approved by the ethical committee of the Sri Balaji medical College in Renigunta, Andhra Pradesh.

### References

1. Sabiston Textbook of Surgery, 20<sup>th</sup> edition; Chapter 50, page 1296-1311.
2. Bailey and Love Short Practice of Surgery, 27<sup>th</sup> edition; Chapter 72, page 1299-1318.
3. Manipal Manual of Surgery, fourth edition; Chapter 33, page 824-842.
4. Diagnosis and Treatment of Acute Appendicitis: 2020 update of the WSES Jerusalem guidelines – World Journal of Emergency Surgery. 2020; 15:27.
5. Salomone Di Saverio, Mauro Podda et al. Acute Appendicitis in Adults; Internal Surgery Journal, Ketan vaghalkar, vol 7, No :9,2020.
6. Acute Appendicitis- Journal of Acute care Surgery- Daibo Kojima, Ari Leppaniemi, Suguru Hasegawa, 2019; 9(2): 31-34.
7. George orthopoulos, Elizabeth santoni et al. Increasing incidence of Complicated Appendicitis during Covid-19 Pandemic. The American Journal of Surgery, May 2021; 221(5): 1056-1060.