

**A Rare Case Report of Pancreatic Pseudocyst Formation in Ectopic Pancreas****Manish Somkuwar<sup>1</sup>, Vishal Bhabhor<sup>2</sup>, Parthrajsinh Rathod<sup>3</sup>, Pranav Vasava<sup>4</sup>, Mithun Barot<sup>5</sup>**<sup>1</sup>Resident Doctor, Department of General Surgery, GMERS Gotri Hospital, Vadodara.<sup>2</sup>Assistant Professor, Department of General Surgery, GMERS Gotri Hospital, Vadodara<sup>3</sup>Junior Resident Doctor, Department of General Surgery, GMERS Gotri Hospital, Vadodara.<sup>4</sup>Junior Resident Doctor, Department of General Surgery, GMERS Gotri Hospital, Vadodara.<sup>5</sup>Head of the Unit, Department of General Surgery, GMERS Gotri Hospital, Vadodara

Received: 25-10-2023 / Revised: 23-11-2023 / Accepted: 18-12-2023

Corresponding Author: Dr.Mithun v Barot

Conflict of interest: Nil

**Abstract:****Background and Goals:** The ectopic pancreas is an extremely rare condition. Accidentally found during laparotomy. However, diseases of the pancreas such as pancreatic pseudocysts can also occur in this ectopic tissue. Even with symptoms, preoperative diagnosis is difficult.**Keywords:** Pancreas, Ectopic pseudocyst, Duodenum.

This is an Open Access article that uses a funding model which does not charge readers or their institutions for access and distributed under the terms of the Creative Commons Attribution License (<http://creativecommons.org/licenses/by/4.0>) and the Budapest Open Access Initiative (<http://www.budapestopenaccessinitiative.org/read>), which permit unrestricted use, distribution, and reproduction in any medium, provided original work is properly credited.

**Introduction**

Ectopic pancreatic tissue may occur from the displacement of small amounts of the pancreas during embryologic development, resulting in the formation of a nodule independent from the vascular supply or anatomic connection [1,2]. It may be symptomatic (e.g. Epigastric pain, nausea, vomiting, abdominal fullness, obstruction, ulceration, tarry stool, weight loss) but the majority of cases are incidental findings. In symptomatic cases, a "Tumor" is described radiographically or with an endoscopic procedure. The tissue is found most frequently in the stomach and proximal small intestine (usually in the submucosa), but other locations are possible such as Meckel's diverticulum, esophagus, spleen, gall bladder, and mediastinum [3]. If the ectopic tissue is large enough (1-3 cm) to be seen on gross inspection it appears as a firm, pale, nodular mass. The classic example is composed of acini, islets, and ductal structures with the usual lobular architecture, but either ducts or acini may predominate abnormally. Some cases are composed only of ducts [4,5]. surgical excision relieves symptoms, although a minimally invasive technique should be used if possible. Rarely pancreatic neoplasm including adenocarcinoma may develop in ectopic pancreatic tissue, requiring a more extensive remedy [6-8]. Occasionally, pancreatic tissue occurs as a part of a teratoma.

**Case report**

A 40-year-old female patient, with no known comorbidities presented, with complains of a lump in the abdomen for 20 years. She had no history of

jaundice, decreased appetite, weight loss, or pancreatitis. There was no similar illness in the family. On examination, her pulse was 84/min, blood pressure 130/90 mmHg, and respiratory rate 20/min. Her temperature was afebrile, She weighed 60 kg, and her height was 165 cm. Abdominal examination revealed a large, firm, freely mobile retroperitoneal mass of size 10 x 7 cm occupying the right hypochondrium and right iliac region which was associated with mild tenderness [Figure. 1]. Further laboratory investigations, including CBC, RFT, LFT, RBS.

On the CECT, [Figure-2] the patient was provisionally diagnosed, as having a pseudocyst in the head of the pancreas. She was posted for surgery. On exploration, a cyst of 12x 10x 10 cm arising from the retro-peritoneum was found to be arising from the 1st part of the duodenum and it was completely free from the pancreas.

So the cysto-duodenectomy along with Roux-en-Y gastro-jejunostomy was performed. The patient was discharged on the 8th postoperative day after a good recovery; She came for follow-up for 3 months.

On gross histopathological examination (HPE) [Figure -3] mass was 14.0 x 13.0 x 5.0 cm with a smooth glistening raw area that was adherent to the 1st part of the duodenum. On cut open, viscid pale brownish fluid came out and rough greyish-whitish areas were noted on the inner wall of the cyst on microscopic examination, the specimen showed a cystic structure without lining epithelium. The wall shows

infiltration of foamy macrophages marked variable mixed inflammatory cells, adjacent areas show

pancreatic tissue and muscular layer suggesting of pseudocyst of pancreas.

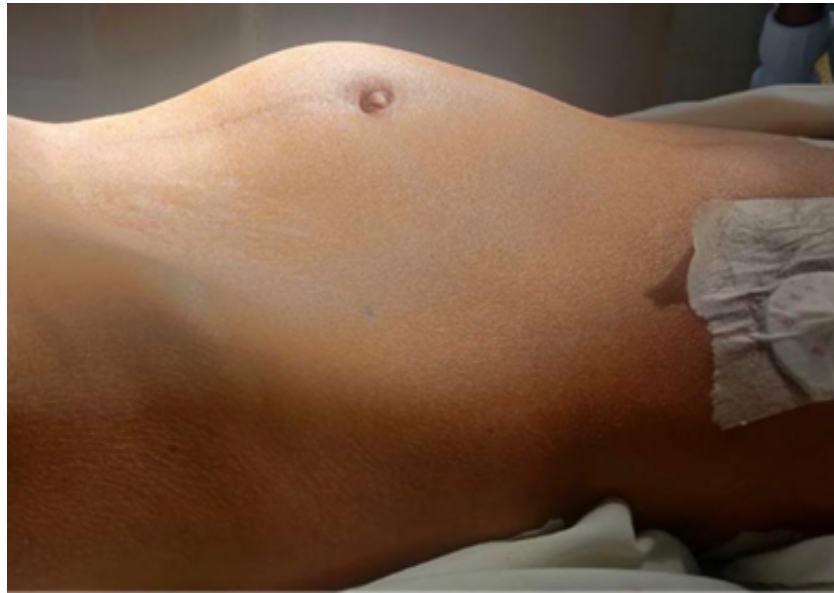

Figure 1: Retroperitoneal mass

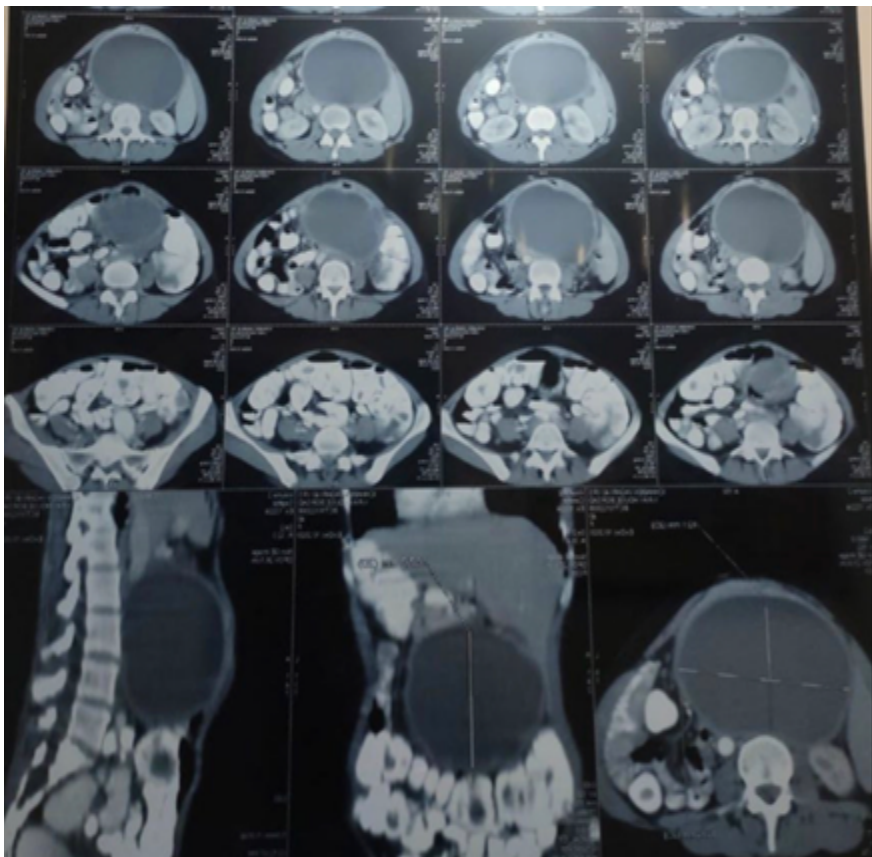


Figure 2: CECT showing cyst of 12x 10x 10 cm

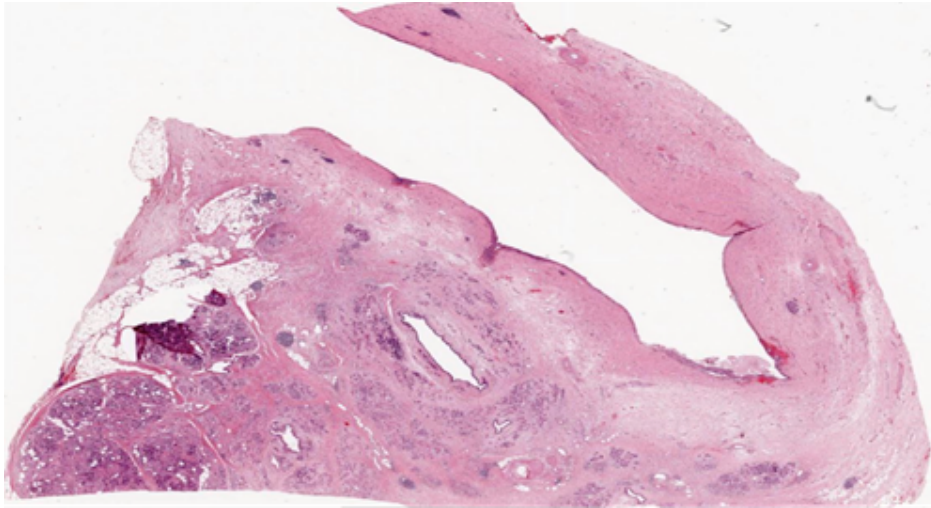


Figure 3: HPE image

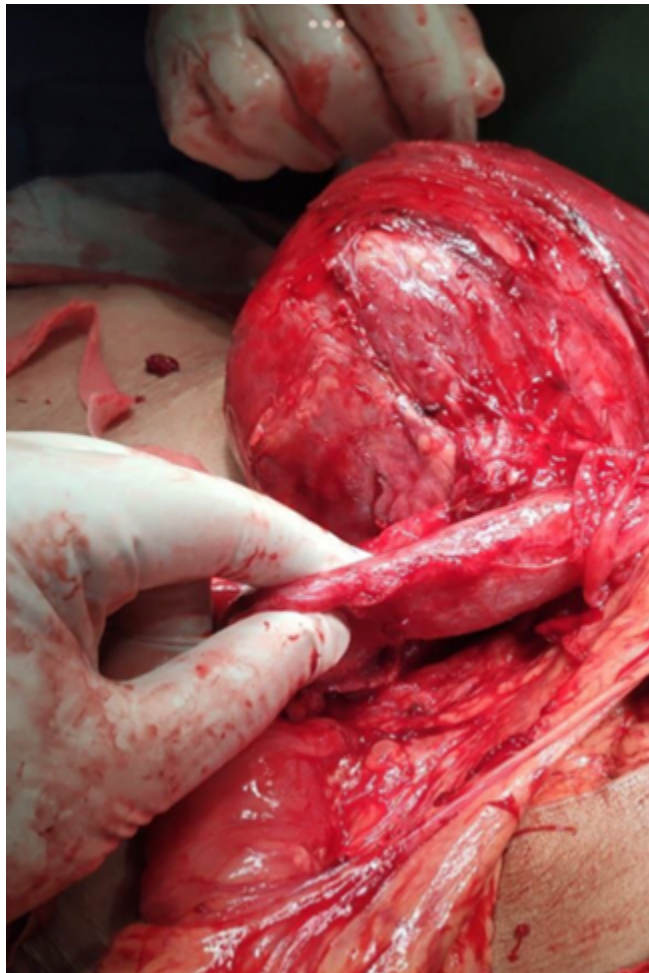


Figure 4: Intra op

### Discussion

Many patients with pancreas in ectopic places are asymptomatic and found incidentally on laparotomy or at the time of postmortem. At that time also the symptomatic preoperative diagnosis is very difficult. The ectopic pancreas is an uncommon condition. It is usually found in the gastrointestinal

tract with 24-38% being seen near the stomach, 9-36% near the duodenum, and 0.5-27% near the jejunum. Ectopic pancreatic tissue near duodenal wall has rarely been diagnosed and reported. Most of the patient presents with an abdominal lump or epigastric pain. It may be miss diagnosed as pancreatic pseudocyst or malignant cystic lesion before any confirmatory test.

In past there are very few cases reported of ectopic pseudocyst of the pancreas and every time it was missed diagnosed as another lesion of the pancreas. The management of ectopic pancreas remains controversial as there are rare cases reported of pseudocyst formation in ectopic pancreatic tissue . There are 61% of cases where the symptoms are attributable to the ectopic pancreas itself.[9] However, it has been noticed that in most of cases ectopic pancreas does not cause any abdominal discomfort and can be controlled with only medical management.[10] This leads to different opinions in managing this kind of patient but it is recommended that if there is such a huge mass and the patient is symptomatic surgical excision is the best available option for these patients.

### Conclusion

To conclude, we describe in this article, a rare case of ectopic pancreatic pseudocyst near the duodenum we highlight that it was difficult to diagnose it preoperatively just on the bases of clinical examination and imaging. We suggest that this kind of cyst requires EUS (Endoscopic ultrasonography) guided FNAC (Fine needle aspiration cytology) before any operative intervention.

### References

1. Corson S. Operative hysteroscopy for infertility. *Clin Obstet Gynecol.* 1992; 35:54-61.
2. Ekerhovd E, Fried G, Granberg S. An ultrasound-based approach to the assessment of infertility, including the evaluation of tubal patency. *Best Pract Res Clin Obstet Gynecol.* 2004; 18:13-28.
3. Gautam JN. Imaging in the evaluation of female infertility. *JR Eprod Med.* 1992; 37:54-61.
4. Valle RF. Hysteroscopy. *Curr Opin Obstet Gynecol.* 191;3:422-426. March CM. Hysteroscopy. *J Repord Med.* 1992; 37:293-311.
5. SperoffL, Fritz MA. *Clinical Gynecologic Endocrinology and Infertility.* 6th edition. Philadelphia, PA: Lipincott Williams & Wilkins, 2004.
6. Fadare O, Zheng W. Histologic dating of the endometrium: accuracy, reproducibility, and practical value. *Adv Anat Pathol.* 2005;12:39-46.
7. Murray MJ, Meyer WR, Zaino RJ, et al. A critical analysis of the accuracy, reproducibility, and clinical utility of histologic endometrial dating fertile women. *Fertil Sterile* 2004; 81:1333-1343.
8. Salamonsen LA, Lathbury LJ. Endometrial leukocytes and menstruation. *Hum Repord Update.* 2000; 6:16-27.
9. Decastro Barbosa JJ, Dockerty MB, Waugh JM. Pancreatic heterotopia. *Surg Gynecol Obstet.* 1946; 80:527-42.
10. Dolan RV, Remine WH, Docherty MB. The fate of heterotopic pancreatic tissue. *Arch Surg.* 1974; 109:762-5.