

A Comprehensive Study of Cervical Biopsy Findings and Hysterectomy Specimen Pathology in Women with Abnormal Uterine Bleeding

Ranjeet Kumar¹, Rupala Dipti Pravin Bhai²

¹Associate Professor, Department of Pathology, Gouri Devi Institute of Medical Sciences and Hospital, Durgapur, West Bengal, India

²Assistant Professor, Department of Pathology, Gouri Devi Institute of Medical Sciences and Hospital, Durgapur, West Bengal, India

Received: 10-09-2024 / Revised: 16-10-2024 / Accepted: 22-11-2024

Corresponding Author: Dr. Rupala Dipti Pravin Bhai

Conflict of interest: Nil

Abstract:

Background: Abnormal uterine bleeding (AUB) is among the commonest diseases affecting females from all age groups because of various lesions within the cervix and uterus. Microscopic examination of biopsied tissues taken from the cervix as well as those removed through hysterectomy is the only definitive diagnosis for inflammation, benign, pre-malignant or malignant lesions causing AUB.

Aim: To comprehensively evaluate cervical biopsy findings and hysterectomy specimen pathology in women presenting with abnormal uterine bleeding.

Methodology: This retrospective study was done for a period of one year on 180 cases with regard to cervical biopsy specimens and hysterectomy specimens. This observational study was done at the Department of Pathology of Gouri Devi Institute of Medical Sciences & Hospital, Durgapur, West Bengal, India. The statistical analysis was done on the study of the demographic, clinical, and pathological features of the lesions.

Results: The highest percentage among the subjects is that of the 41 to 50 age group, which 38.9% is. The predominant types of patients included pre-menopausal females, which constituted 65.6% of the sample. The majority of the diagnoses among the patients included those who had menorrhagia (46.1%). The predominant lesions in the samples from the biopsy of the cervix include chronic cervicitis (35.6%) and chronic cervicitis with squamous metaplasia (23.3%). Lesions that were observed through histopathological analysis of the samples taken during hysterectomy included leiomyoma (28.9%), adenomyosis (22.8%), and endometrial hyperplasia (15.6%). Among the histopathology diagnoses, the most common types of lesions were those of an inflammatory and benign nature (42.2%, 40.0%). Premalignant and malignant lesions were observed at 11.7% and 6.1%, respectively.

Conclusion: AUB is primarily concerned with inflammatory and benign conditions of the cervix and uterus. Examples include chronic cervicitis, leiomyoma and adenomyosis. Histopathological assessment of the cervical and the hysterectomy specimens are vital in the correct diagnosis and early detection of precancerous and cancerous changes of the cervix and of the uterus. The role of histopathology remains central to the care of patients with AUB.

Keywords: Abnormal uterine bleeding, Cervical biopsy, Hysterectomy specimen, Histopathology, Chronic cervicitis, Leiomyoma, Adenomyosis, Endometrial hyperplasia, Endometrial carcinoma.

This is an Open Access article that uses a funding model which does not charge readers or their institutions for access and distributed under the terms of the Creative Commons Attribution License (<http://creativecommons.org/licenses/by/4.0>) and the Budapest Open Access Initiative (<http://www.budapestopenaccessinitiative.org/read>), which permit unrestricted use, distribution, and reproduction in any medium, provided original work is properly credited.

Introduction

Abnormal Uterine Bleeding (AUB) is one of the most frequently seen problems in gynecology clinics and is an important source of morbidity amongst females in reproductive age and pre-menopausal group [1]. Abnormal Uterine Bleeding refers to the presence of a variation of the normal menstrual pattern either in terms of periodicity, consistency, frequency, and amount of blood flow. AUB has major ramifications in terms of physiological, emotional, societal, and economic impacts [2]. In addition, this condition may hamper

day-to-day activities and quality of life, contributing to the overall use of health care services. Due to its potential association with either benign or malignant gynecologic conditions, proper diagnosis and treatment of AUB are imperative for optimal patient results [3]. There are various reasons behind AUB, including cervical, endometrial, myometrial, and hormonal anomalies. The International Federation of Gynecology and Obstetrics FIGO came up with a classification method known as PALM-COEIN for

standardization of diagnosis and treatment of AUB cases [4]. As per this classification technique, the causes for AUB that are structural include Polyps, Adenomyosis, Leiomyoma, and Malignancy/Hyperplasia, while the non-structural causes are Coagulopathy, Ovulatory dysfunction, Endometrial, Iatrogenic, and others [5]. Although physical examination and other tests can give some indication regarding AUB diagnosis, confirmation is often obtained after histopathological analysis of biopsy samples.

Histopathological assessment of cervical biopsies is crucial in the diagnosis of cervical inflammatory lesions, precancerous lesions, and cancer [6]. Some of the pathological findings in cases with abnormal uterine bleeding include chronic cervicitis, squamous metaplasia, cervical intraepithelial neoplasia, and cervical cancer. Cervical biopsy is regarded as the most reliable diagnostic method to identify any lesion in the cervix before an invasion takes place [7]. It is especially necessary to diagnose early any lesion in the cervix in less developed nations because cervical cancer is a significant public health problem there.

Furthermore, hysterectomy specimens give a full picture of uterine pathology, making a thorough analysis of the endometrium, myometrium, cervix, and adnexal possible [8]. Pathological diagnosis of hysterectomy specimens is always done together with the discovery of different kinds of lesions like leiomyoma, adenomyosis, endometrial hyperplasia, endometrial polyp, chronic endometritis, and endometrial carcinoma. All these conditions have been described as the causes of abnormal uterine bleeding [9]. This highlights the importance of studying hysterectomy specimens.

Worldwide, abnormal uterine bleeding (AUB) constitutes an overwhelming problem on women's health [10]. Epidemiology shows that up to a third of all women may have experienced AUB during their lifetime. Prevalence is much higher in women who are at the perimenopausal stage where endocrine changes and pathological changes in the uterine wall become more common [11]. Chronic and untreated AUB can lead to a multitude of complications: anemia, infertility and psychological problems and the well-being of the women suffering from AUB is largely affected. Beyond the problem itself, AUB might be an alert for serious pathologies as endometrial hyperplasia and gynecological malignancies [12].

While the availability of imaging techniques and laboratory tests has expanded over the years, histopathological diagnosis still continues to be the gold standard in the determination of the etiologies of AUB [13]. Awareness of the range of cervical and uterine pathologies found in women with AUB can contribute to better diagnoses and more

appropriate therapy. Analyses of cervical biopsy with hysterectomy specimen are useful to assess the distribution and incidence of gynecological lesions in certain population groups [14]. This research work is conducted to evaluate the histopathology reports of cervical biopsies and hysterectomies in women complaining of AUB. This research intends to identify the most frequent lesions found in patients diagnosed with AUB [15]. The results generated from this research would prove valuable in developing evidence-based guidelines to manage patients with AUB.

Methodology

Study Design: This is a retrospective observational study aimed to study the histopathological pattern of the cervical biopsy and hysterectomy specimen in patients with abnormal uterine bleeding. Clinical data and histopathology reports that had been stored previously were retrieved and reviewed to establish the prevalence and distribution of different cervical and uterine lesions presenting with abnormal uterine bleeding. The use of a retrospective study was to review the past record of patient's notes and biopsy reports within a specified time and hence establish the common patterns of diseases in cervical biopsy and hysterectomy specimen with AUB.

Study Area: The research work was carried out at the Department of Pathology at Gouri Devi Institute of Medical Sciences & Hospital, Durgapur, West Bengal, India.

Study Duration: The study was performed over one year.

Study Participants

Inclusion Criteria

- Women of 20 years and above presenting with Abnormal Uterine Bleeding (AUB) in the facility where the study was conducted.
- Individuals who belong to this cohort and were treated for AUB with cervical biopsy and hysterectomy.
- Files containing clinical, operative, histological, and demographic data of patients.
- Females accessing outpatient and inpatient gynecological facilities in the study period.

Exclusion Criteria

- Patients with insufficient, autolyzed, or poor-quality tissue samples.
- Women who have incomplete clinical and/or histopathological documentation.
- Patients whose uterine bleeding is caused by obstetric conditions.
- Women whose gynecological cancers have been detected and treated before.

Sample Size

The study included 180 cases, all fulfilling the criteria for inclusion. The sample was chosen in such a way that it represents different age groups, various clinical features and the histopathological spectrum seen in abnormal uterine bleeding.

Procedure: Data are collected by retrieving patient records from the medical records section and the pathology department of the hospital. The demographics, symptoms, clinical history, cervical biopsy findings, pathological findings from hysterectomy specimens, and histopathological diagnosis are documented. The histopathological results are classified based on inflammation, benign lesions, premalignant, and malignant lesions.

Gross findings and microscopic histopathological diagnoses made in the pathology report are studied to correlate with the clinical picture of abnormal uterine bleeding. Inflammatory lesions, cervical intraepithelial neoplasia, and malignancy of the cervical biopsies and endometrium, myometrium, cervix, and adnexae in the hysterectomy specimens are analyzed. Data collection is done using a standardized form to maintain uniformity in documentation. All patient information is anonymized to preserve privacy, and ethical approval is taken from the Institutional Ethics Committee of Gouri Devi Institute of Medical Sciences and Hospital prior to conducting the study.

Statistical Analysis: Data obtained were analyzed using the SPSS software version 27.0 (IBM, USA). Descriptive analysis using the measures such as mean, standard deviation, frequencies, and percentage were performed for continuous and categorical data, respectively. Statistical relationship among the demographic factors, clinical features, and diagnosis after the histopathological examination was determined using the chi-square test if the data was categorical; otherwise, the t-test was used if the data was numeric. The level of statistical significance was at $p < 0.05$. Analysis results were presented using tables, percentages, and graphics interpretation.

Result

The following table shows demographic information about the 180 participants involved in the study. The biggest group of women aged between 41 and 50 years was represented by 70 women who constituted 38.9%. The second-biggest age group was that of women aged between 31 and 40 years, made up of 46 women accounting for 25.6%. Pre-menopause accounted for 65.6%, being the biggest menopausal state, followed by perimenopause (23.3%) and then post-menopause (11.1%).

Table 1: Demographic Characteristics of Study Participants

Parameter	Category	Frequency (n)	Percentage (%)
Age (years)	21–30	24	13.3
	31–40	46	25.6
	41–50	70	38.9
	51–60	32	17.8
	>60	8	4.4
Menopausal Status	Premenopausal	118	65.6
	Perimenopausal	42	23.3
	Postmenopausal	20	11.1
Parity	Nulliparous	42	23.3
	1–2 Children	82	45.6
	≥3 Children	56	31.1

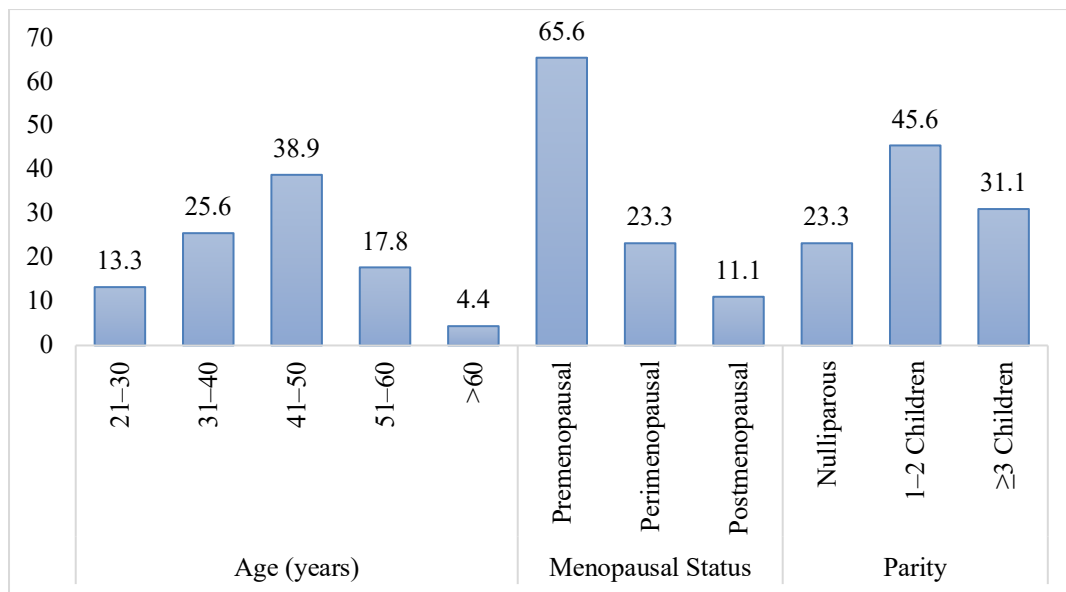


Figure 1: Visual Representation of Demographic Characteristics of Study Participants

The results revealed that cases of AUB were highest in the age group of 41-50 years old and premenopausal women. The fact that more women had between one to two kids implies that AUB is common in multiparous women. From these results, it is evident that middle-aged and premenopausal women comprised the greatest number affected by AUB.

Table 2 represents the clinical presentation of the 180 subjects included in this study. Among this

type menorrhagia were found in 83 women (46.1%) followed by metrorrhagia found in 38 women (21.1%). There were 24 women (13.3%) with polymenorrhea followed by 19 women (10.6%) with post-menopausal bleeding and 16 women (8.9%) had menometrorrhagia.

Duration of symptoms was 8.4 ± 3.2 months on an average. This indicates that, women were experiencing symptoms of AUB for approximately six months prior to diagnosis.

Table 2: Clinical Presentation of Study Participants

Clinical Presentation	Frequency (n)	Percentage (%)
Menorrhagia	83	46.1
Metrorrhagia	38	21.1
Polymenorrhea	24	13.3
Postmenopausal Bleeding	19	10.6
Menometrorrhagia	16	8.9
Duration of Symptoms (months)	Mean \pm SD	8.4 ± 3.2

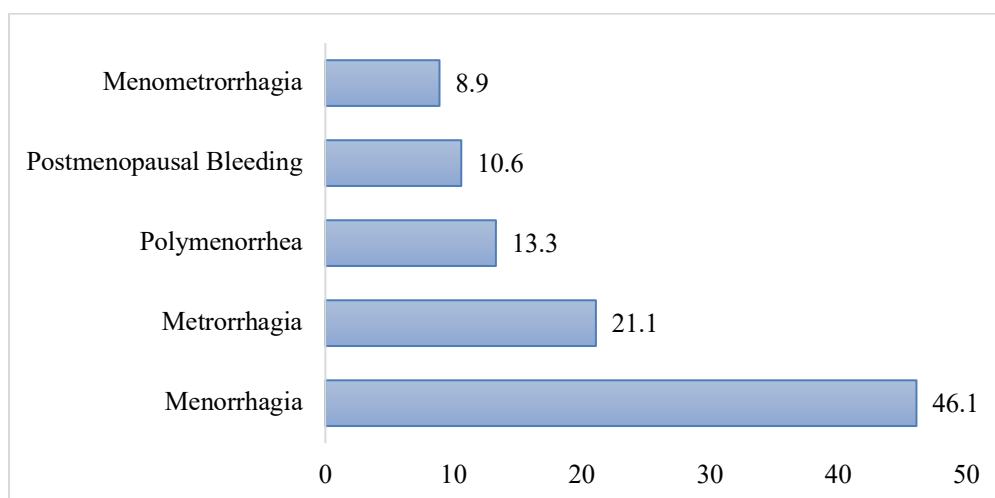


Figure 2: Visual Representation of Clinical Presentation of Study Participants

The results have shown that menorrhagia is the leading clinical presentation of abnormal uterine bleeding in the study group, indicating that excessive menstrual blood loss is most frequently why patients attend with their symptom.

The large proportion of patients attending with metrorrhagia and polymenorrhoea further emphasizes the spectrum of abnormal uterine bleeding. The length of symptoms of >8 months indicate that many patients have to endure symptoms for a significant length of time before diagnosis and appropriate management. In conclusion abnormal uterine bleeding can present

as a number of patterns, menorrhagia being the most common. Table 3 gives the histological results found in cervical biopsies of the subjects in the study. Chronic cervicitis was the commonest result recorded at 64 cases (35.6%), and chronic cervicitis with squamous metaplasia was the second commonest at 42 cases (23.3%). Cervical polyps were diagnosed in 20 subjects (11.1%).

The premalignant conditions that were recorded were atrophy, CIN I in 18 cases (10.0%) and CIN II/III in 14 cases (7.8%). Squamous cell carcinoma was found in 10 subjects (5.6%), and normal histology was found in 12 cases (6.6%).

Table 3: Histopathological Findings in Cervical Biopsy Specimens

Diagnosis	Frequency (n)	Percentage (%)
Chronic Cervicitis	64	35.6
Chronic Cervicitis with Squamous Metaplasia	42	23.3
Cervical Polyp	20	11.1
CIN I	18	10.0
CIN II/III	14	7.8
Squamous Cell Carcinoma	10	5.6
Normal Histology	12	6.6

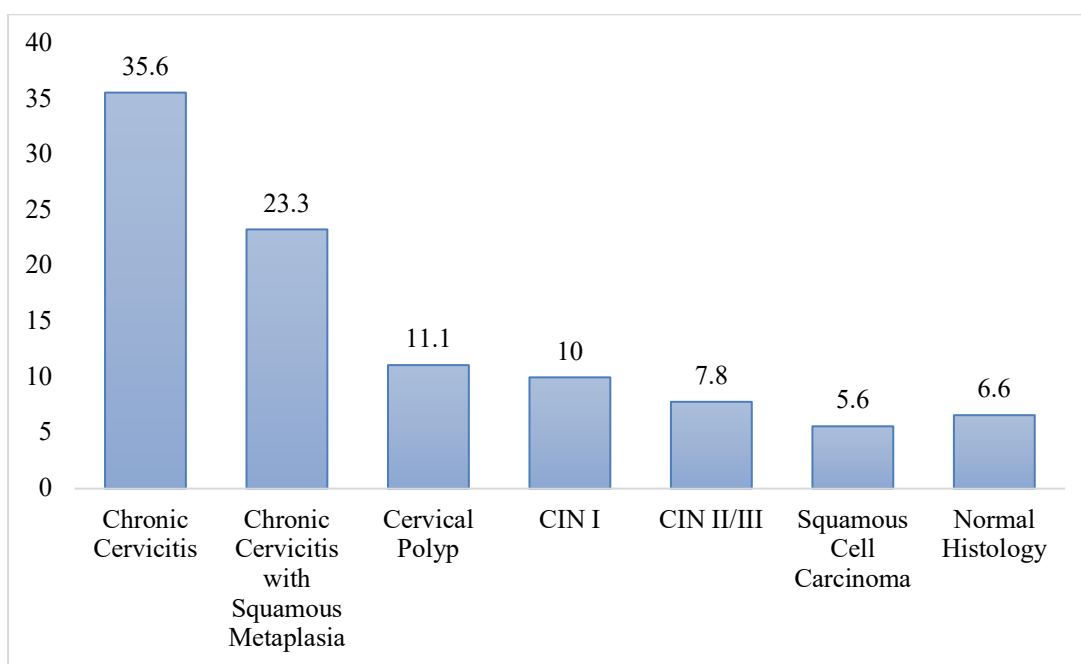


Figure 3: Visual Representation of Histopathological Findings in Cervical Biopsy Specimens

According to the results obtained from this study, most cervical pathologies were inflammation-related, such as chronic cervicitis and chronic cervicitis with squamous metaplasia. Nevertheless, the existence of cervical intraepithelial neoplasia and squamous cell carcinoma is important to emphasize when considering cervical biopsies. The overall incidence of benign inflammatory disorders was much higher than neoplastic conditions of the cervix. Table 4 shows data regarding the results of histopathological assessment of hysterectomy

specimens collected from 180 patients. The most frequent finding in the hysterectomy specimens includes leiomyoma which was found in 52 cases (28.9%), adenomyosis in 41 cases (22.8%), and endometrial hyperplasia in 28 (15.6%) hysterectomy specimens. Endometrial polyps were seen in 18 cases (10%), while chronic endometritis and endometrial carcinoma had a frequency of 12 cases (6.7%) and 11 cases (6.1%). Atrophic endometrium was identified in 8 cases (4.4%), while other lesions were seen in 10 cases (5.5%).

Table 4: Histopathological Findings in Hysterectomy Specimens

Diagnosis	Frequency (n)	Percentage (%)
Leiomyoma	52	28.9
Adenomyosis	41	22.8
Endometrial Hyperplasia	28	15.6
Endometrial Polyp	18	10.0
Chronic Endometritis	12	6.7
Atrophic Endometrium	8	4.4
Endometrial Carcinoma	11	6.1
Others	10	5.5

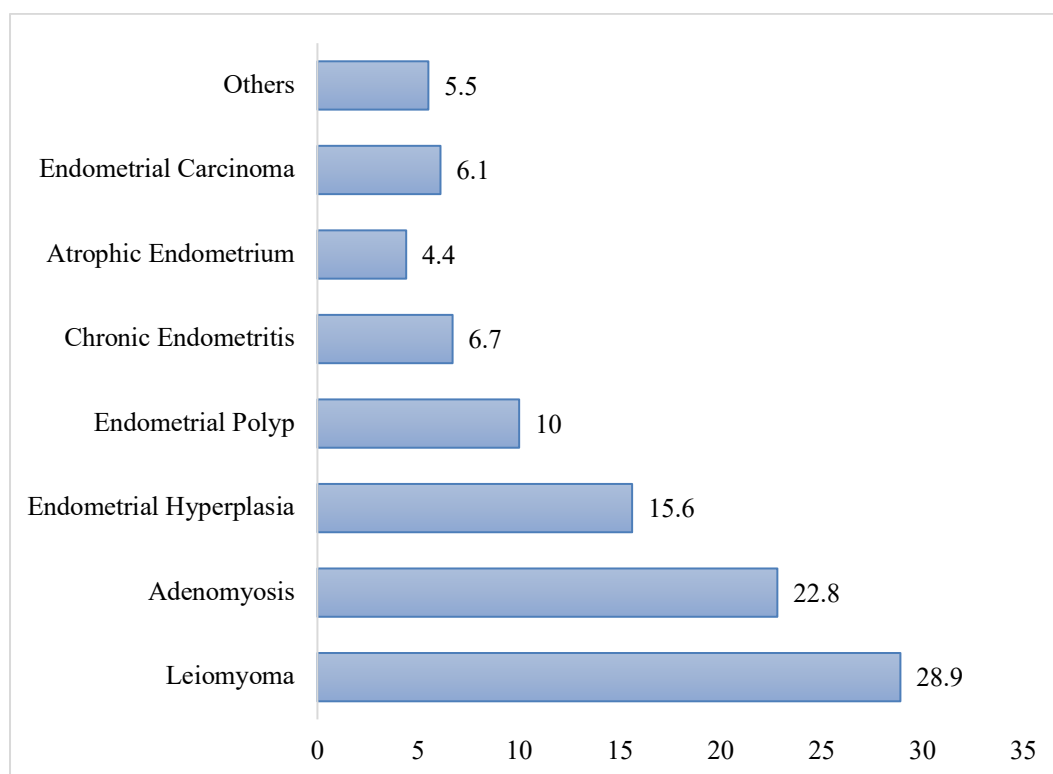


Figure 4: Visual Representation of Histopathological Findings in Hysterectomy Specimens

The study shows that the commonest causes of AUB were leiomyomas and adenomyosis, which made up more than 50% of all hysterectomies conducted. Moreover, the frequent occurrence of endometrial hyperplasia clearly underlines the importance of this disease as a cause of AUB. Malignant tumors like endometrial carcinoma, on the other hand, were rarer, but their existence serves to demonstrate the importance of a proper examination in order to diagnose serious problems. Benign uterine diseases outnumbered malignant

ones significantly in this sample group. Table 5 shows the overall distribution of the different histopathological lesions diagnosed in the 180 subjects of the study population. Largest groups of lesions are the inflammatory ones where 76 (42.2%) participants had inflammatory lesions and the benign ones where 72 (40.0%) participants had benign lesions. In premalignant lesions 21 (11.7%) and in malignant lesions 11 (6.1%) patients were recorded.

Table 5: Distribution of Histopathological Lesions

Lesion Category	Frequency (n)	Percentage (%)
Inflammatory	76	42.2
Benign	72	40.0
Premalignant	21	11.7
Malignant	11	6.1

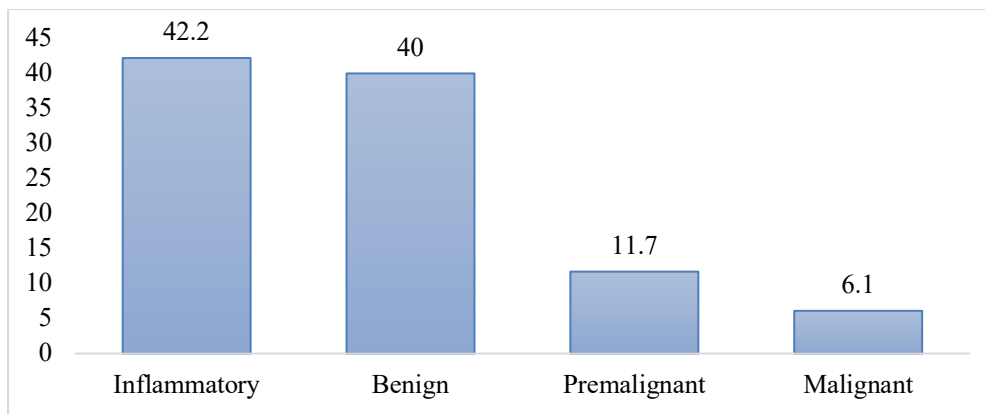


Figure 5: Visual Representation of Distribution of Histopathological Lesions

Results showed that inflammatory and benign lesions were the primary histopathological disorders that were related to the development of abnormal uterine bleeding, contributing to over 80% of the cases observed. In comparison, premalignant and malignant lesions occurred less frequently; nonetheless, the fact that these lesions did occur highlights the need for a histopathological examination to detect any serious condition at its early stage. Generally speaking, it is evident that non-neoplastic lesions are the main causes of abnormal uterine bleeding. Table 6 shows the relation between age group and main

histopathological diagnoses among study subjects. In age group 41-50 years, leiomyoma occurred most frequently with 28 cases, followed by women 40 year and women >50 years with 16 and 8 cases respectively. For adenomyosis, this was the same, in women aged 41-50 years with 23 cases. Endometrial hyperplasia occurred across the age groups, most frequent in women aged 41-50 years with 12 cases, and in women >50 years with 10 cases. Endometrial polyps were evenly distributed among all age groups. Endometrial carcinoma was mainly diagnosed in women >50 years with 8 cases, but none in women aged 40 years.

Table 6: Association between Age Group and Major Histopathological Diagnosis

Diagnosis	≤40 Years	41–50 Years	>50 Years	Total
Leiomyoma	16	28	8	52
Adenomyosis	10	23	8	41
Endometrial Hyperplasia	6	12	10	28
Endometrial Polyp	5	8	5	18
Endometrial Carcinoma	0	3	8	11
Others	33	38	19	90

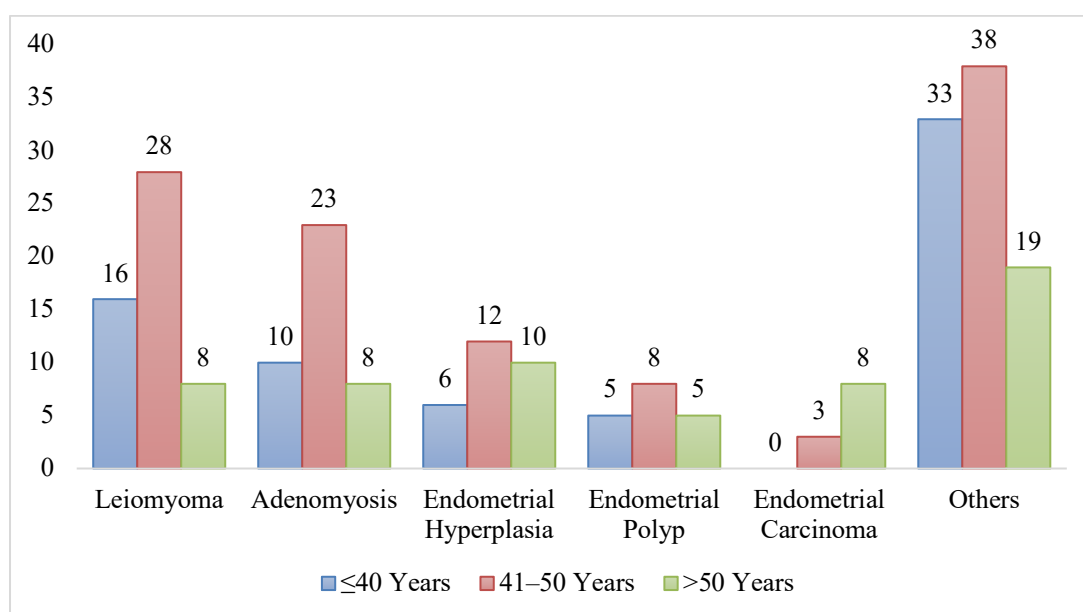


Figure 5: Visual Representation of Association between Age Group and Major Histopathological Diagnosis

The results show that benign lesions of the uterus like the leiomyoma and adenomyosis are more prevalent in women aged between 41 to 50 years old, which indicates an increase in the number of cases associated with the perimenopausal period. However, the malignant lesions of the uterus, especially endometrial carcinoma, occurred mainly in those who were older than 50 years old. This demonstrates the association of age with the frequency of lesions, and stresses the importance of pathological assessment, particularly in cases involving women with abnormal bleeding.

Discussion

The present investigation analyzed the histopathological profile of cases diagnosed with abnormal uterine bleeding in terms of the biopsy results and histopathology following hysterectomy (Shanu, 2016) [16].

The age range of 41-50 years was the most common, and pre-menopausal women dominated the patient pool. The most prevalent form of presenting abnormal uterine bleeding was menorrhagia, suggesting that abnormal menstrual blood loss continues to be the main reason for consulting physicians.

This observation is supported by other literature where similar trends were found among perimenopausal women (Sawke et al., 2015) [17]. According to histopathology results obtained from cervical biopsy, it became clear that the most common lesion is chronic cervicitis and chronic cervicitis with squamous metaplasia (Ghosh et al., 2017) [18].

Thus, it is evident that inflammation is a significant element in the pathology of the cervix in patients who suffer from abnormal uterine bleeding. The pre-cancerous and cancerous lesions were less frequent in occurrence than those already mentioned.

In hysterectomies, the two most commonly diagnosed entities included leiomyoma and adenomyosis, with endometrial hyperplasia as the third most prevalent disorder (Chaitanya, 2016) [19]. The predominance of the inflammatory and benign conditions signifies that non-cancerous pathologies are the leading cause of irregularities in the menstrual cycle. Nevertheless, it is essential to consider that premalignant and malignant entities can be found in patients, especially those of advanced age (Kumar et al., 2017) [20].

Conclusion

The current retrospective study emphasizes the role of histopathology in understanding the etiology of abnormal uterine bleeding in patients. The patients were mostly premenopausal and had the age category between 41-50 years. Most common

clinical presentation was menorrhagia. Chronic cervicitis and chronic cervicitis with squamous metaplasia were the commonest histopathological diagnosis in cervical biopsies, while leiomyoma, adenomyosis, and endometrial hyperplasia were the commonest lesions found in hysterectomy samples. Inflammatory or benign lesions comprised the largest number of diagnoses. However, premalignant and malignant lesions were found to be fewer. It is notable, especially since they have a high incidence rate among women over 50 years. In summary, it becomes clear that cervical biopsy and hysterectomy sample examination are important techniques that help in understanding the pathology associated with abnormal uterine bleeding. Histopathological investigation helps in making an earlier diagnosis of premalignant and malignant lesions among patients with the same complaint.

References

1. Sinha, P., Yadav, N., & Gupta, U. (2018). Use of hysteroscopy in abnormal uterine bleeding: an edge over histopathological examination. *The Journal of Obstetrics and Gynecology of India*, 68(1), 45-50.
2. Patil, H. A., Patil, A., & Mahajan, S. V. (2015). Histopathological findings in uterus and cervix of hysterectomy specimens. *MVP Journal of Medical Sciences*, 2(1), 26-29.
3. Sreedhar, V. V., Jyothi, C., Sailaja, V., Paul, M. C., Sireesha, O., Vani, T., & Kumar, K. M. (2016). Histopathological spectrum of lesions of hysterectomy specimens-a study of 200 cases. *Saudi J Pathol Microbiol*, 1(2), 54-59.
4. Gkrozou, F., Dimakopoulos, G., Vrekoussis, T., Lavasidis, L., Koutlas, A., Navrozoglou, I., & Paschopoulos, M. (2015). Hysteroscopy in women with abnormal uterine bleeding: a meta-analysis on four major endometrial pathologies. *Archives of gynecology and obstetrics*, 291(6), 1347-1354.
5. Firdous, N., Mukhtar, S., Bilal, S., & Beigh, S. K. (2017). Role of hysteroscopy and histopathology in evaluating patients with abnormal uterine bleeding. *International Journal of Reproduction, Contraception, Obstetrics and Gynecology*, 6(2), 615-620.
6. Zaid, S. M. O., & Thabet, M. A. B. (2017). Histopathological findings in hysterectomy specimens: a retrospective study. *Middle East J Intern Med*, 10, 1-8.
7. Nair, S. (2015). *Histopathological Study of Hysterectomy Specimens in Uterus and Cervix* (Doctoral dissertation, Rajiv Gandhi University of Health Sciences (India)).
8. Kumari, A., Pankaj, S., Choudhary, V., Kumari, J., Nazneen, S., Kumari, A., & Kumar, S. (2019). Ultrasonic and histopathological evaluation to exclude premalignant and malignant lesions in perimenopausal and postmenopausal

- women presenting as abnormal uterine bleeding. *The Journal of Obstetrics and Gynecology of India*, 69(Suppl 2), 171-176.
9. Baral, R., Sherpa, P., & Gautam, D. (2017). Histopathological analysis of hysterectomy specimens: one year study. *Journal of Pathology of Nepal*, 7(1), 1084-1086.
 10. Nicholson, R. C., Khunda, A., Ballard, P., Rees, J., & McCormick, C. (2021). Prevalence of histological abnormalities in hysterectomy specimens performed for prolapse. A systematic review and meta-analysis. *International urogynecology journal*, 32(12), 3131-3141.
 11. Makki, J., & hussein Al Khafaj, A. (2021). Endometrial biopsy is an important diagnostic tool for the evaluation of abnormal uterine bleeding. *Journal Port Science Research*, 4(1), 22-26.
 12. Bosco, R. J., & Sarada, V. (2020). Clinicopathological spectrum of hysterectomy specimens in a tertiary care hospital—a review of 82 6 cases. *Trop J Pathol Microbiol*, 6(1), 50-57.
 13. Husain, S., Al Hammad, R. S., Alduhaysh, A. K., AlBatly, M. M., & Alrikabi, A. (2021). Pathological spectrum of endometrial biopsies in Saudi women with abnormal uterine bleeding: A retrospective study of 13-years. *Saudi Medical Journal*, 42(3), 270.
 14. Swathi, G. R. (2017). A Comparative Study of Hysteroscopy and Transvaginal Sonography in Diagnosis of Endometrial Pathology in Abnormal Uterine Bleeding (Master's thesis, Rajiv Gandhi University of Health Sciences (India)).
 15. Sarkar, P., Mikhail, E., Schickler, R., Plosker, S., & Imudia, A. N. (2017). Optimal order of successive office hysteroscopy and endometrial biopsy for the evaluation of abnormal uterine bleeding: A randomized controlled trial. *Obstetrics & Gynecology*, 130(3), 565-572.
 16. Shanu, V. (2016). Histopathological Study of Endometrium in Abnormal Uterine Bleeding (Doctoral dissertation, Rajiv Gandhi University of Health Sciences (India)).
 17. Sawke, N. G., Sawke, G. K., & Jain, H. (2015). Histopathology findings in patients presenting with menorrhagia: A study of 100 hysterectomy specimen. *Journal of mid-life health*, 6(4), 160-163.
 18. Ghosh, S., Chowdhury, A. R., & Chakraborty, S. (2017). Abnormal uterine bleeding: histopathology with clinical correlates in premenopausal vis-a-vis postmenopausal women, with special reference to preoperative diagnostic imaging. *British Journal Of Pharmaceutical And Medical Research*, 2(1), 327-41.
 19. Chaitanya, K. (2016). Comparative Study of Transvaginal Ultrasonography and Hysteroscopy as Diagnostic Modalities in Evaluation of Abnormal Uterine Bleeding (Master's thesis, Rajiv Gandhi University of Health Sciences (India)).
 20. Kumar, A., Sathya, P., & Sampathkumar, S. (2017). Study of hysteroscopic evaluation in patients with abnormal uterine bleeding. *International Journal of Reproduction, Contraception, Obstetrics and Gynecology*, 6(4), 1413-1420.