

**Evaluation of Variables in Laparoscopic Management of Ventral Hernia in Tertiary Care Centre****Pushendra Agarwal<sup>1</sup>, Sushil Kumar<sup>2</sup>, Shiva Kumar<sup>3</sup>**<sup>1</sup>Associate Professor, Department General Surgery, RMC, Jalaun, Orai, Uttar Pradesh, India.<sup>2</sup>Assistant Professor, Department General Surgery, RMC, Jalaun, Orai, Uttar Pradesh, India.<sup>3</sup>Assistant Professor, Department of General Surgery, RMC, Jalaun, Orai, Uttar Pradesh, India.

Received: 04-02-2024 / Revised: 20-02-2024 / Accepted: 21-03-2024

Corresponding Author: Dr. Pushendra Agarwal

Conflict of interest: Nil

**Abstract:**

**Background:** The explosion of video-assisted surgery in past 20 years was a result of the development of compact, high resolution, charged coupled devices that could be mounted on the internal end of flexible endoscopes or on the external end of the Hopkins telescope. Coupled with bright light sources, fibre optic cables, and high-resolution video monitors, the video endoscope has changed our understanding of surgical anatomy and reshaped surgical practice.

**Aims and Objectives:** (1) To evaluate how much overlap of mesh is optimal for the hernia repair. (2) To analyze and evaluate the minimum number of the transfascial stitches for optimal fixation of the mesh with the abdominal wall. (3) To analyze and evaluate the minimum numbers of the tacks for optimal fixation of the mesh with abdominal wall. (4) To analyze and evaluate post-op recovery time, complications and recurrence.

**Methods:** A Prospective study was carried out on patients presenting with complaints suggestive of ventral (incisional) hernia in the Emergency or Outpatients Department of Surgery Rajkiya Medical College (R.M.C.) Jalaun. The study time was between September 2022 to February 2024.

**Observation:** In our study Length of post-op hospital stay is reduced to 2.75 days, operative time is reduced to average 48.5 minutes Vs 60 to 90 minutes in previous studies, In our study, the fixation of mesh is done with absorbable suture (vicryl2-0), prolene 2-0 and tackers, Incidence of enterotomy is 0.5%, seroma formation is reported in 4% of the patients, which is managed conservatively.

**Conclusion:** (1) Requires advance expertise of operating surgeon. (2) Prolene mesh can be placed intra peritoneally, we have not found any post-op complication in total duration of our study. (3) While placing the mesh in preperitoneum only fixation at the four corners of the mesh is required. (4) Mesh fixation can also be done with the absorbable suture even when it is placed IPOM.

**Keywords:** Laparoscopic, Ports, Incisional Hernia.

This is an Open Access article that uses a funding model which does not charge readers or their institutions for access and distributed under the terms of the Creative Commons Attribution License (<http://creativecommons.org/licenses/by/4.0>) and the Budapest Open Access Initiative (<http://www.budapestopenaccessinitiative.org/read>), which permit unrestricted use, distribution, and reproduction in any medium, provided original work is properly credited.

**Introduction**

Although the term minimally invasive surgery (MIS) is relatively recent, the history of its component part is nearly 100 years old. What is considered the newest and most popular variety of MIS, laparoscopy, is in, fact, the oldest. Primitive laparoscopy, by placing a cystoscope within inflated abdomen, was performed by Kelling in 1901. Johann Welfang et al [1]

The explosion of video-assisted surgery in past 20 years was a result of the development of compact, high resolution, charged coupled devices that could be mounted on the internal end of flexible endoscopes or on the external end of the Hopkins telescope. Coupled with bright light sources, fibre optic cables, and high-resolution video monitors, the video endoscope has changed our understanding of surgical anatomy and reshaped surgical practice.

The advantages of minimal access surgery are decrease in wound size, reduction in wound infection, dehiscence, bleeding, herniation and entrapment, decrease in wound pain, improved mobility, decreased wound trauma, decreased heat loss, improved vision.

Despite early controversies regarding surgeon training and complication related to lack of experience with this new technique it has become very popular. This success, as expected, led to the application of laparoscopy to other procedures, though often with less resounding result. Management of ventral hernia is one such rapidly developing field.

**Materials & Materials**

Study was conducted on patients presenting with complaints suggestive of ventral (incisional) hernia in the Emergency or Outpatients Department of

Surgery R.M.C. Jalaun. The study time was between September 2022 to January 2024. All patients were interrogated for a detailed history and were then investigated:

1. Appropriate laboratory studies: Complete hemogram (Hb, TLC, DLC, ESR), Blood sugar.
2. Evaluation of urine routine and microscopic, blood group and serum creatinine.
3. Any other comorbid conditions viz. cough, constipation, obesity, etc.
4. Any other prior surgical procedure done.
5. USG abdomen (optional)

### Methodology

#### Laparoscopic Incisional Hernia Repair

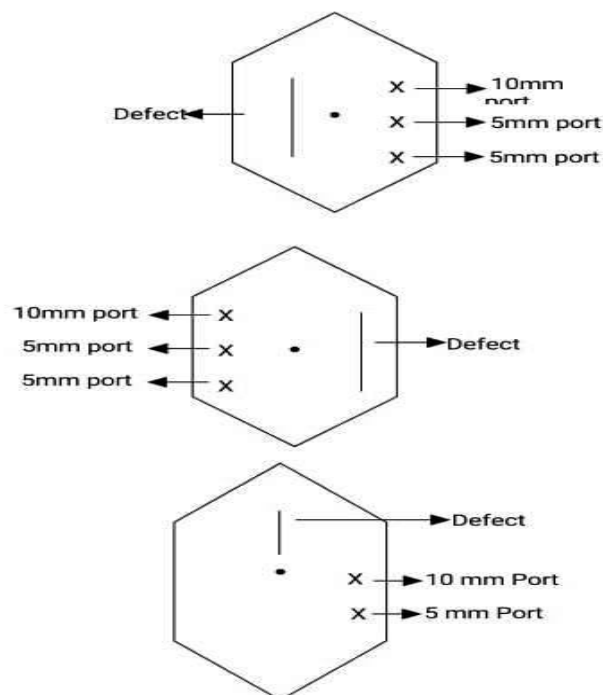
- Position: Supine with slight tilt opposite to the defect.
- Anaesthesia: SA
- Intra-abdominal Pressure: 10-12mmHg

#### Steps

Laparoscopic incisional repair was carried out using lateral port higher up along the anterior axillary line (palmer's point), one 10mm cameraport, one 5 mm working port and one 5mm working port to be placed on the right or left side depending upon site of hernia. Intra-abdominal adhesiolysis was carried out using cautery or harmonic scalpel. The margin of defect was then defined and appropriate mesh selected whose margin would extend at least 3cm beyond the margin of defect on all side. The mesh used was prolene mesh either as intraperitoneal placement or preperitoneal. The fixation of mesh was carried out by multiple 2-0 prolene transfascial suture through anterior abdominal wall using suture carrier and would be supplemented with the use of tacker.

#### Technique

The technique of laparoscopic repair of incisional hernias involves intraperitoneal onlay mesh placement and in selected cases, partial or total extraperitoneal mesh placement. Like most surgical procedures, there are numerous variations described in literature, but surgical principles are constant.



**Our port placements**

#### Initial Access

After pneumoperitoneum is created with veress needle, the 10mm port is inserted at palmer's point higher up in the anterior axillary line. Next 5 mm working port is also inserted 5 cm below the previous port in the anterior axillary line another 5 mm working port is also inserted in the same line 5 cm below the second port.

Sometimes we used only two ports (one 10mm and one 5mm).

#### Adhesiolysis and reduction of Sac Contents

Once the appropriate number of trocars were introduced into the abdomen at adequate locations, adhesiolysis was commenced. Adhesions of the abdominal contents to the hernia sac and the surrounding abdominal wall were lysed and the con-

tents of the hernia reduced.

**Mesh Sizing and placement:** After adequate delineation of all the defects and the scar tissue, the size of the mesh required was assessed. This was done by desufflation of the abdomen after marking the defect on the skin by direct palpation of the defects under laparoscopic guidance. To the measured size of the defect, 3 to 5 cm was added in all directions to provide for overlap in all directions. The mesh configuration was also marked on the abdominal wall and the site for four to six transfascial sutures was marked. The mesh was then rolled and inserted through a 10mm trocar.

**Fixation of Mesh:** The already inserted sutures are then taken out through the fascia at the previously marked site on the abdominal wall through a stab incision, with the help of a fascia closure needle. The suture material was prolene 2-0/ vicryl 2-0.

Alternatively mesh fixation was also done with spiral titanium tacks either exclusively or in combination with sutures.

**Aim of study**

Aims of our study were:

- To evaluate how much overlap of mesh is optimal for the hernia repair.
- To analyze and evaluate the minimum number of the transfascial stitches for optimal fixation of the mesh with the abdominal wall.
- To analyze and evaluate the minimum numbers of the tacks for optimal fixation of the mesh with abdominal wall.
- To analyze and evaluate post-op recovery time, complications and recurrence.

**Results and Observation**

**Patients Demography**

- No. of patients: 40
- Male: Female Ratio: 1:1.86.
- Male: 14 patients.
- Female: 26 patients.
- Age:
- Youngest: 22yrs.
- Eldest: 78yrs.

**Table-1: Age distribution**

Age Groups (in years)	Male	Female
<20	----	----
20-40	04	06
40-60	08	16
>60	02	04

**Total = 40 pts.**

- Type of hernia:
- Paraumbilical Hernia: 18 patients.
- Incisional Hernia: 16 patients.
- Epigastric Hernia: 4 patients.
- Umbilical Hernia: 2 patients.
- Site of port depends on the defect.
- 10mm port is the Camera Port and also for insertion of mesh inside of the abdomen.
- Size of mesh: 6x4 or 6x6 inches according to size of defect.
- Type of mesh: Prolene Mesh/Double layered mesh (used in 3 patients).
- Mesh placement: Onlay Intra Peritoneally (IPOM) - 30 patients.
- Transabdominal preperitoneally (TAPP) – 10 pt.

**Operative:**

- Type of anaesthesia: Spinal Anaesthesia (SA).
- No. of port:
- 3 Ports - 38 patients.
- 2 Ports- 2 patients.

**Table-2: Method of Placement**

Type of hernia	Method of Placement (No. of pts.)	
	IPOM	TAPP
Incisional Hernia	16	----
Paraumbilical Hernia	10	06
Umbilical Hernia	02	01
Epigastric Hernia	02	03
<b>Total</b>	<b>30</b>	<b>10</b>

- Type of suture used for fixation of mesh:
  - Exclusively: 4 patients.
  - With sutures: 6 patients.
- Tack used in: 10 pts.
- Operative time:

- Maximum: 96 minutes.
- Minimum: 22 minutes.
- Average: 48 minutes.
- Operative Blood Loss: Minimal (<15ml)
- Use of drain: None.
- Enterotomy: 1 patient (repaired laproscopically and mesh implantation continued in same setting)

#### Post Operative Parameter

- Use of I/V analgesic – upto 12 hrs.
- Hospital stay: 2.75 days.
- Maximum: 10 days.
- Minimum: 2 days.
- Seroma formation: 2.
- Port site infection: Nil.
- Mesh Infection: Nil.
- Intraperitoneal abscess: Nil.
- Postoperative morbidity: Nil.
- Recurrence: None.
- Relief of symptoms: In all patients.

#### Discussion

Incisional hernia is a complication in 11-20% of patients after laparotomy. These hernias can range in size from very small to large and complex in size from very small to large and complex and near to the area of previous surgical scar. It is especially advised that these hernias be repaired via a tension free repair method.

In the laparoscopic techniques, the mesh is placed in an intraperitoneal location, where the rise in intraabdominal pressure is totally diffused along each square inch of mesh and not along tenuous suture line, as happens in conventional suture repairs. Yahchowky et al found that midline incision have higher rate 10.5% compare to 7.5% with transverse incision and 2.5% with paramedian incision. [2]

The laparoscopic approach also affords the surgeon the ability to clearly and definitively define the margins of the hernia defect and to identify additional defects that may not have been clinically apparent preoperatively.

The discussion on incisional hernia comparing prior studies with my present study will be done under following Heads:

1. Age/Sex.
2. Initial access and No. of ports.
3. Mesh sizing, placement and fixation.
4. Operative time.
5. Suture site pain.
6. Postoperative morbidity.

**1. Age/Sex:** In several prior studies, average age of presentation of ventral hernia was 35-40yrs. No study has shown repair of incisional hernia before puberty. The lowest age in one study conducted by Bruce Ramshaw *et al.*, was 16 yrs. [3] The maximum age in various several studies was 70 yrs. In our study, youngest patient was aged 22 yrs eldest patient was 78 yrs.

In our study females had about 1.86 times higher incidence in comparison to males which is same as conducted by prior studies Toyoshima H *et al* shows the significant increase in female is to male ration approximately 17 times high incidence in female. [4]

**2. Initial access and no of Ports:** This may include Veress needle-closed method or Hasson's technique-open method. More often a Veress needle entry is possible without additional risk, however in some cases of severely scarred abdomen- battlefield abdomen- an open entry is the method of choice. Before commencement of the operation a nasogastric tube may be placed in situ to decompress the stomach and also a urinary catheter if the hernia is located in the lower abdomen. The most preferred site for initial access is the palmer's point-a point 3 cm below the left costal margin in midclavicular line, as one is least likely to encounter intraabdominal adhesions at this point. Alternative sites include the right hypochondrium and the right and left iliac fossae.

- In our study, we used 3 ports (one 10mm ports and two 5mm ports) in 38 patients.
- 2 ports (one 10mm and one 5mm) were used in 2 patients.
- We have accessed the peritoneal cavity by closed method using Veress needle for creating pneumoperitoneum.

**Table 3: No. of ports and configuration**

No. of ports	Configuration	No of patients
3	10,5,5	38
2	10,5	2

**3. Mesh:** Selection of mesh material.

**To choose a prosthesis a framework based on relevant variables may be useful. This should take into Account:**

- The raw material used to make the prosthesis.

- The prosthetic design.
- The technique of implantation.
- The clinical scenario.

#### Raw Material

The raw material is also at play in determining how well an implanted prosthesis functions. These fac-

tors include:

#### Factors associated with prosthetic Performance:

##### 1. Raw material and design:

- Polymer/tissue.
- Strength.
- Elasticity.
- Architecture.
- Pore size.
- Fibre size.
- Density.
- Weave.
- Bioreactivity.

##### 2. Implantation technique:

- Position in relation to structures of the abdominal wall.
- Muscleyayers.
- Ligaments.
- Folding of the prosthesis.
- Fixation method.

##### 3. Clinical situation and host factors:

- Physical activity.
- Obesity.
- Immunogenic response.
- Propensity for infection.
- Need for reoperation.
- Other diseases.

#### Synthetic Non Absorbable Mesh:

**a) Prolene:** By far the most widely used raw material is polypropylene. It is an ethylene with an attached methyl group, and was developed a polymerized in 1954.

To reduce the inflammatory response, yet maintain the benefits of the prosthetic repair, there has been a trend toward lighter weight, more porous polypropylene mesh which are designed to form a “scar net” rather than a “scar plate”.

The biologic response to prolene begins with protein adherence that ultimately envelops the prolene in scar tissue.

Direct contact of the prolene with the abdominal viscera can lead to the bowel obstruction or fistula formation, however the adhesion formation may be independent of the mesh composition, and are more related to the structure of the mesh.

The intensity of the host response is related with the density and coating of the mesh.

**b) Polyester:** It is the common term for the polyethylene terephthalate (PET).

Polyester is hydrophilic and has propensity to swell.

The inflammatory response attracts predominantly macrophages along with neutrophils and is heavily influenced by the adsorbed protein coagulum.

**c) Polytetrafluoroethylene (PTEF):** Discovered in 1938, but comes in clinical use after 1958.

It is relatively compatible with viscera, so its use in TAPP in laparoscopic hernia repair allows to leave the peritoneum open once the mesh is in place.

**Partially Absorbable Prosthesis:** Selection of size was done in the flat abdomen without pneumoperitoneum and then reconfirmed after placing the mesh intraperitoneally that the size is adequate with a 3-4cm overlap. The light mesh had a lower rate of chronic pain and infection and no fistulization compared with other mesh. Cobb et al. [5]

**Method of Introduction of Mesh:** In several studies, introduction of mesh inside the abdomen was done via 10 mm camera port. In few cases where the hernia defect was larger, mesh was introduced inside the abdomen directly through the skin incision.

- In our study, in all cases mesh introduction was via 10mm camera port. In no case mesh was inserted directly through the skin incision overlying the hernia.

**Mesh Placement:** Onlay mesh repairs can be performed with or without primary closure of the fascia. The foremost reason for primary fascial closure with anterior prosthetic reinforcement is that contact between the underlying viscera and the prosthetic material is avoided or minimized.

If the underlay technique is used, the mesh placement can be done in two ways:

- Intraperitoneal onlay mesh placement.
- In this conventional technique, the contents of the hernial sac are reduced and a prosthetic mesh is placed intraperitoneally extending at least 4-5 cm beyond the borders of the fascial defect and held in place by sutures and /or staples. The intra-abdominal pressure and later by the fibrinous growth holds the mesh in place.
- Tansabdominal preperitoneal placement

An alternative laparoscopic ventral hernia repair technique is the inlay method in which the prosthetic mesh is placed and fixed in the preperitoneal space.

This space has been approached,

- Trasnsabdominally (TAPP) or througha
- Totally extraperitoneal approach (TEP).

This new technique takes advantage of immediate mesh fixation by the peritoneal sac and avoids di-

rect interaction of the mesh prosthesis and the intraperitoneal viscera and The TEP avoids the abdominal cavity altogether with the attendant potential complications. It is supposed that formation of adhesions with this technique will be less and thus, it has been suggested to be advancement over the intraperitoneal mesh placement of ventral hernia repair in selected patients.

In our study, we placed the mesh as intraperitoneally onlay or trans-abdominal via preperitoneal route. We did not place any mesh by TEP method. Harral AG, *et al* concluded that formation of adhesion with this technique were less and suggested its advancement over interperitoneal mesh placement for ventral Hernia repair. [6]

**Method of fixation of Mesh:** Minimally invasive (laparoscopic) ventral hernia repair is performed by covering the hernia defect with a sheet of prosthetic mesh, which requires fixation with a combination of staples and anchoring sutures. There are two major issues with this technique: **(1)** sometimes some of the staples need to be removed in order to adjust the mesh position prior to final fixation; and **(2)** anchoring sutures are a source of chronic abdominal wall pain. The proposed device addresses these two issues by employing two types of staples (denoted here as spikes), temporary or permanent; the former spike can be removed easily so that the mesh position can be adjusted, and the latter spike has an anchoring ability which should make anchoring sutures unnecessary.

In one study, conducted in USA, all nine recurrences in 96 patients treated by laparoscopic repair occurred in whom only tacks or staples, rather than sutures had been used. The reported interval distance between sutures varies between 4-5 cm and tackers are inserted between sutures and these probably should be no more than 1 cm apart. Duffy *et al* found that combination of transfixation and transfixing trans abdominal suture with circumferential taking devices was most favourable. [7]

Tackers and staples should be placed every 2 cm. newly developed tackers are absorbable that absorb within one year. Tackers are placed by double crown technique in which first row of tackers are placed 1 cm close to outer margin of mesh and second row of tackers are placed 1 cm away from the outer margin of fascial defect:

- In our study, we used transfascial sutures for fixing the mesh. Initially we used prolene 1-0 but latter on shifted on shifted to vicryl 2-0. The fixation sutures were applied 5cm apart from one another.
- We are placing the mesh in preperitoneal space, the fixation in done only at the four corner of the mesh.
- We also used titanium tackers to fix the mesh approximately 1 cm apart. In four patients we used exclusively tacks.
- Mesh fixation methods:

Table 4

Suture		Tacker	
Prolene	Vicryl	Exclusive	With suture
15	20	4	6

Table 5: Patient details in whom only tacks were used for fixation of the mesh

Type of hernia	Method of placement	Mesh size	No. of tacks
IH	IPOM	6x6(2)	10
IH	IPOM	6x6	13
IH	IPOM	6x6	08
PUH	TAPP	6x6	4

- We never used central aligning suture for mesh fixation.
- In six patients we used tackers with transfascial fixation sutures
- The transfascial fixation sutures have been applied approximately 5cms apart.

#### Discharge Time

- In our study the discharge time is 2.75 days.
- In several studies conducted earlier, discharge time was 3-6 days.
- One patient who came to us with recurrence and infected mesh had the longest stay of 10

days.

- Mishra *et al* found that average discharge time was 3.43 days. [8]

#### Operative Time

The time required for laparoscopic surgery of incisional hernia varied in different studies. Although the time ranges widely from 45 mins to 1½ hrs, the average time for repair was approximately 1 hr.

Our operating time varied between 22-96 minutes with 1 case taking 1 hour 36 minutes time. In this case, the defect was multiple and there were dense adhesions. In our series, patient as a group had

good outcome. The operating time tended to decrease with gaining of experience. The average operative time was 48.5 minutes. White *et al* found average operate time for Laparoscopic Hernia repair was about 68 minutes. [9]

**Intraoperative Complication:** One patient with dense adhesion met with an enterotomy while the adhesiolysis was in progress with cautery. The enterotomy was closed laproscopically and repair procedure completed at the same setting. Karl *et al* from that mortality rate of Laparoscopic Hernia repair was 0.5% - a recognized enterotomy was associated with mortality upto 1.7% and unrecognized enterotomy had a rate of 7.7%. [10]

**Postoperative Morbidity:** One of the greatest benefits of laparoscopic ventral hernia repair is the reduction in wound and mesh infections and hence reduced postoperative morbidity. In a detailed analysis of wound complications from a pooled data of forty-five published series involving 5340 patients Martomena G *et al* [11] reported wound infection rate of 4.6-8 percent times higher in open versus laparoscopic method. The number of mesh infections was also higher with open approaches. An analysis of all series with more than 50 patients indicated a mesh infection rate of 0.69 percent, cellulitis of the trocar site that resolved alone on antibiotics alone, of 1.1 percent. This has led to the widely perceived conclusion that the most compelling argument for laparoscopic repair of ventral hernia is the minimization of soft tissue dissection and the associated reduction in the morbidity, local wound complications and potential infection of the implanted mesh.

- Our study also showed that postoperative morbidity was substantially reduced as claimed by prior studies. Our average hospital stay after laparoscopic repair was 2.75 days. None of the patients had hospitals stay greater than 10 days except one case where the repair is done in two stages. None of our patients had postoperative wound infection except for seroma formation in two cases. There were no mesh infection hence no removal of mesh was required postoperatively in any of the cases.

#### Suture Site Pain

We also observed suture site pain as a minor complication after laparoscopic management of incisional hernias as reported in other series as well. The suture site pain experienced may have originated from tissues or nerve entrapment during placement of tacks or sutures through the full thickness of the anterior abdominal wall. It could also have resulted from traction of the trans-abdominal sutures fixing the mesh to the anterior abdominal wall. According to Scott *et al* patient

undergoing laparoscopic ventral hernia repair with primarily transe abdominal suture or tacks experience similar post operative pain. [12]

However, suture placement is vital to the long term durability of the mesh repair and in none of our cases, we changed our technique except that in prior cases we used prolene 2-0 sutures and later we moved to placement of vicryl 2-0 sutures for mesh fixation. These suture site pains tend to resolve spontaneously within 6-8 wks. without any surgical intervention.

#### Conclusion

- Requires advance expertise of operating surgeon.
- Prolene mesh can be placed intra peritoneally, we have not found any post-op complication in total duration of our study.
- While placing the mesh in preperitoneum only fixation at the four corners of the mesh is required.
- Mesh fixation can also be done with the absorbable suture even when it is placed IP-OM.
- Hernia repair can also be done with 2 ports (One 10 mm and one 5 mm working port).
- Tack alone fixation can be done but it increases the total cost approximately double.

#### Summary

Ventral hernia is a common problem and now most of the cases are managed by laparoscopic repair. In our study of laparoscopic ventral hernia repair we compared the different variables to the data of previous studies. We have found that:

- Length of post-op hospital stay is reduced to 2.75 days.
- Operative time is reduced to average 48.5 minutes Vs 60 to 90 minutes in previous studies.
- In our study, the fixation of mesh is done with absorbable suture (vicryl 2-0), prolene 2-0 and tackers.
- Incidence of enterotomy is 2.5%.
- Seroma formation is reported in 4% of the patients, which is managed conservatively.

#### References

1. Johann Wolfgang, Bernet Verlag *et al*. Laproscopy - The early attempts: spotlighting George Kelling and Hens Christia Jacobaeu. JLS 1997;1(1) 83-5.
2. Yahchowky, Chocrillred E, aura T Picono *et al*. Incisional Hernia relative risk factor Dig Surg 2003;20:3-9.
3. Bruce, Ramshaw, JM *et al*. III: Prospective evaluation of laproscopic and open ventral

- hernia repair JSLs 2007;11:408-14.
4. Toyoshima H. Surgery of Incisional Hernia and its prognosis – statistical analysis in 65 patient) Nippon Geke Sarshi 1986; 87:789-96.
  5. Cobb WS, Kercher KW, Heniford BT. The argument for lightweight polypropylene mesh in hernia repair. Surg Innov 2005;12 (1):63-9.
  6. Harral AG, Nowitsky YW Peindel RD. et al. Prospective evaluation of adhesion formation shrinkage of Intraabdomen as Surg 2006;72(9); 1508-17.
  7. Duffy AJ. Hogle NJ, LaPerle KM, et al. Comparison of two composite meshes using two fixation devices in a porcine laparoscopic ventral hernia repair model. Hernia 2004;8(4):358-64.
  8. Mishra MC, Banshal VK, Kulkarni MP. Comparison of Laparoscopic and open repair of incisional & Ventral Hernia: result of prospective randomized study Surg Endos 2006;20(12): 1839-45.
  9. White TJ, Santos MC, Thomson JS. Factor Affecting wound complication in repair of Ventral Hernia AM Surg 1998; 64:278-80.
  10. Karl Andrew Leblance, Melvine Joseph, James Corder; Enterotomy and Mortality of Laparoscopic Incisional and Ventral Hernia repairer: A review of Literature JSLs 2007;11(4):408-19.
  11. Martomena G, Carlucci Atia et al: Laparoscopic Incisional Hernia repair: our experience and review literature, 2007;11(1):51-6.
  12. Scott Q, Nquogen, Celia M divino: Post-operative pain after Laparoscopic Ventral Hernia repair a prospective comparison of Suture versus tacks JSLs 2008;12(2):113-6.