

**Precision Vs. Tradition: A Comparative Study of Microscopic Lumbar Discectomy versus Open Discectomy in a Tertiary Care Teaching Hospital****Kumar Lakshman<sup>1</sup>, B.G. Sagar<sup>2</sup>, Mir Mohammad Ghulam Ali Khan<sup>3</sup>, Gayatri Brahmandam<sup>4</sup>, Triza Kumar Lakshman<sup>5</sup>**<sup>1</sup>Associate Professor, Department of Neurosurgery, Adichunchanagiri Institute of Medical Sciences<sup>2</sup>Professor and Head, Department of Orthopaedics, Adichunchanagiri Institute of Medical Sciences<sup>3</sup>Junior Resident, Department of Orthopedics, Adichunchanagiri Institute of Medical Sciences<sup>4</sup>Junior Resident, Department of Neurosurgery, Adichunchanagiri Institute of Medical Sciences<sup>5</sup>Professor, Department of OBG, Adichunchanagiri Institute of Medical Sciences

Received: 25-02-2024 / Revised: 23-03-2024 / Accepted: 26-04-2024

Corresponding Author: Dr. Kumar Lakshman

Conflict of interest: Nil

**Abstract:**

**Background:** Fenestration discectomy and open discectomy are commonly performed surgeries for low back pain, which poses a significant health concern for patients of all ages. A key cause of low back pain is lumbar disc herniation, which forms the crux of our study. This study aims to draw a comparison between the two procedures in patients with symptomatic lumbar back pain as a function of pain levels postoperatively, and return to daily activities using the Visual Analogue Scale as a primary outcome measure, Oswestry Disability Index and other secondary outcome measures.

**Methods:** 60 patients aged between 18 to 65 years with lumbar disc herniation at L4-L5, were divided randomly into group A - where 30 patients underwent open discectomy and Group B - where 30 patients underwent fenestration discectomy. All patients were assessed at 24 hours, 2 weeks, 6 months and 2 years postoperatively after surgery using the Oswestry Disability Index and Visual Analogue Scale for pain and ability to return to daily activities.

**Results:** In both groups, all patients had minimal discomfort post-surgery according to the Visual Analogue Scale (24 hours postoperatively: t value - 1.5861, p = 0.118 - not significant). There was no recurrence of disc herniation among both the groups, over the 2-year follow-up period. The mean stay in hospital and time taken to return to daily activities were similar across groups.

**Conclusion:** Given the outcome of our surgery, using a smaller incision is beneficial in many ways, including lesser tissue disruption which in turn leads to lesser post-operative pain, and lesser duration of hospital stay, as noted in our study, both in open and fenestration discectomy.

**Keywords:** Fenestration Discectomy, Open Discectomy.

This is an Open Access article that uses a funding model which does not charge readers or their institutions for access and distributed under the terms of the Creative Commons Attribution License (<http://creativecommons.org/licenses/by/4.0>) and the Budapest Open Access Initiative (<http://www.budapestopenaccessinitiative.org/read>), which permit unrestricted use, distribution, and reproduction in any medium, provided original work is properly credited.

**Introduction**

Low back pain as a health problem poses a significant interruption to both activities of daily living as well as clinical outcomes. [1] The comparison between microscopic fenestration discectomy versus open discectomy provides insights into which approach might offer better results in terms of patient recovery and recurrence rates. [2]

At the centre of our discussion lies the anatomy of the intervertebral disc pathologies which necessitate surgeries such as fenestration discectomy and open discectomy. The intervertebral disc functions to separate the vertebrae from each other and provides the surface for the shock-absorbing gel of the nucleus pulposus. The nucleus pulposus of the disc functions to distribute hydraulic pressure in all

directions within each intervertebral disc under compressive loads. The nucleus pulposus consists of large vacuolated notochord cells, small chondrocyte-like cells, collagen fibrils, and aggrecan, a proteoglycan that aggregates by binding to hyaluronan. Attached to each aggrecan molecule are glycosaminoglycan (GAG) chains of chondroitin sulphate and keratan sulphate. Increasing the amount of negatively charged aggrecan increases oncotic pressure, resulting in a shift of extracellular fluid from the outside to the inside of the nucleus pulposus. The amount of glycosaminoglycans (and hence water) decreases with age and degeneration. The intervertebral discs provide a strong attachment between the vertebral bodies.

Disc herniations are a common manifestation of degenerative lumbar disc disease. They occur early within the degenerative cascade representing the tensile failure of the annulus fibrosus to contain the gel-like nuclear portion of the disc. Several factors in the biology of the intervertebral disc are proposed to contribute to disc herniation. These include reduction in water retention in the nucleus pulposus, increase in the amount of type I collagen within the nucleus pulposus and inner annulus fibrosus, degradation of collagen and extracellular matrix (ECM) materials and upregulation of systems of degradation such as apoptosis, matrix metalloproteinase (MMP) expression, and inflammatory pathways.

According to the location the disc herniations are classified as:

1. Central prolapse (10-15%): Often associated with back pain only. This may present with cauda equina syndrome which is a surgical emergency
2. Posterolateral(paracentral): Most common (75-80%) affects the exiting nerve root at L4-L5
3. Foraminal (far lateral, extraforaminal): Less common (5-10%) affects exiting nerve root

Disc protrusion leads to increased tension over the roots in the posterolateral corner. Increased tension in the posterolateral corner eventually leads to the nucleus pulposus tearing the lamina of annulus and protruding into the canal in the posterolateral region. The exiting nerve root is usually present in this region leading to exiting nerve root compression effects. The disc may sometimes protrude into the extraforaminal space and produce proximal nerve root compression leading to low back pain.

Considering the significance of low back pain and its impact on a patient's quality of life, identifying the most effective and least invasive surgical approach is crucial. [3] This study focuses on functional improvement, pain relief, duration of hospital stay, and return to daily activities and provides a holistic view of patient outcomes, which is essential for informed decision-making by clinicians and patients alike.

However, the absence of clear superiority between open and microscopic techniques in existing literature highlights the need for further research, particularly randomised controlled trials, to establish more definitive evidence regarding the optimal surgical approach for lumbar disc herniation.

In the study, the 2-year follow-up period allows for the assessment of long-term outcomes, including recurrence rates and reoperation rates, which is essential for understanding the efficacy of surgical interventions for this condition.

Overall, the study contributes valuable insights to the field of spine surgery and neurosurgery, helping clinicians make informed decisions about the most appropriate surgical approach for patients with symptomatic lumbar disc herniation.

## Methods

### Study Design and Patients:

**Study Design:** The study design included 60 patients and is a single-centre, prospective, randomised, controlled trial.

1. Patients with low back ache and symptomatic lumbar disc herniation at L4-L5 level presenting to the neurosurgery department at AIMS, B.G. Nagara between April 2021 to April 2023 were selected after fulfilling inclusion and exclusion criteria.
2. Patients were randomly segregated into two groups; Group A: Patients treated with open discectomy, and Group B: Patients treated with fenestration microdiscectomy.

### Methods of Randomization

Dividing patients into two groups, A and B, based on whether their assigned number was odd or even in a straightforward method of randomization. This method helps ensure that both groups are similar in terms of baseline characteristics, reducing the likelihood of confounding variables, influencing the results.

Each group was followed for outcomes and complications by researchers to assess the effectiveness and safety of the interventions being studied.

### Inclusion Criteria

1. Patients with symptomatic L4-L5 disc herniation with failed conservative treatment
2. Age between 18 to 65 years

### Exclusion Criteria

1. Fracture of lumbar vertebra
2. Previous lumbar spine surgery
3. Neuromuscular disorders
4. Patients with foot drop
5. Spondylolisthesis
6. Multi-level disc herniation
7. Recent cardiac event/CVA patient (within 3 months)
8. Grade 4 bilateral Osteoarthritis of the knee joint

### Follow-Up and Outcome Measures

The study's comprehensive approach to assessing outcomes provides valuable insights into the effectiveness and impact of the intervention.

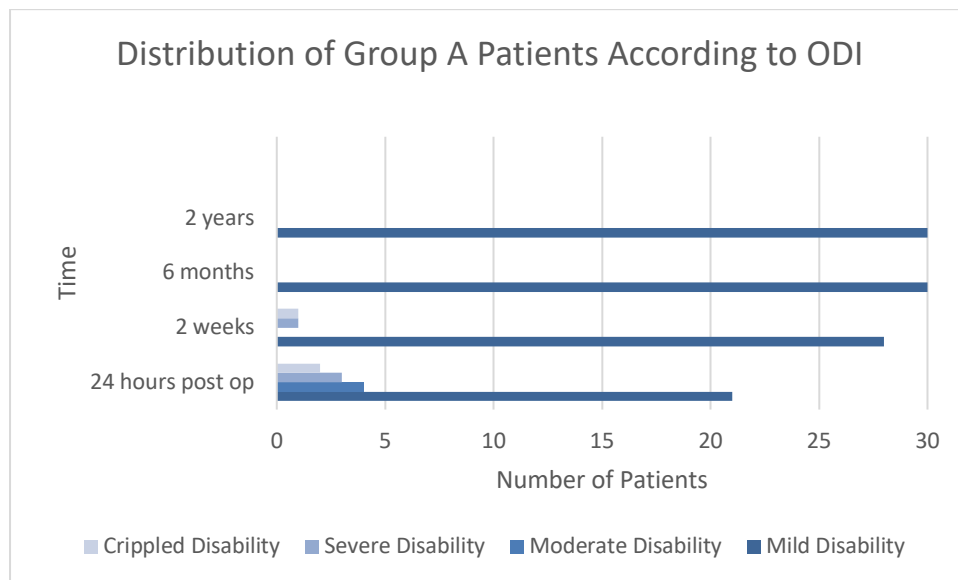
**1. Primary Outcome Measure:** Visual Analog Scale (VAS) for pain: VAS is a subjective measure used to quantify pain intensity. Tracking VAS

scores helps gauge the effectiveness of the surgery in relieving pain, with 10 being unbearable pain and 0 meaning no pain.[4]

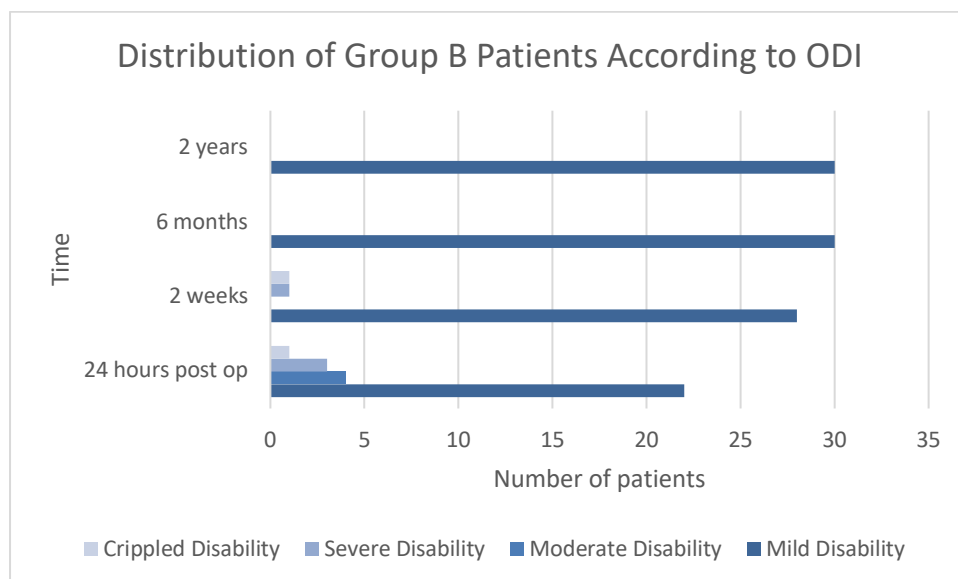
**2. Secondary Outcome Measures:** Oswestry Disability Index (ODI): This index is widely used to assess functional disability related to low back pain. Monitoring ODI scores before and after surgery allows for the evaluation of improvements in

patients' ability to perform daily activities. [5][6] It ranges from a score of 0 to 50.

- 0-4: no disability
- 5-14: mild disability
- 15-24: moderate disability
- 25-34: severe disability
- 35-50: completely disabled



**Figure 1: Distribution of Group A Patients According to ODI**



**Figure 2: Distribution of Group B Patients According to ODI**

- Length of Hospital Stay: This metric reflects the recovery process and the immediate postoperative period.
- Time to Return to Daily Activities: Assessing how soon patients can resume their normal activities providing insights into their overall recovery and functional status.
- Complications (e.g., Infection): Monitoring complications helps gauge the safety profile of

the surgery and identify potential areas for improvement in patient care.

- Reoperation of Disc Herniation: Determining the rate of recurrence provides information on the long-term efficacy of the surgical intervention.
- Rate of Reoperation and Type of Surgery for Recurrent Disc Herniation: This aspect sheds

light on the efficacy of the initial surgical treatment and the need for further interventions.

**3. Follow-up Period:** The two-year follow-up period allows for the assessment of both short-term and long-term outcomes, providing a comprehensive understanding of the intervention's efficacy and durability.

### Intervention

All the surgeries were performed by two senior neurosurgeons. The common steps of surgical intervention are outlined below for both open discectomy for fenestration microdiscectomy for patients with symptomatic lumbar disc herniation at the L4-L5 level:

1. Anaesthesia: Patients in both groups received general anaesthesia.
2. Positioning: The patient is placed in a prone position, lying on Bolsters or on Wilson's frame.
3. Localization: Using a needle marker and fluoroscopy the level of the L4-L5 vertebrae was determined.
4. Incision: A midline incision, approximately 2.5 cm in length, is made over the L4-L5 space. This incision provides access to the spine and facilitates the subsequent steps of the procedure.
5. Dissection of Tissues: Following the incision, the deep fascia (thoracolumbar fascia) is incised. The paraspinal muscles on the symptomatic side are then carefully elevated by subperiosteal dissection.

This process exposes the lamina, a bony structure that forms the posterior aspect of the vertebral arch.

6. Exposure of Lamina: By retracting the paraspinal muscles, visual and physical access to the lamina is obtained.

In Group A, Hemilaminectomy is performed on the affected side using a Kerrison's punch or high speed drill, ligamentum flavum is excised using Kerrison's punch and this exposes the axilla between the cord and roots. The root is gently retracted and a vertical incision is made over the PLL and discectomy is performed using pituitary rongeur.

For Group B, A diamond high-speed drill is used to drill the inferior part of the upper lamina of L4. This creates space to pass a hook under the ligamentum flavum. The ligamentum flavum is incised using a tenotome over the hook, and then part of it is removed using a Kerrison punch. This exposes the nerve root. The herniated disc is exposed using a nerve root retractor, then removed using a rongeur.

7. Hemostasis and Closure: Hemostasis is achieved using bipolar electrocautery. The incision is closed in layers without the use of a drain

### Post-Operative Care

Early patient mobilisation after 24 hours was done in both the groups. Stitches were removed 2 weeks after surgery.

### Data Analysis

Statistical analysis was carried out through SPSS 18 (SPSS, IBM Company, Chicago, USA). Continuous variables were presented as Means  $\pm$  SD. Student t-test was used to compare means between the two groups. Paired t-test was used to compare means. A p-value of  $\leq 0.05$  was considered significant.

### Results

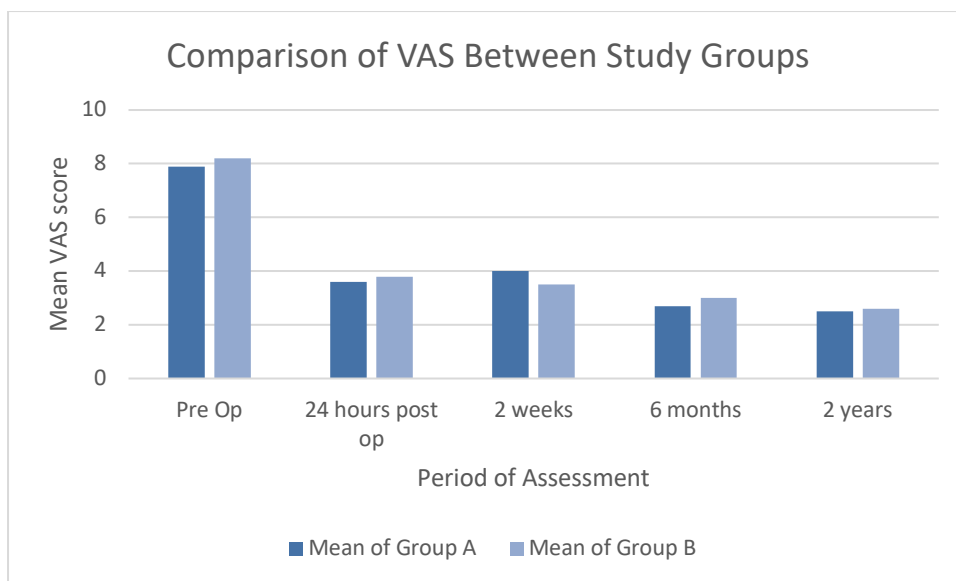
#### Demographic data

In the current study, the mean age of patients was (47.80) years. The younger patient was 28 years old and the older patient was 65 years old.

Regarding gender, the percentage of both males and females is equal between the two groups; 13 males and 17 females in Group A and 16 males and 14 females in Group B.

#### Visual analogue scale

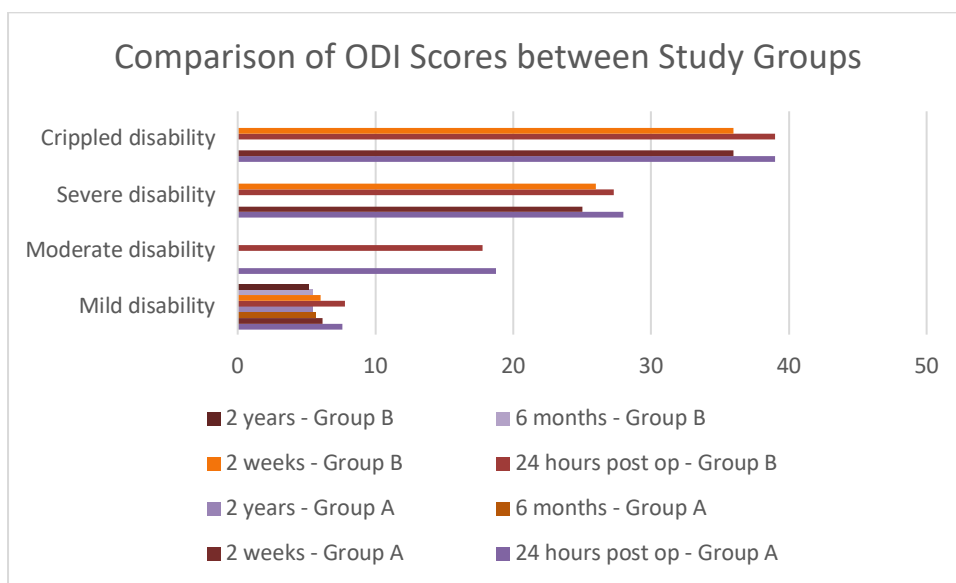
The distribution of group A and group B patients, according to VAS in the pre-operative period, 24 hours post-surgery, 2 weeks, 6 months and 24 months postoperatively is plotted in Graph 3.[7] The comparison of patient in both groups, according to ODI in the pre-operative period, 24 hours post-surgery, 2 weeks, 6 months and 24 months postoperatively is depicted in Graph 4.



**Figure 3: Comparison of VAS Between Study Groups**

The p-value was not significant.

**Oswestry disability index [8]**



**Figure 4: Comparison of ODI Scores between Study Groups**

The P-value was not significant.

**Hospital stay and time of returning to daily activities:** The mean differences in length of hospital stay and time of returning to daily activity between the study groups (Group A and Group B) are shown below.

**Table 1:**

Length Of Stay	Number	Mean (Days)	Standard Deviation
Group A	30	6.33	0.97
Group B	30	5.93	0.89

**Table 2: Return to Daily Activities**

Return To Activities	Number	Mean (Days)	Standard Deviation
Group A	29	10.28	0.726
Group B	28	10.15	0.55

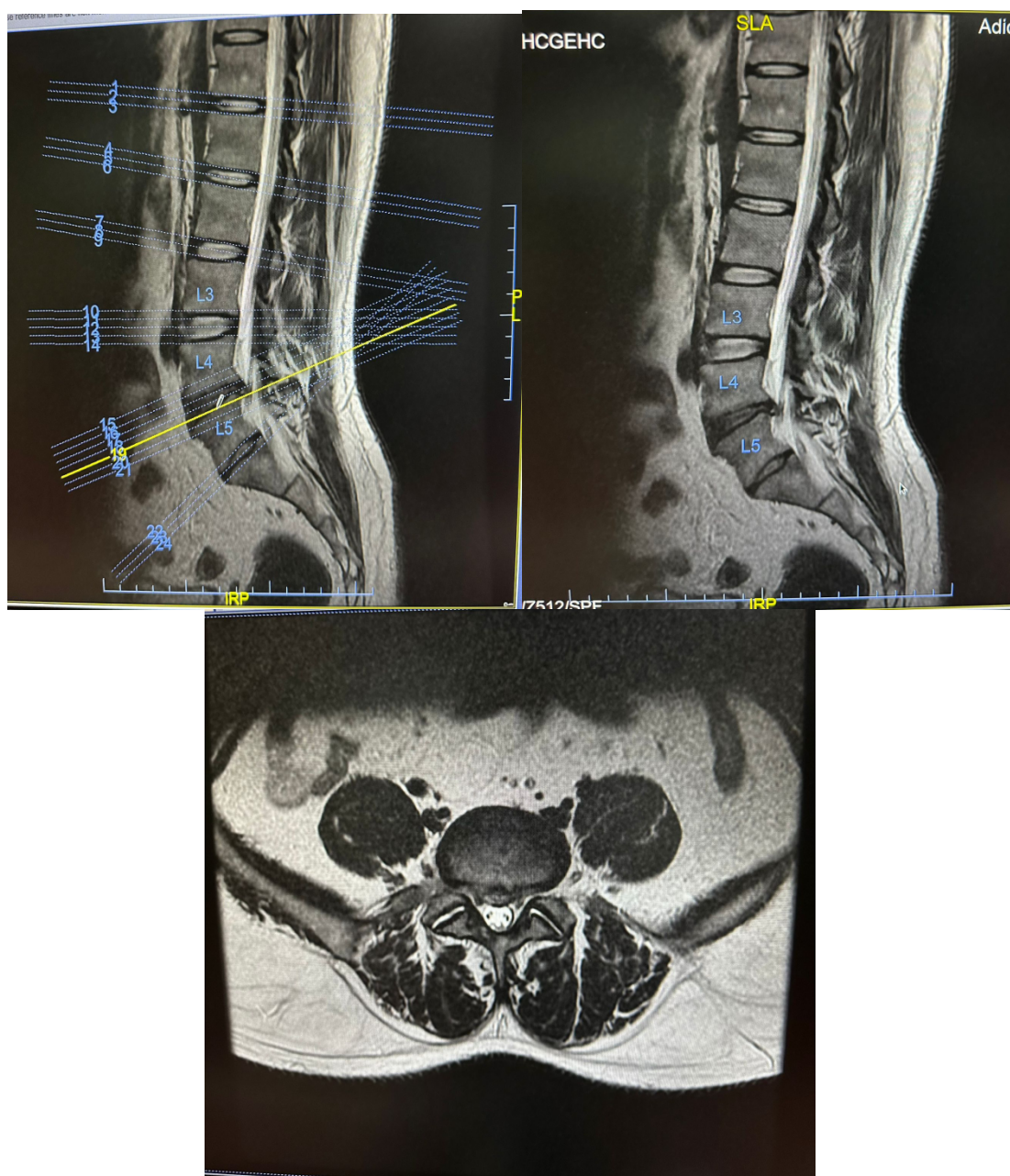
In group A one patient underwent reoperation on POD 1 due to the persistence of radiculopathy and the presence of a remnant disc on repeat MRI scan, and he returned to his daily activities within 14 days.  
 In group B, two patients underwent reoperation on POD 1 due to persistence of radiculopathy and they returned to their daily activities on day 12 and day 15, respectively.

**Table 3:**

	<b>P value</b>	<b>Significance</b>
Duration Of Hospital Stay	0.2492	Not Significant
Return To Daily Activities	0.6068	Not Significant

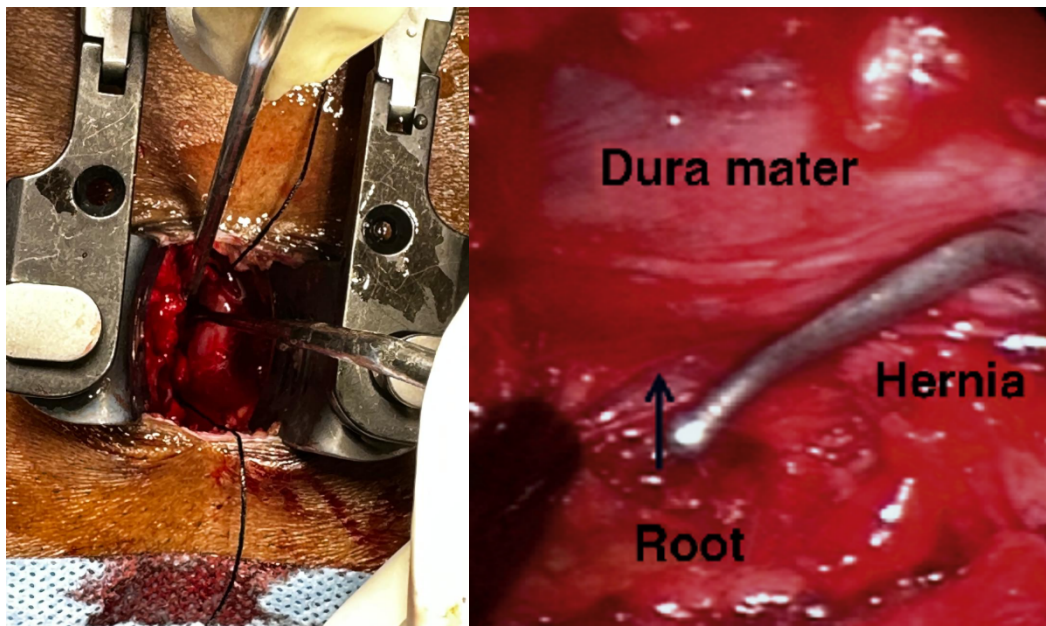
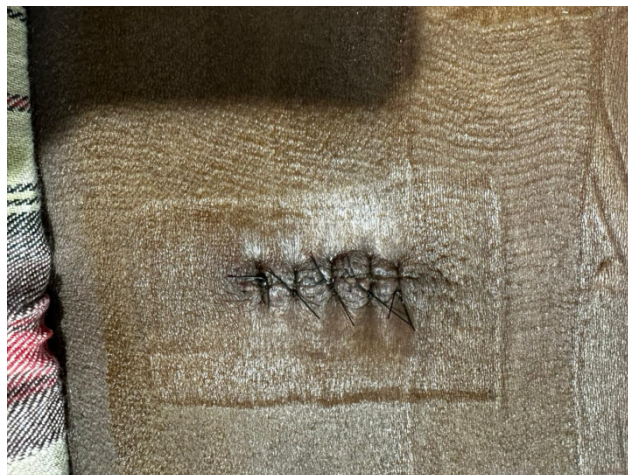**Recurrence:** Recurrent lumbar disc herniation (rLDH) is defined as the presence of new material in the spinal canal, originating from a previously operated disc, either on the same or on the contralateral side, with a pain-free period of at least 6 months after the index discectomy.[9] In our study, no patients had recurrent disc prolapse at L4-L5 levels among both Group A and Group B cohorts over the 2-year follow-up.

**Preoperative Imaging**



**Figure 5**



**Intraoperative Images****Figure 6****Postoperative Images****Figure 7****Discussion**

In our study, there was no significant difference between the means of post-operative VAS among the two groups at 2 weeks ( $t = 1.154$ ,  $P = 0.2581$ ) and at 6 months ( $t = 1.879$ ,  $P = 0.0707$ ) and it is comparable to study conducted by Nozomu et al. [10] This explains that open discectomy or microscopic fenestration discectomy do not have a sizable change in the impact of the back pain either in the early postoperative stage or at 6 months when the size of the incision is similar (2.5cm).

When VAS was compared for pain in each group between preoperative and 4 periods of assessments (multiple comparisons), it was noted that there were significant differences between means of preoperative VAS and postoperative assessments

over four time periods and this explains that discectomy, whether it be open or microscopic, can remove herniated disc fragments and remove the local irritation caused by it. In the postoperative period, we noted a similar VAS in patients both at two weeks post-op as well as at 2 months post-op among both the groups, while according to Sherwan et al, there was a significant difference in postoperative VAS between one week and three months post-operatively among both the groups. This was probably due to variations in the size of the incision. Another noteworthy dissimilarity between our study and a study conducted by Tureyen K. [11], is that the patients treated by the microsurgery group returned to work in less time while patients of both groups in our study returned to work in almost the same time duration ( $t=0.5212$ ,  $P=0.6068$ ). This

could be due to variations in the size of incisions among the two groups in their study. No significant differences in means of the length of hospital stay ( $t= 1.1768$ ,  $P=0.2492$ ) were observed in our study.

When we compare the ODI preoperatively and postoperatively through all periods of assessment in both groups A and B, there is a significant difference which means that both methods of treatment were effective in achieving excellent functional improvement for lumbar disc herniation.

There was no significant difference between means of post-operative ODI among the two groups at 2 weeks ( $t = 0.3899$ ,  $P = 0.6995$ ) and at 6 months ( $t = 0.7592$ ,  $P = 0.4541$ ).

### Conclusion

Using a smaller incision is beneficial in many ways, including lesser tissue disruption which in turn leads to lesser post-operative pain, and lesser duration of hospital stay, as noted in our study, both in open and fenestration discectomy. Performing microscopic fenestration discectomy in treating symptomatic lumbar disc herniation can achieve the same goal as open fenestration in terms of nerve root decompression and relief of pain. We need further larger multicentric randomised clinical trials with larger cohorts to draw more conclusive evidence between open and fenestration discectomy.

### References

1. Yiengprugsawan V, Hoy D, Buchbinder R, Bain C, Seubsman S-A, Sleigh AC. Low back pain and limitations of daily living in Asia: longitudinal findings in the Thai cohort study. *BMC Musculoskelet Disord* [Internet]. 2017; 18(1). Available from: <http://dx.doi.org/10.1186/s12891-016-1380-5>
2. Hamawandi SA, Sulaiman II, Al-Humairi AK. Open fenestration discectomy versus microscopic fenestration discectomy for lumbar disc herniation: a randomised controlled trial. *BMC Musculoskelet Disord* [Internet]. 2020; 21(1). Available from: <http://dx.doi.org/10.1186/s12891-020-03396-x>
3. Sajadi K, Azarhomayoun A, Jazayeri SB, Baigi V, Ranjbar Hameghavandi MH, Rostamkhani S, et al. Long-term outcomes of laminectomy in lumbar spinal stenosis: A systematic review and meta-analysis. *Asian J Neurosurg* [Internet]. 2022; 17(02):141–55. Available from: <http://dx.doi.org/10.1055/s-0042-1756421>
4. Caniklioglu M, Özkaya M. The use of visual analogue scale score as a predicting tool in differentiating renal colic from lumbar back pain. *Cureus* [Internet]. 2021; Available from: [https://assets.cureus.com/uploads/original\\_article/pdf/62143/20210813-17837-m2qes5.pdf](https://assets.cureus.com/uploads/original_article/pdf/62143/20210813-17837-m2qes5.pdf)
5. Fairbank JCT, Pynsent PB. The Oswestry Disability Index. *Spine (Phila Pa 1976)* [Internet]. 2000; 25(22):2940. Available from: [https://journals.lww.com/spinejournal/abstract/2000/11150/the\\_oswestry\\_disability\\_index.17.aspx](https://journals.lww.com/spinejournal/abstract/2000/11150/the_oswestry_disability_index.17.aspx)
6. El Tabl MA, El Sisi YB, Al Emam SE, Hussen MA, Saif DS. Evaluating the outcome of classic laminectomy surgery alone versus laminectomy with fixation surgery in patients with lumbar canal stenosis regarding improvement of pain and function. *Egypt J Neurosurg* [Internet]. 2020; 35(1). Available from: <http://dx.doi.org/10.1186/s41984-020-00087-6>
7. Takahashi H, Aoki Y, Saito J, Nakajima A, Sonobe M, Akatsu Y, et al. Unilateral laminectomy for bilateral decompression improves low back pain while standing equally on both sides in patients with lumbar canal stenosis: analysis using a detailed visual analogue scale. *BMC Musculoskelet Disord* [Internet]. 2019; 20(1). Available from: <https://pubmed.ncbi.nlm.nih.gov/30832643/>
8. Vianin M. Psychometric properties and clinical usefulness of the Oswestry Disability Index. *J Chiropr Med* [Internet]. 2008; 7(4):161–3. Available from: <http://dx.doi.org/10.1016/j.jcm.2008.07.001>
9. Dokponou YCH, Obame FLO, Mouhssani M, El Akroud S, Siba Z, Saad ME, et al. 1318 cross-sectional study of recurrent disc herniation risk factors and predictors of outcomes after primary lumbar discectomy: A STROBE compliance. *Br J Surg* [Internet]. 2023;110(Supplement\_7):znad258.448. Available from: [https://academic.oup.com/bjs/article/110/Supplement\\_7/znad258.448/7254195](https://academic.oup.com/bjs/article/110/Supplement_7/znad258.448/7254195)
10. Ohtomo N, Nakamoto H, Miyahara J, Yoshida Y, Nakarai H, Tozawa K, et al. Comparison between microendoscopic laminectomy and open posterior decompression surgery for single-level lumbar spinal stenosis: a multicenter retrospective cohort study. *BMC Musculoskelet Disord* [Internet]. 2021; 22(1). Available from: <http://dx.doi.org/10.1186/s12891-021-04963-6>
11. Türeyen K. One-level one-sided lumbar disc surgery with and without microscopic assistance: 1-year outcome in 114 consecutive patients. *J Neurosurg Spine* [Internet]. 2003 99(3):247–50. Available from: <https://pubmed.ncbi.nlm.nih.gov/14563140/>