

A Prospective Study on Treatment of Idiopathic Clubfoot by Ponseti Method

Sandeep Rana¹, Sandesh C Patil², Kailash Karur³

¹Consultant Orthopaedic Surgeon, G. S. Multispeciality Hospital, Gurugram, Haryana

²Assistant Professor, Department of Orthopaedics, Shri Atal Bihari Vajpayee Medical College and Research institute, Bengaluru

³Senior Resident, Department of Orthopaedics, Sanjay Gandhi Institute of Trauma and Orthopaedics, Bengaluru

Received: 15-03-2024 / Revised: 27-04-2024 / Accepted: 10-05-2024

Corresponding Author: Dr Kailash Karur

Conflict of interest: Nil

Abstract:

Background: From long time clubfoot has been a clinical challenge to orthopaedic surgeons. It is one of the commonest congenital deformity of the musculoskeletal system in children. Each year more than 1,00,000 babies are born with congenital clubfoot. 80% of which occur in developing countries.

Methods: Data collected from the Department of Orthopaedics, Sanjay Gandhi Institute of Trauma and Orthopaedics, Bengaluru 60 feet in 40 children were treated by the Ponseti method from September 2022 to august 2023. Prospective follow up for a mean duration of 18 months was undertaken. The deformity was evaluated by Pirani score before and after the treatment. At the end of treatment all feet were functionally classified into good, fair and poor.

Results: The average number of casts applied before full correction was 8. 21.66% of the feet needed tenotomy before full correction. 90% of the patients showed good results, 3.3% had fair results and 6.6% of patients had poor results. There was a significant difference in the pre-treatment and post-treatment pirani score values.

Conclusions: Ponseti method of manipulation and plaster casting is very effective to correct club foot deformity.

Keywords: Clubfoot, Ponseti method, Pirani score, Tenotomy.

This is an Open Access article that uses a funding model which does not charge readers or their institutions for access and distributed under the terms of the Creative Commons Attribution License (<http://creativecommons.org/licenses/by/4.0>) and the Budapest Open Access Initiative (<http://www.budapestopenaccessinitiative.org/read>), which permit unrestricted use, distribution, and reproduction in any medium, provided original work is properly credited.

Introduction

Clubfoot occurs in 1:1000 live births and is the most common birth defects of the musculoskeletal system. Majority occur in developing countries. CTEV is characterized by ankle plantar flexion, subtalar inversion and adduction of the hind and forefoot, mid-foot cavus with or without secondary distal internal tibial torsion. The main aim of the treatment is to achieve plantigrade painless, functionally and cosmetically acceptable foot. There are various modalities of treatment like plaster casts by kite to surgical treatment. Previously kite method of manipulation and casting was done. Kite used thumb over the calcaneocuboid joint for manipulation. Abducting the foot with the thumb pressure near the calcaneocuboid joint blocks abduction of the calcaneus and interferes with correction of the heel varus (kites error). Ponseti method used lateral head of the talus as lever for manipulation of the foot. Ponseti method of serial manipulation and casting with limited surgery claims to avoid open surgery in 89% of cases. Cooper and Dietz reviewed Ponseti cases with an average of 30 years of follow up and found that 78% of the patients achieved excellent or good functional and clinical outcomes compared with 85% in a

control group without congenital foot deformity. [1] The stages in Ponseti method of treatment are manipulation by mother, conservative casting, tenotomy and then splinting and observation.

Methods

The study included 40 patients (60 feet) collected from the Department of Orthopaedics, Sanjay Gandhi Institute of Trauma and Orthopaedics, Bengaluru 60 feet in 40 children were treated by the Ponseti method from September 2022 to august 2023

Inclusion Criteria: Children between 7 days to 1 year of age with idiopathic clubfoot.

Exclusion Criteria: Patients aged more than 1 year of age, clubfoot secondary to syndromic involvement, patients that have undergone prior surgical intervention for clubfoot.

Categorization of feet

The feet were then classified into three categories with respect to the severity of the deformity on basis of initial Pirani score.

- Group 1 feet with a Pirani score of 1.5 to 2.5 points
- Group 2 feet with a Pirani score of 3 to 4.5 points
- Group 3 feet with a Pirani score of >5 points.

Technique

Ponseti method is divided into 2 phases.

- Treatment phase during which deformity is corrected by serial casting and tenotomy if required.
- Maintenance phase during which brace is utilized to prevent recurrence.

The treatment phase starts as soon as possible after the birth whenever the skin condition allows

All the patients were evaluated through detailed history and physical examination. In our study, every clubfoot was managed by Ponseti method of treatment. Every clubfoot was scored at each week by Pirani's scoring for hindfoot, midfoot and total score.

Tenotomy was indicated when hindfoot score >1, midfoot score <1 and the head of the talus was covered. The steps in correction are Cavus correction, Correction of adduction and varus, Overcorrection of adduction and varus and lastly Correction of equinus. Cavus is corrected in first 1 or 2 casts. This is done by stabilizing the talus by placing the thumb over the lateral part of its head and elevating the first ray to achieve supination of the forefoot in respect to the midfoot and hindfoot; padded plaster cast is applied in this position. Next adduction is corrected by stabilizing the talus by placing the thumb over the lateral part of its head and holding the supinated foot in abduction and applying the cast. The heel varus and equinus or corrected last and simultaneously. Weekly plasters are applied till we get 70° of abduction in supination. In children, when equinus deformity persisted, it is corrected by percutaneous tenotomy of the achilles tendon under general

anaesthesia in operating room. Tenotomy is done by No 11 blade where in the Achilles tendon is split. After tenotomy the final cast is applied with the foot in 70 degree of abduction and 10-15 degrees of dorsiflexion. This cast is retained for 3 weeks. Tenotomy was done

1. If residual equinus was observed i.e. after the adduction of the foot and the varus deformity of the heel have been corrected.
2. 15 degree dorsiflexion has not been obtained with use of casts.
3. When Hindfoot score >1, Midfoot score <1 and the head of talus was covered.

After that splitting with Dennis Brown splint was done. The splint was applied for 23 hours per day for the first 3 months. After those 12 hours at night and 2 to 4 hour in the middle of the day for a total of 14-16 hours until the child is 3-4 years of age. Once the child started walking CTEV shoes were used. Patients were followed up regularly after the treatment protocol. Final grading of the patients result was done into good, fair and poor.

- Good - patients were labeled as having a good result if Pirani score is 1.5 point or better or if all the deformities get corrected by Ponseti technique alone on final follow up.
- Fair - patients were labeled as having a fair result if additional surgical procedures such as tendon lengthening through an open approach or a posterior release of the ankle and subtalar joint were done to get correction.
- Poor - patients were labeled as having a poor result if Ponseti technique failed to give complete correction of foot even once.
- In this study Wilcoxon signed rank test was used. The Z value was away from zero, therefore the test was significant. There was significant difference between the pretreatment and post treatment Pirani scores

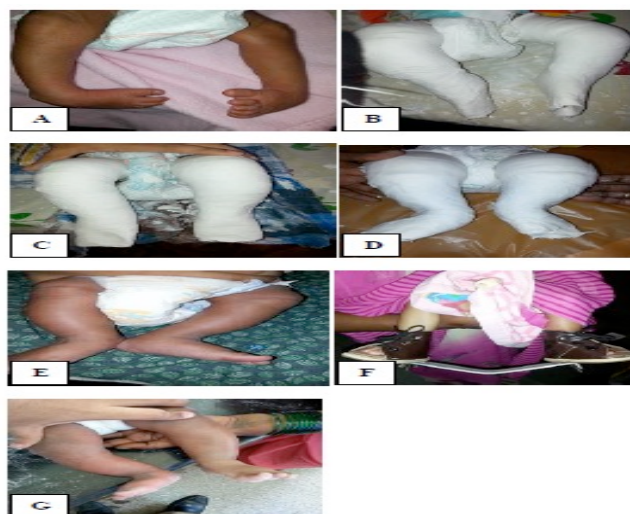

Figure 1: Clinical photographs showing 1.5 months old male baby with bilateral CTEV. (A=Showing feet at initial presentation; B=Cavus correction; C=Correction of adduction; D=Over correction of adduction; E=After correction of adduction, varus and equinus; F=Application of D-B splint and G=At final follow up the feet was fully corrected).

Results

A total of 40 children with 60 feet were treated by Ponseti method and the results were assessed. 16 (40%) were female, 24 (60%) were male. The total mean score at presentation was 5.5. The majority of cases required 6 casts for correction of the deformity. The average duration of cast application was 6 weeks. Tenotomy was required in 13 feet

(21.66%). In the present study 90% (36) of the children showed good results about 3.3% (1) had fair results and 6.6% (3) of patients had poor results showing failure with Ponseti technique. Overall 93.3% of the patients showed satisfactory results. 4 patients had relapsed (10%), 3 were lost for follow up. In case of abrasions and blisters the casting was not done for 1 week and the wound was allowed to heal. In case of slippage, cast was reapplied.

Table 1: Showing the side involvement of clubfoot in our study.

Side involved	Number of children (%)
Right	12 (30)
Left	8 (20)
Bilateral	20 (50)
Total	40

Table 2: Showing the type of feet and their numbers in our study.

Type of feet	Number of feet (%)
Supple	45 (75)
Rigid	15 (25)

Table 3: Showing the number of feet in each group.

Category	Number of feet (%)
Group 1	8 (13.3)
Group 2	40 (66.6)
Group 3	12 (20)

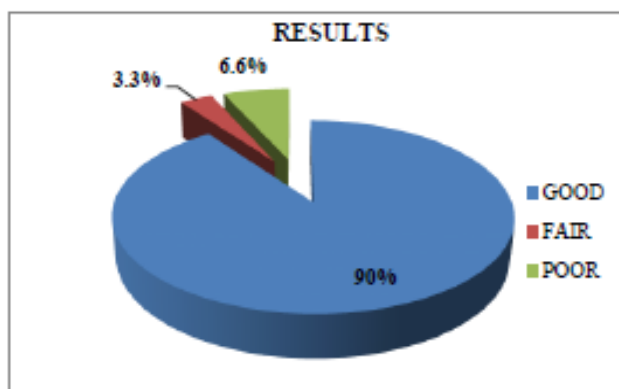


Figure 2: Showing the results of our study.

Table 4: Showing the complications encountered in our study.

Complications	Number of feet
Abrasions	9
Slippage of cast	1
Blister	1

Discussion

Clubfoot is a complex deformity of foot which poses a challenge for the orthopaedic surgeon. The Ponseti method of correction of clubfoot deformity requires manipulation and serial corrective casts with long term brace compliance for maintaining the correction. [2,3,6,7] There are many guidelines and protocols for the treatment. [4-13] The treatment should be started as soon as the skin condition of baby

allows for casting. In our study the male to female ratio is 3:2 in comparison to the series of cowell and wein and yamamoto (m:f3:1). [14,15] Palmer explained that females require more number of predisposing factors to produce clubfoot than males. [16] There are various studies showing that clubfoot occurs in first born baby (65%). [8,10,14-16] The earliest cast applied was at the age of 10 days and maximum age at which a cast applied was 6 months. The number of casts per feet in our study was 6-10

(average 8). In a series by Ponseti et al the number of casts per foot was 5-10 (average 7.6). [4] In study by Laaveg et al, the mean number of casts was 7. [13] Morcuende reported that 90% of the children required less than 5 casts. [17,18] In our study the duration of casts for majority of the feet was 6 weeks. Ponseti et al reported 5 to 12 weeks duration of casts (average 9.5 weeks). [4] In study by Laaveg et al the average duration was 8-6 weeks. [13] Morcuende et al reported an average time from the first cast to tenotomy as 16 days for one group and 24 days for another group in the same study. [17] In our study tenotomy was required in 21.66% of the cases and had initial Pirani score >5. In study carried out by Pirani, tenotomy was done in >90% of patient. Laaveg et al did tenotomy in 78% cases. In our study after serial casting Dennis Brown splint was used. In a study by Thacker et al 44 clubfoot were treated with Ponseti method followed by Steenbeck foot abduction brace. [20] In our study Pirani score become 0 in majority of cases after Dennis Brown splint was used for 8 months. The Ponseti method is an excellent method of treatment of clubfoot. [8-13,15-20] 40 years of follow up in some studies showed that patient treated by Ponseti method are leading a normal life. Ponseti method avoids surgery, gives a painless, mobile, normal looking foot with good mobility. All the institutions are adopting Ponseti method for clubfoot treatment. Proper motivation of patients to accept long term brace treatment helps to maintain the correction over large periods of time and prevents relapse.

Conclusion

Ponseti method is an excellent conservative method for treatment of CTEV deformity. Treatment must be started at the earliest possible age. Number of casts required to achieve full correction increases as the age at presentation increases. The patients who have lower Pirani score at initial visit respond better and faster to the treatment as compared to those who have high Pirani score at initial visit. Early results of treatment of idiopathic CTEV by Ponseti technique results in very good correction of the deformity with minimal surgery i.e. percutaneous Tenotomy of heel cord.

References

1. Cooper DM, Dietz FR. Treatment of idiopathic clubfoot: a thirty-year follow-up note. *J Bone Joint Surg Am.* 1995; 77:1477-89.
2. Ponseti IV. The Treatment of Congenital Clubfoot. *J Orthop Sports Phys Ther.* 1994;20 (1):1.
3. Ponseti IV. Treatment of Congenital Clubfoot. *J Bone Joint Surg Am.* 1992;74(3):448-54.
4. Ponseti IV, Smoley EN. Congenital Clubfoot: The Results of Treatment. *J Bone Joint Surg Am.* 1963;45(2):2261-75.
5. Jekel F, Ktazl D, Elmore G. *Epidemiology, Biostatistics and Preventive Medicine.* 2nd edition. W.B. Saunders Company. 2001; 173:177.
6. Ponseti IV. Correction of the Talar Neck Angle in Congenital Clubfoot with Sequential Manipulation and Casting. *IOWA Orthop J.* 1998; 18:74-5.
7. Ponseti IV. Clubfoot Management. *J Pediatr Orthop.* 2000;20(6):699-700.
8. Brand RA, Laaveg SJ, Crowninshield RD, Ponseti IV. The center of pressure path in treated clubfoot. *Clin Ortho Prelat Res.* 1981; 160:43-7.
9. Colburn M, Williams M. Evaluation of the treatment of idiopathic clubfoot by using the Ponseti method. *J Foot Ankle Surg.* 2003; 42 (5):259-67.
10. Cooper DM, Dietz FR. Treatment of idiopathic clubfoot: a thirty-year follow-up note. *J Bone Joint Surg Am.* 1995;77(10):1477-89.
11. Herzenberg JE, Radler C, Bor N. Ponseti versus traditional methods of casting for idiopathic clubfoot. *J Pediatr Orthop.* 2002;22 (4): 517-21
12. Ippolito E, Farsetti P, Caterini R, Tudisco C. Long-term comparative results in patients with congenital clubfoot treated with two different protocols. *J Bone Joint Surg Am.* 2003; 85(7):1286-94.
13. Laaveg SJ, Ponseti IV. Long-term results of treatment of congenital clubfoot. *J Bone Joint Surg Am.* 1980;62(1):23-31.
14. Cowell HR, Wein BK. Genetic aspects of clubfoot. *J Bone Joint Surg Am.* 1980;62(8): 1381-4.
15. Yamamoto H. A clinical, genetic and epidemiologic study of congenital clubfoot. *Jinrui Idengaku Zasshi.* 1979;24(1):37-44.
16. Palmer RM. Genetics of Talipes equinovarus. *J Bone Joint Surg Am.* 1964; 46:542-56.
17. Morcuende JA, Abbasi D, Dolan LA, Ponseti IV. Results of an accelerated Ponseti protocol for clubfoot. *J Pediatr Orthop.* 2005;25 (5): 623-6
18. Morcuende JA, Dolan LA, Dietz FR, Ponseti IV. Radical reduction in the rate of extensive corrective surgery for clubfoot using the Ponseti method. *Pediatrics.* 2004;113(2):376-80
19. Scher DM, Feldman DS, Van Bosse HJ, Sala DA, Lehman WB. Predicting the need for tenotomy in the Ponseti method for correction of clubfeet. *J Pediatr Orthop.* 2004;24(4):349-52
20. Thacker MM, Scher DM, Sala DA, Van Bosse HJ, Feldman DS, Lehman WB. Use of the foot abduction orthosis following Ponseti casts: is it essential? *J Pediatr Orthop.* 2005; 25(2):225-8