

## Study on the Specificity and Sensitivity of Ultrasonography in the Diagnosis of Acute Right Lower Quadrant Pain in Fertile Women

Navneet Ranjan Lal<sup>1</sup>, Shamrendra Narayan<sup>2</sup>, Gaurav Raj<sup>3</sup>

<sup>1</sup>Senior Resident, Department of Radiology, Dr. Ram Manohar Lohia Institute of Medical Sciences, Lucknow, UP

<sup>2</sup> Professor Junior Grade, Department of Radiology, Dr. Ram Manohar Lohia Institute of Medical Sciences, Lucknow, UP

<sup>3</sup> Professor and Head of Department, Department of Radiology, Dr. Ram Manohar Lohia Institute of Medical Sciences, Lucknow, UP

Received: 10-01-2024 / Revised: 13-02-2024 / Accepted: 10-03-2024

Corresponding Author: Dr. Navneet Ranjan Lal

Conflict of interest: Nil

### Abstract:

**Background:** One of the most typical presentations in surgical and gynecological crises is RLQ discomfort. When thinking about the organs in the belly and pelvis that can cause pain that is referred to the pelvis, one must also think about the diseases that start in specific viscera. The purpose of the study is to evaluate the sensitivity and specificity of ultrasonography in identifying the underlying causes of acute discomfort in the right lower quadrant in women who are or may become pregnant, using the results of surgery as the gold standard.

**Methods:** The descriptive analytical study was conducted at Department of Radiology, Dr. Ram Manohar Lohia Institute of Medical Sciences, Lucknow, U.P. from July 2023 to December 2023 and comprised female patients of child-bearing age who presented with acute right lower quadrant pain and underwent surgery after ultrasonography. SPSS 10 was used for statistical analysis.

**Results:** Of the 75 patients, 54(72%) patients were symptomatically and sonographically positive to have either acutely inflamed non-compressible appendix or focal fluid collection in right lower quadrant with normal pelvic viscera. Sensitivity of 94% and specificity of 84% were calculated.

**Conclusion:** In order to prevent unnecessary surgical operations, ultrasound is a useful diagnostic technique in emergency settings due to its high sensitivity and specificity.

**Keywords:** Ultrasonography, Specificity, Sensitivity, Right lower quadrant, pain.

This is an Open Access article that uses a funding model which does not charge readers or their institutions for access and distributed under the terms of the Creative Commons Attribution License (<http://creativecommons.org/licenses/by/4.0>) and the Budapest Open Access Initiative (<http://www.budapestopenaccessinitiative.org/read>), which permit unrestricted use, distribution, and reproduction in any medium, provided original work is properly credited.

### Introduction

It is an established fact that appropriate treatment of any pathological condition is dependent on appropriate diagnosis made on the basis of history, clinical examination and laboratory/radiological investigations. Cost-effectiveness is an important factor in our country and, hence, targeted investigations should be ordered.

Unfortunately, one-third of all cases of abdominal pain and a quarter of cases of right iliac fossa pain urgently admitted to hospital leave hospital with no precise diagnosis. [1] In such cases, imaging studies play a significant role in pre-operative diagnosis and determination of proper treatment. [2]

Among the imaging studies, ultrasonography (USG) has become an important tool which can efficiently recognize patients with possible life-threatening conditions of different origins. [3] Most patients presenting with right lower quadrant

(RLQ) pain are clinically suspected to have acute appendicitis and ultrasonography is useful in making alternative diagnoses. [4] Similarly, ultrasound is an established imaging tool not only for gynaecological diseases but it is also a useful modality for diagnosing non-gynaecological disorders that cause acute RLQ pain. [5] Such pain may be the manifestation of various disorders from less alarming rupture of the follicular cyst to life-threatening rupture of ectopic pregnancy. [6]

Ultrasonography is a non-invasive and cost-effective technique carrying no risk to the patient. After thorough literature and Medline search, it was found that very little work has been done in our country on the subject. The current study was planned to assess the sensitivity and specificity of ultrasonography in differentiating causes of acute RLQ pain in women of child-bearing age by taking surgical outcome as the gold standard.

## Material and Methods

The descriptive analytical study was conducted at the Radiology Department of Dr. Ram Manohar Lohia Institute of Medical Sciences, Lucknow, U.P. from July 2023 to December 2023. Those included were women between 20 and 40 years of age regardless of their marital status who presented with acute RLQ pain and underwent surgery after ultrasonography. Those who refused surgery or did not come back with postoperative or histopathological findings were excluded, and so were those who were morbidly obese with poor echo window. Informed consent was obtained from all those who volunteered to participate.

Detailed history was taken from all patients, especially regarding the marital status, duration of pain and associated symptoms. Menstrual cycle regularity and last menstrual period (LMP) were also documented.

USG examination was performed first with 3.5 megahertz curvilinear transducer and then with 7-10 megahertz linear transducer. All possible causes were evaluated by thoroughly examining all organs

of RLQ. Ultrasonographic findings with possible diagnosis were recorded in every patient proforma containing relevant information.

Postoperative findings were checked and recorded from the operating surgeon/from patient follow-up proforma by contacting the patient on telephone. Data was analysed using SPSS 10. Frequency and percentages were computed for calculating sensitivity and specificity of USG by taking surgery as the gold standard. The positive predictive values (PPVs) and negative predictive values (NPVs) were also calculated using the formulae:

$$PPV = TP/TP+FP$$

$$NPV = TN/FN+TN$$

For the purpose of the study, true positive (TP) was 'positive both sonographically and surgically'; false positive (FP) was 'positive sonographically and surgically negative'; false negative (FN) was 'negative sonographically and surgically positive'; and true negative (TN) was 'negative both sonographically and surgically' (Table-1).

**Table 1: Positive and negative predictive values**

| Groups              | Surgically +ve | Surgically -ve |
|---------------------|----------------|----------------|
| Ultrasonography +ve | TP (54)        | FP (4)         |
| Ultrasonography -ve | FN (3)         | TN (14)        |

- TP = True Positive
- FP = False Positive
- TN = True Negative
- FN = False Negative

Frequency and percentages were computed for calculating sensitivity and specificity of USG by taking surgery as gold standard. The positive predictive value (PPV) and negative predictive value (NPV) were also calculated using the formulae given below:

$$PPV = TP/TP+FP$$

$$NPV = TN/FN+TN$$

## Results

Of the 75 patients, 54(72%) were TP, and 35(47%) of them showed either acutely inflamed non-compressible thickened blind ending appendix or had focal fluid collection along with probe tenderness in RLQ with sonographically normal pelvic viscera, and 28(37%) were unmarried. In the remaining 19(25%) patients, 5(7%) had ectopic

pregnancy with a typical history of missed cycle along with a positive pregnancy test, and 12(16%) had ovarian cysts. Three (4%) of these 12 had torsion surgically not picked up sonographically, 5(7%) had ruptured ovarian cysts, and 4(5%) had simple ovarian cysts.

Besides, 4(5%) of the total 75 patients were on treatment for infertility, had lower abdominal discomfort, sonographically had cystic lesion right adnexal region with small pockets of free fluid in right iliac fossa (RIF)/pelvis. On USG, they only proved to be ovarian hyper stimulation syndrome (OHSS) and no ectopic evidence was found on surgery. Three (4%) of the total patients were unmarried and sonographically normal, but were found to have acute appendicitis on surgery. Finally, 14(19%) of the total 75 patients did not have any positive finding on USG, but underwent surgery due to strong clinical indication. There were no positive findings on surgery as well (Table-2).

**Table 2: Diagnosis distribution**

| No. of cases | U/S findings       |
|--------------|--------------------|
| 35           | Acute appendicitis |
| 5            | Ectopic pregnancy  |
| 9            | Ovarian cyst       |
| 3            | Endometrioma       |

|    |              |
|----|--------------|
| 2  | Dermoid      |
| 4  | OHSS         |
| 17 | Normal Study |

## Discussion

RLQ pain is one of the commonest presentations in surgical and gynaecological emergencies. When one considers the organs located in the pelvis and abdomen whose pain may be referred to the pelvis, one has to consider the diseases originating from certain viscera.

Given such a vast differential diagnosis, the key investigative tool is ultrasound. In the emergency department setting, ultrasound is the best initial imaging modality for evaluation of pelvic pathology due to its low cost, easy accessibility, wide spread availability and lack of ionising radiation. [8] Acute appendicitis, though a common cause of acute RLQ pain, may be mimicked by a range of gynaecological pathologies in women of reproductive age. The most commonly encountered are ovarian cyst rupture or torsion, haemorrhage into an ovarian cyst, hydrosalpinx or pyosalpinx, endometriosis and ectopic pregnancy. Thus, ultrasound evaluation of this subgroup

of patients presenting with RLQ pain is very important as faulty diagnosis results in undue surgical intervention, negative surgeries and at times a number of complications such as adhesions. These can be one of the causes of infertility. This reduces possible physical and mental trauma to the patient and surgical complications. The data augments other studies suggesting the same that undue surgeries are associated with an increased risk of infertility, perinatal mortality and morbidity. [9-12]

In order to improve the diagnostic accuracy, different aids were introduced like computer-aided programmes, different scoring systems, gastrointestinal tract (GIT) contrast studies, computed tomography (CT) scan, USG, magnetic resonance imaging (MRI) and laparoscopy.

Among these modalities, USG is the simplest, easily available, non-invasive, convenient and cost-effective tool. USG in the diagnosis of acute appendicitis was first popularised in 1986, a hundred years after the publication of first paper on acute appendicitis. [13,14] The study reported sensitivity of 89% and specificity of 100% in the diagnosis of acute appendicitis. Many other workers later on reproduced the same findings [15-20] and the results of the current study are also comparable. Overall, sensitivity of 94% and specificity of 84% were recorded in our study which is comparable to studies reporting sensitivity of 75-89%, specificity of 95%, PPV of 93% and NPV of 23%. [11,12]

The advantages of ultrasound in this patient population are well accepted. It is quick, readily available and noninvasive [21-24] and reduces the number and need of surgeries in patients with RLQ pain along with physical and psychological trauma that the patients go through.

In a prospective study done in Qasur, Pakistan, on a total of 44 patients presenting with acute abdominal pain and also having some gynaecological problems, despite clinical assessment and routine laboratory investigations, erroneous diagnosis were made because of lack of experience and limited diagnostic facilities. Wound infection and delayed wound healing were among the most common postoperative complications. Mortality occurred in ectopic pregnancy (16.66%) and pelvic inflammatory disease (PID) (5.55%). The study concluded that surgeons often fall in this un-wary trap because of close resemblance of clinical features, less exposure to gynaecological problems and non-availability of more sophisticated diagnostic tools in emergency. [25] Another study was conducted at Sheikh Zayed Hospital in Lahore and included 105 female patients aged 15-45 having presented in emergency department with RIF pain.

Diagnosis was clinical in all cases along with lower abdominal ultrasound scan to improve diagnostic accuracy; the rate of negative appendectomy was 22.9%. [26] The results of the study are comparable and reinforce the results of the current study which also emphasise that good clinical judgment and routine use of USG is desirable to reduce the negative rate. One study described the usefulness of colour Doppler also. Doppler signals disappear when gangrene or perforation occur. [26]

A cohort observational study was done that compared the adverse outcome in two different groups of patients admitted with suspected acute appendicitis at two different hospitals in two different countries. [27] The first group of 200 patients at Ayub Teaching Hospital, Abbottabad, Pakistan, was managed without preoperative USG. In the second group of 200 patients admitted at Najran General Hospital Najran, Saudi Arabia, graded compression abdominal USG was routinely performed preoperatively. Diagnostic accuracy of the protocol in each group was measured statistically and rates of negative appendectomy and perforation were determined.

Addition of routine USG in clinical assessment for acute appendicitis decreases the sensitivity but significantly increases the specificity of the protocol, thereby reducing the FP rate translating

into decreased negative appendectomy rate. Proper clinical assessment is the mainstay of diagnosis in acute appendicitis and addition of routine ultrasound by graded compression technique can improve the diagnostic accuracy and reduce adverse outcome. [28] The same results are shown by our study. Because of USG's sensitivity and specificity, its efficacy in diagnosing acute appendicitis in non-gravid patients has been reported as more than 90%. [29]

One study in a similar setting concluded that use of graded compression USG as preoperative diagnostic technique has a good sensitivity (84.3% and 81.81%) but poor specificity, implying that

value of USG may remain unclear in reducing the negative appendectomies.[30] In 2000, the International Commission on Radiological Protection recommended that if the dose for the foetus was expected to be high, the clinician should attempt to make a diagnosis without using ionising radiation.[31] Thus, to avoid faulty diagnosis and undue surgeries, USG should be performed in every affected case as the first-line investigation.

Ultrasound is quick, readily available and non-invasive, and it is also extremely user-dependent. The only thing needed is to develop expertise in this field so that patients in Pakistan can derive benefit from this.

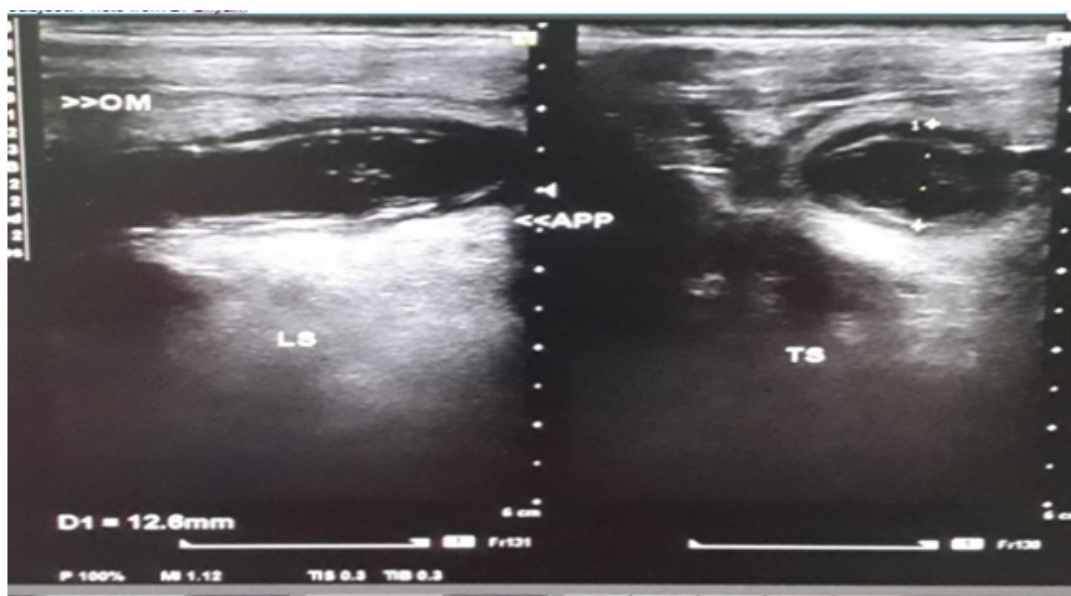


Figure 1:

22yr/Female showing blind ended tubular non-compressible structure (having cross sectional diameter of 12.6mm) near the base of caecum in RIF with mild periappendicular fluid s/o - acute appendicitis

### Conclusion

With sensitivity and specificity of 94% and 84% respectively, USG justified its usage as a good diagnostic tool in emergency situations to avoid undue surgical interventions.

### References

- Groebli Y, Deruaz C, Merlini. M. Outcome of nonspecific right iliac fossa pain syndromes. *AnnChir.* 1998; 52: 959-64.
- Jain KA, Ablin DS, Jeffrey RB, Brant. WE. Sonographic differential diagnosis of right lower quadrant pain other than appendicitis *Clin Imaging.* 1996; 20: 12-6.
- Kupescic S, Aksamija A, Vucic N. Ultrasonography in acute pelvic pain. *Acta Med Croatica.* 2002; 56: 171-80.
- Gaensler EH, Jeffrey RB Jr, Laing FC, Townsend RR. Sonography in patients with suspected acute appendicitis: value in establishing alternative diagnoses. *AJR Am J Roentgenol.* 1989; 152: 49-51.
- Bau A, Atri M. Acute female pelvic pain: ultrasound evaluation. *Semin Ultrasound CT MR.* 2000; 21: 78-93.
- Andolsek KM. Ectopic pregnancy: 'classic' vs common presentation *J FamPract.* 1987; 24: 481-5.
- Heston Thomas F. "Standardizing predictive values in diagnostic imaging research". *J MagnReson Imaging.* 2011; 33: 505-7.
- Yitta S, Mausener VE, Kim A. Pelvic ultrasound immediately following MDCT in female patients in abdominal/ pelvic pain: Is it always necessary? *EmergRadiol.* 2011; 18: 371-80.
- Puylaert JB, Rutgers PH, Lalisang RI. A prospective study of ultrasonography in the diagnosis of appendicitis. *N Engl J Med.* 1987; 317: 666-9.

10. Jeffrey RB Jr, Laing FC, Townsend RR. Acute appendicitis: Sonographic criteria based on 250 cases. *Radiology*. 1988; 167:327-9.
11. Schulte B, Beyer D, Kaiser C, Horsch S, Wiater A. Ultrasonography in suspected acute appendicitis in childhood - Report of 1285 cases. *Eur J Ultrasound* 1998; 8: 177-82.
12. Ramachandran P, Siviti CJ, Newman KD, Schwartz MZ. Ultrasonography as an adjunct in the diagnosis of acute appendicitis: A four-year experience. *J PediatrSurg* 1996; 31: 164-7.
13. Franke C, Böhner H, Yang Q, Ohmann C, Röher HD. Ultrasonography for the diagnosis of acute appendicitis: results of a prospective multicenter trial. *World J Surg*. 1999; 23: 141-6.
14. Seal A. Appendicitis: a historical review. *Can J Surg*. 1981; 24: 427-33.
15. Puylaert JB. Acute appendicitis: US evaluation using graded compression. *Radiology*. 1986;158: 355-60.
16. Chan I, Bicknell SG, Graham M. Utility and diagnostic accuracy of sonography in detecting appendicitis in a community hospital. *Am J Roentgenol*. 2005; 184: 1809 -12.
17. Rettenbacher T, Hollerweger A, Macheiner P, Gritzmann N, Daniaux M, Schwamberger K et al. Ovoid shape of the vermiform appendix: a criterion to exclude acute appendicitis-evaluation with US. *Radiology*. 2003; 226: 95-100.
18. Rodriguez DP, Vargas S, Callahan MJ. Appendicitis in young children: Imaging experience and clinical outcomes. *Am J Roentgenol* 2006; 186: 1158-64.
19. Gisler M, Rouse G, DeLange M. Sonography of appendicitis: A Review. *JDMS*.1989; 5: 57-60.
20. Puig S, Hormann M, Rebhandl W, Felder. US as primary diagnostic tool in relation to negative appendectomy: six years experience. *Radiology*. 2003; 226: 101-4.
21. Lee JH, Jeong YK, Hwang JC. Graded compression sonography with adjuvant use of posterior compression technique in the sonographic diagnosis of acute appendicitis. *AJR Am J Roentgenol*. 2002; 178: 863-8.
22. Puylaert JB, Rutgers PH, Lalisang RI. A prospective study of ultrasonography in the diagnosis of appendicitis. *N Engl J Med*.1987; 317: 666-9.
23. Jeffrey RB Jr, Laing FC, Townsend RR. Acute appendicitis: Sonographic criteria based on 250 cases. *Radiology*. 1988; 167: 327-9.
24. John H, Neff U, Kelemen M. Appendicitis diagnosis today: Clinical and ultrasonic deductions. *World J Surg*. 1993; 17: 243-9.
25. Ali S, Shah STA. Gynaecological Emergencies. *Professional Med J*.2007; 14: 43-8.
26. Shahid G, Dar HM, Majid HJ. A study of gynaecological emergencies presenting as Acute Appendicitis. *Proceeding Shaikh Zayed Postgrad Med Inst* 2005; 19: 13-7.
27. Schwerk WB, Wichtrup B, Rothmund M, Rüschoff Ultrasonography in the diagnosis of acute appendicitis: a prospective study. *Gastroenterol*. 1989; 97: 630-9.
28. Mardan MA, Mufti TS. Role of ultrasound in acute appendicitis. *J Ayub Med Coll Abbottabad*. 2007; 19: 72-9.
29. Zielke A, Hasse C, Sitter H. Influence of ultrasound on clinical decision making in acute appendicitis: a prospective study. *Eur J Surg*. 1998; 164: 201-9.
30. Malik KA, Khan A, Waheed I. Evaluation of Alvarado score in diagnosis of acute appendicitis. *J Coll Physicians Surg Pakistan*.2000; 10: 392-4.
31. Mufti TS, Akhtar S, Khan K. Diagnostic accuracy in acute appendicitis; comparison between clinical impression and ultrasound findings: *J Ayub Med Coll Abbottabad* 1996; 8: 13-5.