e-ISSN: 0975-5160, p-ISSN: 2820-2651

Available online on www.ijtpr.com

International Journal of Toxicological and Pharmacological Research 2022; 12(12); 88-97

Original Research Article

Role of High-Resolution Sonography and Doppler in Evaluation of Acute Scrotal Disease

Vishnu A.R.[1], Mini M.V.[2], Raini K.P.[3], Sinni K.V.[4]

[1]Senior Resident, Department of Radiodiagnosis, Government Medical College, Thrissur, Kerala, India.
[2]Associate Professor, Department of Radiodiagnosis, Government Medical College, Manjeri, Kerala, India.
[3]Associate Professor, Department of Radiodiagnosis, Government Medical College, Kozhikode, Kerala, India.
[4]Associate Professor, Department of Radiodiagnosis, Government Medical College, Thrissur, Kerala, India.

Received: 15-10-2022 / Revised: 17-11-2022 / Accepted: 05-12-2022
Corresponding author: Dr. Sinni K.V.
Conflict of interest: Nil

Abstract

Background: Acute scrotum possesses a difficult diagnostic challenge because of the non-specific nature of symptoms and difficulty in adequately examining the tender, swollen scrotum. It is a cross sectional study, a diagnostic test evaluation to assess the accuracy of doppler ultrasound in the diagnosis of acute scrotal disease and identify and classify causes of acute scrotum based on the sonographic appearance and doppler evaluation.

Methods: This is a cross sectional study carried out in 90 patients presented with acute scrotum in Department of Radiodiagnosis Government Medical College Thrissur, over one year starting from December 2020. The patients were evaluated with high resolution ultrasonography and Doppler ultrasound. Ultrasound diagnosis is then compared with final diagnosis arrived after conservative management or postoperative and histopathological findings. Results are analysed, and, with the final data sensitivity, specificity, positive predictive value and negative predictive value are calculated.

Results: Color Doppler ultrasound was found to be 100% sensitive and 95% specific for the diagnosis of testicular torsion in our study with positive predictive value of 88.4% and negative predictive value of 100%. Color Doppler ultrasound was found to be 96.61% sensitive and 96.78% specific for the diagnosis of testicular/ epididymal / peri-testicular inflammation with positive predictive value of 98.2% and negative predictive value of 93.75%.

Conclusion: Grey-scale changes are nonspecific and Doppler ultrasound clinches the diagnosis when evaluating the differential diagnosis of acute scrotum. Power Doppler sonography, because of its better visualization of low velocity flow, increases the diagnostic accuracy by better characterization of the testicular and peri-testicular perfusion.

Keywords: testicular torsion, grey scale changes, power Doppler ultrasound, low velocity flow

Introduction

The male has reproductive organs, or genitals, that are both inside and outside the pelvis. The male genitals include testicles, the duct system, which is made up of epididymis and vas deferens, the accessory glands, which include the seminal vesicles, prostate gland and the penis. Among these, testes, epididymis and vas deferens are located in scrotum [1]. Many diseases can affect these structures, acute or chronic. Acute scrotum is a broad term encompassing clinical conditions characterized by the sudden onset of scrotal symptoms – particularly pain, swelling and reddening that may occur alone or in combination [2]. Though testis is accessible for clinical examination, the acute scrotum possesses a difficult diagnostic challenge because of the nonspecific nature of symptoms and difficulty in adequately examining the tender, swollen scrotum. Clinical history may play a crucial role in identifying the causes of acute scrotal diseases [3].

Although epididymitis is the most frequent cause of acute scrotal pain, the most important diagnosis to establish is testicular torsion, since this requires emergency surgical correction to preserve testicular viability and function. Therefore, assessment of perfusion of testis is the primary requirement for any imaging modality used in this clinical situation [4].

High frequency ultrasonography is the modality of choice in investigating scrotal and testicular pathology [5]. While CT and MRI have dominated imaging of other regions of the body, they have certain limitations in evaluation of scrotal disease. Computed tomography delivers radiation to gonads, MRI imaging is costly and not readily available. Radionuclide imaging, which was used as the modality of choice for evaluation of acute scrotal diseases in the past provides excellent information regarding perfusion of scrotal contents, but its depiction of anatomic relations is limited [6].

High resolution sonography using high frequency transducers provides excellent anatomic detail of the scrotal wall, testes, epididymis. When color Doppler and power Doppler imaging's are added, it allows visualization of morphology and parenchymal blood flow characteristics. Spectral analysis of the doppler waveform allows quantitative assessment of perfusion more meaningful and less subjective in differentiating normal from acutely inflamed testes and epididymis in excluding torsion [7].

Sonography is simple to perform, rapid, non-invasive, relatively inexpensive, easily reproducible, widely available and does not involve irradiation of gonads

Our study aims to assess the accuracy of Doppler ultrasound in the diagnosis of acute scrotal disease and to identify and classify causes of acute scrotum based on sonographic appearance and Doppler evaluation.

Methodology

It is a cross sectional study ,diagnostic test evaluation conducted in the Department of Radio-diagnosis, Govt. Medical College Hospital, Thrissur over a period of one year starting from December 2020. Sample size is calculated based on the formula

$$n \geq \frac{Z^2_{1-\frac{\alpha}{2}} x Spec(1-Spec)}{d^2 x(1-Prev)}$$

n=sample size, z=1.96 for 95% confidence interval, α= Type 1 error rate (0.05), spec= estimated specificity(0.75 from previous study [8], prev = prevalence of the disease in the population(in our study prevalence taken as 0.2 from previous study[8], d= marginal error rate (0.14), So here $n \geq \frac{Z^2_{1-\frac{0.05}{2}} \times 0.85(1-0.85)}{0.14^2 \times (1-0.75)}$ =90. Therefore calculated sample size is 90 cases.

Study started after getting approval from ethical committee of government medical college, Thrissur (IEC/GMCTSR /065/2020 dated 2-12-2020) (Annexure A). Written informed consent was obtained from all the participants. The participants were informed about the procedure they are involved and they have the full right to discontinue from the study if they want due to any reason. Expenses involved in the study will be met by the investigator.

Inclusion and Exclusion Criteria

Patients of all age groups referred from the general surgery or pediatric surgery departments with clinical manifestations of acute scrotal disease are included in the study**.**

Known cases of post scrotal trauma / surgery and those who don't give consent for study are excluded.

All consecutive patients satisfying the inclusion criteria are selected for the study till the sample size is achieved.

Data Collection Procedure

Data was collected using the study proforma prepared. The patients with history of acute onset of scrotal pain/swelling who are first examined in the surgery or pediatric surgery departments and referred to the department of Radiodiagnosis are selected based on inclusion and exclusion criteria.

The name, age, unit, registration number and address of the patients will be recorded. Detailed clinical history, both present and past, will be enquired and recorded. Clinical examination findings and various laboratory results will be recorded.

Using a 7-15 MHz variable frequency linear phased array transducer of GE LOGIQ S8 Doppler ultrasound machine, high resolution grey scale sonography and Doppler ultrasound are performed

Pediatric patients are examined only after adequate sedation. The patients are examined in the supine position, with the scrotum supported over a towel tightly draped over the thighs. Bilateral testicular and epididymal grey scale imaging are performed in longitudinal, transverse and oblique planes. Morphologic assessment includes side to side comparison of testicular size and echogenicity

In Color Doppler ultrasonography, supra-testicular, capsular and intratesticular arteries are searched for in each testis with use of low flow settings (low pulse repetition frequency and filter values). Scanning plane is optimized for vessel visualization and spectral analysis. The transducer is positioned such that an angle of incidence that was as close to 0 degree was obtained. Threshold values are adjusted to maximize visualization of testicular vessels while avoiding artifactual color assignment due to system noise. The normal testis in each patient is used as a control to guide adjustment of equipment settings. Power doppler sonography is also performed. Spectral Doppler parameters (peak systolic velocity, resistivity index) are studied.

Greyscale and doppler evaluation findings in torsion of testis are mild scrotal wall oedema, minimal/ excess of fluid in TV sac, testicular enlargement, epididymal enlargement, homogenous normal echogenicity of testis, homogenous or heterogenous echogenicity of epididymis, absent intratesticular flow and normal peritesticular flow

In non-viable testis, testes may show heterogenous echopattern, presence of focal lesions {representing areas of necrosis} & increased peritesticular flow

Grey-scale and doppler evaluation findings in epididymitis are ,normal sized testes with normal homogenous echogenicity, increased size of epididymis, decrease in echogenicity or heterogenous echopattern of epididymis, minimal hydrocele, mild scrotal wall thickening, normal testicular blood flow, increase in number and size of vessels in epididymis showing increase in colour flow compared to normal side,

increase in peak systolic velocity, decrease in resistivity index &normal testicular blood flow.In epididymo-orchitis testes also show the same changes as in epididymis

All the details are entered in a pro-forma and diagnosis is made based on grey scale and Doppler ultrasound findings. These results are then compared with final diagnosis from hospital records. Finally, the data is statistically analyzed and evaluated.

Statistical Analysis

Data will be entered into Microsoft Excel sheet. Analysis of data will be done using appropriate statistical software (SPSS).Sensitivity, specificity, positive predictive value and negative predictive values were calculated.

Results and Analysis

In our study, patients enrolled in the study had age ranging from four months to 55 years. Most of them belonged to 10 to 20 years of age accounting 30 % of the study population. Approximately 9% of the study population is below 1 year of age and 9% belongs to prepubertal age group. Approximately 25 % of study population is in the age group of 20 to 30 years of age.

Initial clinical diagnosis of examining general/pediatric surgeon includes epididymo-orchitis, torsion testes and scrotal fasciitis. Approximately 56% of cases, surgeon gave initial clinical diagnosis as epididymo-orchitis (50 cases).

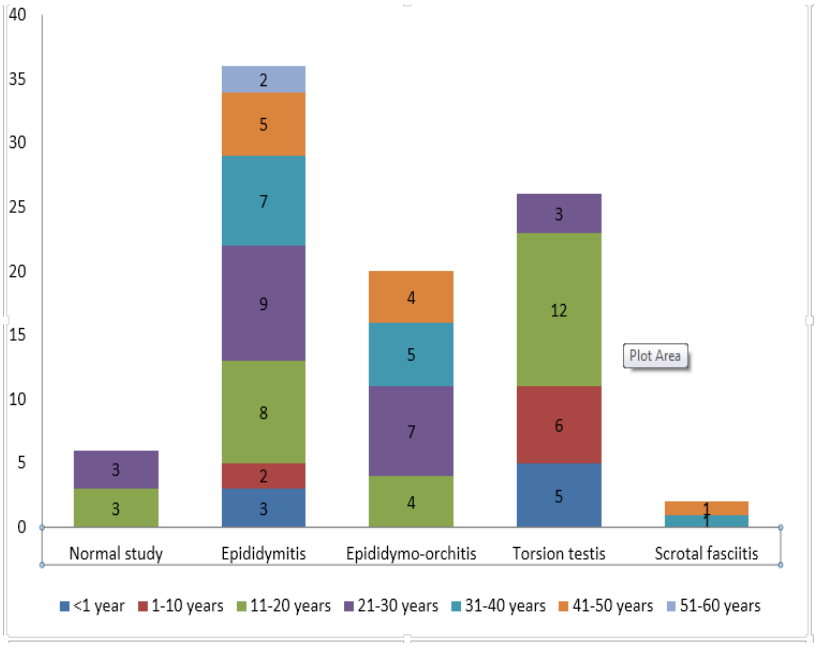

Figure 1: Ultrasound Diagnosis in Different Age Groups of Patients Studied

Ultrasound shows torsion testis in 26 patients, Epididymo-orchitis in 20 Epididymitis in 36 and Scrotal fasciitis in 2 patients. USG was normal in 6 patients. Torsion testis was more common in 11-20 age groups, 12 Out of 26 cases. Epididymo-orchitis. was more common in 21 -40 age group, 12 out of 20 cases.

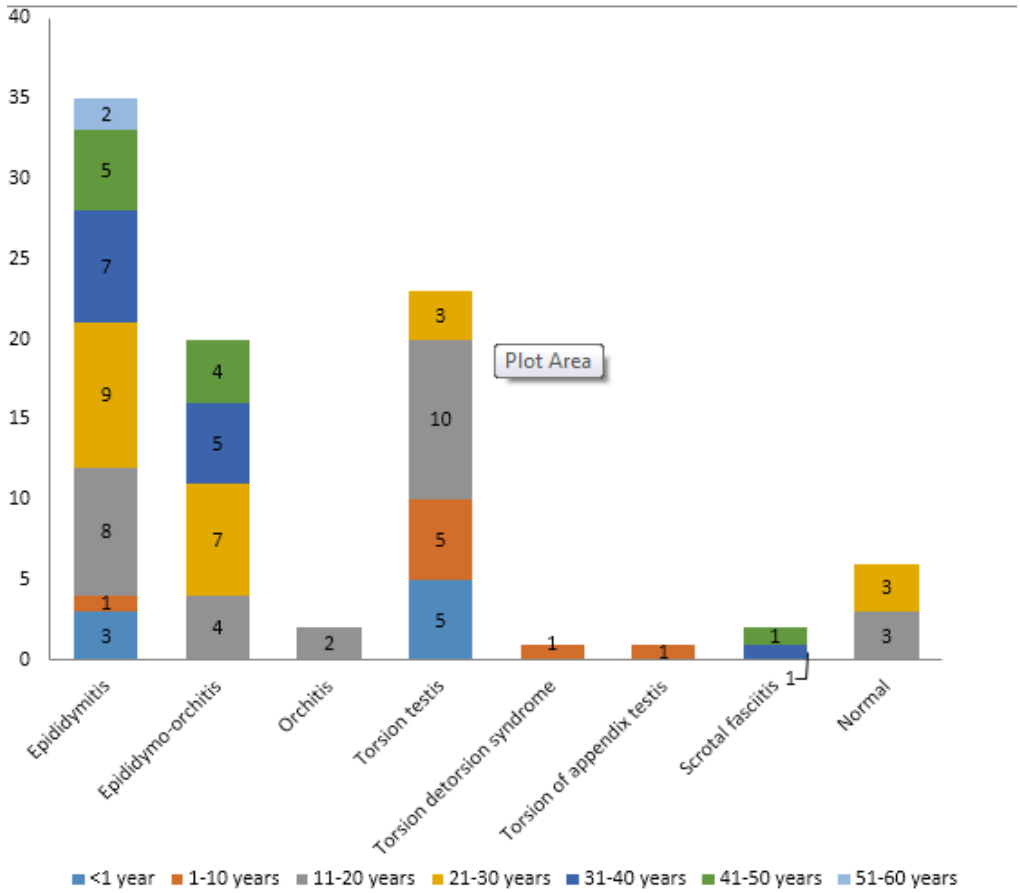

Figure 2: Final Diagnosis in Different Age Groups of Patients Studied

Final diagnosis shows Epididymitis in 35, Epididymo-orchitis in 20, Orchitis in 2, Torsion testis in 23, Torsion detorsion syndrome 1, Torsion of appendix testis 1, Scrotal fasciitis 2 &Normal 6 Patients. In patients less than 1 year shows 3 cases of Epididymitis and 5 no of Torsion testis. Patients within 1 -10 years shows 1 Epididymitis, 5 no of Torsion testis, one each of torsion detorsion and torsion of appendix. Patients within 11- 20 years shows 8 cases of Epididymitis, 4 cases of Epididymo-orchitis, 2 Orchitis, 10 Torsion testis and 3 Normai patients. Patients within 21- 30 years shows 9 cases of Epididymitis, 7 cases of Epididymo-orchitis, 3 Torsion testis & 3 Normal. Patients within 31- 40 years shows 7 cases of Epididymitis, 5 cases of Epididymo-orchitis & 1 case of scrotal fasciitis. Patients within 41- 50 years shows 5 cases of Epididymitis, 4 cases of Epididymo-orchitis, 1 case of scrotal fasciitis. Patients within 51- 60 years shows 2 cases of Epididymitis.

Of the 23 diagnosed cases torsion testis 9 were homogenous 3 were hypoechoic and 11 were Heterogenous in USG. Of the 38 clinically diagnosed cases of torsion testes sonological features of torsion were present only in 26 cases. Out of 26 sonologically diagnosed cases of torsion 23 cases turned out to be torsion after surgery.one was torsion detorsion syndrome and two were orchitis with secondary vascular compromise.

USG shows increased size of epididymis in 80 patients. Out of this after final diagnosis 35{43.8} cases turned out to be Epididymitis, 20 Epididymo-orchitis, 23 Torsion testis, 1 Torsion detorsion testis, and 1 Torsion of appendix testis.

Mean of peak systolic velocity ratio of epididymis between involved side and normal in cases of inflammation is 1.7305

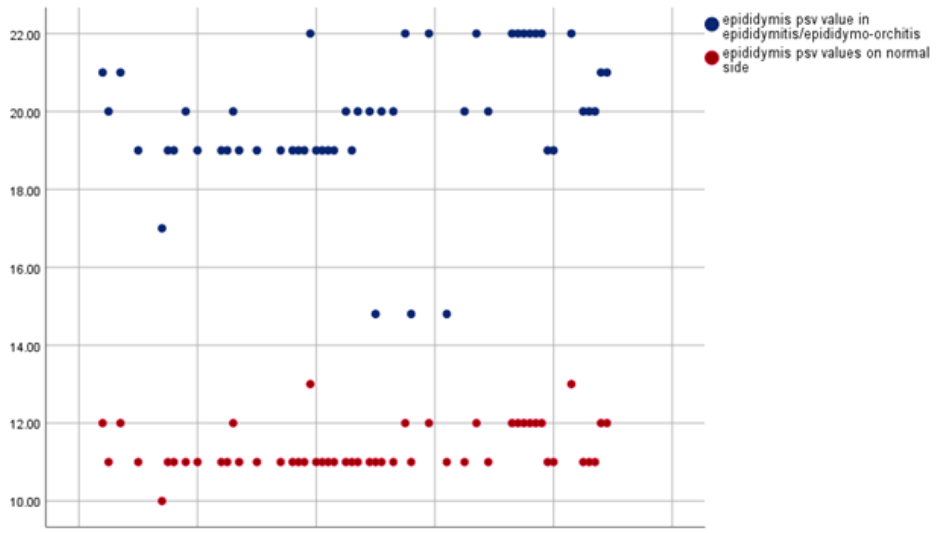

Figure 3: PSV Values in Epididymis Inflammation ; Involved Side Vs Normal Side

Mean of PSV ratio of Testes between involved side and normal in cases of inflammation is 1.8581

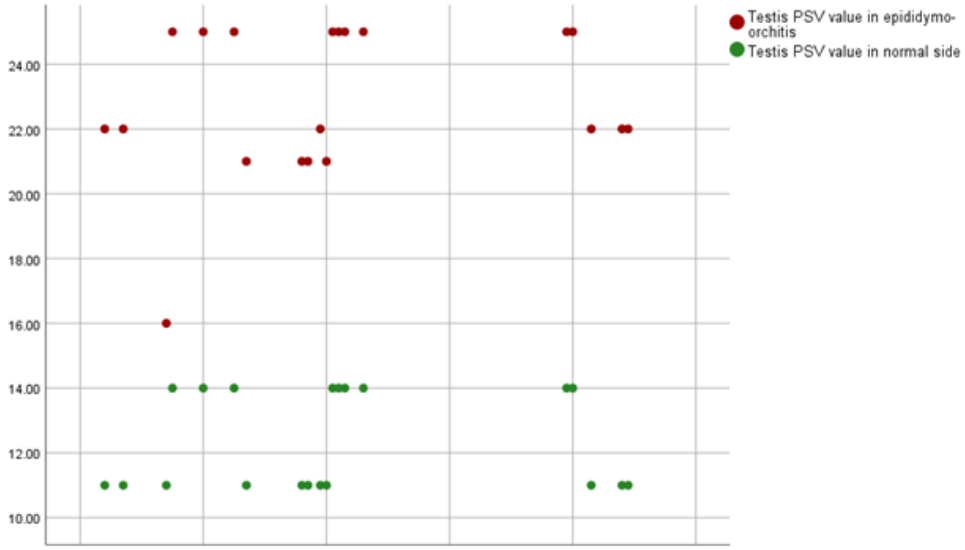

Table/scatter diagram -4 PSV Values in Testicular Inflammation, Involved Vs. Normal Side Testis

Out of 90 cases color Doppler shows features of torsion in 26 cases and 64 without torsion. Of the 26 cases diagnosed as torsion by USG 23 turned out to be torsion testes after final diagnosis. Out of other 64 cases without USG features of torsion none came out be torsion after final diagnosis. Sensitivity of color Doppler in diagnosing torsion testes were 100%, Specificity 95.52%, Positive Predictive Value 88.46%, Negative Predictive Value 100%, and Accuracy 96.7%.

Out of 59 finally diagnosed cases of Epididymis/ Testes/ Peritesticular Inflammation 57 showed features of inflammation in colour doppler. Out of rest 31 cases without features of inflammation after final diagnosis 1 was diagnosed as inflammation in color doppler. Sensitivity of color doppler in

diagnosing Epididymis/ Testes /Peritesticular Inflammation was 96.49%, Specificity 96.97%, Positive Predictive Value 98.21%, Negative Predictive Value 94.12% and Accuracy 96.67%

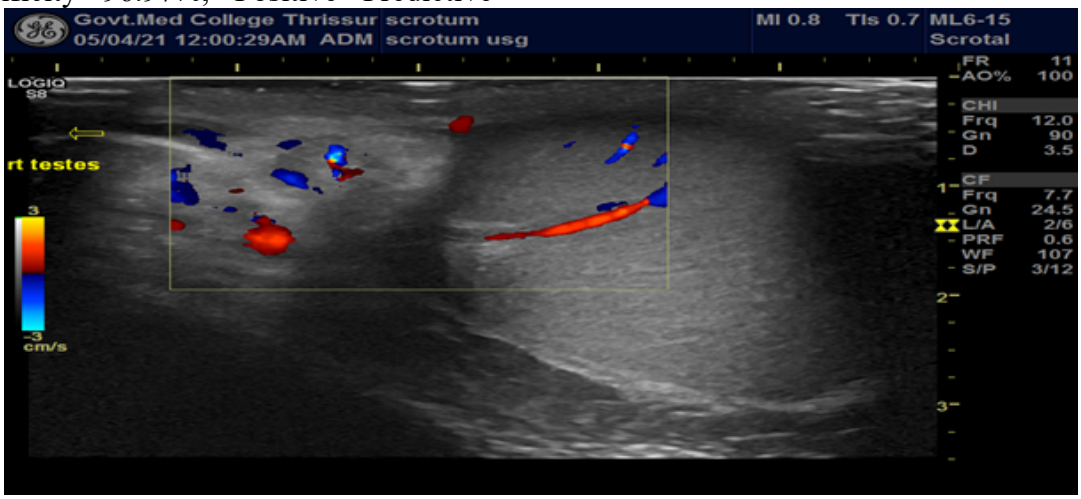

Figure 5: USG image showing r testis and epididymis with normal echogenicity and vascularit

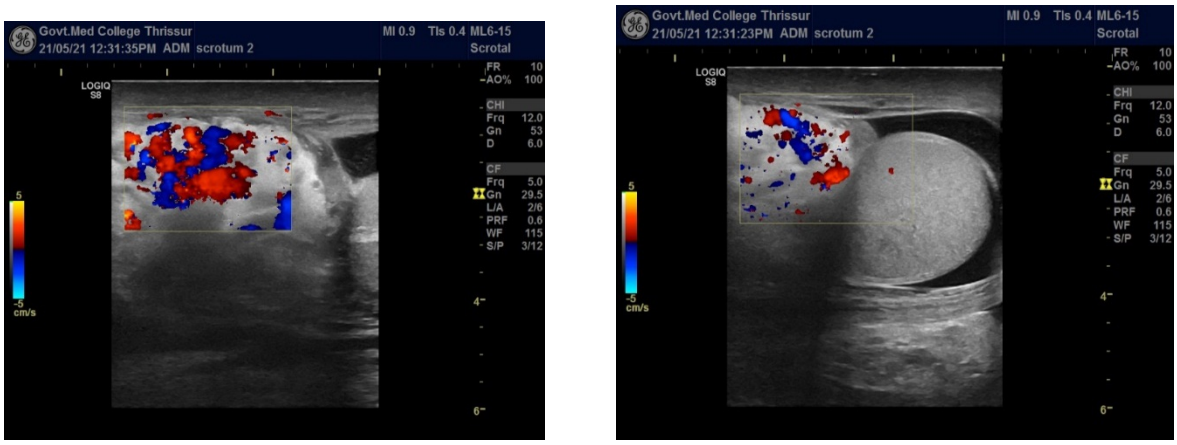

Figure 6: USG Images Showing Enlarged and Heteroechoic Epididymis With Fluid in TV Sac- In A Case of Epididymitis

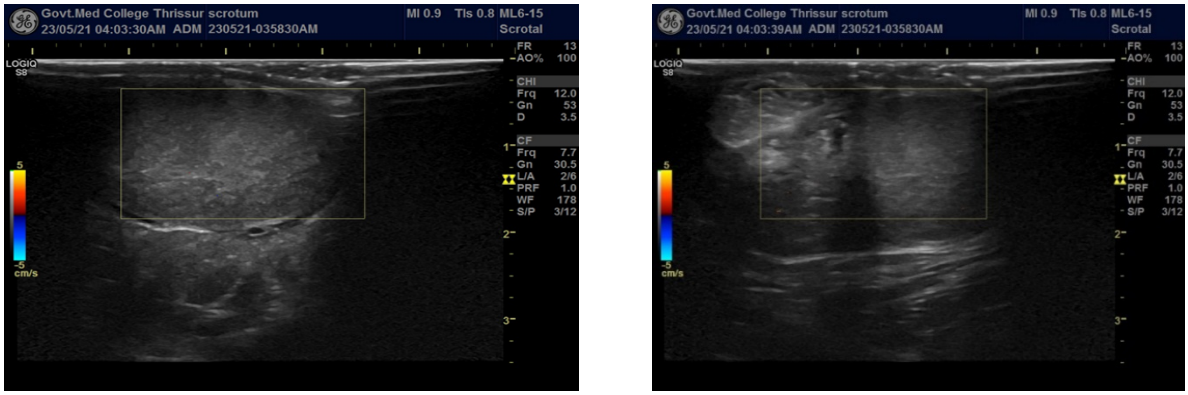

Figure 7: USG Images Showing Enlarged Testes And Epididymis With Heteroechogenicity And Showing No Colour Flow- Final Diagnosis Is Torsion Testes

Discussion

This is a cross sectional study to assess the accuracy of doppler ultrasound in the diagnosis of acute scrotal disease, and to identify and classify causes of acute scrotum based on the grey scale appearance and doppler ultrasound evaluation. Study was carried out in 90 patients presented with acute scrotum in government medical college Thrissur over the study period.

Colour doppler sonography was found to be 100% sensitive and 95% specific for the diagnosis of testicular torsion in our study with positive predictive value of 88.4% and negative predictive value of 100%. A study by Drumadala I Gajbhiye et al [9] also shows 100% sensitivity for colour doppler when compared to physical examination……

In the study by middleton et al., doppler evaluation was found to be 100% sensitive and 100 % specific for the diagnosis of testicular torsion [10]. In that study, involved testis did not show any change in size or echogenicity and showed complete absence of intratesticular flow on doppler assessment. This may be because cases were examined at an early phase of acute torsion.

Colour doppler sonography was found to be 86% sensitive and 100 % specific for the diagnosis of testicular torsion in the study by Burks et al. this study assessed 7 patients with proven testicular torsion [11].

The lowered specificity in our study is due to the wrong sonological diagnosis of torsion testis made in three cases. Those were one case of torsion detorsion syndrome and two cases of Orchitis. These findings can be explained by the view that In torsion detorsion patient had partial torsion at the time of our study but the testis had detorsion by the time he was taken up for surgery. And in orchitis the testis was oedematous and the capsule was stretched around it. which in turn had caused capsular compression and secondary vascular compromise.

A sonological diagnosis of epididymitis was made in a 2-year-old boy who had torsion of the appendix of testis at exploration. In a study of cases in the paediatric age group, Atkinson et al have suggested that in most instances, distinction between torsion of the appendix testis and epididymis could not be made [12].

Power doppler evaluation is a useful adjunct in our study. It is useful to confirm absence of testicular perfusion in cases of suspected torsion and in enhancing conventional color doppler findings of hyperemia in testicular and epididymal inflammation. This is in agreement with the conclusions of Garrigo Farriol et al and Luker et al., [13,14].

Blood flow is demonstrated in the normal adult epididymis that are examined with colour and power doppler. A diagnosis of epididymitis could be made only by the asymmetric flow pattern on comparison with the normal side. This was in agreement with findings of Keener et al [15]. Colour doppler and power doppler failed to demonstrate any flow in normal testis or epididymis in infants and small children.

In our study, we had a 96.61% sensitivity, 96.78% specificity, 98.2% positive predictive value and 93.75% negative predictive value for the diagnosis of testicular/ epididymal /peritesticular inflammation. With the use of colour and power doppler imaging, cases of epididymitis and epididymo-orchitis could be well delineated. The extent of involvement and additional involvement of the testis in addition to the epididymis could be well appreciated. Presence of complications of inflammatory disease could be well assessed. Epididymal abscess were seen in two cases of epididymitis and epididymal/testicular

abscess seen in two cases of epididymo-orchitis.

In our study, Spectral doppler analysis of testis/epididymis flow in cases of epididymitis and epididymo-orchitis shows that increase in PSV values on the affected side compared to normal side. In epididymitis or epididymo-orchitis cases, mean PSV value of 19.7cm/sec (std. deviation of 1.75 and std. error of 0.24) in epididymis of the involved side and 11.3 cm/sec (std. deviation of 0.58 and std. error of 0.0824462) in normal side. Mean PSV ratio of epididymal vessels between involved and normal side epididymis is 1.73. In epididymo-orchitis, testis shows increased PSV values on affected side with mean PSV of 22cm/sec (std. deviation of 2.3 and std. error of 0.52) and on the normal side with mean PSV of 12.35 cm/sec (std. deviation of 1.53 and std. error of 0.34). Mean PSV ratio between involved and normal side testis is 1.858. In cases of inflammatory diseases of epididymis/testis resistivity index values are decreased in affected side compared to normal side.

Denis M Brown et al have concluded that spectral analysis should be performed in case suspected inflammation. The quantitative criteria proposed by them for the diagnosis of inflammation are a peak systolic velocity of 15 cm per second or greater in the epididymis or testis and a peak systolic velocity ratio of greater than 1.7 in the epididymis or 1.9 in the testis [14] which is comparable with our study [16].

In the two cases of scrotal fasciitis, the testis and epididymis were normal. So that an origin for scrotal fasciitis from these tissues could be excluded. [17]

Conclusion

Grey-scale changes are nonspecific when evaluating the differential diagnosis of acute scrotum. Doppler ultrasound clinches the diagnosis in this situation where it gives details of the perfusion to the testis and epididymis. A positive predictive value of 88.4% proves that doppler ultrasound is a valuable investigation especially when the diagnosis of torsion is in doubt. Colour doppler ultrasound had a sensitivity of 96.61% and specificity of 96.78% for the diagnosis of testis/epididymis/peritesticular inflammation and it allows better characterization of the extent of involvement. Complications also better assessed. Power doppler sonography, because of its better visualisation of low velocity flow, increases the diagnostic accuracy by better characterization of the testicular and peritesticular perfusion. In epididymitis, spectral doppler analysis shows that ratio of Peak Systolic Volume value between affected epididymis to normal side is a better parameter than the increase in Peak Systolic Volume value of the affected epididymis.

References

1. Dogra VS, Gottlieb RH, Oka M, Rubens DJ. Sonography of the scrotum. Radiology. 2003 Apr; 227 (1):18-36.
2. Günther P, Rübben I. The acute scrotum in childhood and adolescence. Deutsches Ärzteblatt International. 2012 Jun;109(25):449
3. Blaivas M, Sierzenski P, Lambert M. Emergency evaluation of patients presenting with acute scrotum using bedside ultrasonography. Academic Emergency Medicine. 2001 Jan; 8(1): 90-3.
4. Ong CY, Low HM, Chinchure D. Scrotal emergencies: An imaging perspective. The Medical journal of Malaysia. 2018 Dec 1;73(6):445-51.
5. Aganovic L, Cassidy F. Imaging of the scrotum. Radiologic Clinics. 2012 Nov 1; 50(6):1145-65.
6. Forrest A, Brahmbhatt A, Dogra V. Decreased Blood Flow in the Test is: Is it Testicular Torsion? American Journal of Sonography. 2018 Jul 25;1.

7. Ragheb D, Higgins Jr JL. Ultrasonography of the scrotum: technique, anatomy, and pathologic entities. Journal of ultrasound in medicine. 2002 Feb; 21(2):171-85.
8. Horstman WG, Middleton WD, Melson GL. Scrotal inflammatory disease: color Doppler US findings. Radiology. 1991 Apr; 179(1):55-9.
9. Drumadala I Gajbhiye et al. Role of Ultrasonography & Colour Doppler in Scrotal Pathologies. JMSCR Volume 08 Issue 05 May 2020.
10. Middleton WD, Melson GL. Testicular ischemia: color Doppler sonographic findings in five patients. American Journal of Roentgenology. 1989 Jun 1;152(6):1237-9.
11. Burks DD, Markey BJ, Burkhard TK, Balsara ZN, Haluszka MM, Canning DA. Suspected testicular torsion and ischemia: evaluation with color Doppler sonography. Radiology. 1990 Jun;175(3):815-21. a Journal of Roentgenology. 1989 Jun 1; 152(6): 1237-9.
12. Atkinson Jr GO, Patrick LE, Ball Jr TI, Stephenson CA, Broecker BH, Woodard JR. The normal and abnormal scrotum in children: evaluation with color Doppler sonography. AJR. American journal of roentgenology. 1992 Mar;158(3):613-7
13. Farriol VG, Comella XP, Agromayor EG, Crèixams XS, Martinez de la Torre IB. Grayscale and power Doppler sonographic appearances of acute inflammatory diseases of the scrotum. Journal of clinical ultrasound. 2000 Feb;28(2):67-72.
14. Luker GD, Siegel MJ. Scrotal US in pediatric patients: comparison of power and standard color Doppler US. Radiology. 1996 Feb;198(2):381-5
15. Keener TS, Winter TC, Nghiem HV, Schmiedl UP. Normal adult epididymis: evaluation with color Doppler US. Radiology. 1997 Mar; 202(3):712-4. oppler US. Radiology. 1996 Feb;198(2):381-5
16. Brown JM, Hammers LW, Barton JW, Holland CK, Scoutt LM, Pellerito JS, Taylor KJ. Quantitative Doppler assessment of acute scrotal inflammation. Radiology. 1995 Nov; 197(2): 427-31. a
17. Batool D. R., Jamal D. K., Sheroze D. M. W., Bhatti D. I. A., Jaffar D. N., Haider D. G., & Faridi D. M. A. Clinical features of colorectal carcinoma at the Jinnah Postgraduate Medical Centre, Karachi, Pakistan: a cross-sectional study. Journal of Medical Research and Health Sciences. 2022; 5(9): 2203–2209.