

Prospective, Observational and Longitudinal Study to Evaluate the Use of Laparoscopy As A Diagnostic Tool in Patients with Lower Abdominal Pain

Nitish Kumar

Assistant Professor, Department of General Surgery, Shree Narayan Medical Institute & Hospital, Saharsa, Bihar, India.

Received: 20-12-2021 / Revised: 21-02-2022 / Accepted: 14-03-2022

Corresponding author: Dr. Nitish Kumar

Conflict of interest: Nil

Abstract

Aim: To evaluate the use of laparoscopy as a diagnostic tool in patients with lower abdominal pain where other investigations fail to reach a conclusion, to enumerate the common causes of intractable abdominal pain and to study the usefulness of incidental appendectomy performed during diagnostic laparoscopy.

Material & Method: The study was a prospective, observational and longitudinal. Diagnostic laparoscopy was performed in 50 patients with intractable lower abdominal pain.

Results: All the patients in the study presented with abdominal pain (100%). Majority of patients 46% showed pain at right iliac fossa followed by lower abdomen (22%). 48% patients showed Mesenteric lymphadenopathy.

Conclusion: When radiological studies are inconclusive, diagnostic laparoscopy is a very excellent and accurate technique for diagnosing the causes of abdominal pain. It should be utilized on a regular basis. When performed on the right age group and in the right circumstances, incidental appendectomy provides a lot of benefits.

Keywords: Incidental appendectomy, Diagnostic laparoscopy, Lower abdominal pain

This is an Open Access article that uses a fund-ing model which does not charge readers or their institutions for access and distributed under the terms of the Creative Commons Attribution License (<http://creativecommons.org/licenses/by/4.0>) and the Budapest Open Access Initiative (<http://www.budapestopenaccessinitiative.org/read>), which permit unrestricted use, distribution, and reproduction in any medium, provided original work is properly credited.

Introduction:

Appendicitis is the most common cause of acute right lower quadrant abdominal pain (ARLQP); however, a broad spectrum of common and uncommon conditions may mimic acute appendicitis especially in women of childbearing age which may carry a diagnostic dilemma [1-3]. Accurate diagnosis is the cornerstone in avoiding inappropriate treatment and despite

improvements in imaging; it may still be difficult to differentiate between gynecologic and non-gynecologic causes of abdominal pain which makes diagnostic laparoscopy to be the gold standard for proper diagnosis and treatment in such condition [4].

Since its introduction in 1983,[5] laparoscopic appendectomy has not

completely replaced the conventional method of open appendectomy. Previous randomized studies of laparoscopic appendectomy had conflicting results[6-8] due in part to limited sample sizes, contributing to the controversy of this relatively new surgical technique.

Laparoscopic surgery, also called minimally invasive surgery (MIS), band aid surgery or key hole surgery, is performed through small incisions (usually 0.5-1.5 cm) as opposed to the larger incisions needed in laparotomy. Diagnostic laparoscopy is a minimally invasive method for the diagnosis of intra-abdominal diseases by direct inspection of intra-abdominal organs.[9]

Incidental appendectomy which is the removal of a macroscopically normal appendix has been evolved during diagnostic laparoscopy especially in females with ARLQP [7]. The procedure gained popularity amongst surgeons to avoid future acute appendicitis and the need of recurrent hospitalization and reoperation. [10, 11]

The objective of the study is to evaluate the use of laparoscopy as a diagnostic tool in patients with lower abdominal pain where other investigations fail to reach a conclusion, to enumerate the common causes of intractable abdominal pain and to study the usefulness of incidental appendectomy performed during diagnostic laparoscopy.

Material & Method:

The study was performed at the Department of General Surgery, Shree Narayan Medical Institute & Hospital, Saharsa, Bihar, India over a period of 15 months.

Inclusion Criteria:

Adolescents and adults between 15 and 65 years of age, patients having lower abdominal pain, patients who cannot be stamped as having acute appendicitis by

laboratory and radiological investigations and patients who were fit to tolerate general anesthesia.

Exclusion Criteria:

Paediatric and geriatric patients, patients with prior appendectomy, patients having acute or subacute appendicitis on ultrasonography, pregnant patients, patients who were positive for HIV, HBsAg and HCV and patients who could not tolerate general anaesthesia.

Methodology

The study was a prospective, observational and longitudinal. Diagnostic laparoscopy was performed in 50 patients with intractable lower abdominal pain. In addition to treating the cause of the pain laparoscopically like adhesiolysis, ovarian cystectomy, etc, an appendectomy was performed in all cases.

In each case, a detailed history, clinical examination, investigations and follow up was recorded as per the pro forma. Diagnostic laparoscopy was performed through a 12 mm sub-umbilical incision via a 10 mm 30-degree telescope with the patient in general anesthesia. Appendectomy was performed via two 5mm working ports- one in the suprapubic region and one in the left iliac fossa. Patients were started on enteral feeds within 24 to 48 hours of surgery. Regular dressings of the stitches were done and stitches were removed on 8 to 10 days. Post-operatively patients were followed up for a period of 1 year and evaluated for any post-operative complications, post-operative pain, incidence of stumpitis and any untoward complication of incidental appendectomy.

Statistical analysis

The collected data was compiled in Microsoft office excel 2010 format. Data was processed using Epi Info statistical

software version 7.2. Frequency and proportions were obtained from the collected data.

Results:

All the patients in the study presented with abdominal pain (100%). Anorexia was found to be the 2nd commonest symptom. Nausea, vomiting and fever were other concurrent symptoms. Diarrhoea was found to be the least common (Figure 1).

The distribution of patients according to the site of pain is tabulated in Table 1. Majority of patients 46% showed pain at right iliac fossa followed by lower abdomen (22%)

Table 2 demonstrates distribution of cases according to laparoscopic findings. 48% patients showed Mesenteric lymphadenopathy, 14% had Adhesions/Bands, 12% showed Free fluid and Terminal ileitis/ colitis was seen in 10% of patients.

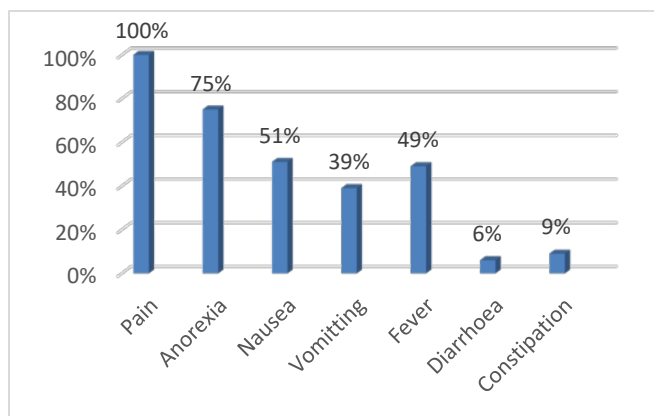


Figure 1: Distribution of cases according to symptoms.

Table 1: Distribution of cases according to site of pain

Site of pain	No. of cases	%
Peri-umbilical region	6	12
Right iliac fossa	23	46
Left iliac fossa	2	4
Hypogastrium	3	6
Lower abdomen diffuse	11	22
Total	50	100

Table 2: Distribution of cases according to laparoscopic findings

Laparoscopy finding	No. of cases	%
Adhesions/ Bands	7	14
Free fluid	6	12
PID	2	4
Ovarian cyst	4	8
Mesenteric lymphadenopathy	24	48
Terminal ileitis/ colitis	5	10
Mesenteric cyst	1	2
Uterine fibroid	1	2
Total	50	100

Discussion:

The incidence of appendicitis in the general population is approximately 11 per 10 000 population per year. According to the life table model produced by Addiss et al,[12] the lifetime risk for appendicitis in women is 6.7%.

Morino et al. in their study found that acute appendicitis was the cause of ARLQP pain in 18% of cases and gynecological causes in 15% only of cases; however, the study of Anteby et al. found that appendicitis was the cause of pelvic pain in 3% only of cases and gynecological pathologies represented 57% of cases[13, 14].

In patients more than 50 years of age, the incidence of acute appendicitis decreases and the risk associated with operation and prolonged anaesthesia is such that an incidental appendectomy is not beneficial. In mentally handicapped patients less than 50 years of age who are physically healthy, incidental appendectomy should be performed. Patients undergoing procedures that may compromise access to the appendix in the future should undergo incidental appendectomy. Incidental appendectomy is contraindicated in patients whose conditions are unstable, patients previously diagnosed with Crohn's disease, patients with an inaccessible appendix, patients undergoing radiation treatment, patients who are pathologically or iatrogenically immunosuppressed and patients with vascular grafts or other foreign material. [15]

Diagnostic laparoscopy increased diagnostic accuracy without elimination of the problem of missed appendicitis where its rate was 9-29% in various studies[16, 17]. Song et al. in their study confirmed appendicitis

pathologically in 4.3% only of the incidentally removed appendices; however, they found that only 22.7% of the appendices in 772 cases enrolled in their study were normal; the rest had varying degrees of pathology and the most common pathology result was adhesions, followed by fibrosis [18].

Barring abdominal pain, which was the indication for performing a diagnostic laparoscopy, other concurrent symptoms were anorexia, nausea, vomiting, fever, diarrhoea and constipation. All these symptoms were nonspecific and did not point to a specific intra-abdominal cause of pain.

Barring abdominal pain, which was the indication for performing a diagnostic laparoscopy, other concurrent symptoms were anorexia, nausea, vomiting, fever, diarrhoea and constipation. All these symptoms were nonspecific and did not point to a specific intra-abdominal cause of pain.[19]

Biswas et al studied 362 patients admitted with abdominal pain in Tralee general hospital, Ireland between January 1997 and December 1999, who then underwent a laparoscopy. The study reported non-specific abdominal pain in 36.18% of cases. Next in the frequency of occurrence were the gynaecological conditions (31.21%) followed by adhesions in 13.25% cases. Adhesions and gynaecological pathologies together make around 40% of cases in both the studies.[20,21]

Conclusion:

When radiological studies are inconclusive, diagnostic laparoscopy is a very excellent and accurate technique for diagnosing the causes of abdominal pain. It should be utilized on a regular basis. When performed on the right age group and in the right

circumstances, incidental appendectomy provides a lot of benefits.

References:

1. Paulson EK, Kalady MF, Pappas TN. Clinical practice. Suspected appendicitis. *The New England journal of medicine*. 2003;348:236-42.
2. Humes DJ, Simpson J. Clinical presentation of acute appendicitis: clinical signs - laboratory findings - clinical scores, Alvarado score and derivative scores. In: Keyzer C, Gevenois PA, editors. *Imaging of acute appendicitis in adults and children*. Springer-Verlag. 2011.
3. Andersson RE. Meta-analysis of the clinical and laboratory diagnosis of appendicitis. *The British journal of surgery*. 2004;91:28-37.
4. Khatuja R, Jain G, Mehta S, Arora N, Juneja A, Goel N. Changing Trends in Use of Laparoscopy: A Clinical Audit. *Minimally Invasive Surgery*. 2014;562785.
5. Semm K. Endoscopic appendectomy. *Endoscopy*. 1983;15: 59-64.
6. Laine S, Rantala A, Gullichsen R, Ovaska J. Laparoscopic appendectomy- is it worthwhile? A prospective, randomized study in young women *Surg Endosc*. 1997;11:95-97.
7. Macarulla E, Vallet J, Abad JM, Hussein H, Fernandez E, Nieto B. Laparoscopic versus open appendectomy: a prospective randomized trial. *Surg Laparosc Endosc Percutan Tech*. 1997;7(4):335-39.
8. Chung RS, Rowland DY, Li P, Diaz J. A meta-analysis of randomized controlled trials of laparoscopic versus conventional appendectomy. *Am J Surg*. 1999;177(3):250-56.
9. Laparoscopy. Available at: <https://medlineplus.gov/lab-tests/laparoscopy/>.
10. Biondi A, Di Stefano C, Ferrara F, Bellia A, Vacante M, Piazza L (2016):Laparoscopic versus open appendectomy: a retrospective cohort study assessing outcomes and cost-effectiveness. *World Journal of Emergency Surgery : WJES*, 1: 44.
11. Kaderli R. Incidental appendectomy: standard or unjustified risk? *Ther Umsch*. 2014;71:753-8.
12. Anayo , N. K. ., Guinhouya, K. M. ., Apetse , K. ., Agba , L. ., Assogba , K. ., Belo , M. ., & Balogou, K. A. Posterior Reversible Encephalopathy Syndrome. A case report. *Journal of Medical Research and Health Sciences*, 2022;5(3), 1804-1807.
13. Addis DG, Schaffer N, Fowler B, et al. The epidemiology of appendicitis and appendectomy in the United States. *Am J Epidemiol*. 1990;132:910-25.
14. Morino M, Pellegrino L, Castagna E, Farinella E, Mao P. Acute nonspecific abdominal pain: A randomized, controlled trial comparing early laparoscopy versus clinical observation. *Ann Surg*. 2006;44: 881-8.
15. Anteby SO, Schenker JG, Polishuk WZ. The value of laparoscopy in acute pelvic pain. *Ann Surg*. 1975;181: 484-6.
16. Fisher KS, Ross DS. Guidelines for therapeutic decision in incidental appendectomy. *Surg Gynecol Obstet*. 1990;171(1):95-8.
17. Frazee R, Burlew CC, Regner J, McIntyre R, Peltz E, Cribari C et al. (2017): Outpatient laparoscopic appendectomy can be successfully performed for uncomplicated appendicitis: A Southwestern Surgical Congress Multicenter Trial. *Am J Surg.*, 214:1007-9.
18. Alfa-Wali M, Osaghae S: Practice, training and safety of laparoscopic surgery in low and middle-income countries. *World Journal of Gastrointestinal Surgery*, 2017;9: 13-18.

19. Song J Y, Yordan E, & Rotman, C: Incidental Appendectomy During Endoscopic Surgery. JLS : Journal of the Society of Laparoendoscopic Surgeons, 2009;13: 376–83.
20. Yordan E, Rotman C, Song JY. Incidental appendectomy during endoscopic surgery. JLS. 2009;13(3):376-83.
21. Biswas S, McDonald K, Gleeson N, Falke L. Is NSAP A Myth in Today's World? Laparoscopy As a Diagnostic Tool in The Diagnosis Of (Nsap) Nonspecific Abdominal Pain: A Peripheral County Hospital Experience. Internet J Surg. 2005;8(2):1-8.