

## Assessment of Nasal Bones and Piriform Apertures in Human Skulls: A Morphometric Study

Vishwajeet Kumar

Associate Professor, Department of Anatomy, Lord Buddha Koshi Medical College and Hospital, Saharsa, Bihar, India

Received: 07-01-2022 / Revised: 04-02-2022 / Accepted: 20-02-2022

Corresponding author: Dr. Vishwajeet Kumar

Conflict of interest: Nil

### Abstract

**Aim:** The present study was undertaken to evaluate the dimensions (maximal width and length), the size and the shape of the piriform aperture (PA) and nasal bone.

**Methods:** 70 adult dry skulls were collected from the Department of Anatomy of Lord Buddha Koshi Medical College and Hospital, Saharsa, Bihar, India. All measurements were taken using digital Vernier caliper accurate up to 0.001 mm. Nasion and anterior nasal spine was marked. Then nasomaxillary and internasal sutures were traced.

**Results:** It is evident from Table 1 that height, upper width and lower width of piriform aperture were greater in male as compared to female. This difference was not statistically significant for upper width of piriform aperture ( $p=0.59$ ) and for lower width of piriform aperture ( $p=0.75$ ) while the difference in height of piriform aperture was statistically significant. ( $p<0.0001$ ).

**Conclusion:** The width of piriform shows an equal average for both sexes. The results obtained in this study showed the importance of the morphological knowledge of the piriform aperture.

**Keywords:** Nose, Dimension, Sexual Dimorphism

This is an Open Access article that uses a funding model which does not charge readers or their institutions for access and distributed under the terms of the Creative Commons Attribution License (<http://creativecommons.org/licenses/by/4.0>) and the Budapest Open Access Initiative (<http://www.budapestopenaccessinitiative.org/read>), which permit unrestricted use, distribution, and reproduction in any medium, provided original work is properly credited.

### Introduction

The nasal bone and piriform aperture (PA) together form the nose. Its morphology varies depending on the ethnicity and gender. The two nasal bones articulate in the midline to form the internasal suture. Superiorly both nasal bone articulate with the frontal bone and forms the fronto-nasal suture. Nasion is the point of intersection between internasal and frontonasal suture. The piriform aperture is an anatomical structure formed by several bones that are part of the face. It usually has a pear-shape appearance, anatomically formed in its upper portion by the nasal bone, palatal

process of the maxilla inferiorly and laterally by the frontal process of the maxilla. There is racial and geographical difference in the shape of the nose and the nasal aperture owing to climatic variation. This variation is necessary in order to adapt to the physiological and functional need of climate. These changes occur with respect to external nasal morphology, orientation of nasal bone and piriform aperture and in the mucosa lining the internal passages. [1]

The fractures of the facial skeleton involving the nasal bone and Piriform

aperture are very frequent findings. The shape and the size of the nasal bone varies in different races, ethnic groups and climates. Preoperative evaluation of nasal bone and piriform aperture will predict type of nose, soft tissue as well as skeletal changes which will further improve surgical outcome. [2]

The piriform aperture (PA) is the skeletal aperture located in the middle part of the face and limited by the frontal processes of the maxillary bones, the nasal bones, and the anterior nasal spine, palatal process of the maxilla inferiorly. It corresponds to the anterior limit of the skeletal nose, and a major component of the size of the nose and [3,4] the features of the piriform aperture have been reported as classic indicator of sexual differentiation. [5]

Most of investigation was done to investigate adaptive changes of human nasal morphology in living but there are little considerations of external bony nasal morphology and piriform aperture. The North Indian population has different ethnicity, racial changes and exposure to different climate. There are very few literatures available till date which deals with morphology of nasal bone and piriform aperture (PA). From a clinical and surgical point of view, it is interesting to perform piriform aperture (PA) measurements and shape evaluation, with

their sexual dimorphism. It would help surgeons in surgical modifications of this area for best suitable air passage modifications according to morphological and functional variations in Indian population.

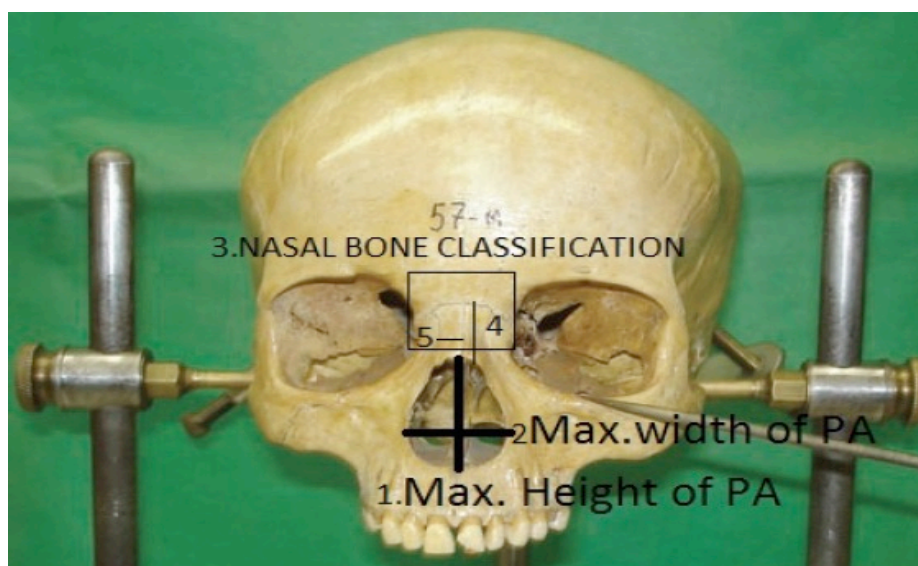
The present study was undertaken to evaluate the dimensions (maximal width and length), the size and the shape of the piriform aperture (PA) and nasal bone.

### Materials and Methods

Total 70 adult dry skulls of were collected from the Department of Anatomy of Lord Buddha Koshi Medical College and Hospital, Saharsa, Bihar, India. The study was carried out for the period of 1 year.

### Methodology

All measurements were taken using digital Vernier caliper accurate up to 0.001 mm. Nasion and anterior nasal spine was marked. Then nasomaxillary and internasal sutures were traced. Using landmarks defined by Hwang et al [3], measurements of piriform aperture (PA) and nasal bone were taken using digital Vernier calipers, Maximum height at the midline of (PA), width of (PA) at the upper and lower end, nasal bone length, nasal bone width and piriform aperture index (PAI) . The nasal bones were classified according to their shape, using the descriptions of Hwang et al. [3].



A male skull has thicker and more rounded orbital margins, pronounced supra orbital ridges and often a well-defined glabella that occupies the midline above the root of the nose. The temporal lines are more pronounced in the male and the supramastoid crest generally extends posterior to the external auditory meatus. The sites of muscle attachment on the skull are more prominent in male skull especially the mastoid process, nuchal and temporal lines when compared to that of female skull. [5] On the basis of above characteristics the sex distribution was 40 male and 30 female skulls.

So, the sex of skull was determined based on the following features. The male skull

is more robust and the female is more gracile. The female fore head is higher, more vertical and more rounded than the male, and there is a clear retention of the frontal eminences in the female.

**Analysis**

All data collected were thoroughly screened and entered into MS excel spread sheets and analysis was carried out. Differences in male and female skull were recorded and the mean calculated. The calculated mean was analyzed using SPSS statistical software. Sex determination of skull is required to assess sexual dimorphism.

**Results**

**Table 1: Showing measurements of the piriform aperture in skulls by sex**

Type of measurements	Sex	Sample size	Mean ± S. D.	t	P value
Height of piriform aperture	Male	40	36.4 ± 1.8	9.30	<0.001
	Female	30	26.6 ± 1.6		
Upper width of piriform aperture	Male	40	16.6 ± 2.6	0.70	0.59
	Female	30	15.5 ± 2.5		
Lower width of piriform aperture	Male	40	24.6 ± 1.5	0.40	0.75
	Female	30	24.4 ± 1.3		

It is evident from Table 1 that height, upper width and lower width of piriform aperture were greater in male as compared to female. This difference was not statistically significant for upper width of piriform aperture (p=0.59) and for lower width of piriform aperture (p= 0.75) while the difference in height of piriform aperture was statistically significant. (p <0.0001).

**Table 2: Showing measurements of the nasal bone in skulls by sex**

Type of measurements	Sex	Sample size	Mean ± S.D.	t	P value
Height of nasal bone	Male	40	16.6 ± 2.4	0.80	0.44
	Female	30	16.4 ± 2.2		
Width of nasal bone	Male	40	10.8 ± 1.5	0.70	0.60
	Female	30	10.4 ± 1.7		

Differences in Height and width of nasal bone were not and width of nasal bone were not statistically significant among male and female nasal bones.(Table 2)

**Table 3: Showing shape of piriform aperture**

S. No.	Shape of piriform aperture	Male	Female	Total
1.	Long and Narrow	3	2	5(7.14%)
2.	Triangular	8	4	12 (17.14%)
3.	Triangular to oval	20	15	35 (50%)
4.	Tending to Roundness	7	9	16(22.85%)

Shapes of nasal bone were classified as A, B,C,D and E as mentioned by Hwang et al. Most common shape of nasal bone observed was Type A followed by Type B and C. (Table 3)

### Discussion

Information concerning the nasal bone and piriform aperture is quite important, and preoperative evaluation of anatomy will ensure better performance and good outcome during surgery. The size and the shape of the nasal bones and piriform aperture show racial differences, characteristics which can be used in anthropologic classification.

The data pertaining to the nasal bone and piriform aperture is important especially, in preoperative evaluation of anatomy will ensure better performance and good outcome during surgery. The size and the shape of the nasal bones and piriform aperture shows racial differences these characteristics can be used in anthropologic classification. It has been noted that nasal bone type A (45%) is predominant in North Indian population, followed by Type C (20%), Type D and E and least Type E Adil Asghar, et al. [6]

Adult human skulls were used for morphometric study of nasal bone and piriform aperture. It is evident from Table 1 that height, upper width and lower width of piriform aperture were greater in male as compared to female. The difference in height of piriform aperture was statistically significant. ( $<0.0001$ ). Height of piriform aperture in a study by Durga Devi et al [7] on south Indian population was  $31.2 \pm 1.3$  mm in male  $27.2 \pm 1.3$  mm in female while in a study done by Cantin et al on Brazilian dry skull was  $50.82$  mm in male  $47.53$  mm in female. [8]

In present study PA height was  $36.4 \pm 1.8$  mm in males and  $26.6 \pm 1.6$  mm in females. In a study done by Asghar et al 6 on North Indian the mean Height of PA was  $29.57 \pm 3.28$  mm in females and  $31.16 \pm 3.58$  mm in males which

corresponds with present study. Upper width of piriform aperture was  $15.6 \pm 2.4$  mm in male  $16.6 \pm 2.8$  mm in female in a study conducted by Durga Devi et al on south Indian population. [7]

In present study, upper width of piriform aperture was greater in male as compared to female. This difference was not statistically significant for upper width of piriform aperture ( $p=0.49$ ). Hwang et al reported lower width of PA  $25.7 \pm 1.7$  mm in males and  $25.4 \pm 2.1$  in females. [1] Durga Devi et al observed lower width of PA in male  $24.03 \pm 1.4$  mm and  $24.4 \pm 2.3$  mm in female. [7]

Height of Nasal bone in present study is  $16.6 \pm 2.4$  mm in male and  $16.4 \pm 2.2$  in female. (Table 2) In a study of Turkish population by Yüzbasıoğlu N et al, height of nasal bone was  $18.7$  mm in male and  $17.2$  mm in female. [9] Baek et al in a study carried out study in Korean population and that height of nasal bone was  $22$  mm in male and  $17.3$  in females. [10]

According to Of Odile, the shape of the piriform aperture was oval (equivalent to types III and IV) in Ashanti, triangular (type II) in Austrians and American Indians, and varied from oval to triangular in black Americans (type III). [9] It was observed that the most common was the type I (pear -  $39.1\%$ ) and the less common were type III (diamond -  $0.0\%$ ), type II (inverted heart -  $1.6\%$ ) and type IV (inverted heart -  $3.1\%$ ). [11] Maximum width of PA in present study is  $24.15$  mm (Male  $24.9 \pm 1.59$  mm & Female  $22.77 \pm 1.57$  mm  $p=0.0105$ ). Moreddu et al., also measured mean PA Width as  $24.00$  mm ( $\pm 1.77$ ) in females and  $25.32$  mm ( $\pm 1.86$ ) in males. Male has higher value on Student t-test with  $p < 0.001$ . [12,13]

### Conclusion

The width of piriform shows an equal average for both sexes. The results obtained in this study showed the importance of the morphological

knowledge of the piriform aperture. As the skeletal structure of human face is influenced by environmental factors specific standards of assessment must be drawn and applied to particular population under consideration. Thus the present study may be useful for anthropologist, forensic researchers, otorhinologist and plastic surgeons.

### References

1. Yokley TR. Ecogeographic variation in human nasal passages. *American Journal of Physical Anthropology: The Official Publication of the American Association of Physical Anthropologists*. 2009 Jan;138(1):11-22.
2. Karadag D, Ozdol NC, Beriat K, Akinci T. CT evaluation of the bony nasal pyramid dimensions in Anatolian people. *Dent maxillofacial radiology*. 2011 Mar;40(3):160-4.
3. Hwang TS, Song J, Yoon H, Cho BP, Kang HS. Morphometry of the nasal bones and piriform apertures in Koreans. *Annals of Anatomy-Anatomischer Anzeiger*. 2005 Sep 1;187(4):411-4.
4. Gray H, Standring S, Ellis H, Berkovitz BKB. *Gray's anatomy: the anatomical basis of clinical practice*. 39th ed. Edinburgh: Elsevier Churchill Livingstone; 2005.
5. Standring S. *The anatomical basis of clinical practice* 40th Edition. Philadelphia: Elsevier Churchill Livingstone. 2008:978-80.
6. Asghar A, Dixit A, Rani M. Morphometric study of nasal bone and piriform aperture in human dry skull of Indian origin. *Journal of clinical and diagnostic research: JCDR*. 2016 Jan;10(1):AC05.
7. Durga D, Archana R, Johnson W. Morphometric study of nasal bone and piriform aperture in human dry skull of South Indian origin. *Int J Anat Res*. 2018; 6:5970-73.
8. López MC, Galdames IC, Matamala DA, Smith RL. Sexual Dimorphism Determination by Piriform Aperture Morphometric Analysis in Brazilian Human Skulls. *International Journal of Morphology*. 2009 Jun 1;27(2).
9. Karadag D, Ozdol NC, Beriat K, Akinci T. CT evaluation of the bony nasal pyramid dimensions in Anatolian people. *Dent maxillofacial radiology*. 2011 Mar;40(3):160-4.
10. Baek HJ, Kim DW, Ryu JH, Lee YJ. Identification of nasal bone fractures on conventional radiography and facial CT: comparison of the diagnostic accuracy in different imaging modalities and analysis of interobserver reliability. *Iranian Journal of Radiology*. 2013 Sep; 10(3):140.
11. De Araujo T. M. S., Da Silva C. J. T., De Medeiros I. K.N., Estrela Y. C. A., Silva N. A., Gomes F. B., Assis, T.O. & Oliveira A. S. B. Morphometric analysis of piriform aperture in human skulls. *Int. J. Morphol.*,2018;36(2):483-487.
12. Moreddu E, Puymeraill L, Michel J, Achache M, Dessi P, Adalian P. Morphometric measurements and sexual dimorphism of the piriform aperture in adults. *Surg Radiol Anat*. 2013;35(10):917-24.
13. Atbib Y., Essad A., Zhar H., Tadlaoui yasmina., Ait El Cadi M., & Bousliman Y. Impact de l'immunothérapie dans la prise en charge du cancer du poumon « Etude rétrospective menée à l'Hôpital Militaire d'Instruction Mohammed V-Rabat. *Journal of Medical Research and Health Sciences*, 2022;5(9): 2221–2243.