e-ISSN: 0975-5160, p-ISSN: 2820-2651

Available online on www.ijtpr.com

International Journal of Toxicological and Pharmacological Research 2023; 13(1); 01-08

O.riginal Research Article

Clinical Outcome after Microscopic Assisted Antegrade Parotidectomy: A Retro-Spective Observational Study

S. K. Pippal[1], Dinesh Kumar[2], Vrashabhan Ahirwar[3], Jaymala S Malbhage[4]

[1]Professor and Head, Department of E.N.T., Bundelkhand Medical College, Sagar, M.P. India.

[2]Assistant Professor, Department of E.N.T., Bundelkhand Medical College, Sagar, M.P. India.

[3]Assistant Professor, Department of Radiodiagnosis., Bundelkhand Medical College, Sagar, M.P. India.

[4]Senior Resident, Department of E.N.T., Bundelkhand Medical College, Sagar, M.P. India.

Received: 30-10-2022 / Revised: 30-11-2022 / Accepted: 15-12-2022

Corresponding author: Dr Dinesh kumar

Conflict of interest: Nil

Abstract

Aim objective: The most common type of benign salivary gland tumor is Pleomorphic adenoma. 75% of such tumors occur in the parotid glands. During parotid surgery identification and preservation of facial nerve trunk and its branches is very important. Advancement of microsurgical technique has helped in better visualization, identification and preservation of the facial nerve.

Methods: This is retrospective observational study on twenty- eight patients. Preoperative ultrasonography and fine needle aspiration cytology were done for all cases. Computed tomography/magnetic resonance imaging were performed in some cases when needed. Standard surgical technique antegrade parotidectomy was performed by using with microscope. Data analysis was done using SPSS.

Results: The patient's age ranged from 20 to 70 years. 57.14% patients were male and 42. 86% were females. In Seventeen patients, a 60.71% tumor was located on the right side whereas in 11 patients, (39.28%) it was on the left side. Most of the tumors were Pleomorphic adenoma (78.5%). Most commonly performed surgery was superficial parotidectomy (89.28%). Postoperative 7.14% patients had temporary facial paralysis, 3.57% patient had developed a flap necrosis and 3.57% had permanent facial paralysis. Frey's syndrome was found in none in follow-up.

Conclusion: The surgeon's experience is the main guarantee for facial nerve preservation and low recurrence rates during parotidectomy. Our study found that microscopic assisted antegrade parotidectomy led to fewer complications than reported with conventional methods. The use of a microscope in surgery may represent a useful tool in improving accuracy and minimizing local tissue trauma and thus decreasing facial nerve paresis.

Keywords: Antegrade parotidectomy, Facial nerve trunk, microsurgical technique

Introduction

Salivary gland tumors account for about 3-5% of all the head and neck neoplasm. About 75% of such tumors occur in the parotid glands [1,2] Pleomorphic Adenoma (PA) is the most common type of benign salivary gland tumor comprising 40-60% of all salivary gland tumors [3].

It is seen more frequently in the fourth and fifth decades of life, particularly in females [4] Pleomorphic adenoma a benign tumor occurs when epithelial and myoepithelial cells are organized in different morphological systems [5]. It generally appears as a mass that is painless, slow-growing, and does not affect the facial nerve functions, in the parotid [6].

Parotidectomy is a common surgical procedure for parotid tumor [7] In total parotidectomy, the parotid tissue present on the lateral and medial side of the nerve has to be removed, whereas in case of superficial parotidectomy, the parotid tissue lateral to the facial nerve has to be removed along with the tumor. In extracapsular dissection, 2 to 3 mm rim of healthy tissue should be removed together with the tumor [8].

Although parotidectomy is a well-known and safe procedure if correctly performed, immediate postoperative facial nerve weakness may occur in 10% to 40% of patients treated for a benign neoplasm [9] whereas permanent postoperative facial weakness has been described in 1% to 7.1% of patients [9-15] Malignant lesions are generally related to a higher rate of postoperative palsy.

The concept of the microsurgical method in parotid surgery is a recent technique. The use of a microscope in such surgeries is to improve the clarity of dissection, to identify the trunk and branches of the nerve. The main aim of this research is to focus on postoperative preservation of facial nerve function and clinical/oncologic outcomes according to histology in Microscopic Assisted Parotidectomy (MAP).

Methods

This is retrospective observational study involving 28 patients, conducted in the Department of Otolaryngology and Head and Neck Surgery, Bundelkhand Medical College, Sagar, Madhya Pradesh from September 2019 to March 2022. The entire patient was followed for 6 month duration.

Informed consent was taken from all the patients included in the study. Medical history was collected before admission.

Preoperative ultra-sonography and Fine Needle Aspiration Cytology (FNAC) were done in all cases. Preoperative diagnosis was based on the preoperative FNAC. Computed Tomography (CT) and Magnetic Resonance Imaging (MRI) were performed if necessary. The patients who had undergone surgery by ante-grade method for parotid tumor with stage T1-T4a, any N, M0 and those patients requiring revision surgery were included in the study. Tumors with stage T4b, M1and those performed with the retrograde method were excluded

Post-operatively Facial nerve function was evaluated, on the first day after surgery, after one month and at three months after surgery using the House-Brackmann scale [16] completed with the description of the function of all the facial nerve branches (frontal, zygomatic, buccal, mandibular). Patients underwent either superficial (removal of all the parotid tissue above the facial nerve) or total parotidectomy (extended to all parotid tissue including the deep lobe of the gland), according to the extension of the tumor. We never performed enucleation or extra-capsular dissection.

This study also considered the correlation between facial nerve dysfunction, histology and surgical complexity (total parotidectomy and superficial parotidectomy, benign neoplasm of the superficial and deep lobe,

inflammatory lesions of the superficial and deep lobe, facial nerve schwannoma).

The statistical significance of the different patient populations was tested with the chi-square test, considering significance when p was less than 0.05.

Surgical technique

All the cases were performed under general anesthesia. Required aseptic precaution was taken. Local infiltration was done with 2% xylocaine or 1:200000 adrenaline solution in the incision line. Modified Blair incision was given. (Figure no 1A) The anterior and posterior flaps were elevated. Facial nerve dissection was always performed coupling the intraoperative microscope (ZEISS, focal length 250 mm) (figure no 1B) and with NIM (Medtronic NIM Response® 3.0-4 channels). Typical parameters used at our institution are: stimulus intensity of 0.5-0.7 mA, duration of the stimulus of 100 µsec, rate of the stimuli of 4 bursts/sec and event threshold of 100 µV. Greater Auricular nerve was identified and the posterior branch was preserved. The main concept behind the antegrade parotidectomy is to identify the main trunk of the facial nerve coming from the stylomastoid foramen. The trunk of facial nerve lies about 1cm deep and inferior to the tragal point. Another landmarks needed to identify the trunk are tympano-mastoid suture, posterior belly of digastric and mastoid tip. In contrast to an antegrade method, the retrograde method requires identification of the buccal branch of the facial nerve which is about 4 cm anterior to the tragus along the alatragal line. This branch is dissected in a retrograde fashion as far as the main trunk of the facial nerve. The remaining branches of the facial nerve are dissected in an antegrade fashion. (Figure 2, 3) [17].

Results

The mean age of the patients was 46 years, with a range from 20 to 70 years. Sixteen (57.14%) patients were male and 12(42. 86%) were females. In Seventeen patients, (60.71%) tumor was located on the right side whereas in 11 patients, (39.28%) tumor was on the left side. The average operation time in the superficial parotidectomy group was 2 hours and 30 minutes (range: 2 hours to 3hours and 40 minutes) and for total parotidectomy, the average operation time was 3 hours 30 minutes (range: 2 hours 50 minutes to 6hours 30 minutes).

Table 1: Types of parotid tumor (N=28)

S.N	Types of parotid tumor (N=28)	Frequency (%)
1.	Pleomorphic adenoma	22(78.5)
2.	Monomorphic adenoma	2(7.14)
3.	Mucoepidermoid carcinoma	2(7.14)
4.	Schwannoma	1(3.57)
	Total	28(100)

Table 2: Treatment of parotid tumor

S.N	Type of surgery	Frequency (%)
1.	Superficial adequate parotidectomy	24(85.71)
2.	Total conservative parotidectomy	2(7.14)
3.	Selective (Partial) Superficial Parotidectomy	2(7.14)

Table 3: Postoperative complications

S.N	Postoperative complication	Frequency (%)
1.	Temporary Facial paralysis	2(7.14)

2.	Permanent Facial paralysis	1(3.57)
3.	Flap necrosis/seroma	1(3.57)
4.	Parotid fistula	0(00)
5.	Frey's syndrome	0(00)

Figure 1: Modified Blair incision and microscopic assisted parotidectomy

Figure 1B

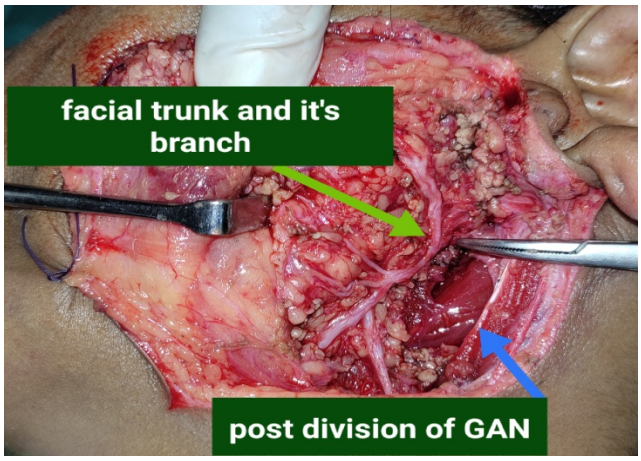

Figure 2: Intraoperative microscopic view of the Right main trunk and the branches of the facial nerve.

Figure 3: Postoperative specimen

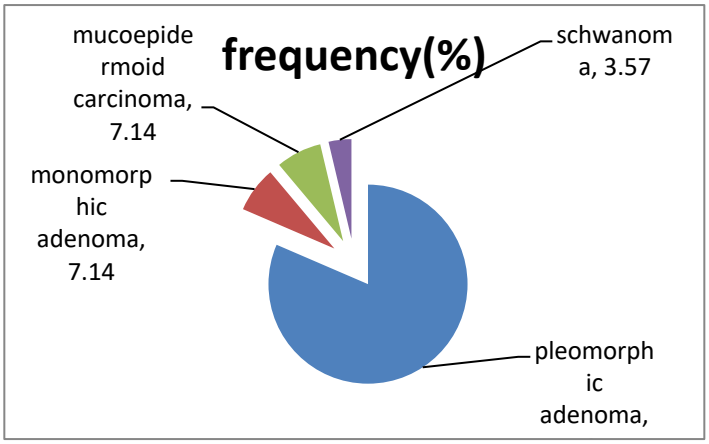

Figure 4: Type of tumor and frequency distribution

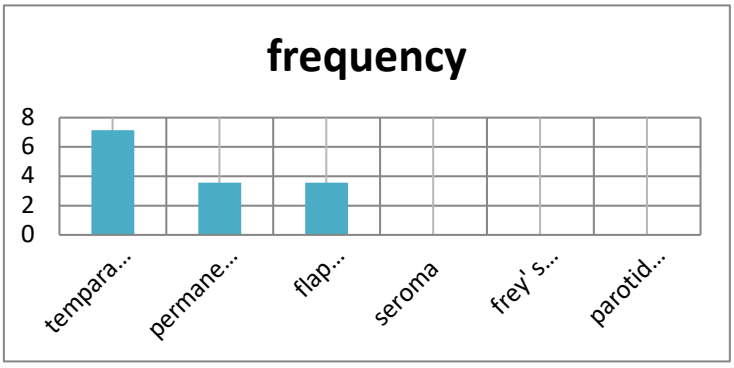

Figure 5: Distribution of postoperative complication

Most of the tumors were Pleomorphic adenoma (n=22, 78.5%) (Table1, figure no 4). Most commonly performed surgery was superficial adequate parotidectomy (25, 89.28%) (Table 2).

Post-operative complications were assessed. In our study two (7.14%) patients had temporary facial paralysis (grade 2) which improved with time. One (3.57%) patient had developed flap necrosis. One (3.57%) patient had permanent

facial paralysis (grade 4) as the nerve was sectioned due to overstretching. Complications such as Frey's syndrome, seroma, parotid fistula did not happen in our patients. (Table no 3, figure no 5)

No recurrence has occurred after surgery for benign lesions till date.

Discussion

In the early 20th century, parotid surgery was concerned more with damaging either the trunk or branches of the facial nerve rather than the recurrence of the disease [18] In those days, injury to the facial nerve was avoided by simple enucleation of the tumor. Recurrence rate was high (20-40%) in such cases [19] Superficial parotidectomy was performed in an attempt to lower the recurrence rate. A study by Webb A and Eveson J reported 1-4% of recurrence rate while using the above procedure [20] In the present series we did not observe any spillage of the tumor as a consequence of accidental rupture of the capsule, and we did not observe recurrence of benign tumors.

In our study, 85.64 % of tumors were found to be benign, whereas in the study done by Bussu *et al* [21] 88.7% cases were benign. Superficial or total parotidectomy was considered the standard method for the treatment of parotid tumors [22-24] Undesired complications were seen because the tumor was in contact with one or more branches of facial nerve and due to involvement of deep lobe and parapharyngeal space [25,26]. We applied modified Blair incision in all cases.

The posterior branch of the greater auricular nerve was saved which supplies lobule and infrauricular area. We closed wounds meticulously thereby providing better cosmetic results [27] Aid of the microscope in surgery helps in better visualization of not only the main trunk of the facial nerve but also its branches [28]. We first identified the main trunk of the facial nerve then followed the branches. According to Witt *et al*., tympanomastoid suture is the key structure used to identify the main trunk of the facial nerve [29]. The main trunk of the nerve is identified and isolated where it emerges from the stylo-mastoid foramen, through the three classical landmarks: mastoid tympanic sulcus, the "pointer" and the posterior belly of the digastric muscle [30]

In our study, 7.14% of patients had temporary facial paralysis which improved over time. One (3.57%) had permanent facial paralysis as the nerve was sectioned due to overstretching. Mantsopopulos *et al* [31] reported a 1.9% rate of postoperative permanent facial palsy after extra-capsular dissection for benign neoplasm of the superficial lobe

None of the patients developed Frey's syndrome post-surgery. But is recognized that a high proportion of patients will develop Frey's syndrome after parotidectomy [32,33].

We felt that microscope aided surgery was better than conventional method because it gives better magnification and visualization, which helps in identifying the facial main trunk and its branches as well as easy dissection of the tumor from nerve trunk and branches. But it is difficult to handle for learning surgeons since it has slow and steady learning curve.

Conclusions

The surgeon's experience is the main guarantee for facial nerve preservation and low recurrence rates during parotidectomy. In our experience most of tumors were Pleomorphic adenoma, for benign tumors superficial parotidectomy is safe procedure as it does not directly involve the nerve thus minimize risk for the facial nerve injury.

Our study found that microscopic assisted antegrade parotidectomy led to fewer complications than reported with conventional methods. The use of a microscope in surgery may represent a useful tool in improving accuracy and minimizing local tissue trauma and thus decreasing facial nerve paresis.

Acknowledgement

Special thanks to department of Radiodiagnosis and pathology for co-operation and support.

References

1. Hoda SA, Hoda RS. Rubin's pathology: Clinicopathologic foundations of medicine. The Journal of American Medical Association. 2007;298(17):2070-75.
2. Spiro RH. Salivary neoplasms: overview of a 35-year experience with 2,807 patients. Head Neck Surg. 1986;8(3):177-84. PMID: 3744850.
3. Woods JE, Chong GC, Beahrs OH. Experience with 1,360 primary parotid tumors. The American Journal of Surgery 1975;130(4):460-62.
4. Emodi O, El-Naaj IA, Gordin A, Akrish S, Peled M. Superficial parotidectomy versus retrograde partial superficial parotidectomy in treating benign salivary gland tumor (pleomorphic adenoma). J Oral Maxillofac Surg 2010; 68: 2092-8.
5. Redaelli de Zinis LO, Piccioni M, Antonelli AR, Nicolai P. Management and prognostic factors of recurrent pleomorphic adenoma of the parotid gland: personal experience and review of the literature. Eur Arch Otorhinolaryngol 2008; 265: 447-52. [CrossRef]
6. Stennert E, Wittekindt C, Klussmann JP, Arnold G, Guntinas-Lichius O. Recurrent pleomorphic adenoma of the parotid gland: a prospective histopathological and immunohistochemical study. Laryngoscope 2004; 114: 158-63.
7. Carta F, Chuchueva N, Gerosa C, Sionis S, Caria R, Puxeddu R. Parotid tumours: clinical and oncologic outcomes after microscopeassisted parotidectomy with intraoperative nerve monitoring. Acta Otorhinolaryngologica Italica. 2017;37(5):375-86.
8. Klintworth N, Zenk J, Koch M, Iro H. Postoperative complications after extracapsular dissection of benign parotid lesions with particular reference to facial nerve function. The Laryngoscope. 2010;120(3):484-90.
9. Sood AJ, Houlton JJ, Nguyen SA, *et al*. Facial nerve monitoring during parotidectomy: a systematic review and metaanalysis. Otolaryngol Head Neck Surg 2015;152:631-7.
10. Reza Nouraei SA, Ismail Y, Ferguson MS, *et al*. Analysis of complications following surgical treatment of benign parotid disease. ANZ J Surg 2008;78:134-8.
11. Koch M, Zenk J, Iro H. Long-term results of morbidity after parotid gland surgery in benign disease. Laryngoscope 2010; 120: 724-30.
12. Guntinas-Lichius O, Kick C, Klussmann JP, *et al*. Pleomorphic adenoma of the parotid gland: a 13-year experience of consequent management by lateral or total parotidectomy. Eur Arch Otorhinolaryngol 2004;261:143-6.
13. Guntinas-Lichius O, Klussmann JP, Wittekindt C, Stennert E. Parotidectomy for benign parotid disease at a University Teaching Hospital: outcome of 963 operations. Laryngoscope 2006;116:534-50.
14. Yuan X, Gao Z, Jiang H, *et al*. Predictors of facial palsy after surgery for benign parotiddisease:multivariate analysis of 626 operations.Head Neck 2009;31:1588-92.
15. Bron LP, O'Brien CJ. Facial nerve function after parotidectomy. Arch Otolaryngol Head Neck Surg 1997;123:1091-6.
16. House JW, Brackmann DE. Facial nerve grading system. Otolaryngol Head Neck Surg 1985;93:146-7.
17. Anjum K, Revington P, Irvine GH. Superficial parotidectomy: antegrade compared with modified retrograde dissections of the facial nerve. British Journal of Oral and Maxillofacial Surgery. 2008;46(6):433-34.

18. Janes RM. Tumours of the Parotid Gland. Ann R Coll of Surg Engl. 1957;21(1):1-20.
19. Park SY, Han KT, Kim M, Lim JS. Recurrent Pleomorphic Adenoma of the Parotid Gland. Arch Craniofac Surg. 2016;17(2):90-92. PMID: 28913262.
20. Webb AJ, Eveson JW. Pleomorphic adenomas of the major salivary glands: a study of the capsular form in relation to surgical management. Clinical Otolaryngology & Allied Sciences. 2001;26(2):134-42.
21. Bussu F, Parrilla C, Rizzo D, Almadori G, Paludetti G, Galli J. Clinical approach and treatment of benign and malignant parotid masses, personal experience. Acta Otorhinolaryngol Ital. 2011;31(3):135-43.
22. Harish K. Management of primary malignant epithelial parotid tumors. Surgical Oncology. 2004;13(1):7-16.
23. Johnson JT, Ferlito A, Fagan JJ, Bradley PJ, Rinaldo A. Role of limited parotidectomy in management of pleomorphic adenoma. J Laryngol Otol. 2007;121(12):1126-8.
24. O'Brien CJ. Current management of benign parotid tumors--the role of limited superficial parotidectomy. Head Neck. 2003;25(11):946-52.
25. Frankenthaler RA, Luna MA, Lee SS, Ang KK, Byers RM, Guillamondegui OM, *et al*. Prognostic variables in parotid gland cancer. Arch Otolaryngol Head Neck Surg. 1991;117(11):1251-6.
26. Hoff SR, Mohyuddin N, Yao M. Complications of parotid surgery. Operative Techniques in Otolaryngology-Head and Neck Surgery. 2009;20(2):123-30.
27. Salgarelli AC, Bellini P, Consolo U, Collini M. Technical tips for a cosmetic approach to parotid surgery. Journal of Craniofacial Surgery. 2012;23(2):e106-e108.
28. Nicoli F, D'Ambrosia C, Lazzeri D, Orfaniotis G, Ciudad P, Maruccia M, *et al*. Microsurgical dissection of facial nerve in parotidectomy: a discussion of techniques and long-term results. Gland Surgery. 2017;6(4):308-14.
29. Witt RL. Facial nerve function after partial superficial parotidectomy: An 11-year review (1987-1997). Otolaryngol Head Neck Surg. 1999;121(3):210-3.
30. Pia F, Policarpo M, Dosdegani R, *et al*. Centripetal approach to the facial nerve in parotid surgery: personal experience. Acta Otorhinolaryngol Ital 2003;23:111-5
31. Mantsopoulos K, Koch M, Klintworth N, *et al*. Evolution and changing trends in surgery for benign parotid tumors. Laryngoscope 2015;125:122-7.
32. McGurk M, Renehan A, Gleave E, Hancock BD. Clinical significance of the tumour capsule in the treatment of parotid pleomorphic adenomas. British journal of surgery 1996;83(12):1747-49.
33. Rodopoulou S, Keramidas E, Metaxotos N, Tagaris G, Tsati E, Ioannovich J. Treatment of Frey's syndrome using botulinum toxin type A. European Journal of Plastic Surgery. 2001;24(6):297-302.