

A Morphometric Assessment of Diverse Locations of Greater Palatine Foramen in Dry Human Skulls

Rajesh Ranjan

Assistant Professor, Department of Anatomy, Shri Ramakrishna Institute of Medical Sciences & Sanaka Hospital, Durgapur, West Bengal, India

Received: 10-05-2023 / Revised: 21-06-2023 / Accepted: 23-07-2023

Corresponding Author: Dr. Rajesh Ranjan

Conflict of interest: Nil

Abstract

Aim: The aim of the present study was to measure the location of greater palatine foramen (GPF), according to clinically identifiable anatomical landmarks.

Methods: The study was performed on 50 dry human skulls. The skulls were obtained from Department of Anatomy.

Results: The situation of the GPF in relation to 3rd maxillary molar was in 20 of the skulls. The average values of the distance between the GPF & midline palatine suture (MPS) & posterior border of hard palate (PBHP) were 16.4 mm (SD 1.4) & 6.4 mm (SD 1.3), respectively.

Conclusion: Diverse locations of greater palatine foramen arouse difficulties in locating exact position during anaesthesia. Therefore, understanding the different positions of greater palatine foramen can help surgeons to improve their surgical procedures.

Keywords: Greater palatine foramen, Hard palate, Maxillary molars, Pterygopalatine ganglion, Nerve block.

This is an Open Access article that uses a funding model which does not charge readers or their institutions for access and distributed under the terms of the Creative Commons Attribution License (<http://creativecommons.org/licenses/by/4.0>) and the Budapest Open Access Initiative (<http://www.budapestopenaccessinitiative.org/read>), which permit unrestricted use, distribution, and reproduction in any medium, provided original work is properly credited.

Introduction

Most of the textbooks locate the foramen in a general way, e.g. near the lateral palatal border, [1] in the posterolateral border, [2] medial to last molar [3] or opposite to the last molar. [4] The position of the GPF in relation to the maxillary molars is stated to be opposite the second molar, [5] opposite to the third molar or anywhere between the second and third molars. [6]

The greater palatine nerve block is common during procedures on the maxillary teeth and palate, however the common problem reported for this application is not easy to locate the exact location of the foramen, thus providing insufficient anaesthesia solution. [7] The foramen is also essential for the access to the palatine canal for reaching the pterygopalatine ganglion. [8,9] Among four parasympathetic ganglions of head and neck region, pterygopalatine ganglion is largest parasympathetic ganglion. It is located in pterygopalatine fossa. Greater palatine nerve is a ganglionic branch of maxillary nerve, which passes through pterygopalatine ganglion without relay. [10] After entering greater palatine foramen, greater palatine nerve along with greater palatine vessels runs through greater palatine canal up to incisive foramen. It supplies the mucous membrane & glands of hard palate and gingivae of maxillary teeth. [10]

Knowledge of location of greater palatine foramen is needed to achieve anaesthesia over hard palate & gingivae of maxillary teeth. Diverse locations of greater palatine foramen produce difficulties while performing anaesthesia of maxillary nerve. [11] This method is high in success rate with minimum risk for obtaining a maxillary block. [12] Most frequent method is used for a maxillary nerve block is via greater palatine canal. Maxillary nerve block through greater palatine canal was first described in 1917 by Mendel. [13] A needle is inserted in greater palatine foramen and pushed forward until it is in the inferior part of the pterygopalatine fossa. In pterygopalatine fossa, anesthetic agent is given. [14] Hence this study was undertaken to define the diverse locations of the greater palatine foramen in regards to several anatomical landmarks.

Material & Methods

The study was performed on 50 dry human skulls. The skulls were obtained from Department of Anatomy, Shri Ramakrishna Institute of Medical Sciences & Sanaka Hospital, Durgapur, West Bengal, India for one year.

Exclusion Criteria

Skulls with damaged, mutilated and deformed hard palate were excluded from the present study

Methodology

All the skulls used for the study were dry, complete & showed presence of third molar either dentate or edentate.

Following observations were recorded in millimeters, using digital vernier caliper:

1. Distance between the medial edge of greater palatine foramen (GrPF) to the mid sagittal plane (MSP) → GrPF-MSP.
2. Distance between the anterior edge of GrPF to the posterior boundary of incisive fossa (IF) → GrPF-IF.
3. Distance between the posterior edge of GrPF to the point of maximum concavity of the posterior border of hard palate (PBHP) → GrPF-PBHP.
4. Shape of the greater palatine foramen → it was recorded as oval, round or irregular.
5. Location of the GrPF in relation to maxillary molar teeth.

6. Direction of the opening of the greater palatine canal into the oral cavity → for determining the direction of opening of the foramen on the palate, a 26 gauge needle was inserted into the greater palatine foramen. The directions were recorded as: anterolateral, anteromedially and anteriorly.

7. Number of lesser palatine foramina (LPF)

All measurements were taken bilaterally & directly on dry skulls.

Statistical Analysis

After the data collection, data were analyzed through the standard statistically software (SPSS). The mean, standard deviation, minimum and maximum for each measurement were assessed. The t-test was used to confirm the significant differences between the means obtained from the distances of each antimere of the GPF & reference points.

Results

Table 1: Variations in the location of greater palatine foramen in relation to maxillary molars

Group	Medial to 2nd molar	Between 2nd & 3rd molars	Medial to 3rd molar	Behind 3rd molar
Right	12	8	20	10
Left	13	7	20	10
Total	25	15	40	20

The situation of the GPF in relation to 3rd maxillary molar was in 20 of the skulls.

Table 2: Distance (mm) of greater palatine foramen from midline palatine suture (MPS) & distance (mm) of greater palatine foramen from posterior border of hard palate (PBHP) (values in mm)

Parameters	Mean	SD	Minimum	Maximum	Median
Right GPF-MPS Distance (mm)	16.4	1.4	12.8	18.2	15.5
Left GPF-MPS Distance (mm)	16.4	1.4	12.8	18.2	15.5
Right GPF-PBHP Distance (mm)	6.4	1.3	4.3	8.8	6.09
Left GPF-PBHP Distance (mm)	6.4	1.3	4.3	8.8	6.09

The average values of the distance between the GPF & midline palatine suture (MPS) & posterior border of hard palate (PBHP) were 16.4 mm (SD 1.4) & 6.4 mm (SD 1.3), respectively.

Table 3: T-test comparing the mean of antimere of each reference point

	Mean	Standard Deviation	P
Right GPF to MPS	16.4	1.4	
Left GPF to MPS	16.4	1.4	
Right GPF to PBHP	6.4	1.3	0.007
Left GPF to PBHP	6.4	1.3	

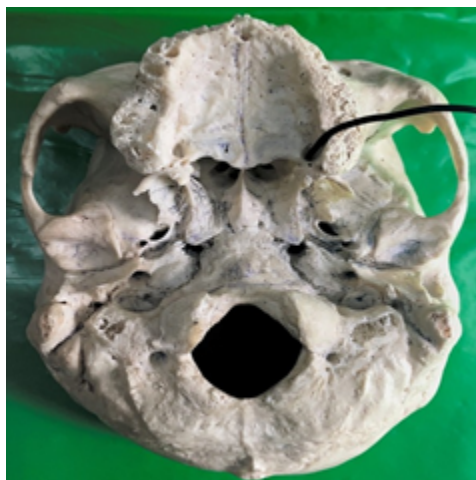


Figure 1: Probe in greater palatine foramen

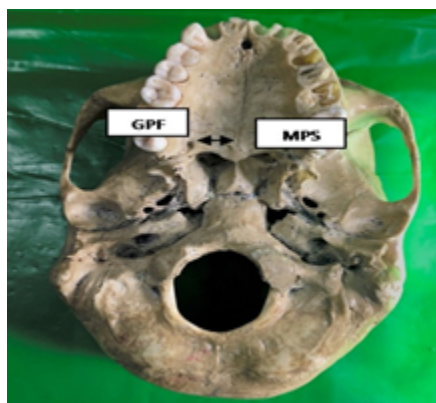


Figure 2: Shows distance between Greater palatine foramen (GPF) & Midline palatine suture(MPS)



Figure 3: Illustrates the measurement of distance from greater palatine foramen (GPF) to Median palatine suture (MPS)

Discussion

Palatine processes of maxillae bones and horizontal plates of palatine bones fused with each other by cruciform suture.¹⁰ Greater palatine foramen is situated in postero-lateral angles of hard palate. The foramen transmits greater palatine nerve & vessels. The maxillary artery is one of the terminal branches of external carotid artery and is divided into three segments by the lower head of the lateral pterygoid muscle. [15] The greater palatine artery arises from the third segment of the maxillary artery and enters

into greater palatine foramen alongside the greater palatine nerve. [10] The mucous membrane of the inferior meatus of the nose, hard palate, gingivae of the maxillary teeth and nasal septum receive blood supply from the greater palatine artery. [16]

The situation of the GPF in relation to 3rd maxillary molar was in 20 of the skulls. The average values of the distance between the GPF & midline palatine suture (MPS) & posterior border of hard palate (PBHP) were 16.4 mm (SD 1.4) & 6.4 mm (SD 1.3), respectively. Westmoreland &

Blanton [18] observed 50.70% of GPF were located medial to 3rd maxillary molar. In the study by Ajmani [17] 48.46% of GPF in Nigerian & 64% of GPF in Indian skulls were located medial or opposite of the 3rd maxillary molar. Saralaya & Nayak [19] observed 74.6% of GPF were located medial to 3rd molar. Hassanali & Mwaniki [20] observed 76% of GPF (in Kenyan skulls) were located medial to 3rd molar. In the study of Wang [21] 33.5% of GPF (in Chinese skulls) were located medial to 3rd maxillary molar. In the study of Langengger [22] 62% of GPF were located medial to 3rd molar. In our study, second most common site of GPF was between 2nd & 3rd molar (10%). GPF was medial to 2nd molar in 8% skulls & it was behind 3rd molar. The direction of GPF in the oral cavity was forward and medially in 46.2% and forward in 41.3%, as compared to 91.4% of Indian skulls. [23] In 82% of skulls, the GPF was directed forward. [17] The opening of the foramen was directed anterolaterally in a large number of Nigerian skulls (38.7%). [23] This explains the variability of the GPF in different races and different geographical regions. This observation may explain the occasional difficulty encountered during surgery when attempting to insert the point of needle into the GPF.

Conclusion

In this study, greater palatine foramen was near to 3rd maxillary molar tooth was found in 25% of the skulls. In regard of distance between GPF-MPS & GPF-PBHP, findings of this study are in line with previous studies except right and left side difference of GPF to PBHP. Diverse locations of greater palatine foramen arouse difficulties in locating exact position during anaesthesia. Therefore, understanding the different positions of greater palatine foramen can help surgeons to improve their surgical procedures.

References

- Williams PL, Warwick R, Dyson M, Bannister H. *Gray's Anatomy*. 37th ed. London, 1989: 354.
- Gardner E, Gray DJ, O'Rahilly R. *Anatomy*. 4th ed. Philadelphia: WB Saunders, 1975: 997.
- Moore KL. *Clinically Oriented Anatomy*, 1st ed. Baltimore: Williams and Wilkins, 1980: 1004.
- Romanes GJ. *Cunningham's Textbook of Anatomy*. 12th ed. New York: Oxford University Press, 1981: 116.
- Seldan HN. *Practical Anaesthesia for Dental and Oral Surgery*. 3rd ed. Philadelphia: Lea & Febiger, 1948: 206.
- Shane SME. *Principles of Sedation, Local and General Anaesthesia in Dentistry*. 1st ed. Illinois: Charles C. Thomas, 1975: 173.
- Douglas R, Wormald PJ. Pterygopalatine fossa infiltration through the greater palatine foramen: where to bend the needle. *The Laryngoscope*. 2006 Jul;116(7):1255-7.
- Teixeira CS, Souza VR, Marques CP, Junior WS, Pereira KF. Topography of the greater palatine foramen in macerated skulls. *Journal of Morphological Sciences*. 2017 Jan 16;27(2):0-.
- Howard-Swirzinski K, Edwards PC, Saini TS, Norton NS. Length and geometric patterns of the greater palatine canal observed in cone beam computed tomography. *Int J Dent*. 2010;2010.
- Data AK. *Essentials of human anatomy, Head & Neck, Part-II*. 5th ed. Kolkata: Books International Publication; 2009. p. 152-4.
- Blanton PL, Jeske AH. The key to profound local anesthesia: neuroanatomy. *J Am Dent Assoc*. 2003;134(6):753-60.
- Malamed SF. *Handbook of Local Anesthesia*. 5th ed. St. Louis: Elsevier Mosby, 2004.
- Mendel N, Puterbaugh PG. *Conduction, Infiltration & General Anesthesia in Dentistry*. 4th ed.
- Brooklyn NY, editor. Chicago: Dental Items of Interest Publishing Company; 1938. p. 140.
- Singh V. *Textbook of Anatomy, Head & Neck & Brain*. vol. Vol. III. 2nd ed. India: Elsevier; 2014. p. 23-137.
- Standing S. *Gray's Anatomy – The Anatomical basis of clinical practice*. 41st ed. Netherlands: Elsevier Health Sciences; 2016. p. 553.
- Westmoreland EE, Blanton PL. An analysis of the variations in position of the greater palatine foramen in the adult human skull. *Anat Rec*. 1982;204(4):383-8.
- Ajmani ML. Anatomical variation in position of the greater palatine foramen in the adult human skull. *J Anat*. 1994;184(Pt 3):635-7.
- Saralaya V, Nayak SR. The relative position of the greater palatine foramen in dry Indian skulls. *Singapore Med J*. 2007;48(12):1143-6.
- Hassanali J, Mwaniki D. Palatal analysis and osteology of the hard palate of the Kenyan African skulls. *Anat Rec*. 1984;209(2):273-80.
- Wang TM, Kuo KJ, Shih C, Ho LL, Liu JC. Assessment of the relative locations of the greater palatine foramen in adult Chinese skulls. *Acta Anat (Basel)*. 1988;132(3):182-6.
- Langenegger JJ, Lownie JF, Cleaton-Jones PE. The relationship of the greater palatine foramen to the molar teeth and pterygoidhamulus in human skulls. *J Dent*. 1983;11(3):249-56.
- Ajmani ML. Anatomical variation in position of the greater palatine foramen in the adult human skull. *Journal of anatomy*. 1994 Jun; 184(Pt 3):635.