RESEARCH PAPER

Severe Pulmonary Tuberculosis Requiring Critical Care Support: A Four-Patient Case Series

Mohammad Elghannam, Mostafa Gooda, Mohamed Allam, Leena Ahmed, Engy Abdallah, Khaled Mohammed Yehia, Rajesh Gupta, Moustafa Nabil Ewila, Reda Mohamed Sherif*
Kuwait Hospital Sharjah
*Corresponding author: Reda Mohamed Sherif, Reda.sherif@ehs.gov.ae

ABSTRACT
Background: Pulmonary tuberculosis may present as fulminant respiratory failure requiring prolonged intensive care in some cases. Case reports on prolonged ventilation, tracheostomy, delayed microbiologic confirmation, and variable outcomes give valuable insights for clinicians.
Case presentation: Four adults with severe pulmonary tuberculosis were managed in a critical care setting. Case 1 involved a woman with fibrocavitary pulmonary tuberculosis and an initial acid-fast bacillus (AFB) smear of 3+, complicated by respiratory failure, tracheostomy, recurrent superinfection, and prolonged rehabilitation prior to discharge on home oxygen. Case 2 was a forty-four-year-old male admitted with profound severe anemia, cachexia, and radiological scans showing miliary-pattern pulmonary TB with cavitary and consolidative disease; diagnosis was confirmed by serial positive AFB smears and TB PCR. His course was complicated by prolonged ventilation, septic shock, and eventual recovery to discharge. In case 3, a 46-year-old male with combined pulmonary fibrosis and emphysema, active pulmonary TB was microbiologically confirmed only after ICU deterioration, and he died despite maximal support. Case 4 was a 27-year-old female with extensive active post-primary pulmonary tuberculosis, AFB smear 3+, respiratory failure, mechanical ventilation, severe hypoxemic, and recovery after a complicated ICU stay.
Conclusion: Common themes were delayed or evolving confirmation, extensive parenchymal disease, and prolonged ventilatory support. The physiologic burden was great in the cases. Severe pulmonary TB should still be kept in mind in critical respiratory failure. This is particularly important in patients in whom radiology is suggestive or in whom management for suspected pneumonia does not entirely explain the course.
Keywords: Pulmonary Tuberculosis, Intensive Care Unit, Respiratory Failure, Mechanical Ventilation, Tracheostomy, Case Series
How to cite this article: Elghannam M, Gooda M, Allam M, Ahmed L, Abdallah E, Yehia KM, Gupta R, Ewila MN, Sherif RM. Severe Pulmonary Tuberculosis Requiring Critical Care Support: A Four-Patient Case Series. Int J Drug Deliv Technol. 2026;16(50s): 155-160. DOI: 10.25258/ijddt.16.50s.19
Source of support: Nil.
Conflict of interest: None

Introduction

Tuberculosis (TB), a pandemic disease caused by the bacillus Mycobacterium tuberculosis, is still a significant public health problem worldwide with an estimated 7.2 million newly diagnosed TB cases in 2022 [1, 2]. In the same year, TB ranked as the single leading cause of death from a single infectious agent, trailing only behind COVID-19, with its numbers nearly double that of deaths caused by the human immunodeficiency virus (HIV)/acquired immunodeficiency syndrome (AIDS) [1, 2]. The World Health Organization (WHO) describes death from TB as all-cause mortality during the plan of TB therapy, accounting for one million deaths during 2022 [1]. Pulmonary TB shows a subacute or chronic clinical course, identified by symptoms like cough, fever, weight loss, and hemoptysis; however, it can occasionally display as acute respiratory failure [3].

To reduce the risk of transmission, therapy aims to achieve complete bacterial clearance and lower the incidence of resistance [4]. In non-critical cases, the success rate of drug-susceptible TB under trial settings can reach 95%; this success is supported by sufficient blood concentrations of these medications [5].

Despite the availability of effective treatment protocols, mortality rates for severe tuberculosis (TB) that requires hospitalization to the intensive care unit (ICU) typically range from 15.5 to 65.9% [6]. Organ failure, respiratory insufficiency needing mechanical ventilation, sepsis, the presence of additional diseases, and delayed treatment are the most common risk factors linked to death [6]. Herein, we presented a case series consisting of four different adult cases that required critical care support in our ICU to control the severe pulmonary tuberculosis infection.

Cases presentation

Case 1

24 November 2024 presentation of an adult female patient with 3 weeks of dyspnea, persistent cough, fever, vomiting, abdominal pain, and progressive generalized weakness. On clinical examination, diffuse coarse crackles were noted with patchy bronchial breathing over the left upper chest.

Chest X-ray revealed bilateral air-space disease (Fig.

1-A). Chest CT demonstrated a large 6 cm cavitary lesion in the left upper lobe (high resolution). There was extensive patchy consolidation and reticular infiltrates in both lungs (Figure 1-B), consistent with advanced or reactivation pulmonary tuberculosis.

On November 25, 2024, initial microbiology tests showed a highly positive AFB smear (3+). The case rapidly worsened, and he had severe hypoxemic respiratory failure, vasopressor assistance, required ICU admission, and intubation. Multiple unsuccessful weaning actions resulted in anemia, acute kidney damage, hypernatremia, recurring septic episodes, coagulopathy, and numerous secondary infections, including Candida species and bacterial respiratory pathogens, which prolonged her stay in the ICU.

As ventilator dependence persisted, tracheostomy was considered in early December and later carried out percutaneously on 19 December 2024. Follow-up AFB smears

suggested slow infection clearance, as results were intermittently negative before turning positive again in early January.

During the following weeks, her state gradually improved; nevertheless, recovery was complicated by critical illness neuropathy/myopathy, bilateral foot drop, and continuous oxygen requirements. Follow-up chest radiography demonstrated partial regression of the bilateral pulmonary opacities during recovery (Figure 1-C).

On March 25, 2025, she was finally discharged on home oxygen with a rate of one liter per minute. Anti-TB treatment is planned to continue until August 25, 2025.

Case 2

A 44-year-old male electrician with no known chronic medical illness was transferred from Sharjah Airport on 11 October 2024 because of hypotension, generalized weakness, and hypoxemia. He described a six-month history of low-grade fever and dry cough associated with approximately 40 kg weight loss since April 2024, progressive anorexia, and marked constitutional decline. On presentation, he appeared cachectic and pale. Laboratory investigations reported severe anemia with a hemoglobin level of 5.8 g/dL, hyponatremia, profound hypoalbuminemia, and markedly elevated inflammatory markers.

The radiologic outcomes were highly indicative of advanced pulmonary TB. The admission chest CT scan showed diffuse bilateral micronodules with tree-in-bud opacities, extensive left upper lobe consolidation with cystic and cavitary changes (Figure 2-A), and extra-cavitary lesions in the right upper lobe, all of which were indicative of severe miliary-pattern pulmonary TB (Figure 2-B). Later follow-up scans showed significant interval improvement (Figure 2-D), but further chest radiographs obtained during the ICU course showed considerable bilateral airspace disease after intubation (Figure 2-C). Positive TB PCR tests and positive sputum AFB smears gave microbiologic proof.

Despite the early initiation of anti-T**B** medication, his health worsened within 48 hours, causing significant respiratory distress that progressed from supporting high-flow oxygen to endotracheal intubation on October 13, 2024, and ICU admission on October 14, 2024. His ICU stay was made worse by septic shock, prolonged sedation, substantial respiratory secretions, difficult ventilator liberation, severe malnutrition, and, eventually, a tracheostomy on November 5, 2024.

The hemodynamic condition and oxygenation gradually enhanced over the next few weeks. On January 26, 2025, He was finally decannulated and went home after he began to tolerate spontaneous breathing and tracheostomy mask trials.

Case 3

On December 21, 2024, a 46-year-old man was admitted with severe hypoxemic respiratory failure,productive cough, fever, vomiting, abdominal pain, and progressive generalized weakness. He also had allergic bronchopulmonary mycosis, heavy smoking, and a remote history of pulmonary tuberculosis.

Chronic structural lung disease with negative AFB smears was reported during a previous admission in September 2024. Emphysema, pulmonary fibrosis, bilateral apical reticulonodular infiltrates, cavitary alterations, left apical calcific foci, and honeycombing—all indicative of prior tuberculosis—were seen on radiographs. Combined pulmonary fibrosis and emphysema (CPFE) exacerbation exacerbated by sepsis and community-acquired pneumonia was the working diagnosis in December.

Due to growing respiratory failure, the patient needed increasing oxygen assistance and was finally intubated on January 2, 2025 (Figure 3-A, B). He experienced severe mixed acidosis, increasing vasopressor needs, oliguria, acute renal damage, hyperkalemia, and significant physiologic instability within the next 48 hours. Sputum AFB testing at that point yielded a strongly positive result (4+ critical). The patient was re-isolated, and anti-tuberculous therapy was initiated on 4 January 2025. Diffuse bilateral air-space opacification overlaid on severe chronic destructive lung disease was shown on portable chest radiography during terminal deterioration (Figure 3-C).

On January 5, 2025, he suffered asystolic cardiac arrest and passed away despite progressive resuscitative measures, vasopressor therapy, maximal ventilatory support, and the beginning of TB-directed therapy.

Case 4

On November 21, 2025, a 27-year-old lady who had no past medical history was referred from Sharjah Airport after it was determined that she was hypoxemic and unsuitable to travel. She reported having a fever, cough, and anorexia for around 15 days, followed by increased dyspnea for two days. She had a fever, tachycardia, and hypoxemia when they arrived. Initial chest radiography demonstrated bilateral pulmonary consolidation, more pronounced on the right. Her early clinical course was managed as severe pneumonia while pulmonary tuberculosis remained under investigation; however, oxygen requirements escalated rapidly from face-mask oxygen to high-flow nasal cannula support.

On November 27, 2025, pulmonary TB was reported microbiologically, with sputum AFB smear positivity (3+). A liver-sparing modified anti-TB regimen was first utilized due to severely abnormal hepatic function tests, but when her clinical state improved, a better comprehensive treatment was used.

Her ICU course was additionally complicated by anemia,severe sepsis, thrombocytopenia, electrolyte disturbances, anxiety, and panic related to extended isolation, and subsequent pneumothorax requiring chest-tube insertion. In spite of these complications, she gradually improved clinically, and she was successfully extubated on 7 December 2025. By January 2026, she remained stable on low-flow nasal oxygen and was considered suitable for transfer out of the ICU while continuing anti-tuberculous treatment and chest-drain follow-up.

Radiologic findings were particularly striking. Initial portable chest radiography demonstrated bilateral consolidation, more extensive on the right side (Figure 4-A).

On November 26, 2025, a chest CT scan revealed widespread active post-primary (reactivation) pulmonary tuberculosis with severe left-lung reticulonodular infiltrates, miliary nodules, fibrosis, and cavitation, as well as multilobar right-lung consolidation with air bronchograms, marked reticulonodular infiltrates, cavitary lesions, and apical traction bronchiectasis (Figure 4-B, C). A right-sided pneumothorax with mediastinal displacement that required intercostal drainage was shown by further imaging (Figure 4-D). Subsequent serial follow-up imaging showed that the persistent bilateral air-space disease was gradually improving.

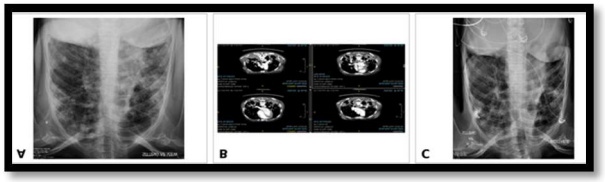

Figure 1. Case 1; (A) Chest radiography showed bilateral air-space disease (B) Contrast-enhanced chest CT showing bilateral ground-glass/reticular-consolidative disease with cavitation and pneumatoceles, supporting ongoing active destructive pulmonary tuberculosis. (C) Later follow-up chest radiograph showing partial interval regression of bilateral pulmonary opacities during recovery.

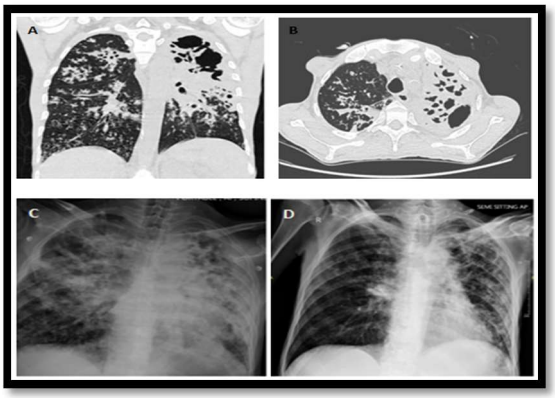

Figure 2. Case 2; (A) Coronal chest CT showing extensive bilateral miliary-pattern nodularity with dominant left-upper-lobe cavitary/consolidative disease. (B) Axial chest CT showing cavitary destruction and surrounding nodular infiltrates. (C) Portable chest radiograph after intubation demonstrating extensive bilateral air-space opacification. (D) Follow-up chest radiograph showing substantial interval improvement during recovery.



Figure 3. Case 3; (A-B) High-resolution chest CT from the earlier admission showing combined pulmonary fibrosis and emphysema with bilateral apical reticulonodular infiltrates, fibrosis/honeycombing, and cavitary change in a structurally abnormal lung. (C) Portable chest radiograph during the terminal ICU deterioration showing diffuse bilateral air-space opacification superimposed on chronic destructive lung disease.

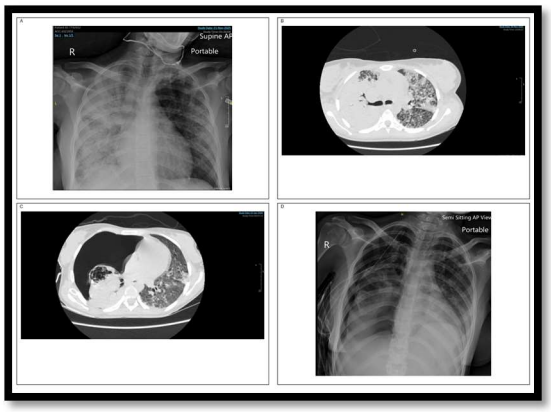

Figure 4. Case 4; (A) Initial chest radiograph showing bilateral consolidation, right greater than left. (B-C) Axial CT chest images demonstrating extensive active post-primary pulmonary tuberculosis with multilobar consolidation, cavitation, traction bronchiectatic change, and contralateral reticulonodular/miliary-pattern disease. (D) Later chest radiograph during recovery, demonstrating persistent bilateral disease with superimposed right-sided pneumothorax that subsequently required chest drainage.

Discussion

Managing severe pulmonary tuberculosis (TB) in the Intensive Care Unit (ICU) requires a multidisciplinary approach focusing on prompt initiation of anti-tubercular therapy (ATT), mechanical ventilation for respiratory failure, and management of complications like Acute Respiratory Distress Syndrome (ARDS) [7]. Critically ill patients often require early intervention due to high mortality rates [7]. Herein, we presented a case series consisting of four different adult cases that required critical care support in our ICU to control the severe pulmonary tuberculosis infection.

The host's immune system, the location and severity of the infection, and any underlying comorbidities can all affect the symptoms of tuberculosis (TB) [8]. One of the common symptoms of pulmonary TB is a persistent cough that lasts longer than two weeks and may produce bloody or purulent sputum [8]. Chest pain, breathing difficulties, and wheezing are additional respiratory symptoms, especially if the illness affects the pleura or obstructs the bronchi. People with active tuberculosis frequently have systemic symptoms such as fever, night sweats, and exhaustion. Fever may be intermittent or sub-grade, and it often accompanies chills and sweating, especially at night [9]. Nightsweats, also known as nocturnal hyperhidrosis, can be profuse and drenching, leading to sleep disturbances and daytime fatigue. Weight loss is a further hallmark feature of TB,often accompanied by loss of appetite and general malaise [10]. Regarding our cases; the first case admitted with history of dyspnea, persistent cough, fever, vomiting, abdominal pain, and progressive generalized weakness, the second one reported approximately 6 months of low-grade fever and dry cough, around 40 kg of weight loss, the third case suffered progressive anorexia, and severe constitutional decline, and the fourth one admitted with severe hypoxemic respiratory failure, fever, productive cough, and abdominal pain. She reported approximately 15 days of fever, cough, and anorexia, followed by two days of worsening shortness of breath.

Early pulmonary TB detection remains a challenge for doctors, and quick TB diagnosis can be tough in clinical practice [11, 12]. Although helpful, a chest X-ray cannot specifically diagnose pulmonary tuberculosis. Furthermore, unusual radiologic features and symptoms of tuberculosis might be confused with those of community-acquired pneumonia [13]. As a result, doctors frequently administer several rounds of antibiotics for pneumonia before appropriately diagnosing pulmonary tuberculosis [14]. Therefore, individuals with symptoms consistent with or suggestive of tuberculosis should undergo bacteriological culture testing and an acid-fast bacilli (AFB) smear. However, it takes two to six weeks to interpret mycobacterial culture, which has the best sensitivity for identifying and confirming active tuberculosis [12]. Sputum smear microscopy has a poor and inconsistent sensitivity, while being a quick, easy, and affordable method of detecting pulmonary tuberculosis. Both molecular and non-molecular tests have recently been developed for the early identification of active tuberculosis, either with or without the discovery of treatment resistance. A mix of clinical circumstances, symptoms, clinical indicators, and investigations are used to suggest tuberculosis. According to the World Health Organization's (WHO) 2013 updated standard case definitions for TB, pulmonary TB is defined as any bacteriologically confirmed or clinically diagnosed case of TB that affects the lung parenchyma or the tracheobronchial tree [15]. Regarding our cases, all of them were studied radiographically were they confirmed the pulmonary TB, case 1 had early heavy smear positivity with slow and inconsistent later clearance, case 2 combined highly compatible radiology with TB PCR detection and repeated smear positivity, case 3 had earlier negative AFB testing in structurally abnormal lungs but became smear 4+ only after critical deterioration; and Case 4 combined strongly suggestive radiology with subsequent AFB 3+ confirmation after initial therapyas severe pneumonia. Repeated microbiologic reassessment matters when clinical suspicion remains high.

Acute respiratory failure from pneumonia or ARDS (with or without miliary tuberculosis) is the most frequent cause of tuberculosis-related ICU admission [16]. This is followed by septic shock with multiple organ dysfunction, adrenal insufficiency, and neurological involvement, particularly tubercular meningitis [16]. Liver dysfunction (65.5%), chronic pancreatitis (12.1%), chronic renal failure (8.6%), and human immunodeficiency virus (HIV) coinfection (6.9%) are among the comorbidities that may coexist with TB. Nineteen percent of patients had extrapulmonary tuberculosis [17]. Compared to other causes of severe pneumonia, patients who needed ICU admission had a poor prognosis and a high death rate (60 vs. 25%) [18]. Sepsis, the requirement for mechanical ventilation, multiorgan failure syndrome, and other conditions have been linked to increased fatality rates in critically sick patients. Compared to other causes of severe pneumonia, patients who needed ICU admission had a poor prognosis and a high death rate (60 vs. 25%) [18]. Multiorgan dysfunction syndrome, sepsis, the necessity for mechanical ventilation, the development of nosocomial pneumonia, cardiogenic shock, and renal failure have all been linked to increased fatality rates in critically sick patients [16]. Regarding our cases, the decisive treatment problems were invasive ventilation or high-level respiratory support, oxygenation failure, nutritional depletion, hemodynamic instability, septic shock, and prolonged ICU support rather than routine ward-based TB care alone. Additionally, severe pulmonary TB in the ICU frequently presents with secondary infection, difficult ventilator liberation, major electrolyte or kidney derangement, prolonged sedation, and procedure-related complications.

Given the disease's frequent complexity and poor prognosis, managing TB in the intensive care unit is difficult. For infections caused by drug-susceptible M. According to WHO standards, pyrazinamide, ethambutol, isoniazid, and rifampin are the usual quadruple treatment for TB [17]. Clinicians skilled in treating extensively drug-resistant TB (XDR-TB), multidrug-resistant TB (MDR-TB), and tuberculosis involving coinfection with other infections should also be consulted [18].

Antituberculosis medication distribution in the intensive care unit (ICU) is mostly dependent on intestinal absorption, which can be affected or delayed by gastroparesis, intestinal paralysis, enteral feeding, hypoalbuminemia-related edema, and critical illness-related alterations in the gut flora [19]. Furthermore, severe illness can change the pharmacokinetics of antituberculosis medications [20]. Only thirty percent of severely sick TB patients in an observational case study who underwent quadruple treatment via a nasogastric tube reached therapeutic blood levels [21]. Second-line medications such as aminoglycosides and fluoroquinolones are often used because first-line agents are rarely available in intravenous formulations [21].

In the ICU, corticosteroids are frequently administered in conjunction with antituberculosis drugs. There is evidence that adjuvant treatment with corticosteroids reduces mortality in non-HIV-infected patients with tuberculous meningitis or pericarditis [22].

Our cases were four adults with severe pulmonary tuberculosis controlled in ICU. Case 1 was controlled with tracheostomy and prolonged rehabilitation before discharge on home oxygen. The case 2 course was complicated by septic shock, prolonged ventilation, and eventual recovery to discharge. Case 3 was microbiologically confirmed with severe pulmonary TB only after ICU deterioration, after which he died despite maximal support. Case 4 was controlled with mechanical ventilation and later recovered after a complicated ICU course.

The main strength of this report is the longitudinal description of four different critical-care phenotypes of pulmonary tuberculosis, with radiologic illustration now incorporated across the full series. The chief limitation is that the source material originated from routine daily clinical documentation rather than a prospectively standardized dataset; accordingly, some variables, such as exact long-term follow-up and fully harmonized microbiologic chronology for every sample, were not consistently available.

Conclusion

P Common themes were delayed or evolving confirmation, extensive parenchymal disease, and prolonged ventilatory support. The physiologic burden was great in the cases. Severe pulmonary TB should still be kept in mind in critical respiratory failure. This is particularly important in patients in whom radiology is suggestive or in whom managment for suspected pneumonia does not entirely explain the course.

References

1. WHO. Global Report. 2023. Available from: https://iris.who.int/bitstream/handle/10665/373828/9789240083851-eng.pdf?sequence=1.
2. Tan DT, See KC. Diagnosis and management of severe pulmonary and extrapulmonary tuberculosis in critically ill patients: A mini review for clinicians. World Journal of Critical Care Medicine. 2024 Jun 9;13(2):91435.
3. Kumar A, Garg S, Bharti P. Acute Respiratory Distress Syndrome as Pulmonary Tuberculosis in a Previously Healthy Adult:

A Case Report. Jour Clin Med Res. 2026;7(1):1-5.
4. Koirala S, Borisov S, Danila E, Mariandyshev A, Shrestha B, Lukhele N, Dalcolmo M, Shakya SR, Miliauskas S, Kuksa L, Manga S. Outcome of treatment of MDR-TB or drug-resistant patients treated with bedaquiline and delamanid: Results from a large global cohort. Pulmonology. 2021 Sep 30;27(5):403-12.
5. Ryu YJ, KOH WJ, Kang EH, Suh GY, Chung MP, Kim H, Kwon OJ. Prognostic factors in pulmonary tuberculosis requiring mechanical ventilation for acute respiratory failure. Respirology. 2007 May;12(3):406-1.
6. Duro RP, Figueiredo Dias P, Ferreira AA, Xerinda SM, Lima Alves C, Sarmento AC, Santos LC. Severe tuberculosis requiring intensive care: a descriptive analysis. Critical care research and practice.2017;2017(1):9535463
7. Tiberi S, Torrico MM, Rahman A, Krutikov M, Visca D, Silva DR, Kunst H, Migliori GB. Managing severe tuberculosis and its sequelae: from intensive care to surgery and rehabilitation. Jornal Brasileiro de Pneumologia. 2019 Apr 25;45(02):e20180324.
8. Straetemans M, Bierrenbach AL, Nagelkerke N, Glaziou P, van der Werf MJ. The effect of tuberculosis on mortality in HIV positive people: A meta-analysis. PLoS One. 2010;5(12):e15241.
9. Gao J, Zheng P, Fu H. Prevalence of TB/HIV co-infection in countries except China: A systematic review and meta-analysis. PLoS One. 2013;8(5): e64915.
10. Gelaw YA, Williams G, SoaresMagalhaes RJ, Gilks CF, Assefa Y. HIV prevalence among tuberculosis patients in Sub-Saharan Africa: A systematic review and meta-analysis. AIDS Behav. 2019;23(6): 1561–1575
11. Tobin EH, Tristram D. Tuberculosis overview. InStatPearls [Internet] 2024 Dec 22. statpearls publishing.
12. Muthu V, Agarwal R, Dhooria S, Aggarwal AN, Behera D, Sehgal IS. Outcome of critically ill subjects with tuberculosis: systematic review and meta-analysis. Respir Care. 2018;63(12):1541–1554.
13. Erbes R, Oettel K, Raffenberg M, Mauch H, Schmidt-Ioanas M, Lode H. Characteristics and outcome of patients with active pulmonary tuberculosis requiring intensive care. Eur Respir J. 2006;27(6):1223–1228.
14. Penner C, Roberts D, Kunimoto D, Manfreda J, Long R. Tuberculosis as a primary cause of respiratory failure requiring mechanical ventilation. Am J Respir Crit Care Med. 1995;151(3 Pt 1):867–872.
15. World Health Organization. Early detection of tuberculosis: an overview of approaches, guidelines and tools [Internet] Geneva: World Health Organization; 2011. [cited 2015 Mar 1]. Available from: http://www.who.int/iris/handle/10665/70824#sthash.TN5snAtB.dpuf.
16. Woodring JH, Vandiviere HM, Fried AM, Dillon ML, Williams TD, Melvin IG. Update: the radiographic features of pulmonary tuberculosis. AJR Am J Roentgenol. 1986;146:497–506.
17. Grossman RF, Hsueh PR, Gillespie SH, Blasi F. Community-acquired pneumonia and tuberculosis: differential diagnosis and the use of fluoroquinolones. Int J Infect Dis. 2014;18:14–21.
18. Wang M, Fitzgerald JM, Richardson K, Marra CA, Cook VJ, Hajek J, et al. Is the delay in diagnosis of pulmonary tuberculosis related to exposure to fluoroquinolones or any antibiotic? Int J Tuberc Lung Dis. 2011;15:1062–1068.
19. World Health Organization. Definitions and reporting framework for tuberculosis: 2013 revision (updated December 2014) [Internet] Geneva: World Health Organization; 2013. [cited 2015 Mar 1]. Available from: http://apps.who.int/iris/bitstream/10665/79199/1/9789241505345_eng.pdf?ua=1.
20. World Health Organization . Guidelines for treatment of tuberculosis. Geneva: World Health Organization; 2010.
21. .Lee K, Kim JH, Lee JH, Lee WY, Park MS, Kim JY. Acute respiratory distress syndrome caused by miliary tuberculosis a multicentre survey in South Korea. Int J Tuberc Lung Dis. 2011;15(8):1099–1103.
22. Otu A, Hashmi M, Mukhtar AM, Kwizera A, Tiberi S, Macrae B. The critically ill patient with tuberculosis in Intensive care Clinical presentations, management and infection control. J Crit Care. 2018;45:184–196.