

# Biocomposite Films of Chitosan–PVA–Aloe vera for the Burns Management in Wistar Rats Model

Dioni Fadia Zatalini<sup>1</sup>, Retno Sari\*<sup>2,3</sup>, Esti Hendradi<sup>2,3</sup>

<sup>1</sup>Faculty of Health and Science, Universitas PGRI Madiun, Madiun

<sup>2</sup>Department of Pharmaceutical Sciences, Faculty of Pharmacy, Universitas Airlangga, Surabaya 60115, Indonesia

<sup>3</sup>Pharmaceutics and Delivery Systems for Drugs, Cosmetics, and Nanomedicine Research Group, Faculty of Pharmacy, Universitas Airlangga, Surabaya 60115, Indonesia

Received: 17<sup>th</sup> Aug, 2025; Revised: 25<sup>th</sup> Oct 2025; Accepted: 6<sup>th</sup> Nov, 2025; Available Online: 1<sup>st</sup> December, 2025

## ABSTRACT

Chitosan–polyvinyl alcohol (PVA) film dressings have been widely recognized for their biocompatibility, biodegradability, and favorable physicochemical properties, making them suitable candidates for wound management. The integration of Aloe vera extract, known for its anti-inflammatory, antimicrobial, and pro-regenerative effects, is hypothesized to potentiate the therapeutic efficacy of such composite films. This study aimed to investigate the wound-healing potential of chitosan–PVA films incorporated with Aloe vera using a second-degree burn wound model in Wistar rats (*Rattus norvegicus*). Composite films were fabricated via solvent casting with varying ratios of chitosan, PVA, and Aloe vera. Wound healing was assessed over 14 days through quantitative measurement of wound contraction and qualitative macroscopic evaluation of tissue regeneration. Results revealed that films containing Aloe vera demonstrated significantly enhanced wound closure compared with both chitosan–PVA films without Aloe vera and the positive control. These findings highlight the synergistic interactions among chitosan, PVA, and Aloe vera, suggesting that these composite films may serve as a promising bioactive dressing for accelerated burn wound healing...

**Keywords:** composite film fabrication, chitosan, polyvinyl alcohol, *Aloe vera*, wound healing

**How to cite this article:** Zatalini DF, Sari R, Hendradi E, Biocomposite Films of Chitosan–PVA–Aloe vera for the Burns Management in Wistar Rats Model. *Int J Drug Deliv Technol.* 2026;16(1): 315-320. DOI: 10.25258/ijddt.16.1.34

**Source of support:** Nil.

**Conflict of interest:** None

## INTRODUCTION

Wound dressings are biomedical materials designed to cover and protect wounds, thereby preventing further damage and promoting the healing process<sup>1</sup>. An ideal wound dressing should possess specific characteristics, including the potential to retain a humid environment within the wound, effectively manage excess exudate, protect against microbial infection, and exhibit biocompatibility, biodegradability, transparency, and elasticity<sup>2</sup>. Among various types, film dressings are widely used due to their ease of application, non-invasive administration route, and favorable patient comfort. In addition, film dressings are typically transparent, elastic, and flexible, which further enhances their clinical applicability<sup>3</sup>. The materials used in film dressing fabrication may include natural polymers such as gelatin, collagen, and chitosan, as well as synthetic polymers, each of which provides distinct contributions to wound healing outcomes<sup>4</sup>.

Chitosan exhibits notable wound-healing activity owing to its classification as a cationic polysaccharide with inherent bacteriostatic properties. Electrostatic interactions occur between the cationic amino groups of chitosan and the anionic components of bacterial cell membranes, thereby conferring significant antibacterial effects<sup>5</sup>. In addition to its antimicrobial action, chitosan facilitates wound healing

by accelerating the migration of inflammatory cells to the wound site, a process that promotes tissue regeneration and enhances the overall healing cascade<sup>6</sup>.

Polyvinyl alcohol (PVA) is widely utilized in wound dressing formulations due to its ability to enhance gel viscosity and form elastic films with favorable tensile strength (TS). However, PVA-based films often exhibit poor adhesiveness, limited gas permeability, and low fluid absorption capacity, which may restrict their effectiveness as wound dressings<sup>7</sup>. The physicochemical properties of PVA films can be improved by combining them with natural polymers such as alginate, collagen, and chitosan. These polymers possess superior absorptive capacity and provide a moist microenvironment that facilitates optimal exudate management, thereby supporting cellular activity and accelerating the wound-healing process<sup>8,9</sup>.

The wound-healing potential of *Aloe vera* is primarily attributed to its bioactive constituents, including amino acids (glutamine, threonine, isoleucine, valine, and phenylalanine), enzymes (bradykinase, catalase, lipase, carboxypeptidase, and peroxidase), and polysaccharides such as glucomannan and acemannan<sup>10</sup>. These components exert synergistic effects with chitosan, thereby enhancing antibacterial activity, stimulating fibroblast proliferation, and promoting collagen synthesis, thereby contributing to accelerated wound closure. Previous studies have

\*Author for Correspondence: [herdiani-s-p@fk.unair.ac.id](mailto:herdiani-s-p@fk.unair.ac.id)

demonstrated that films composed of chitosan and PVA (1.5% w/w each) exhibited favorable physicochemical and mechanical characteristics, including stability in pH, swelling index, moisture content, tensile strength, elongation at break, and Young's modulus<sup>11</sup>.

The present study aimed to evaluate the wound-healing efficacy of a chitosan–PVA–*Aloe vera* composite film in a second-degree burn wound model using Wistar rats (*Rattus norvegicus*).

## MATERIAL AND METHOD

### Material

Chitosan 107 cps (Biotech, Co.Ltd), *Aloe vera* powder (Haldin, Pasific Semesta, Indonesia), polyvinyl alcohol (PT. Brataco, Indonesia), glacial acetic acid (Merck, Germany), propylene glycol (PT. Brataco, Indonesia), Ketamine® (PT Guardian Pharmatama), Xylazine® (PT Darya-Varia, Indonesia)

### Experimental animal

Thirty (30) male Wistar rats (*Rattus norvegicus*), 2–3 months old and weighing 150–250 g, were employed as experimental subjects in this study. All animals were housed in proper cages under standard laboratory conditions with adequate space for free movement. They were maintained at a controlled temperature of  $22 \pm 2$  °C and kept at 50–60% humidity with alternating 12 h periods of light and darkness. Standard laboratory chow and water were provided *ad libitum* throughout the study period to ensure proper nutrition and hydration.

### Ethical clearance

All experimental procedures were conducted in compliance with the ethical guidelines for the care and use of laboratory animals. Ethical clearance for this study was obtained from the Commission of Ethics of the Faculty of Dental Medicine, Universitas Airlangga, Surabaya, Indonesia, with ethical clearance certificate No. 588/HRECC.FODM/VIII/2022.

### Fabrication of chitosan-PVA-*Aloe vera* film

The composite films were prepared by solvent casting. Chitosan was dissolved in 1% (v/v) acetic acid, while PVA and *Aloe vera* powder were dissolved in distilled water according to the formulations presented in Table 1. The resulting solutions were combined, followed by the addition of propylene glycol as a plasticizer. The mixture was sonicated for 15 minutes to eliminate air bubbles and subsequently cast into Petri dishes (5 mL per dish). The films were dried in an oven at 40 °C for 5.5 hours, carefully peeled off, and stored in a desiccator until further use.

**Table 1: Composition of Chitosan-PVA-*Aloe vera* Biocomposite Film**

Materials	Percentage (%)			
	G1	G2	G3	G4
Chitosan	1.5	1.5	-	1.5
PVA	1.5	-	1.5	1.5
<i>Aloe vera</i> powder	1.5	1.5	1.5	-
Propylene Glycol	6			
Glacial Acetic Acid	40			
Aquades (ad)	100	100	100	100

### Wound healing evaluation

White rats (*Rattus norvegicus*, Wistar strain) were acclimatized for seven (7) days under standard laboratory conditions before the experiment. Animals were anesthetized via intramuscular injection of ketamine and xylazine. The dorsal fur was shaved, and second-degree burn wounds were induced using an electric burner (85 °C, 1 cm<sup>2</sup> diameter) applied for 5 seconds. The wound area was subsequently cleaned with 0.9% normal saline.

The animals were randomly divided into six groups (n = 5 per group), consisting of four treatment groups and two control groups, as follows:

G1: Burn wound treated with chitosan–PVA–*Aloe vera* film (1.5%; 1.5%; 1.5%)

G2: Burn wound treated with chitosan–*Aloe vera* film

G3: Burn wound treated with PVA–*Aloe vera* film

G4: Burn wound treated with chitosan–PVA film

G5: Burn wound treated with sulfadiazine cream (positive control)

G6: Burn wound without treatment (negative control).

For groups G1–G4, wound dressings were applied by attaching 2.5 × 2.5 cm films to the wound area. In G5, sulfadiazine cream was applied topically to the lesion. Treatments were administered once daily for 14 consecutive days.

### Wound healing percentage

Macroscopic evaluation of wound healing was performed by visual observation of wound morphology, including changes in shape and color. Wound area measurements were conducted on days 1, 7, and 14 post-injury. The wound surface was photographed with a digital camera, and the images were analyzed in ImageJ to determine wound area (mm<sup>2</sup>). The percentage of wound contraction represents wound healing activity.

### Statistical analysis

Results are shown as mean ± SD. Data were analyzed by SPSS 24.0 (IBM Corp., Armonk, NY, USA). One-way ANOVA was used to determine group differences, with Tukey's HSD applied for posthoc analysis. Statistical significance was considered at  $p < 0.05$ .

## RESULT DAN DISCUSSION

### Wound healing

#### Visual

The visual observations are presented in Table 2, showing that the chitosan–PVA–*Aloe vera* film exhibited significant wound healing activity compared with the negative control group (G6), which did not receive any wound treatment. Furthermore, the wound-healing activity of G1 was superior to that of the others, as evidenced by a greater reduction in wound area and the detachment of eschar, indicating effective tissue repair.









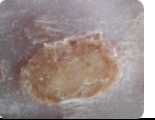
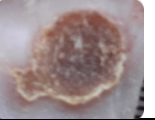


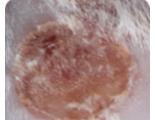


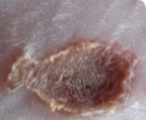



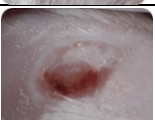
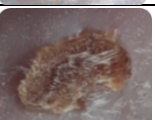
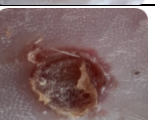
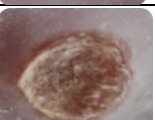
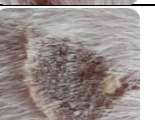
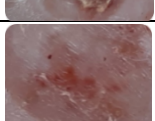
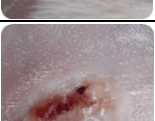
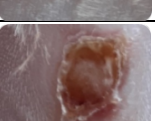
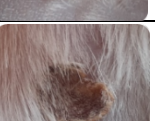
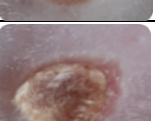
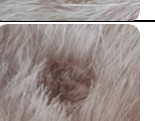

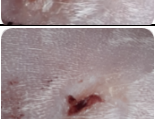
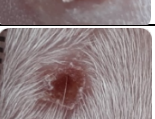


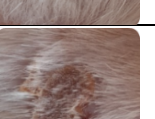
On day 7, the wound areas among the six groups ranged from 0.46 to 0.72 cm<sup>2</sup>. By day 14, a marked contraction of wound size was observed, with areas ranging from 0.03 to 0.28 cm<sup>2</sup> (Table 3). The percentage of wound healing on day 7 ranged from 9.88% and 46.23%, while on day 14 it ranged from 62.82% to 96.15% (Figure 1). These findings indicate that wound healing progressed substantially by day 14

compared with day 7. Increased wound contraction was characterized by a reduction in wound size, eschar detachment, the appearance of granulation tissue, and epithelialization<sup>12</sup>. Wound contraction and epithelialization occurred in a stimulatory manner, supporting effective tissue regeneration.<sup>13</sup>.

Among all groups, G1 (chitosan–PVA–Aloe vera film) demonstrated the smallest mean wound area and the highest percentage of wound healing by day 14, with a residual wound size of  $0.03 \pm 0.02 \text{ cm}^2$  and a wound healing

percentage of  $96.15 \pm 1.69\%$ . Based on the wound healing histogram (Figure 1), the negative control group (G6) exhibited the lowest healing percentage, whereas G1 showed the highest and significantly greater healing than the positive control (G5, sulfadiazine cream). These results strongly suggest that the chitosan–PVA–Aloe vera biocomposite film is more effective at accelerating wound healing than either untreated wounds or conventional treatment.

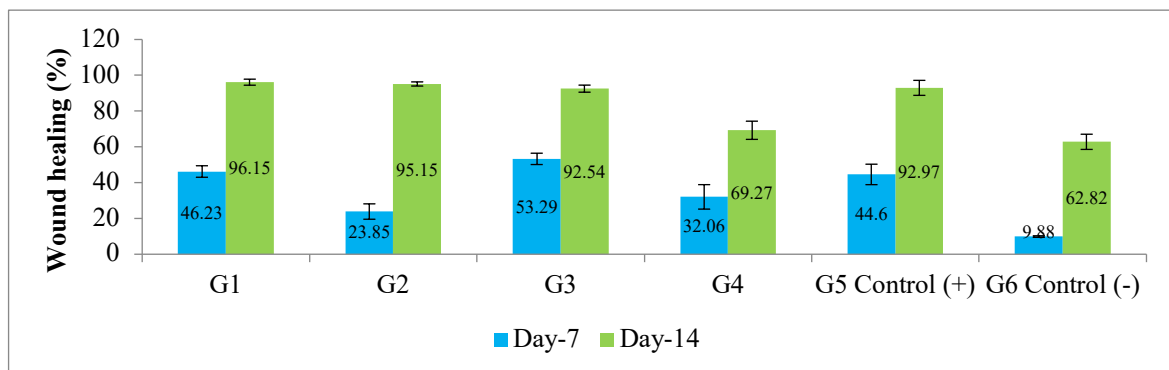
**Table 2: Macroscopic Visualization of Wound Healing During Treatment in Each Treatment Group. G1 (Chitosan 1.5%–PVA 1.5%–Aloe Vera 1.5%), G2 (Chitosan 1.5%–Aloe Vera 1.5%), G3 (PVA 1.5%–Aloe Vera 1.5%), G4 (Chitosan 1.5%–PVA 1.5%), G5 (Positive Control), G6 (Negative Control).**

Day	G1	G2	G3	G4	G5 Positive Control	G6 Negative Control
1						
5						
7						
10						
12						
14						

**Table 3: Clinical (macroscopic) description of burn wounds on the dorsal region of Wistar rats with different treatments. Observations were performed on days 1, 7, and 14 of treatment. G1 (Chitosan 1.5%–PVA 1.5%–Aloe Vera 1.5%), G2 (Chitosan 1.5%–Aloe Vera 1.5%), G3 (PVA 1.5%–Aloe Vera 1.5%), G4 (Chitosan 1.5%–PVA 1.5%), G5 (Positive Control), G6 (Negative Control).**

Day	G1	G2	G3	G4	G5 Positive Control	G6 Negative Control
1	The skin appeared blistered, with a circular, slightly oval, whitish wound.	The skin appeared blistered, with a circular, slightly oval, whitish wound.	The skin appeared blistered, with a circular, slightly oval, whitish wound.	The skin appeared blistered, with a circular, slightly oval, whitish wound.	The skin appeared blistered, with a circular, slightly oval, whitish wound.	The skin appeared blistered, with a whitish wound that was circular and slightly oval in shape
5	The wound began to dry and formed a	The wound started to dry and formed a	The wound started to dry and formed a	The wound started to dry and formed a	The wound started to dry and	The wound started to dry and formed a

Day	G1	G2	G3	G4	G5 Positive Control	G6 Negative Control
	reddish-brown scab.	reddish-brown scab.	reddish-brown scab.	reddish-brown scab.	formed a reddish-brown scab.	reddish-brown scab.
7	The wound showed a modest reduction in size, with the formation of a dry, brownish scab.	The wound showed a modest reduction in size, with the formation of a dry, brownish scab.	The wound showed a modest reduction in size, with the formation of a dry, brownish scab.	The wound showed a modest reduction in size, with the formation of a dry, brownish scab.	The wound showed a modest reduction in size, with the formation of a dry, brownish scab.	The wound showed a modest reduction in size, with the formation of a dry, brownish scab.
10	The wound showed a modest reduction in size, with the formation of a dry, brownish scab.	The wound area progressively diminished, marked by scab separation and the appearance of a small, brownish residual scar with slight erythema.	The wound showed a modest reduction in size, with the formation of a dry, brownish scab.	The wound showed a modest reduction in size, with the formation of a dry, brownish scab.	The wound showed a modest reduction in size, with the formation of a dry, brownish scab.	The wound showed a modest reduction in size, with the formation of a dry, brownish scab.
12	The wound area progressively diminished, marked by scab separation and the appearance of a minor, brownish residual scar with slight erythema.	The wound area progressively diminished, marked by scab separation and the appearance of a minor, brownish residual scar with slight erythema.	The wound showed a modest reduction in size, with the formation of a dry, brownish scab.	The wound exhibited a modest decrease in dimension, with the formation of a dry, brownish scab.	The wound exhibited a modest decrease in dimension, with the formation of a dry, brownish scab.	The wound exhibited a modest decrease in dimension, with the formation of a dry, brownish scab.
14	Complete scab detachment was observed, with the wound area exhibiting whitish to light pink coloration and the onset of hair regrowth.	The wound exhibited a modest decrease in dimension, with the formation of a dry, brownish scab.	Progressive wound contraction was observed, with substantial scab detachment and the presence of residual brownish discoloration, accompanied by slight erythema.	The wound exhibited a modest decrease in dimension, with the formation of a dry, brownish scab.	Progressive wound contraction was observed, with substantial scab detachment and the presence of residual brownish discoloration, accompanied by slight erythema.	The wound exhibited a modest decrease in dimension, with the formation of a dry, brownish scab.



**Figure 1: Percentage of wound healing in each treatment group. G1 (Chitosan 1,5% –PVA 1,5%–Aloe vera 1,5%), G2 (Chitosan 1,5%–Aloe vera 1,5%), G3 (PVA 1,5%–Aloe vera 1,5%), G4 (Chitosan 1,5%–PVA 1,5%), G5 (positive control), G6 (negative control)**

**Tabel 4: Wound Area (cm<sup>2</sup>) on Day 7 and Day 14 in each treatment group. G1 (Chitosan 1.5%–PVA 1.5%–Aloe vera 1.5%), G2 (Chitosan 1.5%–Aloe vera 1.5%), G3 (PVA 1.5%–Aloe vera 1.5%), G4 (Chitosan 1.5%–PVA 1.5%), G5 (positive control), G6 (negative control)**

Group	Wound Area (cm <sup>2</sup> )	
	Day 7	Day 14
G1	0.46 ± 0.03	0.03 ± 0.02
G2	0.65 ± 0.12	0.04 ± 0.01
G3	0.53 ± 0.09	0.07 ± 0.02
G4	0.57 ± 0.06	0.28 ± 0.07
G5	0.44 ± 0.02	0.08 ± 0.01
G6	0.72 ± 0.07	0.30 ± 0.07

The results revealed that groups G1, G2, and G3 did not differ significantly from group G5 (positive control). In contrast, groups G4 and G6 showed significant differences compared to groups G1, G2, G3, and G5 ( $P = 0.000$ ;  $P < 0.05$ ).

These results suggest that adding *Aloe vera* to chitosan, PVA, or chitosan-PVA composite films enhances wound-healing activity. This finding is consistent with the known ability of chitosan and *Aloe vera* to accelerate wound healing, suggesting that their combination provides a more effective healing effect.

*Aloe vera* is recognized as a rich source of multiple bioactive substances that act synergistically to accelerate tissue repair<sup>14</sup>. The polysaccharide acemannan is considered the key compound, as it promotes fibroblast proliferation, supports collagen formation, and facilitates the closure of epithelial gaps<sup>15</sup>. Other constituents, including anthraquinones, saponins, lignins, and salicylic acid, further contribute through antimicrobial, anti-inflammatory, and penetration-enhancing properties<sup>10</sup>. Moreover, incorporating chitosan and PVA as polymers improves the mechanical strength of the films and offers potential for drug delivery applications. Previous studies have also demonstrated that chitosan-PVA composites incorporated with synergistic bioactive agents, such as curcumin, honey, or genipin, can further enhance wound healing efficacy<sup>16–21</sup>.

## CONCLUSION

The chitosan-PVA-*Aloe vera* biocomposite film demonstrated superior wound-healing potential, evidenced by the highest wound-healing percentage and a more favorable macroscopic appearance compared to other formulations. Therefore, this biocomposite holds promise as a wound dressing material.

## ACKNOWLEDGEMENT

Universitas Airlangga financially supported this research through Penelitian Unggulan Fakultas Grant with contract number 989/UN3.1.5/PT/2021.

## REFERENCE

- Dong R, Guo B. Smart wound dressings for wound healing. *Nano Today* [Internet]. 2021;41:101290. Available from: <https://doi.org/10.1016/j.nantod.2021.101290>
- Savencu I, Iurian S, Porfire A, Bogdan C, Tomuța I. Review of advances in polymeric wound dressing films. *React Funct Polym.* 2021;168(July).
- Dhivya S, Padma VV, Santhini E. Wound dressings - A review. *Biomed.* 2015;5(4):24–8.
- Wang B, Li W, Harrison J. An Evaluation of Wound Healing Efficacy of a Film Dressing Made from Polymer-integrated Amnion Membrane. *Organogenesis.* 2020;16(4):126–36.
- Samanta S, Banerjee J, Das B, Mandal J, Chatterjee S, Ali KM, et al. Antibacterial potency of cyto-compatible chitosan-decorated biogenic silver nanoparticles and molecular insights towards cell-particle interaction. *Int J Biol Macromol* [Internet]. 2022;219(July):919–39. Available from: <https://doi.org/10.1016/j.ijbiomac.2022.08.050>
- Liu H, Wang C, Li C. RSC Advances dressing and drug delivery system in the treatment of wound healing. *RSC Adv.* 2018;8:7533–49.
- Mok CF, Ching YC, Muhamad F, Abu Osman NA, Hai ND, Che Hassan CR. Adsorption of Dyes Using Poly(vinyl alcohol) (PVA) and PVA-Based Polymer Composite Adsorbents: A Review. *J Polym Environ.* 2020;28(3):775–93.
- Chaudhari AA, Vig K, Baganizi DR, Sahu R, Dixit S, Dennis V, et al. Future prospects for scaffolding methods and biomaterials in skin tissue engineering: A review. *Int J Mol Sci.* 2016;17(12).
- Yang M, Li L, Yu S, Liu J, Shi J. High performance of alginate/polyvinyl alcohol composite film based on natural original melanin nanoparticles used as food thermal insulating and UV-vis block. *Carbohydr Polym.* 2020;233(October 2019):115884.
- Alven S, Khwaza V, Oyediji OO, Aderibigbe BA. Polymer-based scaffolds loaded with aloe vera extract for the treatment of wounds. *Pharmaceutics.* 2021;13(7).
- Zatalini DF, Hendradi E, Drake P, Sari R. The Effect of Chitosan and Polyvinyl Alcohol Combination on Physical Characteristics and Mechanical Properties of Chitosan-PVA- Aloe vera Film. 2023;10(2):151–61.

12. Farzadinia P, Jofreh N, Khatamsaz S, Movahed A, Akbarzadeh S, Mohammadi M, et al. Anti-inflammatory and Wound Healing Activities of Aloe vera, Honey and Milk Ointment on Second-Degree Burns in Rats. *Int J Low Extrem Wounds*. 2016;15(3):241–7.
13. Ehrlich HP, Hunt TK. Collagen Organization Critical Role in Wound Contraction. *Adv Wound Care*. 2012;1(1):3–9.
14. Al-Saiegh AM, Al-Qadhi AS, Ibrahim SM, Al-Hyani OH. Effect of aloe vera gel on articular cartilage regeneration in dogs. *Iraqi J Vet Sci*. 2024;38(2):275–83.
15. Afewerki S, Sheikhi A, Kannan S, Ahadian S, Khademhosseini A. Gelatin-polysaccharide composite scaffolds for 3D cell culture and tissue engineering: Towards natural therapeutics. *Bioeng Transl Med*. 2019;4(1):96–115.
16. Ceylan S. Propolis loaded and genipin-crosslinked PVA/chitosan membranes; characterization properties and cytocompatibility/genotoxicity response for wound dressing applications. *Int J Biol Macromol*. 2021;181:1196–206.
17. Panchal R, Mateti T, Likhith K, Rodrigues FC, Thakur G. Genipin cross-linked chitosan–PVA composite films: An investigation on the impact of cross-linking on accelerating wound healing. *React Funct Polym*. 2022;178(July).
18. R. N, M. K, J. P, K.S. V, Arpana C, Balashanmugam P, et al. Enhanced wound healing by PVA/Chitosan/Curcumin patches: In vitro and in vivo study. *Colloids Surfaces B Biointerfaces*. 2019;182(April).
19. Ghuriani, V., Wassan, J. T., Deolal, P., Sharma, V., Dalal, D., & Goyal, A. (2023). An integrative approach towards recommending farming solutions for sustainable agriculture. *Journal of Experimental Biology and Agricultural Sciences*, 11(2), 306–315. [https://doi.org/10.18006/2023.11\(2\).306.315](https://doi.org/10.18006/2023.11(2).306.315)
20. Al-Sharqi, A. A., Dari, W. A., Jassim, R., Mohsin, Y. B., Hussian, A. K., & Mohmood, R. R. (2025). The synergistic effects of *Lactobacillus acidophilus* and *Chlorella* spp. against pathogens isolated from dermal infections. *International Journal of Probiotics and Prebiotics*, 20, 19–23. <https://doi.org/10.37290/ijpp2641-7197.20:19-23>
21. Alshahrani, S. M. (2024). Knowledge, attitudes, and barriers toward using complementary and alternative medicine among medical and nonmedical university students: A cross-sectional study from Saudi Arabia. *Current Topics in Nutraceutical Research*, 22(3), 889–894. <https://doi.org/10.37290/ctnr2641-452X.22:889-894>