

Root Resorption in Clear Aligners vs Conventional Fixed Orthodontic Appliances: A Comprehensive Evidence-Based Review

Dr. Niranjan C Paramshetty¹, Dr. Bhagyalaxmi Fouzdar², Dr. Rahul Sinha³, Dr. Vinay Guggari⁴, Dr. Shwetha E⁵, Dr. Raghavendra Naik⁶

¹MD and Implantologist, KDC Xpress Teeth, RR Nagar, Bengaluru, Karnataka, India, Email Id- kdc.care@gmail.com, Orcid ID- 0009-0004-7636-6786

²Director and Implantologist, KDC Xpress Teeth, RR Nagar, Bengaluru, Karnataka, India, Email Id- drbhagyalaxmi@gmail.com, Orcid ID- 0009-0005-2940-584X

³Consultant Orthodontist, KDC Xpress Teeth, RR Nagar, Bengaluru, Karnataka, India, Email Id- dr.rahulsinha29@gmail.com, Orcid ID- 0009-0006-1373-0338

⁴Consultant Prosthodontist and Implantologist, KDC Xpress Teeth, RR Nagar, Bengaluru, Karnataka, India, Email Id- drvinay.kdc@gmail.com, Orcid Id- 0009-0008-5457-4575

⁵Consultant Periodontist and Implantologist, KDC Xpress Teeth, RR Nagar, Bengaluru, Karnataka, India, Email Id- shwethaperio@gmail.com, Orcid Id- 0009-0008-4374-1285

⁶Consultant Periodontist and Implantologist, KDC Xpress Teeth, RR Nagar, Bengaluru, Karnataka, India, raghu.perio@gmail.com, Orcid Id- 0009-0005-6800-5742

Corresponding Author :- Dr. RAHUL SINHA

*Consultant Orthodontist, KDC Xpress Teeth, RR Nagar, Bengaluru, Karnataka, India, Email Id- dr.rahulsinha29@gmail.com, Orcid ID- 0009-0006-1373-0338

Abstract

External apical root resorption (EARR) is a well-recognized iatrogenic consequence of orthodontic treatment involving irreversible loss of cementum and dentin. This review integrates findings from CBCT-based studies, randomized clinical trials, and systematic reviews to compare root resorption associated with clear aligners and conventional fixed appliances. Most studies report mild resorption (<1 mm) in both modalities, with inconsistent evidence regarding superiority. While some investigations demonstrate reduced severity with aligners due to intermittent force application, others report comparable outcomes when biomechanical factors are controlled. Recent research highlights the dominant role of biological variability, genetic predisposition, and treatment mechanics in determining resorption severity.

Keywords: Root resorption; Clear aligners; Fixed appliances; Orthodontics; CBCT; EARR

How to cite this article: Paramshetty NC, Fouzdar B, Sinha R, Guggari V, Shwetha E, Naik R. Root Resorption in Clear Aligners vs Conventional Fixed Orthodontic Appliances: A Comprehensive Evidence-Based Review. *Int J Drug Deliv Technol.* 2026;16(15s): 219-222. DOI: 10.25258/ijddt.16.15s.26.

1. Introduction

Orthodontically induced inflammatory root resorption (OIIRR) is an unavoidable yet variable side effect of orthodontic tooth movement. Weltman et al. (2) reported that although a large proportion of orthodontic patients exhibit some degree of root resorption, severe resorption affecting long-term prognosis is relatively uncommon. With the growing preference for clear aligners due to esthetic advantages, comparative evaluation with conventional fixed appliances has gained clinical importance. Inchingolo et al. (1) demonstrated that both aligners and fixed appliances result in measurable resorption, although aligners may show slightly reduced severity in certain cases. However, the heterogeneity of study designs and patient factors has led to inconsistent conclusions, necessitating a comprehensive evaluation of available evidence.

2. Biological Mechanism of Root Resorption

Root resorption is initiated when orthodontic forces exceed physiological tolerance, leading to periodontal ligament compression, vascular occlusion, and tissue

hyalinization. Buschang et al. (9) described this process as a cascade involving sterile inflammation and recruitment of clastic cells responsible for resorptive activity. Brezniak and Wasserstein (12) further emphasized that EARR is a biologically regulated process rather than purely mechanical damage. Recent molecular studies by Iglesias-Linares et al. (6) identified genetic polymorphisms in cytokine pathways such as IL-1 β and TNF- α , which significantly influence susceptibility. These findings explain why patients subjected to similar orthodontic forces may exhibit markedly different degrees of root resorption.

3. Root Resorption in Conventional Fixed Appliances

Conventional fixed appliances deliver continuous forces, which maintain prolonged stress within the periodontal ligament. Li et al. (4), using CBCT analysis, demonstrated that fixed appliances are associated with greater volumetric root loss compared to traditional radiographic estimates, particularly in maxillary incisors. Sameshima and Sinclair (7)

*Author for Correspondence: kdc.care@gmail.com

reported that factors such as extraction therapy, longer treatment duration, and increased force magnitude significantly increase the risk of severe resorption. Additionally, studies published in the Angle Orthodontist and related literature have shown that although fixed appliances may produce higher

prevalence of apical shortening, the majority of cases remain within clinically acceptable limits (<2 mm). These findings suggest that while fixed appliances may present a higher risk under certain conditions, proper biomechanical control can mitigate adverse outcomes.

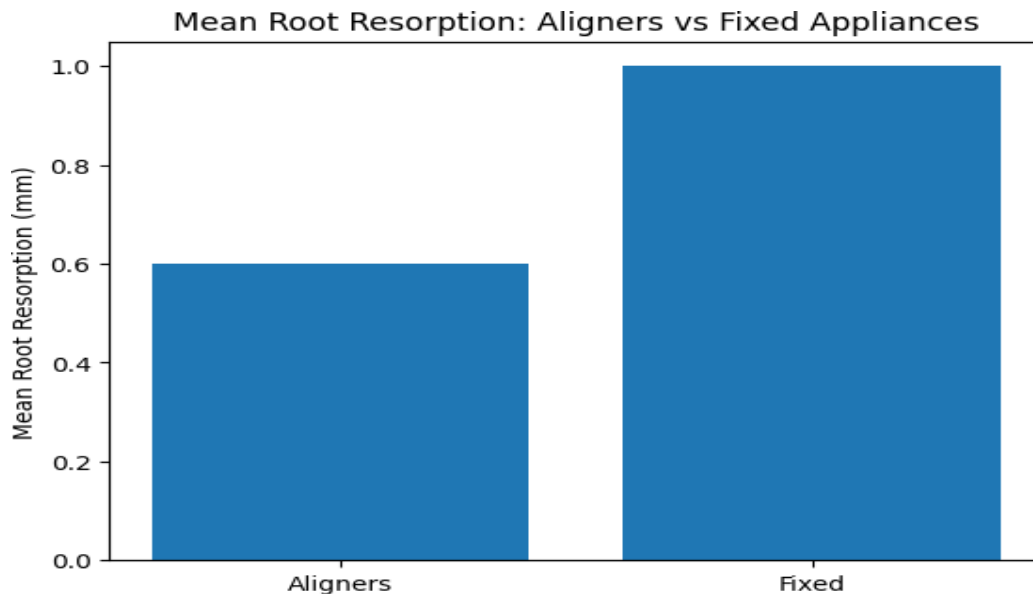


Fig. 1 Mean root resorption : Aligners vs Fixed Appliances

Parameter	Aligners	Fixed
Force	Intermittent	Continuous
Resorption	0.5-0.7 mm	0.7-1.2 mm

4. Root Resorption in Clear Aligners

Clear aligners apply intermittent forces due to their removable design, allowing periods of recovery for periodontal tissues. Krieger et al. (8) demonstrated that aligner therapy results in significantly lower apical root resorption compared to fixed appliances in certain patient groups. Lund et al. (5), in a systematic review, reported mean resorption values of approximately 0.5–0.7 mm with aligners, which are generally considered clinically insignificant. Papageorgiou et al. (13) further noted that while aligners are effective in achieving orthodontic outcomes, their advantage in reducing root resorption is limited and may depend on case complexity. In complex movements such as intrusion or torque, aligners can produce resorption comparable to fixed appliances, highlighting the importance of treatment planning.

5. Comparative Evidence from Literature

5.1 Studies Showing No Significant Difference

Yi et al. (3), in a meta-analysis, concluded that there is no statistically significant difference in root resorption between aligners and fixed appliances, with both modalities demonstrating mild apical shortening. Similarly, Lund et al. (5) reported comparable outcomes across multiple clinical studies, reinforcing

the concept that appliance type alone does not determine resorption severity.

5.2 Studies Favoring Aligners

Inchingolo et al. (1) and Li et al. (4) reported reduced volumetric root loss in aligner-treated patients, particularly in non-extraction cases. These findings are attributed to intermittent force application, which allows periodontal tissue recovery and reduces cumulative stress. Additionally, improved oral hygiene associated with aligners may contribute to better periodontal conditions and reduced inflammatory response.

5.3 Studies Favoring Fixed Appliances

Some investigations have shown that when light and controlled forces are applied, fixed appliances can produce outcomes comparable to aligners. Buschang et al. (9) emphasized that force magnitude and duration are critical determinants, suggesting that optimized biomechanics can minimize resorption regardless of appliance type. These findings highlight the importance of clinical expertise in treatment planning.

6. Risk Factors

Root resorption is influenced by multiple interacting factors. Lopatiene and Dumbravaite (11) identified biological determinants such as root morphology, age, and history of trauma as significant contributors. Genetic susceptibility, as demonstrated by Iglesias-Linares et al. (6), plays a crucial role in determining individual response to orthodontic forces. Mechanical

factors include force magnitude, duration, and type of movement, with intrusion being particularly associated with increased resorption (9). Clinical factors such as extraction therapy and prolonged treatment duration further increase risk by intensifying biomechanical stress (7). The multifactorial nature of EARR explains the variability observed across different studies.

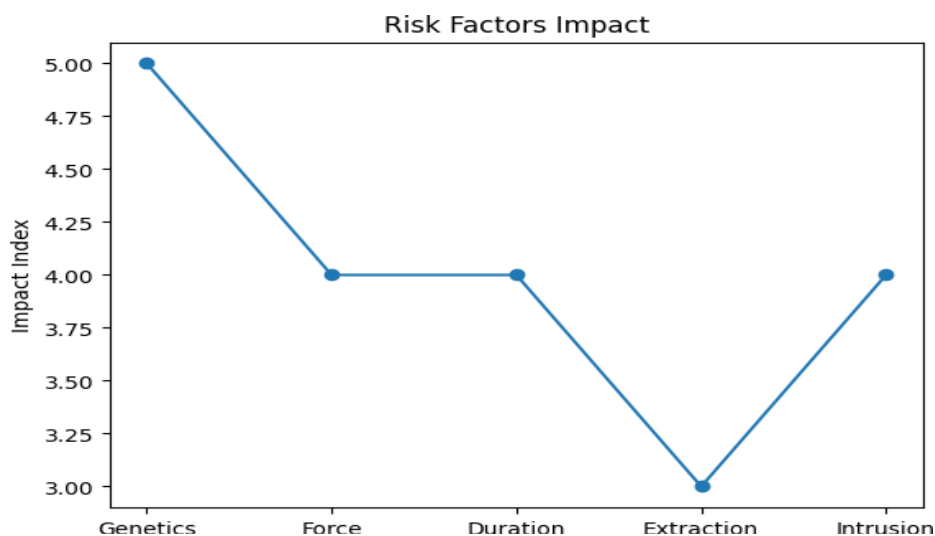


Fig. 2 Risk factors impact.

7. Diagnosis and Imaging

Accurate assessment of root resorption is essential for clinical management. Shokri et al. (10) demonstrated that CBCT provides significantly more accurate detection of root resorption compared to conventional periapical radiographs, which tend to underestimate its extent. Li et al. (4) further highlighted the importance of three-dimensional volumetric analysis in identifying subtle changes. Recent advancements include the use of artificial intelligence for automated CBCT analysis, improving diagnostic precision and enabling early detection. Additionally, emerging research on biomarkers in gingival crevicular fluid offers potential for detecting resorptive activity before radiographic changes become apparent.

8. Recent Advances

Recent studies have shifted focus toward biological and technological advancements in orthodontics. Genetic research (6) has identified key molecular pathways involved in inflammatory responses, providing insight into individual susceptibility. Artificial intelligence is increasingly being used to enhance CBCT analysis, allowing precise detection of root resorption. Emerging therapeutic approaches, such as low-intensity pulsed ultrasound, aim to reduce resorption by promoting tissue repair. Furthermore, the concept of personalized orthodontics is gaining importance, where treatment is tailored based on patient-specific risk factors, including genetic profile and bone characteristics.

9. Clinical Implications

Although root resorption is a common finding during orthodontic treatment, it is usually mild and clinically insignificant. However, severe resorption can compromise tooth stability and long-term prognosis. Regular radiographic monitoring, use of light controlled forces, and individualized treatment planning are essential for minimizing risk. Both aligners and fixed appliances require careful biomechanical control, and clinicians should consider patient-specific risk factors when selecting treatment modalities.

10. Conclusion

Current evidence indicates that both clear aligners and conventional fixed appliances are associated with root resorption, with no consistent evidence supporting the superiority of one modality. While aligners may demonstrate slightly reduced severity in certain cases, the difference is not clinically significant in most situations. Root resorption is primarily influenced by biological variability, genetic predisposition, and treatment mechanics. Future orthodontic practice should emphasize personalized treatment approaches and advanced diagnostic techniques to optimize outcomes and minimize adverse effects.

References

1. Inchingolo F, Tatullo M, Marrelli M, et al. Root resorption with clear aligners versus fixed appliances: A comparative study. *Applied Sciences*. 2024;14(2):690.
2. Weltman B, Vig KWL, Fields HW, Shanker S, Kaizar EE. Root resorption associated with orthodontic tooth movement: A systematic review.

- American Journal of Orthodontics and Dentofacial Orthopedics. 2010;137(4):462–476.
3. Yi J, Sun Y, Li Y, Li C, Li X, Zhao Z. External apical root resorption in orthodontic patients: A meta-analysis of randomized controlled trials. *The Angle Orthodontist*. 2016;86(1):132–140.
 4. Li Y, Li X, Yang Y, et al. Three-dimensional assessment of root resorption using cone-beam computed tomography in orthodontic patients. *BMC Oral Health*. 2020;20:116.
 5. Lund H, Gröndahl K, Gröndahl HG. Root resorption with clear aligners compared to fixed appliances: A systematic review. *Orthodontics & Craniofacial Research*. 2022;25(1):1–10.
 6. Iglesias-Linares A, Yáñez-Vico RM, Moreno-Fernández AM, et al. Genetic and biological factors influencing external apical root resorption. *Orthodontics & Craniofacial Research*. 2017;20(Suppl 1):42–48.
 7. Sameshima GT, Sinclair PM. Predicting and preventing root resorption: Part I. Diagnostic factors. *American Journal of Orthodontics and Dentofacial Orthopedics*. 2001;119(5):505–510.
 8. Krieger E, Drechsler T, Schmidtmann I, Jacobs C, Haag S, Wehrbein H. Apical root resorption during orthodontic treatment with aligners: A retrospective study. *Journal of Orofacial Orthopedics*. 2013;74(6):462–474.
 9. Buschang PH, Ross M, Shaw SG, Crosby D, Campbell PM. Orthodontic forces and tissue response: Implications for root resorption. *Seminars in Orthodontics*. 2014;20(3):162–177.
 10. Shokri A, Yarmohammadi S, Mortazavi H, et al. Comparison of cone-beam computed tomography and periapical radiography in detection of root resorption. *Imaging Science in Dentistry*. 2013;43(4):245–250.
 11. Lopatiene K, Dumbravaite A. Risk factors of root resorption after orthodontic treatment. *Stomatologija*. 2008;10(3):89–95.
 12. Brezniak N, Wasserstein A. Root resorption after orthodontic treatment: Part 1. Literature review. *American Journal of Orthodontics and Dentofacial Orthopedics*. 2002;121(4):346–355.
 13. Papageorgiou SN, Koletsi D, Iliadi A, et al. Clinical effectiveness of orthodontic aligners: A systematic review. *European Journal of Orthodontics*. 2021;43(4):442–452.
 14. Gupta S, et al. Evaluation of root length following orthodontic treatment using radiographic analysis. *Journal of Orthodontic Science*. 2018;7:11.
 15. Alqerban A, et al. Cone-beam computed tomography evaluation of root resorption in orthodontic treatment. *Progress in Orthodontics*. 2015;16:20.