

# Extirpation of Lingual Thyroglossal Duct Cyst with Transoral Extirpation

Latjandu Tiffany Megan<sup>1,2</sup>, Muhtarum Yusuf<sup>2,3</sup>

<sup>1</sup> Resident program of Otorhinolaryngology, Head and Neck Surgery, Faculty of Medicine, Universitas Airlangga,

<sup>2</sup> Dr. Soetomo General Academic Hospital, Surabaya

<sup>3</sup> Department of Otorhinolaryngology, Head and Neck Surgery, Faculty of Medicine, Universitas Airlangga

\*Corresponding Author : Latjandu Tiffany Megan

\*Residency Program of Otorhinolaryngology, Head and Neck Surgery, Faculty of Medicine, Universitas Airlangga, Dr. Soetomo General Academic Hospital, Surabaya, Indonesia; email : latjandu.tiffany.megan-2022@fk.unair.ac.id

---

## Abstract

**Introduction and Objectives:** Thyroglossal duct cyst can be classified based on location, tongue (2.1%), suprahyoid (24.1%), thyrohyoid (60.9%), and suprasternal (12.9%). Lingual thyroglossal duct cyst is a rare lesion and is often found incidentally. The development of surgical technology and patients' cosmetic concerns make the transoral approach favourable.

**Material and Methods:** A case of a thirteen-year-old girl with a thyroglossal duct cyst at the base of the tongue has been reported. A literature review was conducted using PubMed with (thyroglossal duct cyst or TGDC) and (tongue or lingual thyroglossal) and (surgery) as the keywords.

**Results:** In this case, the surgical technique for a lingual thyroglossal duct cyst was performed via a transoral approach without endoscopy. The selection of this surgical technique was based on considerations of easy visualization, minimal risk of bleeding, minimal risk of tissue trauma, and cosmetic. The conventional transoral approach without endoscopy performed in this case showed good surgical results, minimal intraoperative bleeding and no recurrence after one year postoperatively. Similar findings were observed in cases performed with the transoral and Sistrunk approaches.

**Conclusion:** Extirpation of the thyroglossal duct cyst was performed using a transoral approach. After one year of surgery, the patient had no complaints of discomfort when swallowing, eating and drinking were smooth, and no recurrence was found. This procedure can be a reference for the management of other similar cases.

**Keywords:** thyroglossal duct cyst, lingual thyroglossal, Sistrunk Method, Transoral surgery

---

**How to cite this article:** Megan LT, Yusuf M. Extirpation of Lingual Thyroglossal Duct Cyst with Transoral Extirpation. *Int J Drug Deliv Technol.* 2026;16(15s): 233-239. DOI: 10.25258/ijddt.16.15s.28

---

## Introduction

A thyroglossal duct cyst is the most common embryonic mass in the anterior neck. The thyroglossal duct connects the tongue base to the thyroid gland, and failure of its obliteration results in cyst formation. This anomaly occurs in approximately 7% of the population and accounts for 75% of congenital neck masses. Diagnosis can be challenging when the cyst is located at the floor of the mouth or sublingual region, where it may mimic cystic hygroma, dermoid cyst, or ranula. Imaging is required to confirm the diagnosis and to identify thyroid tissue.<sup>1</sup>

Thyroglossal duct cysts are classified by location as intralingual (2.1%), suprahyoid (24.1%), thyrohyoid (60.9%), and suprasternal (12.9%).<sup>2</sup> Lingual variants are rare and often incidental. Thyroglossal duct cysts may present with airway obstruction symptoms such as stridor, retraction, and dysphagia. This complication potentially misdiagnosis as laryngomalacia in neonates.<sup>3</sup>

Surgical excision is the treatment of choice. Advances in minimally invasive surgery and cosmetic considerations have increased the use of transoral and endoscopic approaches.<sup>4</sup> Complete resection of the cyst and tract yields recurrence rates of <2%, particularly when performed without capsule rupture and with

preservation of surrounding musculature.<sup>5</sup> The Sistrunk procedure remains the gold standard, involving excision of the cyst, central hyoid, and a segment of suprahyoid muscles toward the foramen cecum.<sup>6</sup> However, it may not always be applicable to lingual lesions.<sup>7</sup> Based on the above considerations, the management of thyroglossal duct cysts carries a low recurrence risk when performed appropriately. Therefore, a thorough understanding of surgical techniques is essential, particularly in cases involving lingual cysts.

This paper aims to report the clinical results of one case of thyroglossal duct cysts located at the base of the tongue with transoral surgical approach.

## Case Report

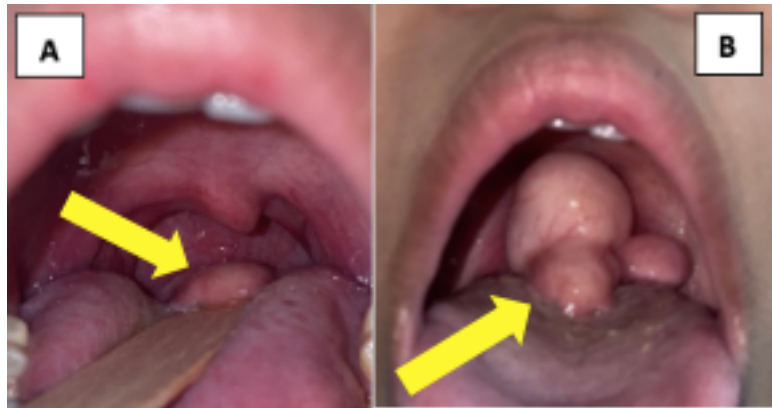
A thirteen-year-old girl was referred from Kediri Hospital to the outpatient clinic of Dr. Soetomo General Hospital, Surabaya, with a diagnosis of hypopharyngeal tumor on September 12, 2023. The chief complaint was a sensation of a lump in the throat for one week, particularly during swallowing. Dysphagia was described as requiring repeated swallowing, although oral intake remained adequate. Dyspnea was noted only during exertion, such as running. A mass in the oral cavity had been recognized since the age of one year, initially the size of a peanut, gradually enlarging to the

\*Author for Correspondence: latjandu.tiffany.megan-2022@fk.unair.ac.id

## Extirpation of Lingual Thyroglossal Duct Cyst with Transoral Extirpation

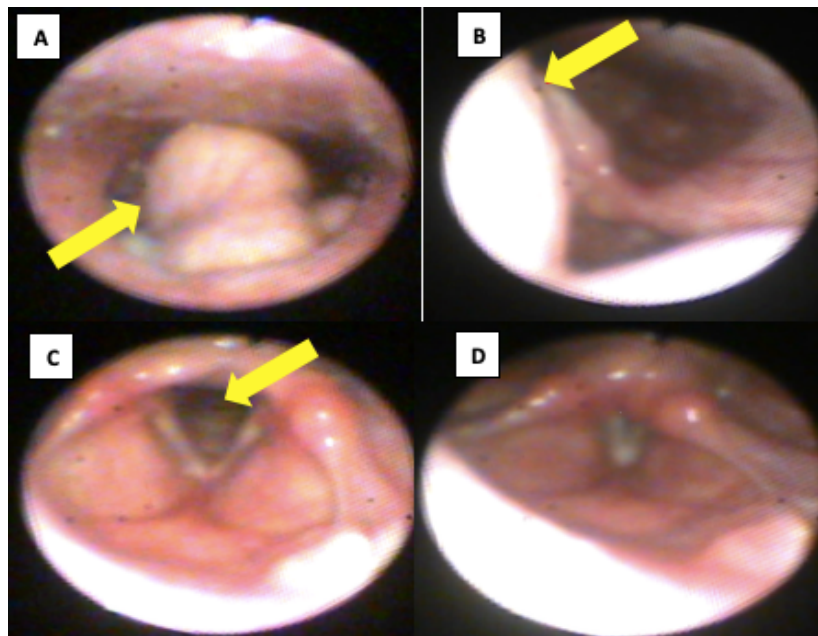
size of a chicken egg. The patient denied dyspnea at rest, pain, bleeding, fever, palpitations, or tremors. There was no family history of malignancy. On examination, the patient was in good general condition with stable vital signs. Ear, nose, and neck examinations were unremarkable. Oropharyngeal examination at rest revealed a smooth-surfaced mass measuring

approximately  $2 \times 2 \times 2$  cm at the tongue base (Figure 1A). With tongue protrusion, the mass measured approximately  $7 \times 4 \times 2$  cm, consisting of three lobes, pink in color similar to the oropharyngeal mucosa, with a smooth surface, regular margins, and non-friable appearance (Figure 1B). Tongue mobility was not restricted.



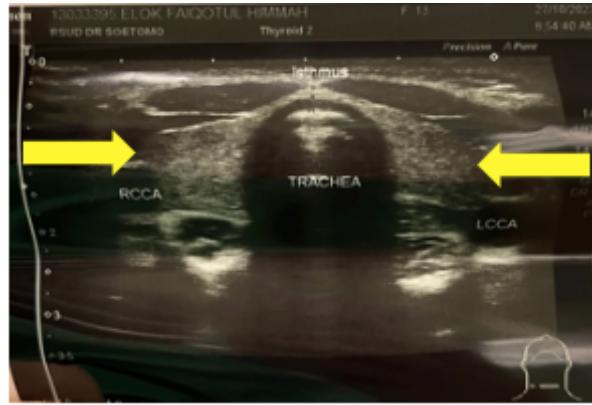
**Figure 1.** (A) Intraoral findings of the patient. (B) Intraoral findings during tongue protrusion.

Fiberoptic laryngoscopy (FOL) revealed a midline mass at the tongue base (Figure 2A), located above the epiglottis (Figure 2B), with a smooth surface and non-friable appearance. The airway was patent, and vocal cord movements were symmetrical (Figures 2C, 2D). Thyroid ultrasonography demonstrated no abnormalities in either lobe (Figure 3).



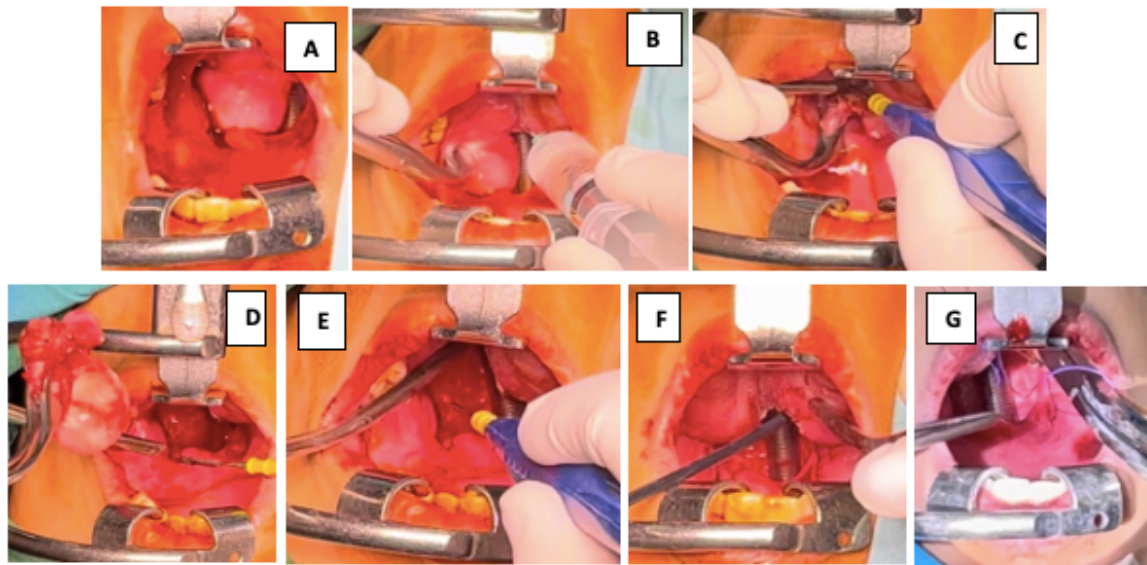
**Figure 2.** Fiberoptic laryngoscopy (FOL) findings. (A) Mass at the tongue base. (B) The mass does not involve the epiglottis. (C, D) Symmetrical vocal cord movements.

## Extirpation of Lingual Thyroglossal Duct Cyst with Transoral Extirpation



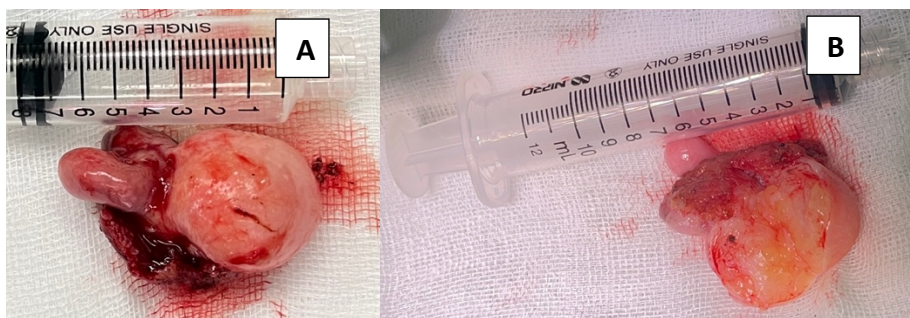
**Figure 3.** Thyroid ultrasonography.

Surgery was performed under general anesthesia with nasotracheal intubation using a non-kinking endotracheal tube. The patient was placed in the supine position with head hyperextension and shoulder support. Aseptic preparation was achieved with 70% alcohol and povidone-iodine. The operative field was draped with sterile cloths, and a size 3 mouth gag was applied. The mass was identified at the tongue base (Figure 4A), grasped with a Blohmke tonsil clamp, and infiltrated with lidocaine-epinephrine (Figure 4B). Excision was performed using electrocautery (Figures 4C, 4D). Hemostasis was achieved (Figures 4E, 4F), followed by closure with 3-0 absorbable multifilament sutures (Figure 4G). The estimated blood loss was 60 ml.



**Figure 4.** Intraoral mass excision.

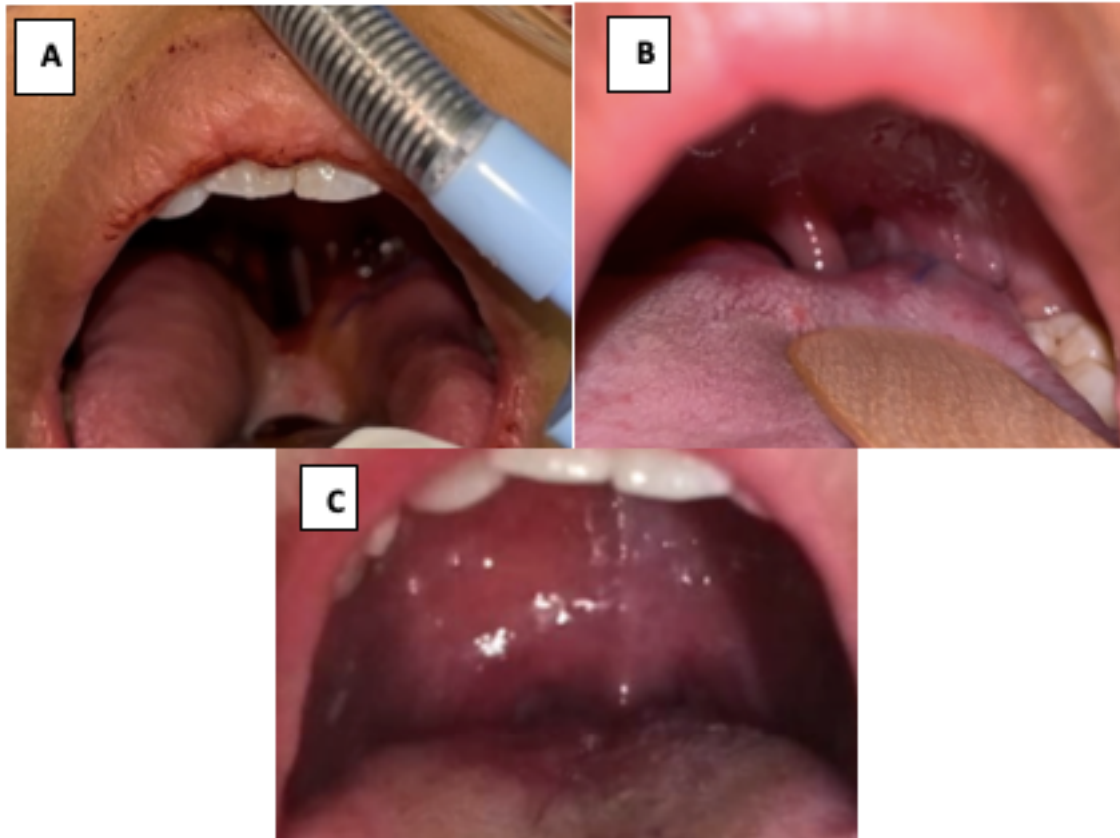
Intraoperative findings after excision revealed a smooth-surfaced, non-friable mass measuring  $7 \times 4 \times 3$  cm, located at the foramen cecum without attachment to the hyoid bone (Figure 5A). On incision, the mass contained solid tissue resembling fat (Figure 5B).



**Figure 5.** Intraoperative findings. (A) Mass before incision. (B) Mass after incision.

## Extirpation of Lingual Thyroglossal Duct Cyst with Transoral Extirpation

Postoperative follow-up showed good intraoral healing with no active bleeding and well-preserved sutures (Figure 6A). The patient received intravenous ceftriaxone 1 g every 8 hours until postoperative day four. At 14 days postoperatively, the patient reported no complaints; intraoral examination again showed no active bleeding and sutures in good condition (Figure 6B). Histopathological examination confirmed the diagnosis of a thyroglossal duct cyst. The patient did not return for further follow-up due to absence of symptoms.



**Figure 6.** Postoperative evaluation. (A) One hour after surgery. (B) Fourteen days after surgery. (C) One year after surgery.

### Method

A literature search was conducted in October 2024 on PubMed with the keywords (thyroglossal duct cyst OR TGDC) AND (tongue OR lingual thyroglossal) AND (surgery). The inclusion criteria were: 1) articles written in English or Indonesian, 2) case reports of PTC patients with thyroglossal duct cyst who underwent surgery, 3) systematic reviews, 4) full-text manuscripts available. Twenty four case reports were relevant to the topic and available in full text from 6 literature search results.

### Result

The primary management of thyroglossal duct cysts is surgical excision. Advances in transoral/endoscopic surgical techniques, along with greater attention to cosmetic outcomes, have gained increasing interest.<sup>4</sup> The outcomes of each method have shown favorable results (Table 1).

**Table 1. Analysis of problem, intervention, comparison, outcomes, and timeframe (PICOT).**

	<b>Problem</b>	<b>Intervention</b>	<b>Comparison</b>	<b>Outcomes/Time Frame</b>
Shumrick, et al., 2023. <sup>3</sup>	A 5-month-old female infant with a cystic lesion in the midline region of the foramen cecum, extending across the vallecula.	Sistrunk, transhyoid suture-guided pharyngotomy, laryngoscopy, and bronchoscopy	Transoral excision	No recurrence in 3 years.

## Extirpation of Lingual Thyroglossal Duct Cyst with Transoral Extirpation

	A 5-month-old male infant with a round submucosal mass located in the midline region of the foramen cecum, anterior to the vallecula.	Sistrunk, transhyoid suture-guided pharyngotomy, direct laryngoscopy, and bronchoscopy, and supraglottoplasty	Transoral excision	No recurrence in 3 years
	A 19-day-old neonate with a cystic mass at the base of the tongue, accompanied by epiglottic retroflexion and shortened aryepiglottic folds.	Sistrunk, transhyoid suture-guided pharyngotomy, direct laryngoscopy, supraglottoplasty	Transoral excision	No recurrence in 6 months.
Das, et al., 2023. <sup>7</sup>	A 7-year-old boy with a cystic lesion at the base of the tongue, with a smooth surface, extending to the vallecula and the lingual surface of the epiglottis.	Transoral surgery	Transoral Robotic Surgery (TORS) Excision	No recurrence in 18 months.
Johnston, et al., 2020. <sup>8</sup>	A 3-year-old boy with a cystic lesion at the base of the tongue, adjacent to the posterior aspect of the hyoid bone.	Sistrunk Prochcedure	Transoral Robotic Surgery (TORS) Excision	No recurrence in 2 weeks.
	A 4-year-old girl with a cystic mass in the midline at the base of the tongue, extending from the foramen cecum to the vallecula.	Sistrunk Prochcedure	Transoral Robotic Surgery (TORS) Excision	No recurrence in 2 weeks.
Chen, et al., 2022. <sup>9</sup>	A 24-year-old woman with a cystic lesion in the neck	Transoral Excision with Frenotomy	Sistrunk Prochcedure	No recurrence in 18 months.
Li, et al., 2024. <sup>10</sup>	A child (<18 years) with a cystic lesion in the neck	Modified (mSis)	Sistrunk Transoral excision	2.3% recurrence in 7 months
Nakai, et al., 2023. <sup>11</sup>	A 35-year-old woman with a cystic lesion in the neck	Transoral endoscopic vestibular approach (TEVAS)	Sistrunk Prochcedure	No recurrence in 19 months.

### Discussion

Thyroglossal duct cysts at the base of the tongue are rare. Based on medical records from the Teratai surgical inpatient unit over the past ten years, this was the first documented case of a thyroglossal duct cyst at the tongue base. The prevalence of intralingual thyroglossal duct cysts worldwide is reported to be 2.1%.<sup>2</sup>

In this case, the patient presented with a sensation of obstruction during swallowing, accompanied by a mass at the tongue base. These symptoms are consistent with previous studies, which describe a globus sensation and dysphagia. In some cases, lingual thyroglossal duct cysts may cause airway obstruction. Flexible laryngoscopy revealed that the mass was attached to the tongue base and did not arise from the epiglottis. Thyroid ultrasonography was normal. The diagnosis was confirmed by histopathological examination, which demonstrated a thyroglossal duct cyst.

Lingual thyroglossal duct cysts arise from failure of the thyroglossal tract to undergo complete obliteration

during embryogenesis, as the thyroid gland migrates from the foramen cecum at the tongue base to the anterior neck. The thyroglossal duct originates from the foramen cecum, located at the junction of the anterior two-thirds and posterior one-third of the tongue, and extends to the thyroid cartilage, where the definitive thyroid gland develops. The inferior portion of the duct may persist as the pyramidal lobe, while the remainder typically involutes by the tenth week of gestation. Failure of obliteration may result in cyst or sinus formation.<sup>5</sup>

In this case, surgical management was performed using a transoral approach without endoscopic assistance. This technique was chosen because it allows adequate visualization, carries minimal risk of bleeding and tissue trauma, and provides superior cosmetic outcomes by avoiding a cervical scar—an important consideration in pediatric and female patients. Intraoperative visualization using a mouth gag and headlight confirmed that the cyst did not extend to the hyoid bone. Radical

excision was performed with electrocautery, and hemostasis was achieved with suturing.

Traditionally, thyroglossal duct cysts are managed via a cervical approach using the Sistrunk procedure, which involves en bloc cystectomy, central hyoid resection, and excision of the entire epithelial tract up to the foramen cecum. Recurrence is a common problem.<sup>8</sup> This technique can be technically challenging when the thyroglossal tract remnant is located near the foramen cecum.<sup>5</sup> Given the cyst location and the patient's young age, a transoral approach is recommended for intralingual cases to improve visualization of the thyroglossal tract remnant while avoiding a cervical scar.<sup>5</sup> Techniques include transoral marsupialization, transoral endoscopic excision, and Transoral Robotic Surgery (TORS).<sup>12,13</sup>

There are reports of three cases of tongue-base thyroglossal duct cysts managed with the Sistrunk procedure, where the indication was extension into the vallecula or associated laryngomalacia. However, this approach carries the risk of laryngeal destabilization and airway compromise, which is less likely with minimally invasive transoral approaches.<sup>3</sup> A modified Sistrunk without endoscopy has also been reported, in which the cartilaginous junction of the hyoid corpus and greater cornu was divided using needle electrocautery. This technique may reduce intraoperative bleeding.<sup>10</sup>

Non-conventional approaches, including transoral techniques, have been reported to yield shorter operative times and lower postoperative morbidity compared to conventional methods. This approach is particularly suitable in pediatric patients with lingual thyroglossal duct cysts, as it avoids unnecessary hyoid dissection. Reported outcomes demonstrate no complications or recurrence. Simple cyst excision with TORS is also an effective option; however, larger dissections are associated with a higher risk of complications such as bleeding.<sup>7,15-17</sup>

Other cases have described transoral excision with frenotomy. A transverse incision is made in the lingual frenulum, followed by dissection of the floor of the mouth. The genioglossus muscle is separated and retracted, while the suprahyoid muscles are dissected under endoscopic guidance (4 mm). The hyoid bone is then identified and divided using a Kerrison rongeur. The infrahyoid muscles are dissected 0.5 cm from the hyoid. Superior traction of the hyoid with forceps exposes the cyst for dissection. This approach shortens operative time and has not been associated with postoperative complications. Potential risks include incision-site infection, sublingual edema leading to airway obstruction, a restricted operative field requiring patience and surgical expertise, and intraoperative rupture of the cyst causing widespread methylene blue staining of the field. This method has been safely applied for cysts up to 6 cm in size.<sup>9</sup> A similar technique has also been performed via the oral vestibule.<sup>11</sup>

Another modification of the Sistrunk procedure employs the posthyoid space (PHS) approach, enabling complete and safe resection of the hyoid bone while avoiding injury to vessels and lymphatics. This concept provides transoral access to the anterior cervical mass using a 30°

endoscope with external pressure on the hyoid. The outcome is a minimally invasive procedure with no visible scar and low recurrence. TORS enhances this further, allowing for four-handed manipulation, three-dimensional visualization, and improved surgical precision.<sup>8</sup>

In the present case, conventional transoral excision without endoscopy yielded excellent results, with minimal intraoperative bleeding and no recurrence at one-year follow-up. Similar findings have been reported in other cases managed either transorally or with the Sistrunk procedure. The highest recurrence rates have been observed in patients managed with modified Sistrunk procedures.

### Conclusions

We report a case of a 13-year-old girl with a thyroglossal duct cyst at the base of the tongue. The cyst was excised via a transoral approach. At one-year postoperative follow-up, the patient was asymptomatic, with no globus sensation during swallowing, normal oral intake, and no evidence of recurrence. This procedure may serve as a reference for the management of similar cases.

### REFERENCES

1. Taha A, Enodien B, Frey DM, Mehlitz ST. Thyroglossal duct cyst, a case report and literature review. *MDPI* 2022;10(1):1-7.
2. Maheshwari S, Agarwal P, Tripathi A, Raheja K, Goel R, Dubey S. Rare case of lingual thyroglossal duct presenting in infant with respiratory distress. *Journal of Pediatric Critical Care* 2022;9(5):183-5.
3. Shumrick CM, Calder AN, Vecchiotti MA, Scott AR. Symptomatic lingual thyroglossal duct cyst in children: a laryngomalacia phenotype. *Annals of Otolaryngology, Rhinology and Laryngology* 2023;132(1):95-9.
4. Gao K, Han J, Zhou X, Luan D, Xie F, Li Y. A new transoral modality for the treatment of lingual thyroglossal duct cyst with suspension laryngoscopy by plasma coblation. *Ann R Coll Surg Engl* 2021;103(6):438-43.
5. Turri-Zanoni M, Battaglia P, Castelnuovo P. Thyroglossal duct cyst at the base of tongue: the emerging role of transoral endoscopic-assisted surgery. *Journal of Craniofacial Surgery* 2018;29(2): 469-70.
6. Fagan J. Thyroglossal duct remnants. In: *Atlas of otolaryngology, head and neck operative surgery*, 1<sup>st</sup> ed. Capetown : University of Capetown; 2017. p. 211-6.
7. Sameer KSM, Mohanty S, Correa MMA, Das K. Lingual thyroglossal duct cysts-a review. *International Journal of Pediatric Otorhinolaryngology* 2012;76(2):165-8.
8. Johnston DR, Maurrasse SE, Maddalozzo J. Transoral robotic surgery excision of lingual thyroglossal duct cysts including the central hyoid bone. *Laryngoscope* 2021;131(4):1345-8.
9. Chen S, Wang D, Qiu J. Endoscopic-assisted transoral thyroglossal duct cyst resection. *Front Endocrinol* 2022;12(1):1-6.

10. Li X, Zhang G, Li Y. Modified sistrunk procedure in 391 pediatric thyroglossal duct cyst cases. *Ear Nose Throat J.* 2024;1(1):1-8
11. Nakai MY, Tenório LR, da Silva COJ. Transoral endoscopic vestibular approach Sistrunk procedure (TEVAS). *Gland Surgery* 2024; 13(1):236–47.
12. Fong S, Hodge JC, Foreman A, Krishnan S. Transoral robotic excision of a lingual thyroglossal duct cyst. *J Robot Surg* 2018;12(2):357–60.
13. Maddalozzo J, Alderfer J, Modi V. Posterior hyoid space as related to excision of the thyroglossal duct cyst. *Laryngoscope* 2010;120(9):1773–8.
14. Burkart CM, Richter GT, Rutter MJ, Myer CM. Update on endoscopic management of lingual thyroglossal duct cysts. *Laryngoscope* 2009;119(10):2055–60.
15. Hay A, Migliacci J, Karassawa ZD, Boyle JO, Singh B, Wong R, et al. Complications following transoral robotic surgery (TORS): a detailed institutional review of complications. *Oral Oncol* 2017;67(1):160–6.
16. Turhan M, Bostanci A. Robotic resection of lingual thyroglossal duct cyst in an infant. *J Robot Surg* 2019;13(2):331–4.
17. Kayhan FT, Kaya KH, Koc AK, Altintas A, Erdur O. Transoral surgery for an infant thyroglossal duct cyst. *Int J Pediatr Otorhinolaryngol* 2013;77(9):1620–3.