

“A Comparative Evaluation of Modified Saturated Salt Solution Versus Salt-Added in Glutaraldehyde Solution used as an Embalming Solution, on Wistar Rats for Anatomical Education, A Morphological Study.”

Dr. Padmini K Shinde,¹ Dr. Mini Mol P.^{2*}

¹PhD scholar, Department of Anatomy, MGM Medical College, Kamothe, MGMIHS, Navi Mumbai, Maharashtra 410209.

^{2*} Professor, Department of Anatomy, MGM Medical College, Kamothe, MGMIHS, Navi Mumbai, Maharashtra 410209.

***Corresponding Author:** Dr. Mini Mol P.

Professor, Department of Anatomy, MGM Medical College, Kamothe, MGMIHS, Navi Mumbai, Maharashtra 410209.

Abstract

Formaldehyde is most commonly used as a fixative and embalming agent because of its quick action, strong bactericidal activity, availability and cost-effectiveness. However, it is known to be a health hazard for both acute and chronic exposure. It is also classified as a class 1B carcinogenic agent by W. Researchers are seeking an alternative to formaldehyde that is effective as a preservative, poses lower health risks to teachers, students, handlers and at the same time environmentally friendly. To reduce the toxicity and irritation caused by formaldehyde, a few chemicals have been studied over the years that can fully or partially replace it in formaldehyde such as glutaraldehyde and saturated salt solutions and other embalming methods.

This study involved Wistar rats embalmed with four different embalming fluids, followed by submersion for 1, 8, and 16 weeks. The fluids included low concentrations of formaldehyde, glutaraldehyde, saturated salt solution, and a mixture of glutaraldehyde with salt solution. The study observed their gross effects, range of motion, and microbial growth. We found that the glutaraldehyde and saturated salt maintained a lifelike appearance of all visceral organs for a longer duration, exhibited greater motility, and showed no microbial growth compared with other groups. Still, glutaraldehyde has an irritant smell & is more costly, while modified SSS is non-irritant & cheaper as compared to other fluids. It also preserved pancreases & cerebrum more life-like as compared to glutaraldehyde solution

How to cite this article: Shinde PK, Mini Mol P. A Comparative Evaluation of Modified Saturated Salt Solution Versus Salt-Added in Glutaraldehyde Solution Used as an Embalming Solution, on Wistar Rats for Anatomical Education, A Morphological Study. *Int J Drug Deliv Technol.* 2026;16(17s): 806-817. DOI: 10.25258/ijddt.16.17s.95.

Introduction

Cadavers are essential resources for medical education it providing detailed information on the structure of human anatomy, which can not be possible through notebooks or by virtual study. The preservation of the cadavers for medical education, research, and surgical training involves a preliminary process called embalming (1) Embalming is the process of preserving cadavers by reducing the presence and growth of microorganisms, retarding decomposition, and restoring an acceptable physical appearance using various embalming techniques and fluids. Formaldehyde is most commonly used as an embalming agent because it is low-cost, highly bactericidal, acts quickly, and a small amount of formalin can preserve a large number of tissue specimens. However, exposure to formaldehyde causes a strong irritant odor. It is known to have health hazards, also classified as a carcinogen by the International Agency for Research on Cancer in June 2004.(2) (benefit & pitfall). There is an increasing need to find an alternative to formaldehyde, a preservative that reduces irritation and toxicity. A small number of chemicals have been researched for years and can either fully or partially replace it, such as low-concentration formaldehyde,

glutaraldehyde, and saturated salt solutions, which are considered good embalming agents (3)

Hayashi et al., Coleman, and Kogan first introduced a saturated salt solution as an embalming fluid, and their results show that this fluid has good antimicrobial properties, maintains joint flexibility, and is suitable for surgical skill training. (4)

(Natekar & Desouza found that glutaraldehyde is also effective for preserving cadavers, owing to its known antimicrobial properties. It also maintains the cadaver's flexibility and is useful for surgical skill training.(5)

The main aim of this study is to investigate and develop an embalming fluid that provides a non-irritant odor, a life-like appearance of the visceral organs, antimicrobial properties, and long-term preservation of the cadaver, while remaining safe for the handler.

In this study, 66 Wistar rats were embalmed with 4 different embalming fluids (Formaldehyde, Glutaraldehyde, saturated salt solution, and Glutaraldehyde with salt), and then the effects of these embalming fluids were compared by evaluating odor, color, and texture of external and internal features, range of motion, and microbial properties after the 1st, 8th, and 16th weeks of embalming,

MATERIALS & METHODS:

*Author for Correspondence: Dr. Mini Mol P.

A Comparative Evaluation of Modified Saturated Salt Solution Versus Salt-Added in Glutaraldehyde Solution used as an Embalming Solution, on Wistar Rats for Anatomical Education, A Morphological Study.”

The Institutional Animal Ethical Committee approved this study under approval number (N-2023/10/02). The study consisted of 66 male and female Wistar rats, aged 8 to 9 weeks. These Wistar rats were randomly divided into 4 main groups according to the embalming solution. (Group A: Formaldehyde, Group B: Glutaraldehyde, Group C: Saturated salt solution, Group D: Glutaraldehyde with salt). The composition of each group is shown in Table 1. Then each group was subdivided into 3 subgroups based on the duration of the immersion period. Each subgroup consisted of 6 Wistar rats. The rats were euthanized by intraperitoneal injection of sodium phenobarbitone at a dosage of 150 mg/kg, followed by embalming solution according to group into the carcasses via the common carotid artery until the fluid flowed from natural orifices, ensuring thorough perfusion. The carcasses (n=6) were then submerged in a tank containing 6 liters of fluid for different time periods (the composition of submerged fluid provided in Table 2). After the 1st, 8th, and 16th weeks of embalming, the odor, gross changes, microbial growth, and range of motion were measured. These changes were evaluated by six independent, blinded examiners (comprising three anatomists and three pathologists). Their findings were scored using a Likert scale, and the most frequently occurring score (mode) among the three assessors was used; if no single mode was present, the median score was used.

Odour of embalming fluid was analysed by using three point scale.

A) The odour of embalming fluid is scored from I to III

Grade I: strongly irritant odour

Grade II: less irritant odour than I

Grade III: Non-irritant odour.

B) The colour & texture of skin, fascia & visceral organs were analysed by using five point likert scale

The physical appearance (color, texture, and tonicity) of the skin, fascia, skeletal muscle, and visceral organs was scored from I to V,

Grade I indicates very poor and totally distorted

Grade II indicates poor and moderately distorted

Grade III indicates fair and mildly distorted

Grade IV indicates good but less intact

Grade V indicates very good and completely intact

C) Range of motion

Range of motion is measured using a 0 to 180-degree stainless steel Goniometer.

The range of motion of the bilateral elbow & knee joint was measured in flexion and extension positions.

Measurements by a single examiner, by 3 times per joint, were made for accuracy.

D) Microbial test

A microbial test was done by using the IN-USE test. Tank fluid was taken after 1, 8 & 16th weeks of embalming. (6)

Table no 1 : Composition of 3 liters of embalming fluid

Formaldehyde (A)	Glutaraldehyde (B)	Saturated salt solution (c)	Glutaraldehyde with salt (D)
Formalin 37% 30 ml Methanol 2000ml Normal saline 300ml Water 637ml Sodium citrate 15ml Glycerine 15ml Phenol 3ml Thymol 1 gm	2% Glutaraldehyde 1300ml Methyl alcohol 200ml Water 1300ml Centrimide 165ml Glycerine 15ml Eosin 15ml Oil of eucalyptus 5ml Thymol 1 gm	Formaldehyde (37%) 50ml Water 2717 + 600gm Nacl Isopropyl alcohol 200ml Glycerine 15ml Phenol 3ml Sodium citrate 15ml Thymol 1 gm	2% Glutaraldehyde 1300ml+salt 100gm Methyl alcohol 200ml Water 1300ml Centrimide 165ml Eosin 15ml Oil of eucalyptus 5ml Thymol 1 gm

Table no 2 : Composition of submerged fluid in a 6-liter tank

Formaldehyde	Glutaraldehyde	Saturated salt solution	Glutaraldehyde with salt
Formaldehyde 1 liter + 5liter water	2% glutaraldehyde 1 liter + 5 liter	1liter formaldehyde + 5Liter water + 1200gm Nacl	2% Glutaraldehyde 1 liter + 5liter water + 200gm salt

Statistics:

Statistical methods were employed to evaluate the effects of embalming agents. The Shapiro–Wilk test was utilized to determine the normality of the data set.

Interrater agreement for each morphological parameter was assessed using Fleiss’ Kappa statistical method. Based on the normal distribution of the data, one-way ANOVA and the Kruskal-Wallis test were applied to

A Comparative Evaluation of Modified Saturated Salt Solution Versus Salt-Added in Glutaraldehyde Solution used as an Embalming Solution, on Wistar Rats for Anatomical Education, A Morphological Study.”

compare multiple group variables, followed by post hoc analysis or multiple comparison analysis using SPSS version 29.

RESULT:

A. Morphological Assessment:

Odour was analysed by three-grade scaling, Mean rank of odour shows that formaldehyde is the lowest rank (3.50 at 16th week), while glutaraldehyde shows (12.50 at 16th week) & glutaraldehyde with salt (12.50 at 8th week) are less irritant than formaldehyde, while saturated salt solution is a higher rank (15.50 at 16th week)

Physical appearance of visceral organs:

Odour : odour of formaldehyde is more irritating than that of glutaraldehyde & with salt is less irritant than formaldehyde & glutaraldehyde, while SSS has a non-irritant smell throughout the study

Skin & fascia: It was observed that Wistar rats embalmed with Group A & Group B solutions maintained the tonicity & elasticity of the skin & fascia, but the skin turned yellowish throughout the 16-week embalming period. Group C embalmed rats showed a lifelike skin appearance and maintained their tonicity throughout 16 weeks of embalming. Group D showed blackish discoloration of the skin & fascia, with a mild-to-distorted appearance at the 8th week of embalming.

Colour & tonicity of visceral organs: Group A shows a lifelike appearance of all visceral organs, with

maintained tonicity throughout the 16-week embalming period. The colour of the visceral organ is reddish brown after 1 week of embalming, then turns brownish to blackish at the end of 16 weeks. Only the pancreas shows early distortion. The Group C & Group D showed a natural, life-like appearance of all visceral organs regarding the color, tonicity, and elasticity of the organs, excluding the pancreas, which is fully preserved only in the Group C. Group D caused blackish discoloration and a distorted appearance of all visceral organs, so this group was excluded after 8 weeks. In this study, the SSS group ranked highest in maintaining the morphology of all visceral organs. (P=.002 and 0.049, respectively)

Cerebrum: In Group A & Group B, the cerebrum maintains its tonicity only after 1 week of embalming; thereafter, it is moderately distorted throughout the 16 weeks of embalming. Group C maintains tonicity throughout the 16-week embalming process. While Group D shows a severely distorted appearance after 8th weeks of embalming

Blood vessels: All blood vessels are easily distinguishable in Groups A, B, and C. Only in Group D show blackish discoloration & distorted appearance.

Flexibility: saturated salt solution shows a greater degree of range of motion as compared to other embalming agents.

Microbial growth: only the glutaraldehyde with a salt solution shows microbial growth after 8 weeks of embalming.

Figure 1

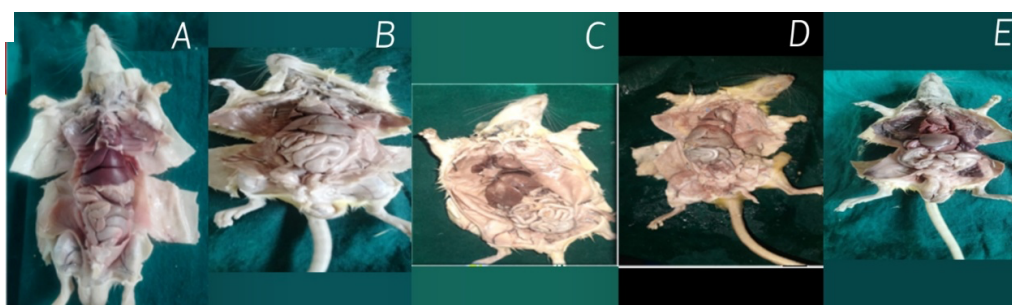


Figure 1 shows the display of visceral organs of embalmed Wistar Rats with gradings.

Grade V: Totally intact (A), Grade IV: less intact (B), Grade III: mildly distorted (C), Grade II :moderately distorted (D), Grade I: severely

Mean Ranks of odour for 1 week of embalming.

Embalming agents	N	Mean Rank
Odour at 1st week		
Odour at 1st week Formaldehyde	6	3.50
Glutaraldehyde	6	12.50
Saturated Salt Solution	6	21.50

A Comparative Evaluation of Modified Saturated Salt Solution Versus Salt-Added in Glutaraldehyde Solution used as an Embalming Solution, on Wistar Rats for Anatomical Education, A Morphological Study.”

Glutaraldehyde with salt	6	12.50
Total	24	

Test Statistics^{a,b}

Odour at 1st week	
Kruskal-Wallis H	23.000
df	3
Asymp. Sig.	.000

a. Kruskal Wallis Test

b. Grouping Variable: Embalming agents

ORGANS

Mean Ranks of visceral organs at 1 week

	Embalming agents	N	Mean Rank
Physical appearance of Skin and Fascia at 1st week	Formaldehyde	6	14.33
	Glutaraldehyde	6	16.00
	Saturated Salt Solution	6	16.00
	Glutaraldehyde with salt	6	3.67
	Total	24	
Physical appearance of Lungs and Heart at 1st week	Formaldehyde	6	14.25
	Glutaraldehyde	6	16.00
	Saturated Salt Solution	6	16.00
	Glutaraldehyde with salt	6	3.75
	Total	24	
Physical appearance of Liver, stomach, Intestines and spleen at 1st week	Formaldehyde	6	14.50
	Glutaraldehyde	6	16.00
	Saturated Salt Solution	6	16.00
	Glutaraldehyde with salt	6	3.50
	Total	24	
Physical appearance of Pancreas at 1st week	Formaldehyde	6	9.50
	Glutaraldehyde	6	18.50
	Saturated Salt Solution	6	18.50
	Glutaraldehyde with salt	6	3.50
	Total	24	
Physical appearance of Kidney at 1st week	Formaldehyde	6	14.17
	Glutaraldehyde	6	16.00
	Saturated Salt Solution	6	16.00
	Glutaraldehyde with salt	6	3.83
	Total	24	
Physical appearance of Muscle at 1st week	Formaldehyde	6	15.50
	Glutaraldehyde	6	15.50
	Saturated Salt Solution	6	15.50
	Glutaraldehyde with salt	6	15.50
	Total	24	

A Comparative Evaluation of Modified Saturated Salt Solution Versus Salt-Added in Glutaraldehyde Solution used as an Embalming Solution, on Wistar Rats for Anatomical Education, A Morphological Study.”

	Glutaraldehyde with salt	6	3.50
	Total	24	
Physical appearance of Blood vessels at 1st week	Formaldehyde	6	15.50
	Glutaraldehyde	6	15.50
	Saturated Salt Solution	6	15.50
	Glutaraldehyde with salt	6	3.50
	Total	24	
Physical appearance of Cerebrum at 1st week	Formaldehyde	6	15.50
	Glutaraldehyde	6	15.50
	Saturated Salt Solution	6	15.50
	Glutaraldehyde with salt	6	3.50
	Total	24	

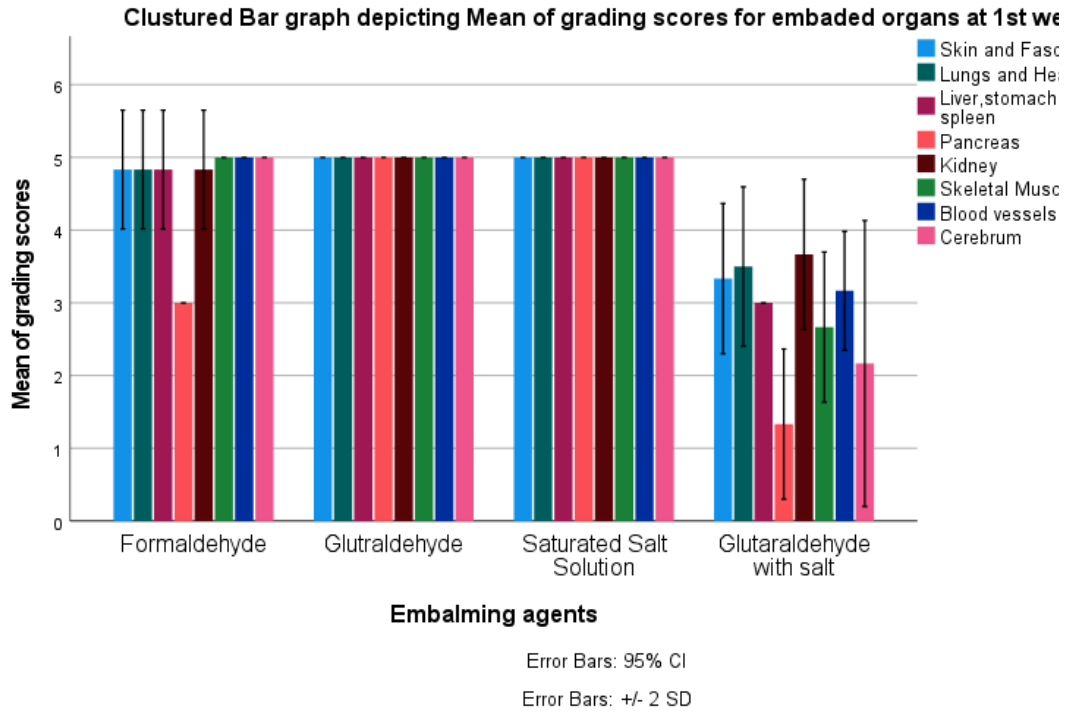
Test Statistics^{a,b}

	Physical appearance of Skin and Fascia at 1st week	Physical appearance of Lungs and Heart at 1st week	Physical appearance of Liver, stomach, Intestine and spleen at 1st week	Physical appearance of Pancreas at 1st week	Physical appearance of Kidney at 1st week	Physical appearance of Muscle at 1st week	Physical appearance of Blood vessels at 1st week	Physical appearance of Cerebrum at 1st week
Kruskal-Wallis H	19.881	19.550	20.857	22.720	19.316	22.582	22.737	22.480
df	3	3	3	3	3	3	3	3
Asymp. Sig.	.000	.000	.000	.000	.000	.000	.000	.000

a. Kruskal Wallis Test

A Comparative Evaluation of Modified Saturated Salt Solution Versus Salt-Added in Glutaraldehyde Solution used as an Embalming Solution, on Wistar Rats for Anatomical Education, A Morphological Study.”

b. Grouping Variable: Embalming agents



8th week study

1. ODOUR

Mean Ranks of odour at 8 th week

Odour at 8th week	Embalming agents at 8 week		Mean Rank
		N	
week	Formaldehyde	6	3.50
	Glutaraldehyde	6	12.50
	Saturated Salt Solution	6	21.50
	Glutaraldehyde with salt	6	12.50
	Total	24	

Independent-Samples Kruskal-Wallis Test Summary

Total N	24
Test Statistic	23.000 ^a
Degree Of Freedom	3
Asymptotic Sig.(2-sided test)	.000

a. The test statistic is adjusted for ties.

2. OTHER ORGAN ANALYSIS

Mean Ranks of visceral organs at 8th week

Skin and Fascia	Embalming agents at 8 week		Mean Rank
		N	
	Formaldehyde	6	12.50
	Glutaraldehyde	6	17.00

A Comparative Evaluation of Modified Saturated Salt Solution Versus Salt-Added in Glutaraldehyde Solution used as an Embalming Solution, on Wistar Rats for Anatomical Education, A Morphological Study.”

	Saturated Solution	Salt6	17.00
	Glutaraldehyde with salt	6	3.50
	Total	24	
Lungs and Heart	Formaldehyde	6	13.50
	Glutaraldehyde	6	16.50
	Saturated Solution	Salt6	16.50
	Glutaraldehyde with salt	6	3.50
	Total	24	
Liver, stomach, Intestines and spleen	Formaldehyde	6	13.50
	Glutaraldehyde	6	16.50
	Saturated Solution	Salt6	16.50
	Glutaraldehyde with salt	6	3.50
	Total	24	
Pancreas	Formaldehyde	6	11.00
	Glutaraldehyde	6	14.00
	Saturated Solution	Salt6	21.50
	Glutaraldehyde with salt	6	3.50
	Total	24	
Kidney	Formaldehyde	6	14.50
	Glutaraldehyde	6	16.00
	Saturated Solution	Salt6	16.00
	Glutaraldehyde with salt	6	3.50
	Total	24	
Skeletal Muscle	Formaldehyde	6	14.50
	Glutaraldehyde	6	16.00
	Saturated Solution	Salt6	16.00
	Glutaraldehyde with salt	6	3.50
	Total	24	
Blood vessels	Formaldehyde	6	12.50
	Glutaraldehyde	6	17.00
	Saturated Solution	Salt6	17.00
	Glutaraldehyde with salt	6	3.50
	Total	24	
Cerebrum	Formaldehyde	6	12.50
	Glutaraldehyde	6	17.00
	Saturated Solution	Salt6	17.00
	Glutaraldehyde with salt	6	3.50
	Total	24	

Test Statistics^{a,b}

A Comparative Evaluation of Modified Saturated Salt Solution Versus Salt-Added in Glutaraldehyde Solution used as an Embalming Solution, on Wistar Rats for Anatomical Education, A Morphological Study.”

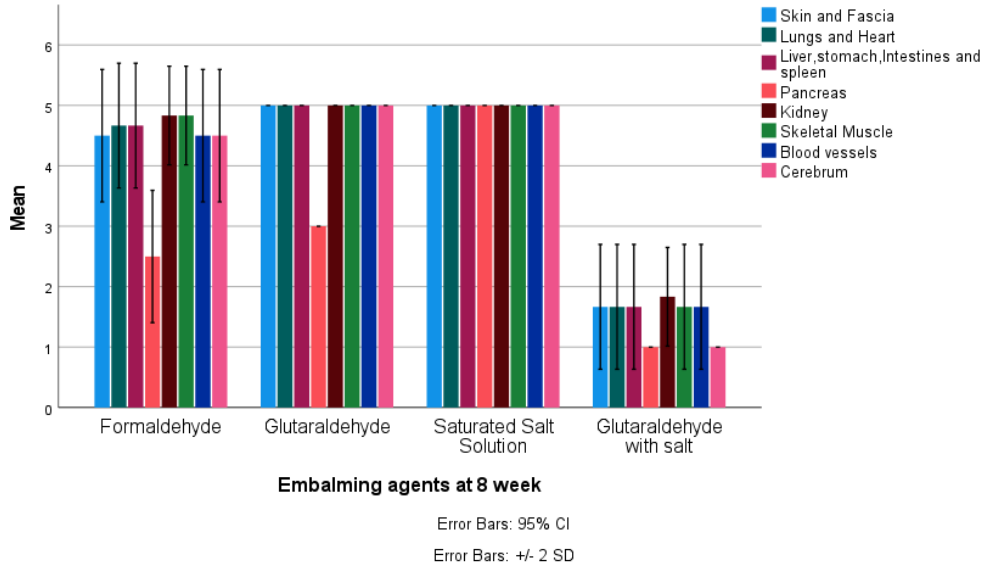
	Skin and Fascia	Lungs and Heart	Liver, stomach, Intestines and spleen	Pancreas	Kidney	Skeletal Muscle	Blood vessels	Cerebrum
Kruskal-Wallis H	19.440	19.567	19.567	21.821	20.643	20.517	19.440	19.440
df	3	3	3	3	3	3	3	3
Asymp. Sig.	.000	.000	.000	.000	.000	.000	.000	.000

a. Kruskal Wallis Test

A Comparative Evaluation of Modified Saturated Salt Solution Versus Salt-Added in Glutaraldehyde Solution used as an Embalming Solution, on Wistar Rats for Anatomical Education, A Morphological Study.”

b. Grouping Variable: Embalming agents at 8 week

Clustured Bar graph depicting Mean of grading scores for physical appearances of various organs at 8th week



16th week study

1. ODOUR

Mean Ranks of odour at 16th week

Odour at 16th week	Embalming agents at 16 week		Mean Rank
	Embalming agents at 16 week	N	
	Formalin	6	3.50
	Glutaraldehyde	6	9.50
	SSS	6	15.50
	Total	18	

Test Statistics^{a,b}

	Odour at 16th week
Kruskal-Wallis H	17.000
df	2
Asymp. Sig.	.000

a. Kruskal Wallis Test

b. Grouping Variable: Embalming agents at 16 week

Each row tests the null hypothesis that the Sample 1 and Sample 2 distributions are the same.

Asymptotic significances (2-sided tests) are displayed. The significance level is .050.

a. Significance values have been adjusted by the Bonferroni correction for multiple tests.

Mean rank of visceral organ at 16th week

Skin and Fascia at 16th week	Embalming agents at 16 week		Mean Rank
	Embalming agents at 16 week	N	
	Formalin	6	3.50
	Glutaraldehyde	6	12.50
	SSS	6	12.50
	Total	18	
	Formalin	6	4.00

A Comparative Evaluation of Modified Saturated Salt Solution Versus Salt-Added in Glutaraldehyde Solution used as an Embalming Solution, on Wistar Rats for Anatomical Education, A Morphological Study.”

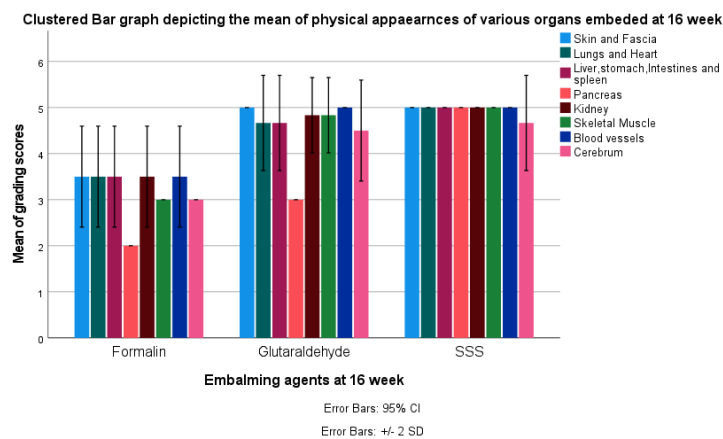
Lungs and Heart at 16th week	Glutaraldehyde	6	11.00
	SSS	6	13.50
	Total	18	
Liver, stomach, Intestines and spleen at 16th week	Formalin	6	4.00
	Glutaraldehyde	6	11.00
	SSS	6	13.50
Pancreas at 16th week	Formalin	6	3.50
	Glutaraldehyde	6	9.50
	SSS	6	15.50
Kidney at 16th week	Formalin	6	3.75
	Glutaraldehyde	6	11.75
	SSS	6	13.00
Skeletal Muscle at 16th week	Formalin	6	3.50
	Glutaraldehyde	6	12.00
	SSS	6	13.00
Blood vessels at 16th week	Formalin	6	3.50
	Glutaraldehyde	6	12.50
	SSS	6	12.50
Cerebrum at 16th week	Formalin	6	3.50
	Glutaraldehyde	6	12.00
	SSS	6	13.00
Total	18		

Pairwise Comparisons of Embalming agents at 16 week

Sample 1-Sample 2	Test Statistic	Std. Error	Std. Test Statistic	Sig.	Adj. Sig. ^a
Formalin-Glutaraldehyde	-6.000	2.910	-2.062	.039	.118
Formalin-SSS	-12.000	2.910	-4.123	.000	.000
Glutaraldehyde-SSS	-6.000	2.910	-2.062	.039	.118

Each row tests the null hypothesis that the Sample 1 and Sample 2 distributions are the same. Asymptotic significances (2-sided tests) are displayed. The significance level is .050.

a. Significance values have been adjusted by the Bonferroni correction for multiple tests.



DISCUSSION

The main goal of this study is to identify an effective embalming solution that is safe, cost-effective, and can

preserve cadavers for a longer duration. Formaldehyde is the primary component of embalming fluid due to its strong antimicrobial properties, easy availability, and

affordability. However, it is not an ideal fluid because of its irritating odor and known health hazards. It also causes blackish discoloration of the visceral organs. Therefore, replacing or modifying formaldehyde is necessary. Glutaraldehyde is also a well-known antimicrobial agent commonly used in hospitals. Only a few studies are available on the use of glutaraldehyde for surgical skill training. It produces less irritating odor than formaldehyde, but it is more expensive compared to formaldehyde. SSS is also studied for surgical skill training. Different authors added varying amounts of NaCl to make SSS, so there is no standardized data available for SSS, but this solution is cost-effective and non-irritant.

This study compared four different embalming solutions. The formaldehyde group consists of a low concentration of formaldehyde (Group A), along with Glutaraldehyde (Group B), and the Group C SSS group. Six hundred grams of salt was added to three liters of solution. Glutaraldehyde with salt (Group D) is a new embalming solution studied to observe the effect of adding salt to glutaraldehyde. Glutaraldehyde and SSS have been studied primarily by various authors for surgical skill training, but in this study, these groups were compared at low formaldehyde levels to assess their effects when used as embalming solutions.

In this study, the formaldehyde and glutaraldehyde groups had an irritant smell, while the SSS did not, whereas glutaraldehyde combined with salt was less irritating than formaldehyde and glutaraldehyde odors throughout the study.

Initially, the external appearance of the skin, fascia, and visceral organs of embalmed rats appears life-like in the Formaldehyde, Glutaraldehyde, and SSS groups, but Glutaraldehyde with salt solution shows a mildly to moderately distorted appearance of the skin, fascia, and visceral organs. After 1 week, the Formaldehyde group shows a mild change in the color of the skin, fascia, and visceral organs, but later, after 16 weeks, it changes to a blackish discoloration. A similar result was found in Gosmoji. ij et al study. (3,4,5)

Pio Renator F. Villacorta et al. obtained similar results with a formaldehyde-embalmed cadaver that had a foul odor and dark brown organs and muscles. (7) In this study, the formaldehyde group does not show any microbial growth throughout the study. Similar results were observed in Ria Margiana's findings, indicating that low formaldehyde also provides effective antimicrobial protection.(7,8)

The glutaraldehyde group showed a natural-life appearance of skin, fascia & visceral organs throughout 16 weeks, with no microbial growth observed during the study. It also showed greater flexibility than formaldehyde and glutaraldehyde in a salt solution. A similar result was found in Dr. Natekar's study, which showed that a glutaraldehyde solution can preserve a cadaver for up to 5 years without fungal infection and with good flexibility.(9)

Navbir Paricha et al. obtain a similar result when cadavers embalmed with glutaraldehyde have no pungent smell and exhibit good flexibility and antimicrobial protection.(5)(13)

SSS shows a non-irritant, small, lifelike appearance of skin, fascia, and all visceral organs. It also preserved the pancreas throughout 16 weeks. Meanwhile, other embalming groups show a distorted appearance of the pancreas. It exhibits a greater range of motion compared to other groups.

Hayashi et al. found that SSS and formaldehyde offer effective antibiotic protection. SSS demonstrates greater flexibility, effective antibiotic protection, and better visual assessment compared to formaldehyde.(10)

Je-Sung Moon et al. get similar results for saturated salt solution, which shows good skin elasticity and a lifelike appearance of visceral organs, with more flexibility than formaldehyde solution.(11)

Mani Kathapill et al studied MSSS, which had a non-irritating smell, improved skin incision, and good flexibility(12).

When salt is added to formaldehyde, its properties change, and the fluid shifts from an inorganic to an organic solution. Adding salt to the formaldehyde solution makes the smell non-irritating, preventing mucosal irritation. Sung Min Nam, Saturated salt solution, and Thiel demonstrate a more lifelike appearance in terms of color, texture, and joint flexibility compared to formaldehyde solution with no irritant smell. However, this solution still shows microbial contamination after 1 month, while formaldehyde did not display any microbial growth contamination.

Glutaraldehyde with salt was used as a new embalming agent in this study, but embalmed rats with this solution showed a distorted appearance of skin & visceral organs with the presence of microbial growth after 8th week of embalming. Adding salt to glutaraldehyde only reduces the irritating smell in that fluid, but it can not preserve the organs for a longer duration

Conclusion:

This study concludes that saturated salt solution and glutaraldehyde prevent microbial growth in visceral organs for a longer period; therefore, both can be used as embalming solutions instead of formalin. However, SSS is non-irritant and more cost-effective compared to the glutaraldehyde solution.

Conflict of interest: No conflict of interest

References

1. Brenner E. Human body preservation – old and new techniques. *Journal of Anatomy*. 2014 Mar;224(3):316–44. doi:10.1111/joa.12160
2. uJAWALA BHARANKAR amIT KP. [eMBALMING BENEFIT & PITFALL]. SIJAP.

A Comparative Evaluation of Modified Saturated Salt Solution Versus Salt-Added in Glutaraldehyde Solution used as an Embalming Solution, on Wistar Rats for Anatomical Education, A Morphological Study.”

3. Ij G, Jo O, Sa H, N W, Ia A. Saturated salt solution an alternative reagent in reducing formaldehyde concentration in embalming. *MOJAP*. 2018 Jun 5;5(3):205–7. doi:10.15406/mojap.2018.05.00192
4. Durongphan A, Chongkolwatana W, Ngamskulrungrroj P, Pochnasomboon T, Pinkaew J, Pamornpol B, et al. A Pilot Comparative Study of Submerge vs. Non-Submerge Saturated Salt Solution Human Cadavers Embalming Method by Gross, Histological, and Microbiological Evaluation. *Sriraj Med J*. 2022 Jul 1;74(7):431–9. doi:10.33192/Smj.2022.52
5. Pasricha N, Sthapak E, Bhatnagar R, Siddiqui M, Jaiswal S. Soft-fixed embalming: Our experiences. *Natl J Clin Anat*. 2020;9(2):43. doi:10.4103/NJCA.NJCA_2_20
6. Department of Anesthesia, M.M.I.M.S.R, Mullana, Ambala, Haryana, India, Singh S, Jeet K, Bareja R, Grover PS, Mishra V, et al. In-use tests for detection of microbial contamination in hospital disinfectants and antiseptics. *IOSRJDMS*. 2014;13(11):85–9. doi:10.9790/0853-131168589
7. Al Aiyan A, Barigye R, Mohamed M, Menon P, Hammoud M, Richardson K. Microbial Status of Animal Anatomical Cadavers Fixed Using Low Formaldehyde Concentrations. *Journal of Veterinary Anatomy*. 2018 Oct 1;11(2):1–16. doi:10.21608/jva.2018.44907
8. Margiana R. Is There Macroscopic Different appearance in using formalin with Low and High Concentration in technic of cadaver embalming?
9. Natekar PE, Desouza FM. A New Embalming Fluid for Preserving Cadavers. Vol. 1. 2012;1(2).
10. Hayashi S, Homma H, Naito M, Oda J, Nishiyama T, Kawamoto A, et al. Saturated Salt Solution Method: A Useful Cadaver Embalming for Surgical Skills Training. *Medicine*. 2014 Dec;93(27):e196. doi:10.1097/MD.0000000000000196
11. Moon JS, Nam SM, Nahm SS, Yoon HY. Usefulness of cadaver embalming solutions as alternatives to formalin in veterinary surgical training. *The Thai Journal of Veterinary Medicine*. 2020 Dec 1;50(4):519–28. doi:10.56808/2985-1130.3057
12. Kathapillai M. Modified saturated salt solution (MSSS) method for embalming. *IJCAP*. 2019 Oct 28;6(3):260–3. doi:10.18231/j.ijcap.2019.058
13. Padmini Shinde. Mini Mol . Comparative Evaluation of Effectiveness of Glutaraldehyde and partial Formaldehyde , Replacement with 2% phenoxyethanol, vinegar as an Alternate Non - Formaldehyde Embalming Agents in Wistar Rats;A morphological & histological Assesment. *IJCHR*. vol15(2025).doi:10.52783/jchr.v

15.i6.10651