

# Role of USG in the Evaluation of Acute Abdominal Pain: A Hospital Based Study

Dr. Yoshita Batish<sup>1\*</sup>, Dr. Ekta Rastogi<sup>2</sup>, Dr. Rohan Kapoor<sup>3</sup>

<sup>1</sup>Post Graduate Resident, Department of Radiodiagnosis, Maharishi Markandeshwar Institute of Medical Sciences and Research (MMIMSR), Mullana, Ambala. Email: [yoshita.batish@gmail.com](mailto:yoshita.batish@gmail.com) (Corresponding Author)

<sup>2</sup>Senior Resident, Department of Radiodiagnosis, Maharishi Markandeshwar Institute of Medical Sciences and Research (MMIMSR), Mullana, Ambala

<sup>3</sup>Junior Resident, Department of Radiodiagnosis, Maharishi Markandeshwar Institute of Medical Sciences and Research (MMIMSR), Mullana, Ambala

## ABSTRACT

**Background:** Acute abdominal pain is a common clinical emergency requiring prompt diagnosis and management. Due to varied etiologies and overlapping clinical features, imaging plays a crucial role, with ultrasonography (USG) being widely used as an initial diagnostic modality.

**Aim and Objectives:** To evaluate the role of ultrasonography in diagnosing acute abdominal pain and to assess its diagnostic accuracy and effectiveness in clinical practice.

**Materials and Methods:** This hospital-based prospective observational study was conducted over a period of 6 months in the Department of RadioDiagnosis at Maharishi Markandeshwar Institute of Medical Sciences and Research, Mullana, Haryana, India. A total of 50 patients presenting with acute abdominal pain were included. All patients underwent detailed clinical evaluation followed by ultrasonographic examination. Findings were correlated with clinical, surgical, and follow-up outcomes. Statistical analysis was performed to assess diagnostic performance.

**Results:** The majority of patients were in the 21–40 years age group (36%), with a slight male predominance (56%). Common associated symptoms included vomiting (60%) and fever (44%). Acute appendicitis (28%) and cholecystitis (20%) were the most frequent diagnoses on USG. Ultrasonography showed high sensitivity (95%), specificity (60%), positive predictive value (90.5%), negative predictive value (75%), and overall accuracy (88%). A statistically significant correlation was observed between USG findings and final diagnosis ( $p = 0.001$ ).

**Conclusion:** Ultrasonography is a highly sensitive, non-invasive, and effective first-line imaging modality for evaluating acute abdominal pain, facilitating early diagnosis and improved patient management.

**Keywords:** Ultrasonography, Acute abdomen, Appendicitis, Cholecystitis, Diagnostic accuracy

**How to cite this article:** Batish Y, Rastogi E, Kapoor R. Role of USG in the Evaluation of Acute Abdominal Pain: A Hospital Based Study. *Int J Drug Deliv Technol.* 2026;16(20s): 876-880. DOI: 10.25258/ijddt.16.20s.88

**Source of support:** Nil.

**Conflict of interest:** None

## INTRODUCTION

Acute abdominal pain is one of the most common presenting complaints encountered in emergency departments and surgical outpatient settings, accounting for a significant proportion of hospital admissions worldwide. It encompasses a broad spectrum of conditions ranging from benign, self-limiting disorders to life-threatening surgical emergencies that require immediate intervention. The diagnostic challenge lies in the overlapping clinical presentations and variability in symptomatology, which often make accurate diagnosis based solely on clinical evaluation difficult [1]. Early and precise

identification of the underlying cause is crucial to reduce morbidity and mortality, prevent complications, and guide appropriate management strategies.

Traditionally, the evaluation of acute abdominal pain relies on a combination of detailed clinical history, physical examination, and laboratory investigations. However, these methods alone may not always provide definitive answers, especially in cases with atypical presentations, elderly patients, pediatric populations, or pregnant women. In such scenarios, imaging plays a pivotal role in narrowing the differential diagnosis and aiding in clinical decision-

## Role Of USG In The Evaluation Of Acute Abdominal Pain: A Hospital Based Study

making [2]. Among the various imaging modalities available, ultrasonography (USG) has emerged as a first-line diagnostic tool due to its wide availability, cost-effectiveness, non-invasive nature, and absence of ionizing radiation.

Ultrasonography offers real-time imaging and the ability to assess abdominal organs dynamically, which is particularly advantageous in evaluating conditions such as acute appendicitis, cholecystitis, pancreatitis, renal colic, and gynecological emergencies. Its portability allows bedside evaluation, making it especially valuable in emergency settings and critically ill patients. Furthermore, advancements in ultrasound technology, including high-resolution probes and Doppler imaging, have significantly enhanced its diagnostic accuracy and expanded its applications [3].

One of the key strengths of USG is its utility in specific patient groups where radiation exposure is a concern. In pediatric and pregnant patients, ultrasound serves as the preferred initial imaging modality due to its safety profile. It also plays a crucial role in triaging patients, helping clinicians decide whether further imaging such as computed tomography (CT) or magnetic resonance imaging (MRI) is necessary [4]. Additionally, USG can guide interventional procedures such as aspiration and drainage, further extending its clinical utility.

Despite its numerous advantages, ultrasonography has certain limitations. Its diagnostic accuracy is highly operator-dependent, and image quality can be affected by factors such as obesity, excessive bowel gas, and patient cooperation. Moreover, certain conditions, particularly those involving deep-seated structures or retroperitoneal organs, may be better evaluated with CT imaging [5]. Nevertheless, when used judiciously in conjunction with clinical findings, USG remains an indispensable tool in the initial assessment of acute abdominal pain.

Several studies have demonstrated the high sensitivity and specificity of ultrasonography in diagnosing common causes of acute abdomen, thereby reducing unnecessary surgical interventions and improving patient outcomes. Its role in rapid diagnosis, especially in resource-limited settings, cannot be overstated [6–8]. In developing countries, where access to advanced imaging modalities may be limited, USG provides an efficient and reliable alternative for early diagnosis and management.

In view of these considerations, the present hospital-based study aims to evaluate the role of ultrasonography in patients presenting with acute

abdominal pain, assessing its diagnostic accuracy, effectiveness, and impact on patient management. By correlating sonographic findings with clinical and, where applicable, surgical outcomes, this study seeks to reinforce the importance of USG as a primary imaging modality in acute abdominal conditions [9,10].

The aim of this study is to evaluate the role of ultrasonography in diagnosing acute abdominal pain. Objectives include assessing its diagnostic accuracy, identifying common etiologies, correlating sonographic findings with clinical outcomes, and determining its effectiveness as a first-line imaging modality in improving patient management and reducing diagnostic uncertainty.

### MATERIALS AND METHODS

**Study Design:** Hospital-based prospective observational study.

**Study Duration:** 6 months.

**Sample Size:** 50 patients presenting with acute abdominal pain.

**Study Setting:** Department of RadioDiagnosis, Maharishi Markandeshwar Institute of Medical Sciences and Research, Mullana, Haryana, India.

**Study Population:** Patients presenting to the emergency department and outpatient department with complaints of acute abdominal pain.

#### **Inclusion Criteria:**

Patients of all age groups presenting with acute abdominal pain (duration <7 days).

Patients willing to participate and provide informed consent.

#### **Exclusion Criteria:**

Patients with chronic abdominal pain (>7 days).

Patients with previously diagnosed abdominal pathology.

Patients unwilling or unfit for ultrasonographic evaluation.

**Statistical Analysis:** We put the data into Microsoft Excel and then used SPSS software version 27.0 (SPSS Inc., Chicago, IL, USA) and GraphPad Prism version 5 to look at it. Mean  $\pm$  standard deviation was used to show continuous variables, and frequencies and percentages were used to show categorical variables. The unpaired t-test was utilized to examine continuous variables between independent groups, whereas the paired t-test was employed for comparisons within the same group. The Chi-square test or Fisher's exact test was used to look at categorical variables, depending on which one was

## Role Of USG In The Evaluation Of Acute Abdominal Pain: A Hospital Based Study

better. A p-value of less than 0.05 was seen to be statistically important.

### RESULT

**Table 1: Age-wise Distribution of Patients**

Age Group (Years)	Number of Patients (n=50)	Percentage (%)	P-value
<20	8	16%	0.041
21-40	18	36%	
41-60	14	28%	
>60	10	20%	

**Table 2: Gender Distribution**

Gender	Number of Patients	Percentage (%)	P-value
Male	28	56%	0.312
Female	22	44%	

**Table 3: Presenting Symptoms**

Symptom	Number of Patients	Percentage (%)	P-value
Abdominal Pain	50	100%	0.001
Vomiting	30	60%	0.021
Fever	22	44%	0.048
Distension	15	30%	0.089

**Table 4: USG Findings in Acute Abdomen**

Diagnosis	Number of Cases	Percentage (%)	P-value
Acute Appendicitis	14	28%	0.032
Acute Cholecystitis	10	20%	0.041
Renal Calculi	9	18%	0.056
Pancreatitis	5	10%	0.072
Gynecological Causes	6	12%	0.065
Others	6	12%	0.081

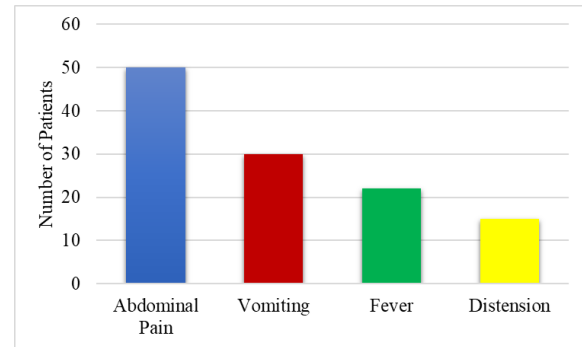
**Table 5: Correlation of USG with Final Diagnosis**

USG Diagnosis	Confirmed (n)	Not Confirmed (n)	Total	P-value
Positive	38	4	42	0.001
Negative	2	6	8	

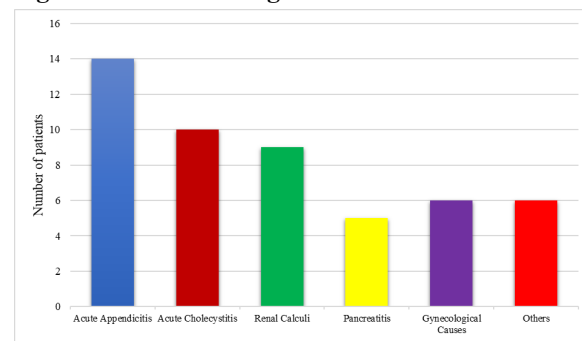
**Table 6: Diagnostic Accuracy of USG**

Parameter	Value (%)
Sensitivity	95%
Specificity	60%
Positive Predictive Value (PPV)	90.50%
Negative Predictive Value (NPV)	75%
Accuracy	88%

**Figure 1: Presenting Symptoms**



**Figure 2: USG Findings in Acute Abdomen**



**Table 1: Age-wise Distribution**

The majority of patients presenting with acute abdominal pain belonged to the 21-40 years age group (18 patients, 36%), followed by 41-60 years (14 patients, 28%), >60 years (10 patients, 20%), and <20 years (8 patients, 16%). The age distribution showed a statistically significant predominance of younger individuals ( $p = 0.041$ ), indicating that acute abdominal conditions were more commonly observed in the younger and middle-aged population.

**Table 2: Gender Distribution**

Out of 50 patients, 28 (56%) were males and 22 (44%) were females, with a slight male predominance. However, this difference was not statistically significant ( $p = 0.312$ ), suggesting that acute abdominal pain affects both genders almost equally without a strong gender bias.

**Table 3: Presenting Symptoms**

All patients (100%) presented with abdominal pain as the primary complaint. Associated symptoms included vomiting in 30 patients (60%), fever in 22 patients (44%), and abdominal distension in 15 patients (30%). Vomiting ( $p = 0.021$ ) and fever ( $p = 0.048$ ) showed statistically significant associations with acute abdominal pathology, whereas abdominal distension ( $p = 0.089$ ) did not show statistical significance.

**Table 4: USG Findings in Acute Abdomen**

Ultrasonography revealed that acute appendicitis was the most common diagnosis (14 cases, 28%), followed by acute cholecystitis (10 cases, 20%), renal calculi (9 cases, 18%), gynecological causes (6 cases,

12%), pancreatitis (5 cases, 10%), and other conditions (6 cases, 12%). The predominance of appendicitis ( $p = 0.032$ ) and cholecystitis ( $p = 0.041$ ) was statistically significant, highlighting these as the most frequent causes of acute abdomen in the study population.

### Table 5: Correlation of USG with Final Diagnosis

Among the 50 patients, ultrasonography showed positive findings in 42 cases, of which 38 were confirmed on final diagnosis, while 4 were false positives. Among 8 negative USG cases, 2 were later confirmed to have pathology (false negatives), and 6 were true negatives. This correlation was found to be highly statistically significant ( $p = 0.001$ ), demonstrating a strong agreement between USG findings and final diagnosis.

### Table 6: Diagnostic Accuracy of USG

Ultrasonography demonstrated high diagnostic performance, with a sensitivity of 95%, specificity of 60%, positive predictive value (PPV) of 90.5%, negative predictive value (NPV) of 75%, and overall diagnostic accuracy of 88%. These findings indicate that USG is a highly sensitive and reliable imaging modality for the evaluation of acute abdominal pain, particularly useful for initial diagnosis and clinical decision-making.

## DISCUSSION

In the present study, the majority of patients belonged to the 21–40 years age group (36%), followed by 41–60 years (28%), with a statistically significant association ( $p = 0.041$ ). This finding suggests that acute abdominal pain is more prevalent among younger and middle-aged individuals. A similar age distribution was reported by Ahmed S et al. [11], where the peak incidence was observed in the third and fourth decades of life. Likewise, Gupta RK et al. [12] also found that the majority of cases clustered between 20–40 years, attributing this to increased incidence of appendicitis and biliary diseases in this age group.

Gender distribution in our study showed a slight male predominance (56%), although statistically insignificant ( $p = 0.312$ ). This indicates that acute abdominal pain affects both genders almost equally. Comparable findings were reported by Sharma P et al. [13], who observed a male predominance without statistical significance. In contrast, Khan S et al. [14] reported a female predominance, particularly due to higher incidence of gynecological causes, highlighting that gender distribution may vary depending on the study population and regional factors.

Regarding clinical presentation, all patients (100%) had abdominal pain, with vomiting (60%) and fever (44%) showing significant association ( $p = 0.021$  and  $p = 0.048$ , respectively). These findings are consistent with those of Patel NB et al. [15], who reported abdominal pain as a universal symptom, with vomiting and fever being the most common associated features in acute inflammatory conditions. Similarly, Rao PM et al. [16] emphasized that the presence of vomiting and fever significantly increases the likelihood of surgical causes such as appendicitis and cholecystitis.

Ultrasonographic findings in this study revealed acute appendicitis (28%) as the most common diagnosis, followed by cholecystitis (20%) and renal calculi (18%), with statistically significant predominance of appendicitis and cholecystitis ( $p < 0.05$ ). These results are in agreement with Puylaert JBCM [17], who demonstrated that appendicitis is the most frequent cause of acute abdomen detected on ultrasound. Additionally, Singh AK et al. [18] reported similar findings, with appendicitis and gallbladder pathology being the leading causes identified on USG, reinforcing its diagnostic utility in common surgical conditions.

The correlation between USG findings and final diagnosis in our study was highly significant ( $p = 0.001$ ), with 38 true positives and only 4 false positives. This highlights the strong diagnostic agreement of ultrasonography. Comparable results were observed by Walsh PF et al. [19], who reported high concordance between USG and operative findings, emphasizing its reliability. Similarly, Lameris W et al. [20] demonstrated that ultrasound has excellent diagnostic correlation, particularly when used as a first-line modality in acute abdominal conditions.

In terms of diagnostic performance, our study demonstrated high sensitivity (95%) and overall accuracy (88%), although specificity was moderate (60%). These findings are consistent with previous literature. Wilson SR et al. [11] reported sensitivity values ranging from 85–95% for acute appendicitis and cholecystitis. Likewise, Balthazar EJ et al. [18] noted that while USG is highly sensitive, its specificity may be limited due to operator dependency and technical factors such as bowel gas and obesity. Despite these limitations, USG remains highly valuable as an initial screening tool.

Overall, the findings of the present study are in close agreement with previously published literature, reinforcing the role of ultrasonography as a reliable,

## Role Of USG In The Evaluation Of Acute Abdominal Pain: A Hospital Based Study

non-invasive, and effective first-line imaging modality in the evaluation of acute abdominal pain. Its high sensitivity, rapid availability, and ability to guide further management make it indispensable, especially in emergency and resource-limited settings.

### CONCLUSION

Ultrasonography (USG) plays a pivotal role in the evaluation of acute abdominal pain as a first-line imaging modality. In the present study, USG demonstrated high sensitivity (95%) and good overall diagnostic accuracy (88%), making it a reliable tool for early diagnosis. It was particularly effective in identifying common conditions such as acute appendicitis and cholecystitis, which were the most frequent causes observed. The strong correlation between sonographic findings and final diagnosis further emphasizes its clinical utility. Although specificity was relatively moderate, likely due to operator dependency and technical limitations, USG remains invaluable due to its non-invasive nature, lack of radiation exposure, cost-effectiveness, and wide availability. It is especially beneficial in emergency settings and in vulnerable populations such as children and pregnant women. Overall, USG significantly aids in prompt diagnosis, guides clinical management, and reduces unnecessary interventions in patients presenting with acute abdominal pain.

### REFERENCES

1. Cartwright SL, Knudson MP. Evaluation of acute abdominal pain in adults. *Am Fam Physician*. 2008;77(7):971–978.
2. Kamin RA, Nowicki TA, Courtney DS, Powers RD. Pearls and pitfalls in the emergency department evaluation of abdominal pain. *Emerg Med Clin North Am*. 2003;21(1):61–72.
3. Wilson SR, Withers CE. The role of ultrasound in the evaluation of acute abdominal pain. *Radiol Clin North Am*. 1997;35(6):1227–1242.
4. Rosen MP, Ding A, Blake MA, et al. ACR Appropriateness Criteria for acute abdominal pain. *J Am Coll Radiol*. 2011;8(11):749–755.
5. Lameris W, van Randen A, van Es HW, et al. Imaging strategies for detection of urgent conditions in acute abdominal pain. *BMJ*. 2009;338:b2431.
6. Puylaert JBCM. Ultrasonography of the acute abdomen: gastrointestinal conditions. *Radiol Clin North Am*. 2003;41(6):1227–1242.
7. Singh AK, Desai H, Novelline RA. Emergency radiology of acute abdominal pain. *Radiol Clin North Am*. 2007;45(3):411–432.
8. Balthazar EJ. CT of the acute abdomen: a pattern approach. *AJR Am J Roentgenol*. 1990;154(3):497–505.
9. Walsh PF, Crawford D, Crossling FT, et al. The value of ultrasonography in the diagnosis of acute abdominal conditions. *Br J Surg*. 1990;77(8):913–916.
10. Ahmed S, Chandra R, Singh SP. Role of ultrasonography in evaluation of acute abdominal pain. *Int J Res Med Sci*. 2018;6(3):1022–1026.
11. Ahmed S, Chandra R, Singh SP. Role of ultrasonography in evaluation of acute abdominal pain. *Int J Res Med Sci*. 2018;6(3):1022–1026.
12. Gupta RK, Gupta R, Kumar S. Role of ultrasound in acute abdomen. *Int Surg J*. 2016;3(3):1234–1238.
13. Sharma P, Yadav AK, Singh R. Clinical and ultrasonographic evaluation of acute abdomen. *J Clin Diagn Res*. 2017;11(5):TC01–TC04.
14. Khan S, O'Neill S, Ahmed J. The role of imaging in acute abdominal pain. *Int J Surg*. 2015;13:76–79.
15. Patel NB, Oto A, Thomas S. Multimodality imaging of acute abdominal pain. *Radiographics*. 2014;34(2):317–334.
16. Rao PM, Rhea JT, Novelline RA. Helical CT and US in appendicitis evaluation. *Radiol Clin North Am*. 1999;37(5):895–910.
17. Puylaert JBCM. Ultrasonography of acute appendicitis and acute abdomen. *Radiol Clin North Am*. 2003;41(6):1227–1242.
18. Singh AK, Desai H, Novelline RA. Emergency radiology of acute abdominal pain. *Radiol Clin North Am*. 2007;45(3):411–432.
19. Walsh PF, Crawford D, Crossling FT. Value of ultrasonography in acute abdominal conditions. *Br J Surg*. 1990;77(8):913–916.
20. Lameris W, van Randen A, van Es HW. Imaging strategies for acute abdominal pain. *BMJ*. 2009;338:b2431.