

Cystic Odontoma of the Anterior Maxilla in a 52-Year-Old Patient: A Rare Case Report and Diagnostic Conundrum

Dr. Samiran Ghosh ¹, Dr. Kaushik Dutta ², Dr. Shankhasweta Kundu ³, Dr. Debopriyo Chatterjee ⁴, Dr. Abhishek De Sarkar ⁵, Dr. Divya Pandya⁶,

¹DESIGNATION: Professor,

Department of Oral and Maxillofacial Surgery,

COLLEGE: Guru Nanak Institute of Dental Sciences and Research, 157/F Nilgunj Road, Panihati, Sodepur, Kolkata, West Bengal, Pin: 700114

MAIL ID: samiran.ghosh@gnidsr.ac.in

²DESIGNATION: Professor and Head of the Department,

Department of Oral Medicine and Radiology,

COLLEGE: Guru Nanak Institute of Dental Sciences and Research, 157/F Nilgunj Road, Panihati, Sodepur, Kolkata, West Bengal, Pin: 700114

MAIL ID: drkaushikduttaradiology@gmail.com

³DESIGNATION: 3RD YEAR, Post Graduate Trainee,

Department of Oral and Maxillofacial Surgery,

COLLEGE: Guru Nanak Institute of Dental Sciences and Research, 157/F Nilgunj Road, Panihati, Sodepur, Kolkata, West Bengal, Pin: 700114

MAIL ID: kundu.shankhasweta@gmail.com

⁴DESIGNATION: 2ND YEAR Post Graduate Trainee,

Department of Oral Medicine and Radiology,

COLLEGE: Guru Nanak Institute of Dental Sciences and Research, 157/F Nilgunj Road, Panihati, Sodepur, Kolkata, West Bengal, Pin: 700114

MAIL ID: dchatterji67@gmail.com

⁵DESIGNATION: Professor,

Department of Oral and Maxillofacial Surgery,

COLLEGE: Guru Nanak Institute of Dental Sciences and Research, 157/F Nilgunj Road, Panihati, Sodepur, Kolkata, West Bengal, Pin: 700114

MAIL ID: avishkeds@gmail.com

⁶DESIGNATION: Associate Professor,

Department of Oral Medicine and Radiology,

COLLEGE: Guru Nanak Institute of Dental Sciences and Research, 157/F Nilgunj Road, Panihati, Sodepur, Kolkata, West Bengal, Pin: 700114

MAIL ID: Divyapandya854@gmail.com

Corresponding author: Dr. Shankhasweta Kundu

3RD YEAR, Post Graduate Trainee,

Department of Oral and Maxillofacial Surgery,

Guru Nanak Institute of Dental Sciences and Research, 157/F Nilgunj Road, Panihati, Sodepur, Kolkata, West Bengal, Pin: 700114

MAIL ID: kundu.shankhasweta@gmail.com

ABSTRACT

Background:

Cystodontoma represents a rare odontogenic lesion where a cystic structure co-exists with an odontoma, accounting for less than one percent of all odontogenic tumours and diagnostic challenges arise due to its overlapping radiological and histopathological features with other mixed radiopaque-radiolucent jaw lesions. Early recognition is essential to prevent maxillary bony expansion, bone destruction, or secondary infection. A rare case of a 52-year-old male presenting with a painful palatal swelling extending across the midline, associated with a mixed radiopaque lesion in the anterior maxilla. Cone beam computed tomography (CBCT) showed well defined borders, cortical erosion and soft tissue extension. Provisional and differential diagnoses included complex odontoma, calcifying epithelial odontogenic tumour and adenomatoid odontogenic tumour. Histopathology confirmed a benign odontogenic neoplasm favouring cystic odontoma. The lesion was surgically excised en bloc and post operative healing was uneventful. This case reinforces the need for multimodal imaging, biopsy-based confirmation and complete surgical excision to avoid recurrence. Cystic odontome should be considered in the differential diagnosis of mixed radiopaque lesions of the anterior maxilla in adults.

Keywords: Anterior maxilla swelling; calcified lesion; CBCT; cystic odontome; case report; mixed radiopaque lesion

How to cite this article: Ghosh S, Dutta K, Kundu S, Chatterjee D, De Sarkar A, Pandya D. Cystic Odontoma of the Anterior Maxilla in a 52-Year-Old Patient: A Rare Case Report and Diagnostic Conundrum. *Int J Drug Deliv Technol.* 2026;16(21s): 1166-1175. DOI: 10.25258/ijddt.16.21s.120

Source of support: Nil.

Conflict of interest: None

INTRODUCTION

Odontomes constitute the most prevalent odontogenic tumours representing approximately 67% of reported cases.^[1] They are broadly divided into compound and complex types, with the WHO 2022 classification recognising them as hamartomatous malformations rather than true neoplasms.^[2] However cystic or hybrid odontomes represent a distinct and extremely uncommon presentation where the odontoma is associated with a cystic epithelial lining, creating a diagnostic overlap with several calcified odontogenic cysts and tumours.^[3]

The term cystodontoma was first introduced to describe odontomes associated with dentigerous or calcifying odontogenic cysts.^[4] Only a limited number of such cases have been documented in indexed literature, and most occur in younger individuals in the posterior mandible. Presentation in the anterior maxilla of an adult patient, as in the present case, is therefore unusual and noteworthy.

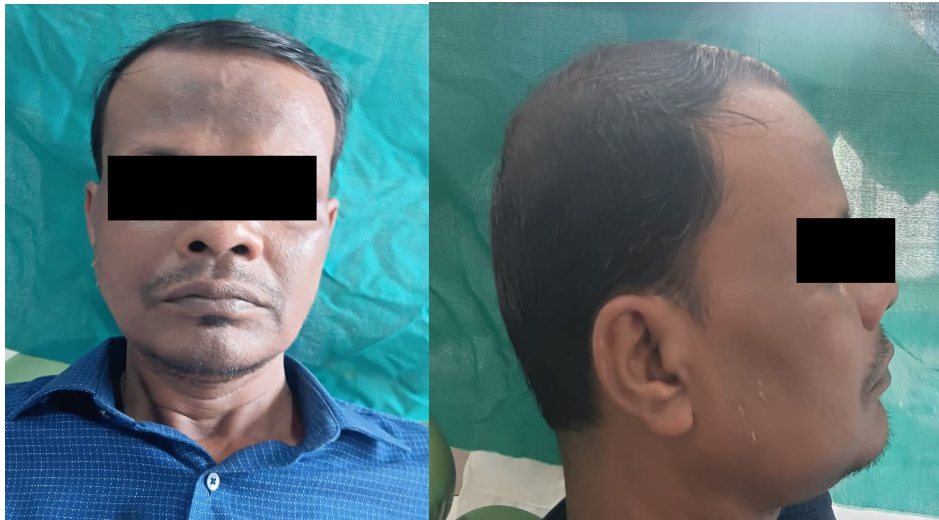Radiographically, cystic odontomes may appear as mixed radiolucent-radiopaque lesions with a surrounding

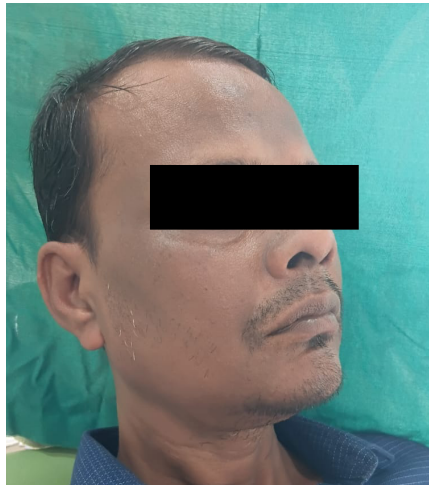corticated border. This pattern may mimic adenomatoid odontogenic tumour (AOT), calcifying epithelial odontogenic tumour (CEOT), calcifying odontogenic cyst (COC) and even ossifying fibroma.^[5] Therefore, histopathologic confirmation remains mandatory for accurate diagnosis.

This article presents a rare case of cystic odontome in the anterior maxilla of a 52-year-old male, followed by a discussion clinical behaviour, imaging features, pathology and treatment outcomes.

. CASE REPORT

A 52-year-old male presented to the Department of Oral Medicine and Radiology with a chief complaint of pain and swelling in the palate for one month. The pain was continuous, dull and localized to the left anterior palate. The patient reported gradual swelling in the region after one week, partially relieved with over-the-counter analgesics. (Figure 1)





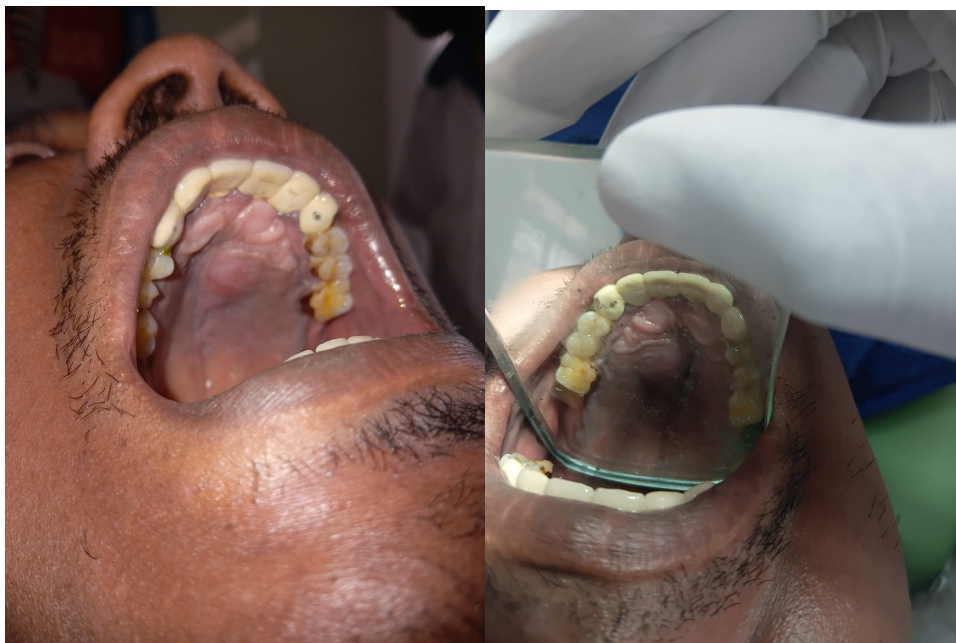1. CLINICAL IMAGES

The patient's medical history revealed controlled hypertension under medication and a chronic smoking habit of 30 cigarettes/day for past 10 years. No history of trauma, nasal obstruction, epistaxis or paraesthesia was reported.

Clinical Examination

Extraoral examination showed no visible facial asymmetry or tenderness over the maxilla or midface.

Intraoral examination revealed a well-defined swelling on the palatal surface extending from the left maxillary second premolar (25) anteriorly across the midline. (Figure 2)



2. CLINICAL PRESENTATION

The swelling measured 1cm x 1cm in dimensions. The overlying mucosa did not show any visible changes and no visible discharge. It was soft to firm in consistency, fluctuant and non-tender on palpation.

measuring 0.7 cm x 2.2 cm with a peripheral radiolucent border. The lesion displaced the nasal floor superiorly, with deviation of the septum toward the right. No root resorption or tooth displacement was observed. (Figure 3)

The patient also had a fixed prosthesis extending from maxillary right canine to left canine and from mandibular right to left canine. 27 was found to be a root stump.

Radiographic Examination

Orthopantomogram (OPG) showed a well-defined, mixed radiopaque lesion in the left anterior palate region

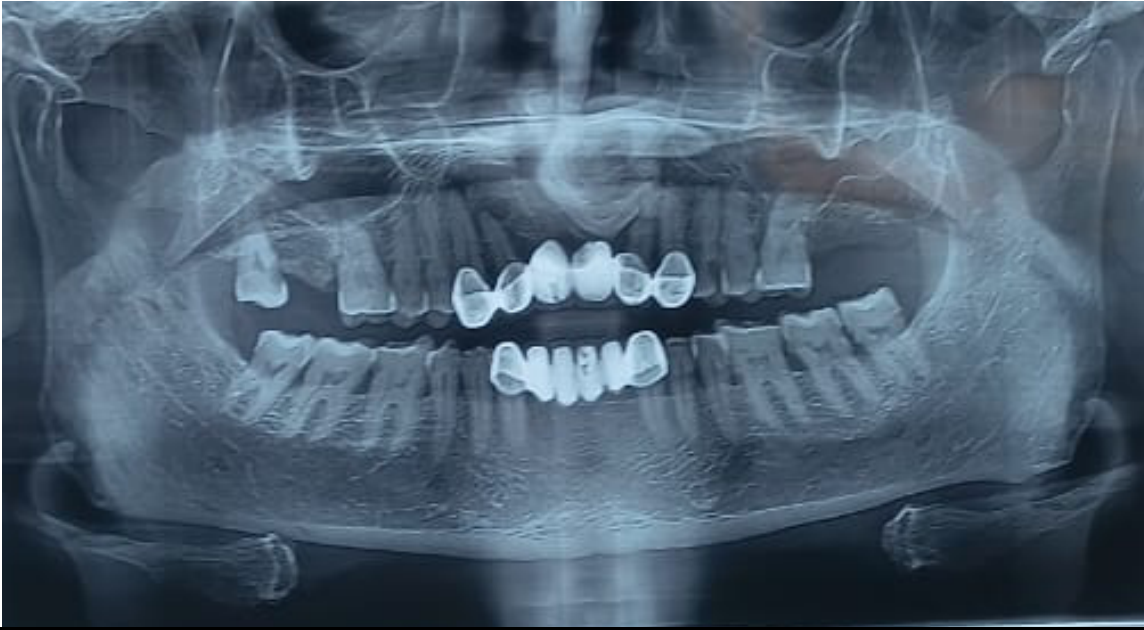

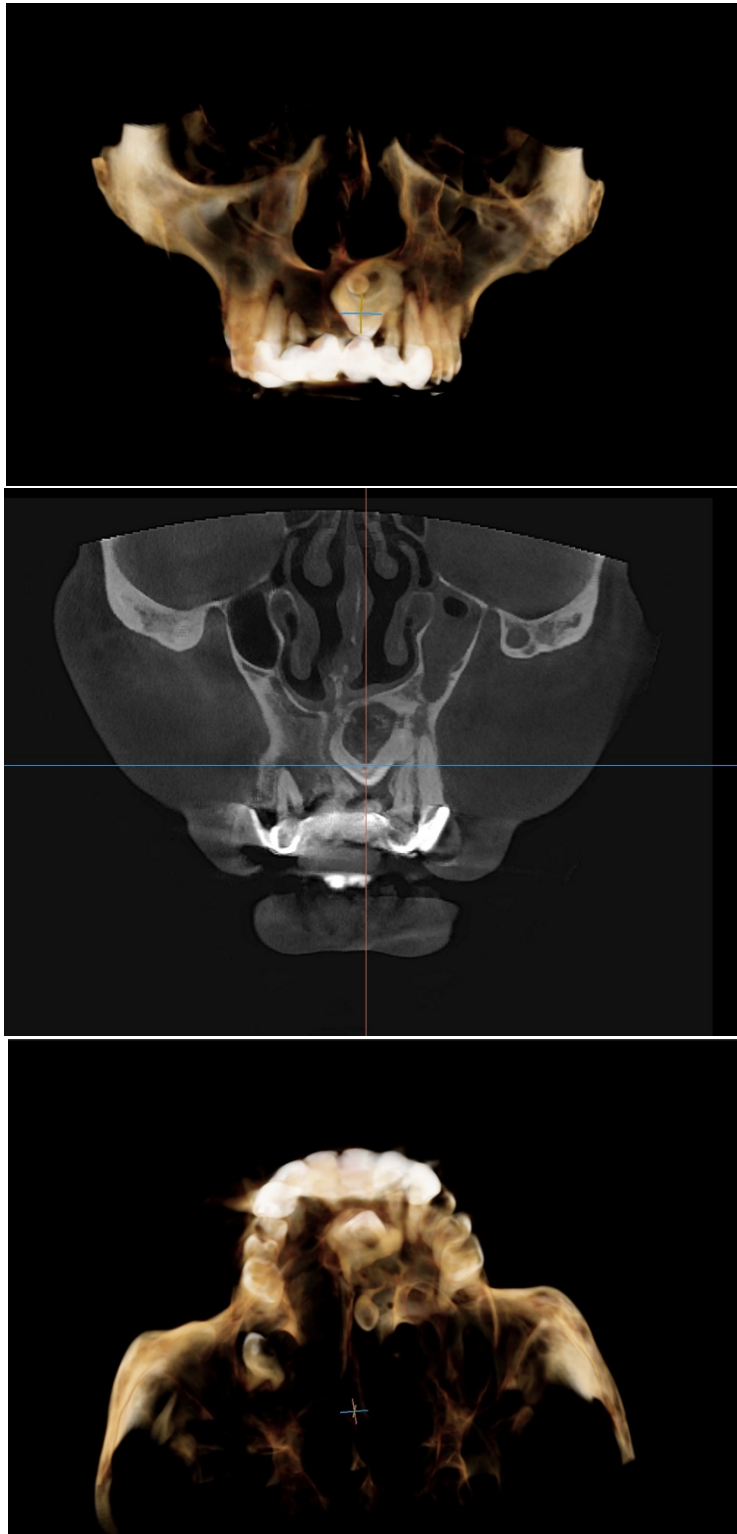
Figure 3- OPG showing mixed radiopaque lesion in anterior maxilla

Cone Beam Computed Tomography (CBCT) multiplanar reconstituted images (MPR) [axial, sagittal and coronal sections] with 3D reconstruction revealed an ill-defined mixed radiodensity space occupying lesion evident in maxillary left anterior region. Teeth involved are 21,22,23,24 in the periapical region with pathologic migration/displacement of 21,22.

Radiographic evidence of agglomerate radiopacity predominantly labially and surrounding homogenous

radiolucency measuring approximately 0.7 cm x 2.2cm x 1.7cm with complete destruction of palatal cortical plate with expansion and thinning and discontinuity of labial cortical plate. Elevation with thinning and suspected breach of floor of nasal fossa.

Radiographic evidence of a tooth like radiodensity at the periphery of the lesion placed palatally, conical crown-like structure of single tooth with evident enamel, dentin and pulp with crown placed palatally and horizontally. (Figure 4)



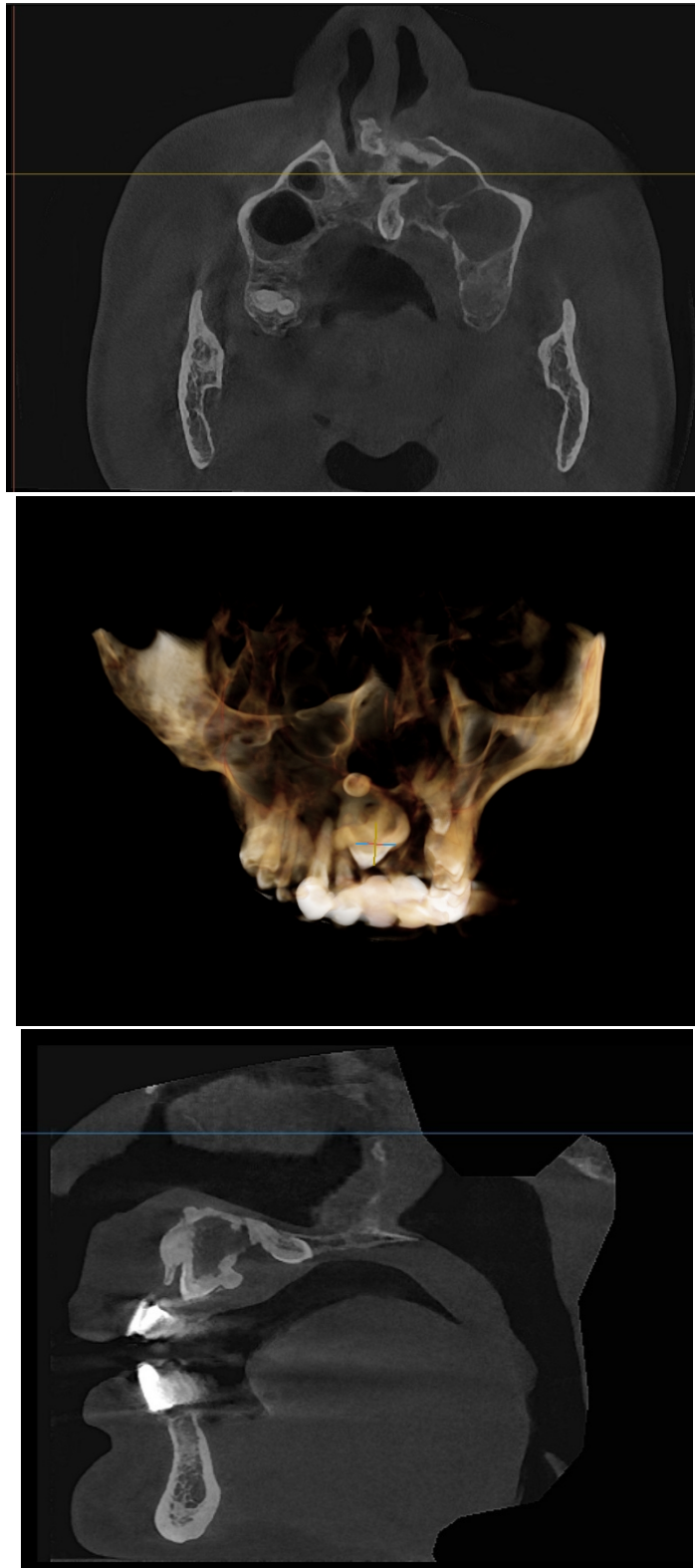


Figure 4. CBCT Coronal, Axial and Sagittal views showing cortical erosion

Differential Diagnosis

- Compound odontome
- Calcifying epithelial odontogenic tumour
- Adenomatoid odontogenic tumour
- Calcifying Odontogenic Cyst

Aspiration and Biopsy

Aspiration yielded thick, reddish, viscous fluid, indicating cystic contents. (Figure 5)

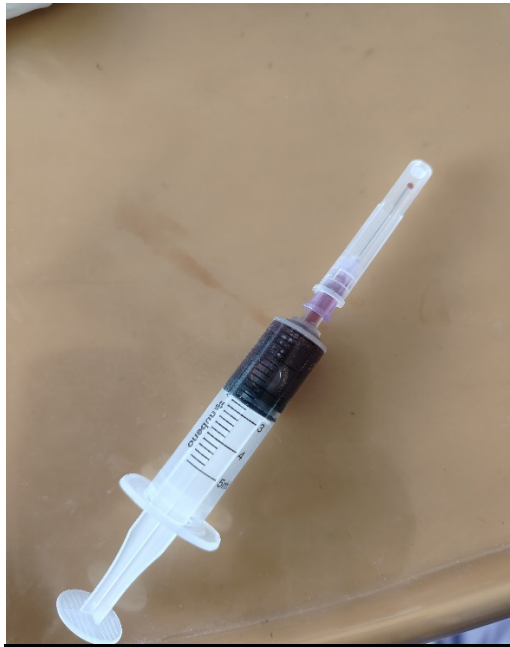

Figure 5- Aspirate sample obtained (reddish thick fluid)

An incisional biopsy was performed under local anaesthesia. Histopathology was suggestive of a benign odontogenic lesion with calcification. (Figure 6)

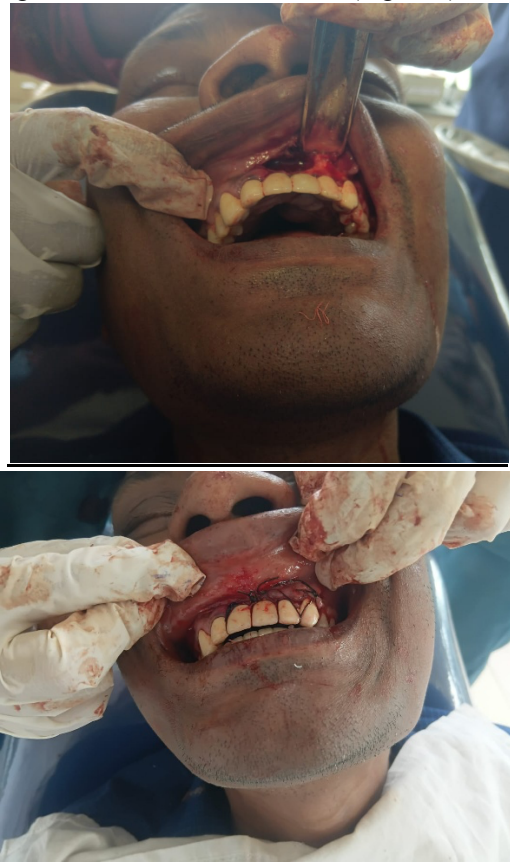

Figure 6- Incisional biopsy under local anaesthesia

Surgical Management

The lesion was surgically excised en bloc along with surrounding maxillary bone under general anaesthesia. (Figure 7) The specimen measured approximately 2.5 cm in diameter and showed multiple calcified masses within cystic tissue. (Figure 8)

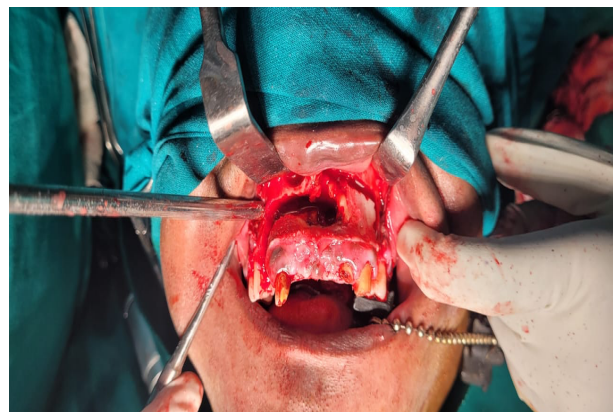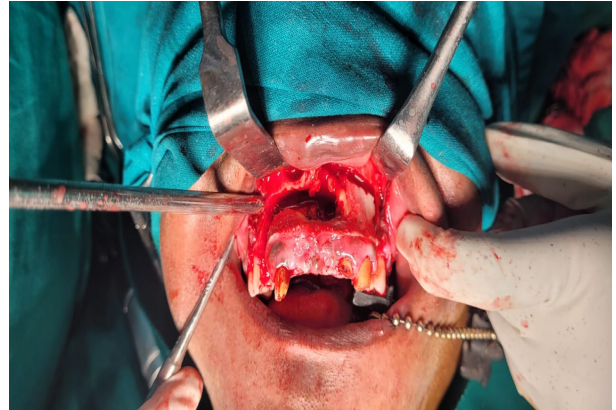


Figure 7- Surgical Excision

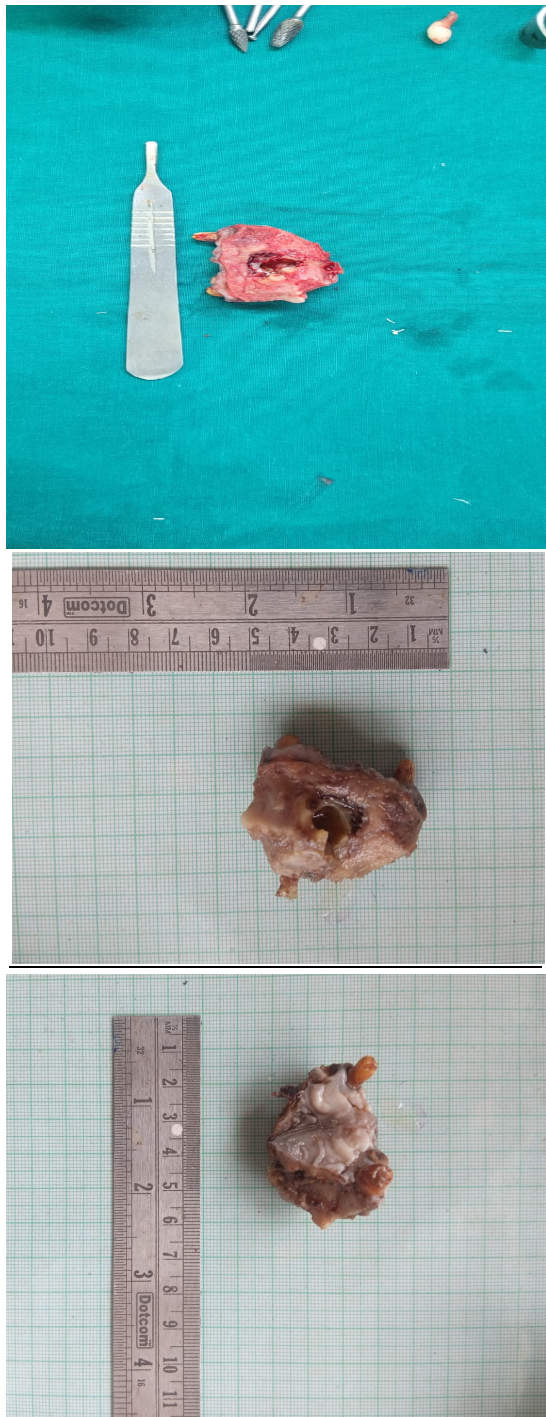


Figure 8- Excised Specimen with surrounding bone

An obturator prosthesis was fabricated to be used by for closure of the defect. Postoperative healing was uneventful and patient recovered without complications. (Figure 9)

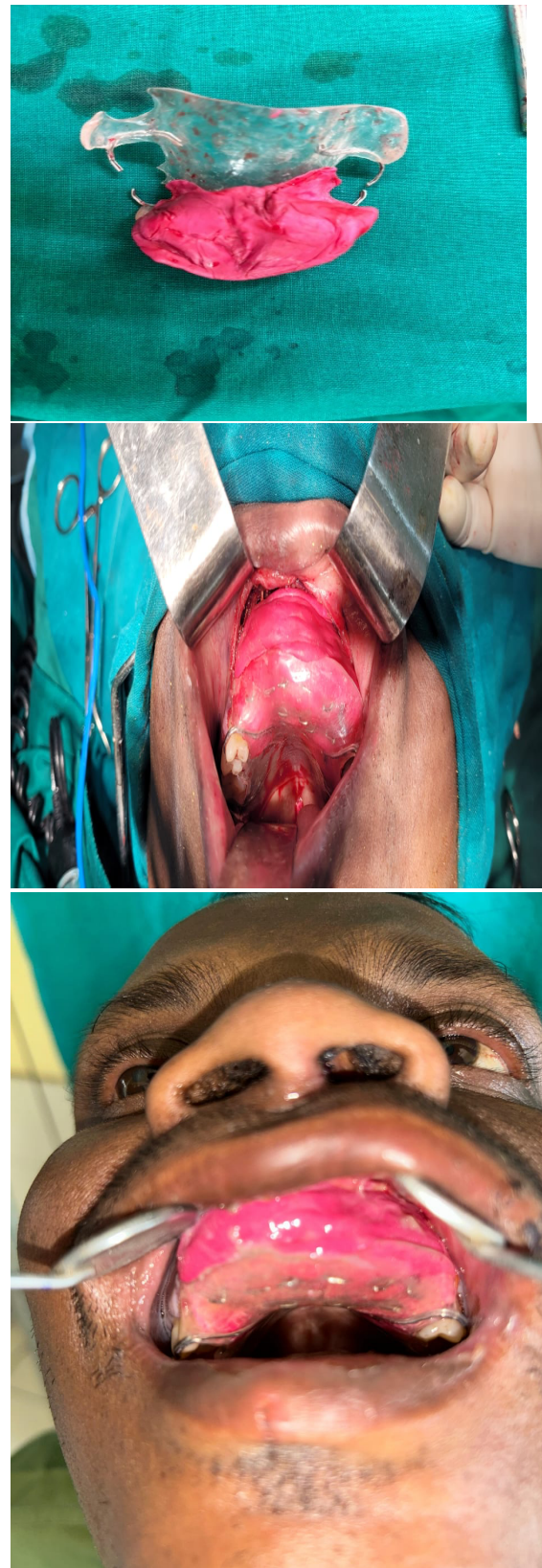


Figure 9- Post operative recovery and prosthetic rehabilitation

Microscopic Findings

Histopathological examination showed presence of parakeratinized stratified squamous epithelium with underlying stroma. The stroma was variably cellular relatively and homogenous and mildly basophilic calcified material enclosing hollow clefts was appreciated. Presence of discontinuous cystic lining of varying thickness backed by prominent fibro-collagenous stroma and non-specific chronic inflammatory cells infiltrate could be noted. Mature bony trabeculae with lacuna, osteocytes and connective tissue stroma were also present. (Figure 10)

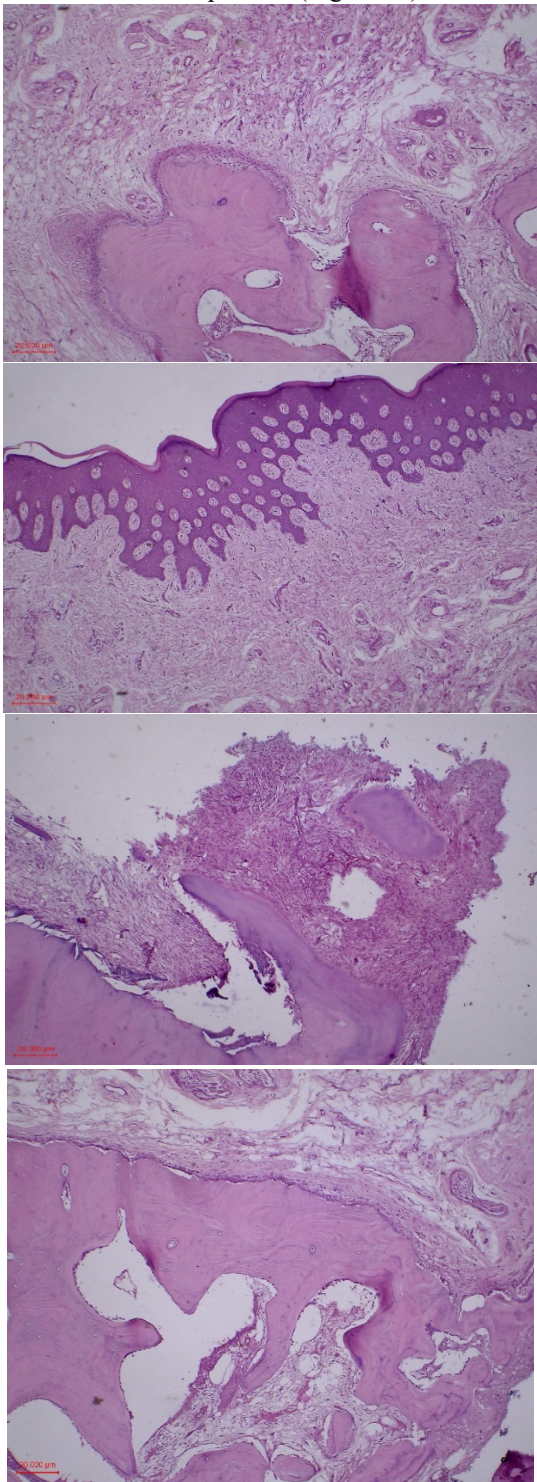


Figure 10- Histopathological Images

Final Diagnosis

Histopathological examination confirmed a benign odontogenic neoplasm consistent with Cystic Odontome (Cystodontoma).

DISCUSSION

Odontomes were first described by Broca in 1867 as developmental malformations rather than true neoplasms. Later, Gabell, James and Payne classified them into compound and complex types, a system still widely used. The term “cystic odontoma” or “cystodontoma” was introduced to describe odontomes associated with cystic degeneration or cystic epithelial lining, most commonly dentigerous cyst or calcifying odontogenic cyst. Less than 1% of odontomes demonstrate a cystic component, making them an uncommon odontogenic entity.

With the 2022 WHO classification of odontogenic tumours, cystic odontomes have been discussed under hybrid odontogenic lesions, since they exhibit features of both cyst and hamartoma/neoplasm.

Cystic Odontome represents an uncommon hybrid odontogenic lesion in which a developing or mature odontome is enclosed partially or completely within a cystic cavity. While odontomes themselves are well documented hamartomatous formations, their cystic transformation is rare and has been reported in <1% of odontogenic tumours. [1-3] The present case contributes to this limited pool of literature and displays several unique features: occurrence in a 52-year-old male, anterior maxillary localization and cortical erosion with soft tissue extension, which are not frequently observed in published reports.

Anterior maxillary mixed radiopaque-radiolucent lesions encompass a wide spectrum, including complex odontome, calcifying odontogenic cyst (COC), adenomatoid odontogenic tumour (AOT), Calcifying Epithelial Odontogenic Tumour (CEOT), ossifying fibroma and cemento-ossifying dysplasia. Radiographically cystic odontoma may closely resemble AOT or COC when a unilocular radiolucency surrounds radiopaque foci. [4,5]

In this case, OPG revealed an ill-defined lesion with internal calcifications and a surrounding halo while CBCT demonstrated cortical expansion and erosion-features suggestive of a lesion more aggressive than hamartomatous odontome alone. CBCT has been consistently reported as the most valuable modality for assessing odontogenic lesions where cortical perforation and three-dimensional architecture must be evaluated.

Most published cases occur in the first and second decades of life, attributed to lesion development during odontogenesis. [8,9] However the current patient presented in his sixth decade, consistent with a slowly developing lesion that underwent late-stage cystic degeneration.

Similarly, Odontomes show a predilection for the anterior maxilla (compound) and posterior mandible (complex). Cystic odontomes however are more frequently reported in the posterior mandible. [10] The present lesion was unusual both in age of detection and location.

Histologically, cystic odontoma can be segregated into two forms:

Odontome with secondary cystic change- cyst is reactionary.

Cyst with odontoma like tissue embedded in wall- Odontome is incidental

The current case featured a cystic lumen lined by odontogenic epithelium with odontome like calcified tissue islands, aligning with the first type. These features help distinguish it from:

COC- Characteristic ghost cells and dentinoid material

CEOT- presence of amyloid and Liesegang rings

AOT- duct like epithelial rosettes

Histopathology therefore remains the gold standard for definitive diagnosis, even when CBCT findings are suggestive.

Complete surgical excision is the treatment of choice. Enucleation is sufficient for lesions confined within the bone, whereas an en bloc excision is advised for lesions with cortical perforation or labial/palatal extension.^[11] No recurrence has been reported when excision margins are adequate.

There is no role for radiotherapy or chemotherapy, as the lesion is benign and exhibits no malignant potential. Long term follow-up has been recommended, as recurrence has been sparsely reported in incompletely removed cases.

CONCLUSION

Given its rarity and overlapping clinical and radiographic appearance with mixed radiopaque lesions such as calcifying odontogenic cyst, adenomatoid odontogenic tumour and calcifying epithelial odontogenic tumour, cystodontoma should be carefully distinguished through combined imaging and histopathologic assessment. The present case is notable due to its occurrence in an older adult, anterior maxillary location and evidence of cortical erosion, all of which are atypical for conventional odontoma presentation.

This report emphasizes three key diagnostic principles:

Multimodal imaging is essential- CBCT provides superior evaluation of lesion borders, cortical perforation and spatial extension.

Aspiration and biopsy are mandatory when radiographic features are non-specific

Histopathology remains the gold standard, particularly for differentiating hybrid or cystic odontogenic lesions

Complete surgical excision is curative and recurrence is rare when adequate margins are achieved. Awareness of this rare lesion allows clinicians to consider cystic odontome in the

differential diagnosis of anterior maxillary mixed lesions in adults and to pursue early biopsy than to assume benign hamartoma.

REFERENCE

1. Philipsen HP, Reichart PA. Odontomas: a clinicopathologic review. *Oral Oncol.* 2002;38(8):707-20. doi:10.1016/S1368-8375(02)00032-9
2. Wright JM, Vered M. Update from the 2022 WHO Classification of Head and Neck Tumours: Odontogenic and Maxillofacial Bone Tumours. *Head Neck Pathol.* 2022;16(1):63-75. doi:10.1007/s12105-021-01414-3
3. Sprawson E. Odontomes: classification and pathogenesis. *Br Dent J.* 1937;62:225-34.
4. Junquera L, de Vicente JC, Roig P, Olay S, Rodríguez-Recio O. Intraosseous odontoma erupted into the oral cavity: an unusual pathology. *Med Oral Patol Oral Cir Bucal.* 2005;10(3):248-51.
5. Neville BW, Damm DD, Allen CM, Chi AC. *Oral and Maxillofacial Pathology.* 4th ed. Elsevier; 2015.
6. Arjona-Amo M, Serrera-Figallo MA, Hernández-Guisado JM, Torres-Lagares D. Odontoma: A clinical study of 102 cases. *Med Oral Patol Oral Cir Bucal.* 2017;22(5):e588-93. doi:10.4317/medoral.21942
7. Zhang J, Wang H, He L, et al. Cone-beam CT in evaluation of odontogenic lesions. *Dentomaxillofac Radiol.* 2019;48(2):20180328. doi:10.1259/dmfr.20180328
8. Katz RW. Odontoma: Review of the literature and report of a case. *J Am Dent Assoc.* 1989;118(2):265-8. doi:10.14219/jada.archive.1989.0206
9. Shetty DC, Urs AB, Ahuja P, Sikka S, Mannan R, Sahu S. Hybrid odontogenic lesions: a systematic review. *J Oral Maxillofac Surg.* 2014;72(7):1343-56. doi:10.1016/j.joms.2014.02.030
10. Chrcanovic BR, Reis BM, Freire-Maia B. Cystic odontoma: Case report and literature review. *Oral Surg Oral Med Oral Pathol Oral Radiol Endod.* 2010;109(5):e71-e76. doi:10.1016/j.tripleo.2009.12.009
11. Tekkesin MS, Pehlivan S, Olgac V. Clinical and histopathological investigation of odontomas: Review of 160 cases. *J Oral Maxillofac Surg.* 2012;70(6):1358-61. doi:10.1016/j.joms.2011.04.046..