

A Comparative Study Of Functional Outcome In Forearm Fracture Treated With Intramedullary Nail And Plate - A Prospective Study

Dinesh Kumar Meena¹, Vimlesh Kumar Meena², Anshul Kumar Pahadiya³, Anil Yadav⁴, Manish Dhankar^{5*}

¹Associate Professor, Department of Orthopaedics, Pacific Medical College and Hospital, Udaipur, Rajasthan

²Assistant Professor, Department of Orthopaedics, Ananta institute of medical sciences and research centre, Udaipur, Rajasthan

³Assistant Professor, Department of Orthopaedics, Ananta institute of medical sciences and research centre, Udaipur, Rajasthan

⁴PG Resident, Department of Orthopaedics, Ananta institute of medical sciences and research centre, Udaipur, Rajasthan

^{5*}Professor and Head, Department of Orthopaedics, Ananta institute of medical sciences and research centre, Udaipur, Rajasthan

Corresponding Author

Manish Dhankar

ABSTRACT

Forearm fractures continue to pose significant medical issues because they disrupt upper limb movement and require surgical teams to restore bone structure to its original state. This study prospectively examined how intramedullary nailing and plate osteosynthesis affected the functional and radiological results of adult patients undergoing treatment. The study involved 68 patients who were assigned to two groups and monitored for 12 weeks while their progress was evaluated through surgical data and their healing results and any problems they encountered and their functional progress which was measured by the Modified Grace and Eversmann Scoring System. The study results showed that intramedullary nailing required less time for surgery while it achieved faster fracture healing because of its less invasive design whereas plate fixation maintained constant anatomical positioning. The two methods achieved similar functional results because their overall score and grade distribution showed no statistically significant differences. The two groups experienced minimal complications which showed different patterns according to the surgical methods used. The research results demonstrate that both intramedullary nailing and plate osteosynthesis serve as effective treatment methods while clinical assessment and fracture details and patient requirements should determine which method to use.

Keywords: Forearm fractures, Plate Osteosynthesis, Intramedullary Nailing, Modified Grace and Eversmann Scoring System

How to cite this article: Meena DK, Meena V, Pahadiya AK, Yadav A, Dhankar M. A Comparative Study of Functional Outcome in Forearm Fracture Treated with Intramedullary Nail and Plate - A Prospective Study. *Int J Drug Deliv Technol.* 2026;16(22s): 319-326. DOI: 10.25258/ijddt.16.22s.34

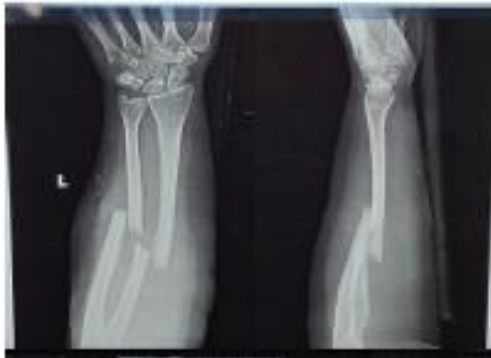INTRODUCTION

Forearm fractures pose as a major medical problem because these fractures occur frequently in both children and adults.¹ The forearm bone structure which includes both the radius and ulna bones serves as an essential element which allows complete upper limb movement through its ability to enable both pronation and supination.² The fractures happen because of high energy traumas from motor vehicle accidents and because osteoporotic patients experience low energy falls as another common type of injury.³ The treatment methods for forearm fractures have changed since past times because current medical practice requires surgical procedures to treat displaced adult fractures which need to restore bone alignment and achieve maximum functional results.⁴ The two main surgical methods used

to fix forearm fractures are intramedullary nailing (IMN) and plate osteosynthesis, which have become the most common choices.⁵ The traditional gold standard for plate fixation involves dynamic compression plates (DCP) and locking compression plates (LCP) because these devices deliver stable fixation while restoring bone alignment.⁶ The method requires surgeons to perform extensive soft tissue dissection, which increases the possibility of infection and delayed healing along with the risk of refracture after removing the surgical hardware.⁷ Intramedullary nailing provides a less invasive treatment option which maintains blood flow to the bone while reducing damage to soft tissues and enabling patients to start moving again.⁸ The use of IMN presents difficulties which include issues with rotation and hardware problems that occur especially with forearm fractures in their distal section.⁹ The medical community has not yet reached a conclusion about which method, plate fixation

A Comparative Study Of Functional Outcome In Forearm Fracture Treated With Intramedullary Nail And Plate - A Prospective Study

or intramedullary nailing, delivers better results because different studies show different results about their effectiveness in producing successful unions and their rates of complications and their impact on patient functioning. Some researchers support plate fixation because it offers better mechanical strength, while other researchers argue that IMN delivers similar outcomes with fewer risks.¹⁰ The primary factors that determine treatment effectiveness at hospitals depend on three assessments which include range of motion and grip strength assessment and patients' ability to resume their normal daily activities. The existing literature lacks sufficient high quality prospective studies which directly assess the two treatment methods through direct comparison. The findings from previous studies have produced conflicting results. The study conducted by Khateeb et al. (2017) showed that patients who underwent intramedullary nailing experienced shorter surgery times and achieved faster bone healing than those who received plating treatment.¹¹ The study conducted



by Ambhore et al. (2018) showed that both surgical methods produced good outcomes but most doctors preferred plate osteosynthesis as their primary method to treat forearm fractures.¹² The research conducted by Gude et al. (2019)¹³ found that patients who received dynamic compression plating achieved better functional results than those who received interlocking nailing. The research conducted by Box et al. (2024)¹⁷ used systematic review and meta-analysis methods to show that IMN resulted in shorter surgical procedures and fewer total complications when compared to open reduction and internal fixation. The current research assessed functional results for patients with forearm fractures treated through two distinct methods: plate fixation and intramedullary nailing. The Modified Grace and Eversmann Scoring System assessed functional outcomes through its evaluation of pain and range of motion and strength and functional ability. The study analysed secondary outcomes through three metrics: time to radiographic union and complication rates and patient satisfaction. The prospective study design established strong evidence for clinical decision-making which led to better results for patients with forearm fractures.

MATERIALS AND METHODS

Study Design and Setting

The study observed patients for 18 months at Ananta Institute of Medical Sciences and Research Centre which operated an Inpatient Department at its Orthopaedics Department. We aimed to compare the functional and radiological results of two treatments for forearm fractures which included intramedullary nailing and plate osteosynthesis. The sample size was determined using the formula for comparative studies with the following assumptions: 95% confidence level ($Z = 1.96$), power of 80%, and an expected effect size based on prior literature. The minimum required sample was calculated to be 61 patients (30.5 per group). A total of 68 patients were selected for the study because we anticipated 11 percent of participants would drop out during the research process. The study included patients who were 18 years old or above and had both bone forearm fractures or isolated radius or ulna fractures or Galeazzi and Monteggia fracture dislocations. The study excluded patients who had pathological fractures, open fractures (Gustilo-Anderson Grade I-III), or prior surgical fixation of the affected forearm. Study participants were divided into two separate treatment groups. The intramedullary nailing group received treatment with titanium elastic nails (TENS) and rigid intramedullary devices through fluoroscopic guided closed reduction which maintained both fracture hematoma and periosteal blood supply. The plating group received open reduction and internal fixation (ORIF) through dynamic compression plates (DCP) and locking compression plates which initiated anatomic reduction to achieve absolute stability through compression at the fracture site. The medical staff conducted all procedures under general or regional anesthesia while following standard aseptic methods and administering prophylactic antibiotics before surgery and thromboprophylaxis protocols according to institutional guidelines. Two methods were used to achieve radius exposure through either the volar Henry approach or the dorsolateral Thompson approach while using a subcutaneous method to expose the ulnar area. The patients received postoperative treatment through two weeks of splint immobilization which were replaced with active physiotherapy that allowed them to move while they followed weight bearing restrictions based on their fracture stability and X-ray indicators of recovery. The assessment process for patients included multiple evaluations that focused on two main assessment times which occurred six weeks and twelve weeks after their surgical procedures. The radiological assessment used standard anteroposterior and lateral radiographs to measure callus formation and determine fracture union through observation of bridging callus presence on three of four cortices at orthogonal views while verifying that no screw loosening or implant failure occurred. The Modified Grace and Eversmann Scoring System was used to evaluate functional outcomes which assesses supination and pronation range of motion and six-week radiological union and elbow range of motion to determine final grades of excellent good fair or poor.

A Comparative Study Of Functional Outcome In Forearm Fracture Treated With Intramedullary Nail And Plate - A Prospective Study

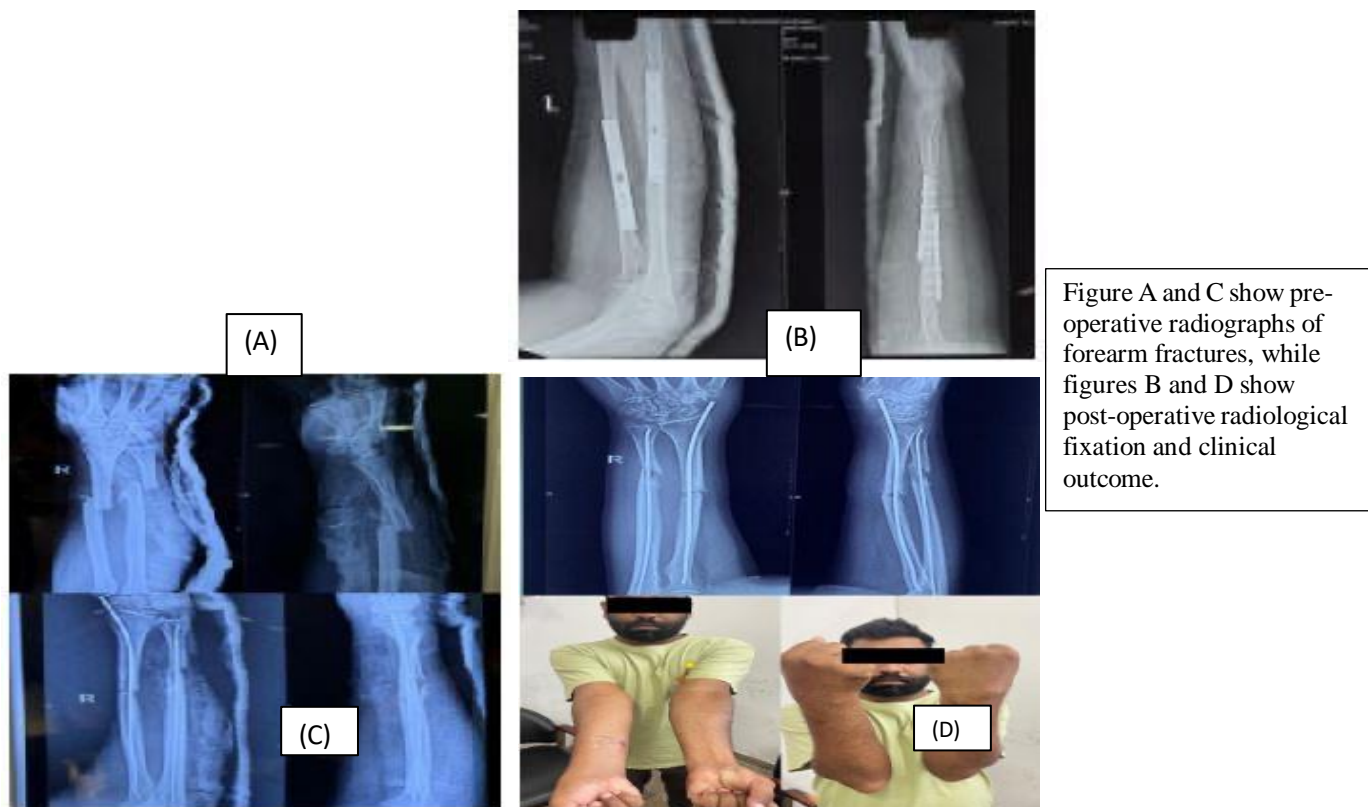


Figure A and C show pre-operative radiographs of forearm fractures, while figures B and D show post-operative radiological fixation and clinical outcome.

The research study followed all guidelines established by the Declaration of Helsinki. The Institutional Ethics Committee of Ananta Institute of Medical Sciences and Research Centre (No. AIMS/IEC/2024/172) granted ethical approval for the study after researchers obtained written informed consent from all study participants before they joined the study. It was assured to protect the patient privacy throughout the entire study period by removing all identifying details and safeguarding data in secure storage facilities.

RESULTS

A total of 68 patients with forearm fractures were enrolled in this prospective comparative study, with 34 patients allocated to the intramedullary nailing (IMN) group and 34 patients to the plating group. All patients completed the minimum follow-up period of 12 weeks. The demographic and baseline characteristics were

comparable between the two groups, with no statistically significant differences observed.

Demographic and Baseline Characteristics

Table 1 presents a summary of the demographic data together with the initial characteristics

which the two study groups possessed. The nailing group had an average patient age of 45.79 years with a standard deviation of 11.30 years. The plating group had an average patient age of 42.30 years with a standard deviation of 8.75 years. The two groups displayed a gender distribution that showed a slightly higher number of females in both groups because 58.82 percent of the nailing group and 55.88 percent of the plating group were female but this difference did not reach statistical significance ($p = 0.81$). The two groups displayed equal residential distribution between urban and rural areas because 55.88 percent of the nailing group lived in urban areas while 47.06 percent of the plating group lived in urban areas ($p = 0.47$). The two groups displayed similar

educational distribution together with their socio-economic status because the p-values reached 0.205 and 0.645 respectively. The nailing group had 58.82 percent Hindu members while the plating group had 61.76 percent Hindu members ($p = 0.803$). The two groups had similar fracture side distribution because 52.94 percent of nailing group members had right-sided fractures while 44.12 percent of plating group members had right-sided fractures ($p = 0.467$).

Table 1: Demographic and Baseline Characteristics of Study Participants

A Comparative Study Of Functional Outcome In Forearm Fracture Treated With Intramedullary Nail And Plate - A Prospective Study

Parameter	Nailing Group (n=34)	Plating Group (n=34)	p-value
Age (years)	45.79 ± 11.30	42.30 ± 8.75	0.183
Gender			0.81
Male	14 (41.18%)	15 (44.12%)	
Female	20 (58.82%)	19 (55.88%)	
Area of Residence			0.47
Urban	19 (55.88%)	16 (47.06%)	
Rural	15 (44.12%)	18 (52.94%)	
Education			0.205
Primary	5 (14.71%)	2 (5.88%)	
Secondary	5 (14.71%)	12 (35.29%)	
Higher Secondary	10 (29.41%)	7 (20.59%)	
Graduate	8 (23.53%)	10 (29.41%)	
Post Graduate	6 (17.65%)	3 (8.82%)	
Socio-economic Status			0.645
Lower	8 (23.53%)	7 (20.59%)	
Lower Middle	6 (17.65%)	10 (29.41%)	
Upper Middle	11 (32.35%)	11 (32.35%)	
Upper	9 (26.47%)	6 (17.65%)	
Religion			0.803
Hindu	20 (58.82%)	21 (61.76%)	
Muslim	14 (41.18%)	13 (38.24%)	
Side of Fracture			0.467
Left	16 (47.06%)	19 (55.88%)	
Right	18 (52.94%)	15 (44.12%)	

Injury Characteristics

Table 2 presents the injury characteristics of both study groups. Accidental falls were the most common cause of injury in both groups (32.35% in nailing group, 35.29% in plating group), followed by assault (41.18% in nailing group, 50.00% in plating group). The difference in the distribution of injury causes was not statistically significant (p = 0.426). Regarding fracture classification according to the AO/OTA system, both groups had equal

representation of 22A3 fractures (29.41% each). Complex 22C3 fractures were more common in the nailing group (41.18% versus 17.65% in plating group), while 22B3 fractures were more frequent in the plating group (35.29% versus 14.71% in nailing group). The overall difference in fracture classification approached but did not reach statistical significance (p = 0.062). In terms of the number of bones fractured, 52.94% of patients in the nailing group had single bone fractures compared to 47.06% in the plating group, while both-bone fractures were present in 47.06% of nailing group and 52.94% of plating group. This difference was not statistically significant (p = 0.63).

Table 2: Injury Characteristics of Study Participants

Parameter	Nailing Group (n=34)	Plating Group (n=34)	p-value
Cause of Injury			0.426
Accidental Fall	11 (32.35%)	12 (35.29%)	
Road Traffic Accident	4 (11.76%)	2 (5.88%)	
Assault	14 (41.18%)	17 (50.00%)	
Fall from Height	3 (8.82%)	0 (0.00%)	
Others	2 (5.88%)	3 (8.82%)	
AO/OTA Classification			0.062
22A3	10 (29.41%)	10 (29.41%)	
22B3	5 (14.71%)	12 (35.29%)	
22C1	0 (0.00%)	2 (5.88%)	
22C2	5 (14.71%)	4 (11.76%)	
22C3	14 (41.18%)	6 (17.65%)	
Number of Bones Fractured			0.63
Single Bone	18 (52.94%)	16 (47.06%)	

A Comparative Study Of Functional Outcome In Forearm Fracture Treated With Intramedullary Nail And Plate - A Prospective Study

Both Bones	16 (47.06%)	18 (52.94%)	
-------------------	----------------	----------------	--

Operative and Radiological Outcomes: The mean operative time was significantly shorter in the nailing group (60.53 ± 6.12 minutes) compared to the plating group (72.79 ± 6.70 minutes), with a p-value of <0.001 . Similarly, the mean fracture union time was significantly shorter in the nailing group (11.76 ± 1.88 weeks) versus the plating group (15.35 ± 2.12 weeks), also with a p-value of <0.001 . Table 3 summarizes the operative and radiological outcomes.

Table 3: Operative and Radiological Outcomes

Parameter	Nailing Group (n=34)	Plating Group (n=34)	p-value
Operative Time (minutes)	60.53 ± 6.12	72.79 ± 6.70	<0.001
Union Time (weeks)	11.76 ± 1.88	15.35 ± 2.12	<0.001

Postoperative Complications: The majority of patients in both groups experienced no complications (64.71% in nailing group, 73.53% in plating group). Delayed union occurred equally in both groups (5.88% each). Surgical site infections were also observed equally in both groups (11.76% each). Nail impingement and olecranon bursitis were reported exclusively in the nailing group (8.82% each). Elbow stiffness was observed exclusively in the plating group (8.82%), with no cases in the nailing group. Table 4 presents the distribution of postoperative complications.

Table 4: Postoperative Complications

Complication	Nailing Group (n=34)	Plating Group (n=34)
None	22 (64.71%)	25 (73.53%)
Delayed Union	2 (5.88%)	2 (5.88%)
Nail Impingement	3 (8.82%)	0 (0.00%)
Olecranon Bursitis	3 (8.82%)	0 (0.00%)
Surgical Site Infection	4 (11.76%)	4 (11.76%)
Elbow Stiffness	0 (0.00%)	3 (8.82%)

Functional Outcomes: Functional outcomes were assessed using the Modified Grace and Eversmann

Scoring System (MGESS) at the final follow-up. Table 5 presents the comparison of MGESS scores between the two groups. The mean MGESS score was 6.79 ± 1.70 in the nailing group and 6.85 ± 1.91 in the plating group, with no statistically significant difference ($p = 0.889$).

Table 5: Modified Grace and Eversmann Scoring System Outcomes

Parameter	Nailing Group (n=34)	Plating Group (n=34)	p-value
Mean MGESS Score	6.79 ± 1.70	6.85 ± 1.91	0.889
Functional Grade			0.648
Poor	8 (23.53%)	10 (29.41%)	
Fair	15 (44.12%)	10 (29.41%)	
Good	9 (26.47%)	12 (35.29%)	
Excellent	2 (5.88%)	2 (5.88%)	

When categorized by functional grade, the nailing group demonstrated poor outcomes in 23.53% of patients, fair outcomes in 44.12%, good outcomes in 26.47%, and excellent outcomes in 5.88%. In the plating group, poor outcomes were observed in 29.41% of patients, fair outcomes in 29.41%, good outcomes in 35.29%, and excellent outcomes in 5.88%. The overall difference in outcome grades between the two groups was not statistically significant ($p = 0.648$).

DISCUSSION

There exists ongoing disagreement about how to treat diaphyseal forearm fractures which doctors use to treat adults because plate osteosynthesis functions as the established treatment method but intramedullary nailing provides a less invasive treatment option. This research study assessed the rehabilitation results of 68 patients who suffered from forearm fractures and received treatment through either intramedullary nailing or plate fixation, with all patients undergoing assessment after at least 12 weeks. The results show that both methods produce similar functional results but intramedullary nailing requires less surgical time and achieves faster bone healing because it has different risk factors.

Demographic Characteristics: The study examined two groups which had an average age of 45.79 years with an age range of 11.30 years for the nailing group and

A Comparative Study Of Functional Outcome In Forearm Fracture Treated With Intramedullary Nail And Plate - A Prospective Study

42.30 years with an age range of 8.75 years for the plating group but the two groups showed no significant age difference. The results match the findings of Gude et al. (2019)¹³ because both treatment groups had about 39 years as their average age while Bhutani et al. (2021)¹⁸ found average ages of 39.05 years and 38.73 years for their intramedullary and plating groups. The study found that female participants outnumbered male participants because 58.82% of the nailing group and 55.88% of the plating group were female whereas Kale et al. (2021)¹⁵ and Mahendiran et al. (2023)¹⁶ found that their studies showed male dominance. The observed differences show regional differences for work related exposure and injury patterns which do not indicate any treatment distribution errors. The nailing group showed higher rates of complex 22C3 fractures 41.18% than the plating group which had 17.65% while the plating group showed 22B3 fractures at 35.29% compared to the 14.71% rate in the nailing group. The distribution showed approaching statistical significance with a p value of 0.062 but the absence of significant difference indicates that surgeons selected nailing to treat more complex fracture patterns. This finding matches the research by Kale et al. (2021)¹⁵ which showed that complex fracture patterns needed more surgical planning during the IMN procedure.

Operative Time: The study found that intramedullary nailing group had an average operative duration of 60.53 minutes which was 12.26 minutes shorter than the plating group that operated for 72.79 minutes. The finding matches with the results from Khateeb et al. (2017)¹¹ who found that IMN surgery average duration was 43 minutes while plating needed 68 minutes. The systematic review and meta-analysis conducted by Box et al. (2024)¹⁷ found that IMN method always produced shorter surgical times than open reduction and internal fixation. The IMN group achieved shorter surgical times because the procedure required fewer invasive methods which led to less tissue damage and did not require surgeons to perform complete surgical field exposure and precise plate shape matching. The advantage shows its biggest impact in surgical facilities that treat a large number of patients because higher surgical efficiency leads to better patient care and lower resource consumption according to Agrawal et al. (2024)¹⁹ who identified IMN advantages for facilities that face limited surgical capacity.

Fracture Union Time: The research showed that fracture healing occurred more quickly in the nailing group which took 11.76 ± 1.88 weeks to heal than in the plating group which took 15.35 ± 2.12 weeks to heal. The study found that fractures healed more quickly in the nailing group which required 7.8-8 weeks to heal than in the plating group which needed 9.3-9.6 weeks to heal according to Khateeb et al. (2017)¹¹ whereas Kale et al. (2021)¹⁵ discovered a 3.6-week mean radiological union time for IMN procedures. Closed nailing techniques lead to faster union times because they maintain periosteal blood supply better and disrupt fracture biology less than

other methods. According to Agrawal et al. (2024)¹⁹ screw nail osteosynthesis provides functional outcomes which match plating results but it produces less blood loss and better biological recovery. The nailing group achieved faster healing because the fracture hematoma and surrounding soft tissue envelope maintained their integrity which provided a rich source of osteoprogenitor cells and growth factors.

Postoperative Complications: Our study discovered significant treatment differences through analysis of complication profiles between two treatment methods. The majority of patients in both groups experienced no complications (64.71% in nailing group, 73.53% in plating group), which is consistent with the systematic review by Box et al. (2024)¹⁷, who reported a lower overall complication rate associated with intramedullary nailing compared to open reduction and internal fixation. The groups showed different complication patterns which developed through their respective treatment methods. Nail impingement and olecranon bursitis were observed exclusively in the nailing group (8.82% each), while elbow stiffness was seen exclusively in the plating group (8.82%). The findings correspond to the results of Khateeb et al. (2017)¹¹ who discovered that plating caused more implant problems which included implant failure and infection and nerve palsy while IMN caused only slight soft-tissue damage and no cases of synostosis or nail migration. Both groups showed identical rates of surgical site infections at 11.76% which indicates that infection risk linked directly to external factors like operating conditions and patient comorbidities and soft tissue injury severity rather than to the fixation method itself. The pattern has shown consistent results through previous studies which include the research conducted by Gude et al. (2019)¹³ and Ambhore et al. (2018)¹² who found similar infection rates that did not connect to specific implant types.

Functional Outcomes: The study's main outcome assessment through the Modified Grace and Eversmann Scoring System showed no significant difference between the two research groups. The nailing group achieved a mean MGEES score of 6.79 ± 1.70 , while the plating group achieved a mean score of 6.85 ± 1.91 ($p = 0.889$). The plating group achieved better results than the nailing group because 35.29% of its members reached good outcomes, compared to 26.47% of the nailing group. The nailing group achieved fair outcomes at a higher rate than the plating group, which achieved 44.12% of its members reaching fair outcomes compared to the plating group's 29.41%. The two groups achieved identical results for excellent outcomes because both groups had 5.88% excellent outcomes, while functional grade distribution showed no significant difference between groups. The findings support the Westcott et al. (2012)²⁰ systematic review, which found that current research shows no difference in functional outcomes between intramedullary nailing and plate and screw fixation. Saini et al. (2023)²¹ found that patients who

A Comparative Study Of Functional Outcome In Forearm Fracture Treated With Intramedullary Nail And Plate - A Prospective Study

received plating treatment and those who received nailing treatment achieved similar functional results, while Agrawal et al. (2024)¹⁹ found that both groups reached good-to-excellent MGESS scores at the same rate of 86.6%. Basha et al. (2021)¹⁴ found that both methods produced similar functional results, but they discovered that plate fixation achieved more outstanding results than the other technique. The present study demonstrates that intramedullary nailing and plating methods provide identical functional results for forearm fracture treatment, which enables surgeons to choose their preferred method based on fracture pattern and soft tissue status and patient requirements.

Conclusion

The present study gently reinforces the understanding that both intramedullary nailing and plate osteosynthesis are dependable methods for the surgical management of forearm fractures in adults. While intramedullary nailing offers certain advantages such as reduced operative time and earlier fracture union, plate fixation continues to provide stable anatomical alignment with comparable functional recovery. Importantly, the overall functional outcomes between the two techniques were found to be similar, suggesting that neither method holds absolute superiority. Each technique carries its own set of advantages and limitations, reflected in their distinct complication patterns. Therefore, the selection of the surgical approach should be individualized, taking into consideration the nature of the fracture, soft tissue condition, available resources, and surgeon expertise. A thoughtful and patient centred approach may help achieve optimal clinical outcomes and satisfactory functional recovery.

References

1. Chung KC, Spilson S V. The frequency and epidemiology of hand and forearm fractures in the United States. *J Hand Surg Am* [Internet]. 2001;26(5):908–15. Available from: <http://dx.doi.org/10.1053/jhsu.2001.26322>
2. Matthews LS, Kaufer H, Garver DF, Sonstegard DA. The effect on supination-pronation of angular malalignment of fractures of both bones of the forearm. *J Bone & Jt Surg* [Internet]. 1982;64(1):14–7. Available from: <http://dx.doi.org/10.2106/00004623-198264010-00003>
3. Court-Brown CM, Caesar B. Epidemiology of adult fractures: A review. *Injury* [Internet]. 2006;37(8):691–7. Available from: <http://dx.doi.org/10.1016/j.injury.2006.04.130>
4. Wei SY, Born CT, Abene A, Ong A, Hayda R, DeLong WG. Diaphyseal Forearm Fractures Treated with and without Bone Graft. *J Trauma Inj Infect Crit Care* [Internet]. 1999;46(6):1045–8. Available from: <http://dx.doi.org/10.1097/00005373-199906000-00011>
5. Jones DB, Kakar S. Adult Diaphyseal Forearm Fractures: Intramedullary Nail Versus Plate Fixation. *J Hand Surg Am* [Internet]. 2011;36(7):1216–9. Available from: <http://dx.doi.org/10.1016/j.jhsa.2011.03.020>
6. Hertel R, Pisan M, Lambert S, Ballmer FT. Plate osteosynthesis of diaphyseal fractures of the radius and ulna. *Injury* [Internet]. 1996;27(8):545–8. Available from: [http://dx.doi.org/10.1016/s0020-1383\(96\)00091-5](http://dx.doi.org/10.1016/s0020-1383(96)00091-5)
7. Rosson JW, Shearer. Refracture after the removal of plates from the forearm. An avoidable complication. *J Bone Joint Surg Br* [Internet]. 1991;73-B(3):415–7. Available from: <http://dx.doi.org/10.1302/0301-620x.73b3.1670441>
8. Lee YH, Lee SK, Chung MS, Baek GH, Gong HS, Kim KH. Interlocking Contoured Intramedullary Nail Fixation for Selected Diaphyseal Fractures of the Forearm in Adults. *J Bone Jt Surgery-American Vol* [Internet]. 2008;90(9):1891–8. Available from: <http://dx.doi.org/10.2106/jbjs.g.01636>
9. Weckbach A, Blattner TR, Weißer C. Interlocking nailing of forearm fractures. *Arch Orthop Trauma Surg* [Internet]. 2006;126(5):309–15. Available from: <http://dx.doi.org/10.1007/s00402-006-0122-9>
10. Droll KP, Perna P, Potter J, Harniman E, Schemitsch EH, McKee MD. Outcomes Following Plate Fixation of Fractures of Both Bones of the Forearm in Adults. *J Bone Jt Surgery-American Vol* [Internet]. 2007;89(12):2619–24. Available from: <http://dx.doi.org/10.2106/jbjs.f.01065>
11. Khateeb M, Surgery MAIJ of O, 2017 undefined. Comparison of Intramedullary Nailing to Plating for Both-bone Forearm Fractures in Adult. *Acad Khateeb, MN AkbarIndian J Orthop Surgery, 2017•academia.edu* [Internet]. [cited 2026 Mar 27]; Available from: https://www.academia.edu/download/53811616/IJOS_32_135-142.pdf
12. Ambhore DN, Babhulkar DS. A comparative study between plating & intramedullary nailing for displaced diaphyseal fractures of radius and ulna in adults. *Surg Updat Int J Surg Orthop* [Internet]. 2018;4(1):29–36. Available

A Comparative Study Of Functional Outcome In Forearm Fracture Treated With Intramedullary Nail And Plate - A Prospective Study

- from:
<http://dx.doi.org/10.17511/ijoso.2018.i01.06>
13. Raju Gude N, Rao Kolati S, Bonda Y, Professor A, Graduate P. Comparative study of functional outcome of dynamic compression plating with interlocking nailing for fracture shaft humerus in adults. *iaimjournal.com* NR Gude, SR Kolati, Y Bond 2019•*iaimjournal.com* [Internet]. 2019 [cited 2026 Mar 27]; Available from: https://iaimjournal.com/wp-content/uploads/2019/08/iaim_2019_0608_15.pdf
14. Basha AMI, S. C, Gajendra G. A Prospective Comparative Study of Both Bone Forearm Fracture in Patients above Twelve Years of Age Treated with Dynamic Compression Plating and Intramedullary Nailing at a Tertiary Care Hospital in Kurnool, Andhra Pradesh. *J Evol Med Dent Sci* [Internet]. 2021;10(45):3816–20. Available from: <http://dx.doi.org/10.14260/jemds/2021/772>
15. Kale SY, Singh SD, Samant P, Bukalsaria D, Chaudhari P, Ghodke RJ. Treatment of diaphyseal forearm fracture with interlocking intramedullary nailing: A pilot study. *J Clin Orthop Trauma* [Internet]. 2021;17:195–200. Available from: <http://dx.doi.org/10.1016/j.jcot.2021.03.004>
16. Mahendiran V, Kumar SSV, Ponnuchamy PB. An Evaluation of the Efficacy of Flexible Nailing in the Management of Diaphyseal Forearm Fractures: A Prospective Study in Rural India's Healthcare Settings. *J Med Sci Heal* [Internet]. 2023;9(3):256–62. Available from: <http://dx.doi.org/10.46347/jmsh.v9i3.23.250>
17. Box MW, Stegelmann SD, Domingue GA, Wells ME, Werthmann NJ, Potgieter CJ, et al. Intramedullary nail fixation versus open reduction and internal fixation for treatment of adult diaphyseal forearm fractures: a systematic review and meta-analysis. *J Orthop Surg Res* [Internet]. 2024;19(1). Available from: <http://dx.doi.org/10.1186/s13018-024-05158-0>
18. Bhutani P, Gupta N, Pujara RD. A prospective comparative study of functional outcome in patients treated with interlocking nailing and dynamic compression plating for fracture shaft of humerus in adults. *Int J Res Orthop* [Internet]. 2021;7(4):786. Available from: <http://dx.doi.org/10.18203/issn.2455-4510.intjresorthop20212422>
19. Agrawal PP, Mankar S, Harkare V V, Sakhare RH, Halmare N. Functional Outcome of Forearm Fractures Managed With Screw Nails vs. Dynamic Compression Plates: A Prospective Study. *Cureus* [Internet]. 2024; Available from: <http://dx.doi.org/10.7759/cureus.67575>
20. Westacott DJ, Jordan RW, Cooke SJ. Functional outcome following intramedullary nailing or plate and screw fixation of paediatric diaphyseal forearm fractures: A systematic review. *J Child Orthop* [Internet]. 2012;6(1):75–80. Available from: <http://dx.doi.org/10.1007/s11832-011-0379-6>
21. Saini R, Sharma A, Baisoya K, Ravalji D. A Comparative Study Between Plate Osteosynthesis and Intramedullary Nailing for Diaphyseal Fracture of Radius and Ulna in Adults. *Cureus* [Internet]. 2023; Available from: <http://dx.doi.org/10.7759/cureus.37277>