

Protective Effects of Ascorbic Acid and Silver Nanoparticles against Pyrazole and Fipronil-Induced Kidney Toxicity in *Gallus domesticus*: A Comparative Study

Fareeha Ambreen^{*1}, Samina Qamer¹, Javaria Tufail¹, Madeeha Chaudhry², Laiba Saifullah¹, Anas Bilal¹, Bilal Ahmad³, Rabea Ejaz¹, Huda Sarwar¹, Husna Anwar¹, Ayesha Ishrat¹, Uzma Habib¹, Rizwana Kausar⁴, Esha Fatima¹, Tayyaba Iqbal¹

¹Department of Zoology, Rawalpindi Women University, Pakistan

²Department of Biological Sciences, Virtual University, Islamabad, Pakistan

³Department of Zoology, The Islamia University of Bahawalpur, Bahawalnagar Campus, Bahawalnagar Pakistan

⁴Department of Biology, Allama Iqbal Open University, Islamabad, Pakistan

Corresponding Author

Dr. Fareeha Ambreen

Email: ID: fareeha.ambreen@f.rwu.edu.pk

ABSTRACT

The current study was planned to analyze the effect of Pyrazole and Fipronil on renal function of growing chicken and treatment with Ascorbic acid and Silver nanoparticles. Chicks weighing 60-70 g, aged 7-10 days were obtained from Hatchery used for the study and divided into 9 groups. Doses were given orally on daily basis for 4 weeks. Group I was control group (0.9% NaCl). Group II was given pyrazole (25mg/kg body weight (b.w)); Group III was given nanoparticles 20µl per animal. Group IV was given pyrazole (25mg/kg b.w) and ascorbic acid (250mg/kg b.w). Group V was given Ascorbic acid (250mg/kg b.w). Group VI was given Fipronil (4.5mg/kg b.w). Group VII was given Fipronil (4.5mg/kg b.w) and Ascorbic Acid (250mg/kg b.w). Group VIII was given Silver Nano particles 20µl per animal and Fipronil (4.5mg/kg b.w). Group IX was given Silver nano particles 20 µl per animal and Pyrazole (25mg/kg b.w). After last dose animals were dissected. Serum was separated to be used for RFT and kidney tissues were separated for histology. Results showed slight increased body weight in pyrazole ($p < 0.0001$) and significantly decreased in fipronil ($p < 0.623$) treated groups while urea, creatinine and uric acid level had increased significantly ($p < 0.0001$). Groups treated with Ascorbic acid ($p < 0.0001$) and Silver nanoparticles ($p < 0.05$) showed increased body weight and the level of urea, creatinine and uric acid was almost same as control group ($p < 0.0001$). There was strong correlation between urea, creatinine and uric acid. The study indicates that Pyrazole and Fipronil are toxicants, treatment with Ascorbic acid and Silver nanoparticles reduced toxicity in chick kidney.

Keywords: chicken; pyrazole; fipronil; kidney; toxicity; nanoparticles.

How to cite this article: Ambreen F, Qamer S, Tufail J, Chaudhry M, Saifullah L, Bilal A, Ahmad B, Ejaz R, Sarwar H, Anwar H, Ishrat A, Habib U, Kausar R, Fatima E, Iqbal T. Protective Effects of Ascorbic Acid and Silver Nanoparticles against Pyrazole and Fipronil-Induced Kidney Toxicity in *Gallus domesticus*: A Comparative Study. *Int J Drug Deliv Technol.* 2026;16(23s): 90-97. DOI: 10.25258/ijddt.16.23s.11

Source of support: Nil.

Conflict of interest: Nil.

INTRODUCTION

Pyrazole

Ludwig Knorr coined the word "pyrazole" in 1883. The family of simple aromatic ring organic compounds known as pyrazoles belongs to the heterocyclic series and is distinguished by its five-membered ring structure, which is made up of two nitrogen atoms in neighboring places and three carbon atoms. Despite being uncommon in nature, they are categorized as alkaloids due to their composition and pharmacological effects on humans. 1-pyrazolyl-alanine, the first naturally occurring pyrazole, was extracted from watermelon seeds in 1959 (Eicher et al., 2003; Alam et al., 2015). Because of the potential for severe adverse effects (such as agranulocytosis), several pyrazole derivatives have been removed from clinical use or advised

to be handled with care (Bakke et al., 1984; Moura et al., 2017).

Pyrazole Derivatives

There are many types and derivatives of pyrazole like Fipronil. More than forty nations and regions reported fipronil in chicken eggs in 2017, which was deemed a worldwide food safety crisis (Ruzza et al., 2020; Chen et al., 2021; Zhang et al., 2023). Since its introduction by the French company Rhone-Poulenc in 1993, fipronil has been a wide ranging Phenyl pyrazole pesticide utilized in veterinary and agricultural sectors for the protection against ticks, lice, fleas, termites, root worms, beetles, and cockroaches (Chaguri et al., 2016; Zhang et al., 2023; Corrias et al., 2021). In order to determine how environmental pollutants, such as pesticides, alter immunological responses, chickens are a useful animal

*Author for Correspondence: fareeha.ambreen@f.rwu.edu.pk

model for immune toxicological risk assessment (Adhikari et al., 2014). Fipronil and its metabolite residues have been found in a number of global chicken monitoring surveys (Merwe et al., 2019; Corrias et al., 2021).

Ascorbic Acid

In human tissue, vitamin C, often known as ascorbic acid, is the most abundant, usually water-soluble nonenzymic antioxidant (Traikovich et al., 1999; Ravetti et al., 2019). Water-soluble antioxidant ascorbic acid, commonly known as vitamin C, helps body to absorb iron and forms collagen in blood vessels, muscles, bones, and cartilage (Bera et al., 2010; Khan et al., 2013). Ascorbic acid (AA), one of the antioxidant vitamins, may have cytoprotective benefits by reducing reactive oxygen species (ROS), according to many experimental investigations (Taha et al., 2004; Korkmaz and Kolankaya, 2009). By reducing the activity of free radicals caused by lead, vitamin C supplementation helped to partially lessen the adverse consequences of lead on kidney and liver of quail (Almansour et al., 2008; Heriba et al., 2020; Hassan et al., 2023). While AA has been shown to lessen oxidative stress caused by ischemia and reperfusion in cardiac or hepatic tissues of rats (Molyneux et al., 2002; De Tata et al., 2005; Korkmaz and Kolankaya, 2009).

Silver Nano Particles

Nanosilver's broad spectrum of antibacterial activity allows it to inhibit the development of both Gram-positive and Gram-negative bacteria, including *Escherichia coli*, *Pseudomonas aeruginosa*, and *Staphylococcus aureus*. (Birla et al., 2009; Yu et al., 2013). Additionally, nanosilver works well as a fungicide. Many common fungal strains, such as *Aspergillus fumigatus*, *Mucor*, *Saccharomyces cerevisiae*, and *Candida tropicalis*, can be killed by AgNPs (Wright et al., 1999; Yu et al., 2013). AgNPs were investigated to provide a next-generation cancer diagnostic and treatment tool (Huy et al., 2020; Takac et al., 2023). AgNPs may prevent cancer cells from growing and surviving, according to many in vivo and in vitro investigations. AgNPs may cause necrosis and death by altering the ultrastructure of cancer cells, generating ROS, and damaging DNA (Muhamad et al., 2022; Takac et al., 2023).

The current study was carried out to investigate the nephrotoxicity cause by exposure of pyrazole and fipronil in chicken and its treatment ascorbic acid and AgNPs.

Materials and Methods

Broiler chicks (*Gallus domesticus*, 7-10 days old, 60-70g) were obtained from Hatchery in Rawalpindi. The animals were divided into 9 groups (n=10 each) and treated orally for 4 weeks. Groups were as follows: Group I Control treated with 0.9% NaCl solution;

Group II given Pyrazole at the dose of 25 mg/kg body weight; Group III given nano particles 20 µl per animal; Group IV given pyrazole 25 mg/kg body weight and ascorbic acid 250 mg/kg body weight; Group V Ascorbic acid 250 mg/kg body weight; Group VI were given fipronil 4.5 mg/kg body weight; Group VII fipronil 4.5mg/kg and ascorbic acid 250 mg/kg; Group VIII Silver Nano Particles 20 µl and Fipronil 4.5 mg/kg body weight; Group IX were given pyrazole 25mg/kg body weight and nanoparticles 20 µl per animal. Pyrazole was obtained from Macklin (China).

Fipronil (80%) from Bayers, Lahore Pakistan. Ascorbic acid was obtained from Sigma Aldrich USA also from Rawalpindi and Nano particles were provided by courtesy of Virtual university of Pakistan.

Animals were weighed before the start of dose administration and doses were given according to the body weight and administered daily. On the last day, chicks were sacrificed using chloroform anesthesia. Blood was collected from the heart, centrifuged at 3000 rpm for 5 minutes, and serum was separated. Kidneys were washed with saline, and processed for histology.

Serum creatinine, urea and uric acid were estimated using Microlab 300 (ELITECH, Switzerland) based on spectrophotometry. Kidneys were fixed in formalin, sectioned, stained with eosin and hematoxylin and examined under a trinocular digital microscope for nephrotoxic changes.

Data were analyzed in SPSS version 28.0 using one-way ANOVA, followed by post hoc tests (LSD/Tukey). Correlation analysis was also performed. The change in body weight among different groups was analyzed by one way ANOVA with the help of LSD and TUKEY's test.

RESULTS

Effects on Body Weight

Body weight of chicks of all groups were recorded weekly during the experiment. Most rapid growth rate was observed between week 2 and 3 in control (P, 0.0001), silver nanoparticle treated (p<0.05), pyrazole treated group (p<0.0001) and pyrazole and ascorbic acid treated group (p< 0.0001). In ascorbic Acid treated group mean weight significantly increased throughout the studied times of 4 weeks (P< 0.0001). In fipronil treated group significant growth was not observed in week 3rd and 4th. As F= 0.617 and (P > 0.05). In Fipronil and Ascorbic Acid treated group the weight significantly increased during the study period of 4 weeks (P > 0.05). In silver NanoParticles and Fipronil treated group no significant difference was observed in the mean weight of 4 groups (P>0.05). In *Silver Nanoparticles and Pyrazole treated* group the weight significantly increased throughout the studied time of 4 weeks (p < 0.0001) (Table 1).

Renal Functions tests

Results showed that urea levels in control group were 6.76±0.86 mg/dl. Urea level in pyrazole and fipronil treated groups were significantly high compared to control group suggesting renal injury or malfunction. The treatment with Ascorbic Acid as well as nano particles lowered urea level compared to pyrazole and fipronil treated groups suggesting a protective effect. Mean serum urea level in Fipronil and Ascorbic Acid treated group were 7.46±1.37 mg/dl which were very close to control group suggesting protective effect against renal toxicity (F= 15.22; p < 0.0001) (Table 2).

Mean Serum creatinine level in pyrazole and Fipronil treated group were significantly high compared to control group (p<0.0001) suggesting renal injury or malfunction. The treatment with ascorbic acid as well as nano particles lowered creatinine level compared to pyrazole and fipronil treated groups suggesting a protective effect. The creatinine

level of fipronil and ascorbic acid treated group and silver nano particles and Fipronil treated group were very close to control group suggesting protective effect against renal toxicity ($p < 0.0001$) (Table 2).

Results showed that uric acid level in control group were 9.50 ± 1.74 mg/dl. Uric acid level in Pyrazole and Fipronil treated groups were significantly high compare to control group ($p < 0.0001$) suggesting renal injury or malfunction. The treatment with ascorbic acid as well as nano particles lowered uric acid level compared to pyrazole and fipronil treated groups suggesting a protective effect. The uric acid level of fipronil and ascorbic acid treated group were very close to control group similarly silver nano particles and pyrazole treated group suggesting protective effect against renal toxicity ($F=10.748$; $p < 0.0001$) (Table 2).

Correlation between different kidney Parameters

Urea mean significantly correlated with creatinine ($r=0.723$; $p < 0.0001$). This indicates that creatinine tends to rise as urea increases. Urea mean strongly correlated with uric acid ($r=0.635$; $p < 0.0001$). That showed increase in urea tends to increase uric acid level (Table 3).

Renal Tissue Histology

The histology of kidney tissues was performed using hematoxyline and eosin staining. In control group cellular architecture of renal tissue was normal. There were no overt signs of necrosis, dilatation, or degeneration; the cuboidal epithelial lining of the proximal and distal convoluted tubules were normal. In pyrazole treated group, there were indications of cellular necrosis, vacuolization and loss of

epithelial integrity in the renal tubules. Silver nanoparticles group showed intact tubular epithelium. In architecture, glomeruli were conspicuous and comparatively typical. No obvious symptoms of glomerular necrosis or atrophy were observed. In pyrazole and ascorbic acid group glomeruli seemed to be more or less typical, with less congestion and clear Bowman's gaps. This implied that ascorbic acid assisted in preserving or repairing the kidney filtration units. In ascorbic acid group glomeruli appeared well-defined and intact. Bowman's gaps were apparent and uncompressed, indicating a robust filtering system (Figure 1).

In fipronil treated group there was clear tubular epithelial degeneration; the cells appeared larger and have eosinophilic or vacuolated cytoplasm. Some of the tubular lumina were dilated, that might indicate necrosis or early atrophy. In fipronil and ascorbic acid treated group, renal tubules frequently retained their native form with reduced epithelial breakdown as compared to slides in fipronil treated group cytoplasmic granulation and vacuolization, were significantly reduced. In fipronil and silver nanoparticles treated animal group tubular epithelial cells were somewhat preserved. There was less tubular cell vacuolation, necrosis, and degeneration than in animal exposed to fipronil only. In silver nanoparticles and pyrazole group, kidney tissue mild histological changes, such as tubular degradation, glomerular shrinkage, and inflammatory infiltration (Figure 2).

	Control group ($p < 0.0001$)	Pyrazole group ($p < 0.0001$)	Silver nanoparticles ($p < 0.03$)	Pyrazole and Ascorbic acid ($p < 0.0001$)	Ascorbic acid ($p < 0.0001$)	Fipronil ($p < 0.623$)	Fipronil and ascorbic acid ($p < 0.225$)	Fipronil and nanoparticle ($P < 0.426$)	Pyrazole and silver nanoparticles ($p < 0.0001$)
Week 1	55.66±5.89	32.00±1.52	75.00±12.05	40.00±1.15	39.66±0.88	51.00±7.76	73.66±10.72	75.33±6.38	39.33±1.76
Week 2	67.00±3.51	38.33±1.45	89.00±7.02	45.00±1.15	45.33±1.76	60.66±1.76	80.00±5.13	83.00±4.58	46.33±2.40
Week 3	98.66±3.84***	46.66±1.85***	115.0±20.42	49.66±1.20	52.66±2.33	52.00±5.29	90.33±5.60	77.66±2.84	69.66±1.20
Week 4	109.33±3.28***	51.66±2.60***	145.3±12.34*	58.66±0.66***	58.33±2.40***	51.66±6.64	94.00±4.58	85.33±3.52	75.00±1.52***

*** = Highly significant ($p < 0.0001$); * = Mild significant ($p < 0.05$)

Table 2 Renal function tests in differently treated animal groups

Group Nos.	Groups	Urea (mg/dl) ($p < 0.0001$)	Creatinine (mg/dl) ($p < 0.0001$)	Uric acid (mg/dl) ($p < 0.0001$)
1	Control	6.76±0.86 ^a	0.33±0.66 ^b	9.50±1.74
2	Pyrazole	23.4±0.63	0.45±0.01	14.0±0.81
3	Nano Particles	13.4±1.73**	0.33±0.03 ^b	8.30±1.21 ^{ns}

Protective Effects of Ascorbic Acid and Silver Nanoparticles against Pyrazole and Fipronil-Induced Kidney Toxicity in Gallus domesticus: A Comparative Study

4	Pyrazole & Ascorbic Acid	15.9±0.61**	0.22±0.04**	8.20±.734 ^{ns}
5	Ascorbic Acid	15.2±3.15**	0.19±0.02**	9.07±1.06 ^{ns}
6	Fipronil	28.1±3.15	0.56±0.04	18.9±0.84
7	Fipronil & Ascorbic Acid	7.46±1.37 ^a	0.20±0.05**	10.2±1.36*
8	AgNPs and Fipronil	9.40±1.87 ^{ab}	0.18±0.03**	9.10±0.85 ^{ns}
9	AgNPs and Pyrazole	17.16±0.58*	0.33±0.17 ^b	5.80±0.23**

a: gnificantly different from Control group

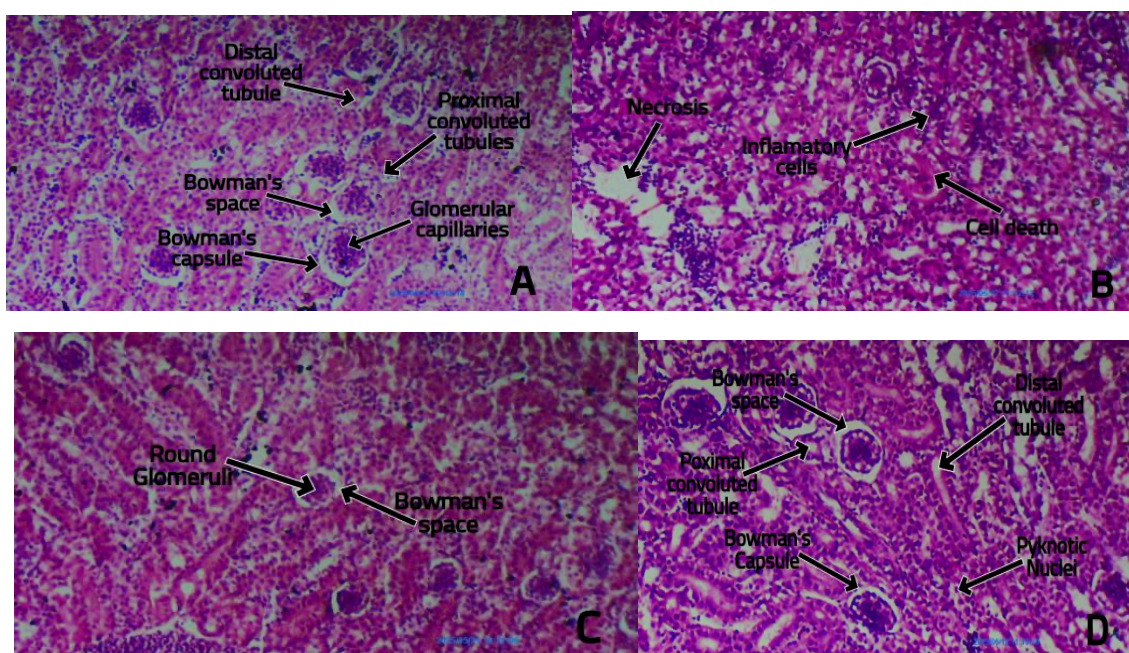
b: Significantly different from Fipronil group

*** Highly significant (p<0.0001); ** Significant (p<0.01); * Mild significant (p<0.05)

Table 3. Correlation across different parameters.

Parameters	Corelate to	Correlation Coefficient (r)	P value
Urea	Creatinine	0.723	0.0001***
Urea	Uric Acid	0.635	0.0001***
Creatinine	Uric Acid	0.643	0.0001***

*** = Highly Significant (p<0.0001)



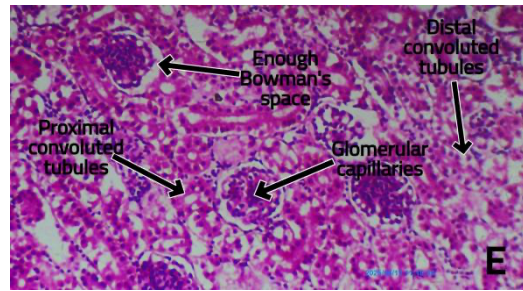


Figure 1: Histology of kidney tissue of animals exposed to different treatments

Fig A: Showing Control Group; Fig B: Showing Pyrazole Group;

Fig C: Showing Silver Nano Particle Group;

Fig D: Showing Pyrazole and Ascorbic Acid Group; Fig E: Showing Ascorbic Acid Group

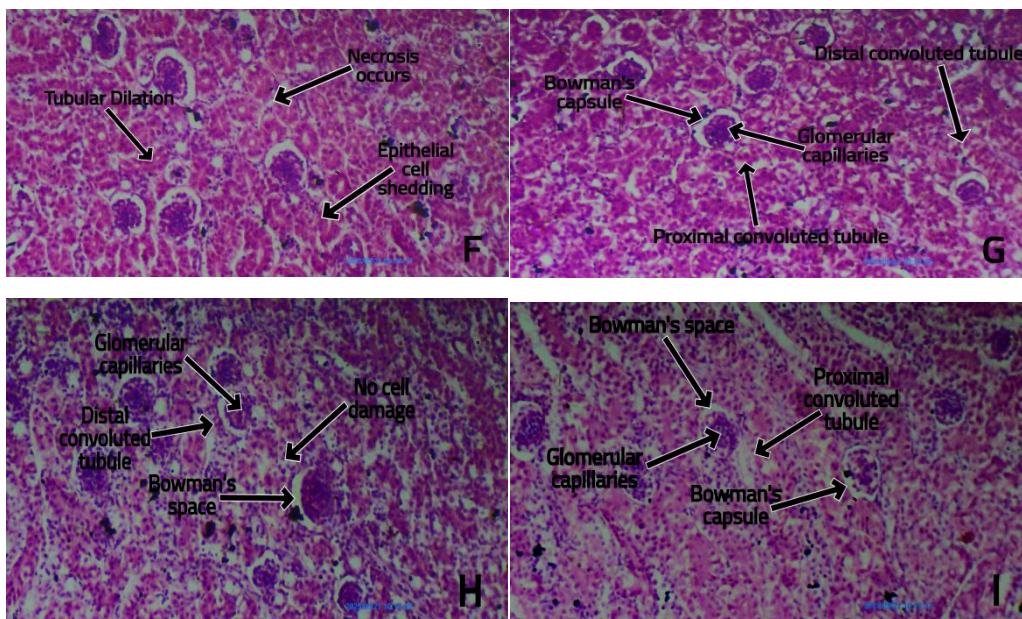


Figure 2: Histology of kidney tissue of animals exposed to different treatments

Fig F: Showing Fipronil Group; Fig G: Showing Fipronil and Ascorbic Acid Group;

Fig H: Showing Fipronil and Silver Nano Particles Group;

Fig I: Showing Pyrazole and Silver Nano Particle Gro

DISCUSSION

Body Weight

Researchers refers that when phenylpyrazole (fipronil) significantly decreased body weight (Khalil et al., 2019). Antioxidant like Vitamin C and ASA improved the growth and immunity (Ferronato et al., 2024). Poultry growth performance, feed intake, and food conversion ratio (FCR) are all positively affected by silver nano particles (Fouda et al., 2021). Silver nano particle also enhanced feed efficiency and growth performance (Khan et al., 2019). In our study, silver nanoparticles with pyrazole and fipronil improved body weight, showing protective effects.

Renal functions

Fipronil caused greater increase in urea, creatinine and uric acid than pyrazole, indicating severe nephrotoxicity (Bhatt et al., 2023). Based on the findings of Abdelgadir et al., (2020) findings, fipronil had a harmful effect on the liver, kidney and heart due to the pathological alterations in these organs (Abdelgadir et al., 2020). Animals treated with fipronil showed markedly elevated levels of creatinine, uric acid, and serum blood urea nitrogen (Uzunhisarcikli et al., 2023).

Currently, silver nanoparticles and ascorbic acid treated groups showed that kidney damage was prevented. In nano particles and ascorbic acid group urea, creatinine and uric acid level increased but up to accepted limit. It has been studied that without affecting broiler chickens liver and

kidney or feeding, nanoparticles coated on zeolite and with organic acid can be utilized as an additional supplement (Tavakoli et al., 2020). In present study, serum creatinine and uric acid levels significantly increased in ascorbic acid treated group. These findings shows that ascorbic acid has positive benefits and may lessen the nephrotoxicity of gentamicin (El-Sheshtawy et al., 2015).

In pyrazole and ascorbic acid and fipronil and ascorbic acid treated groups normal urea level indicated that ascorbic acid has a protective role. Administering ascorbic acid reduced the morphological harm that paraquat toxicity caused to the liver and kidney in male adult rats (Awadalla 2012).

In nanoparticles and fipronil and nano particles and Pyrazole treated group, urea, creatinine and uric acid level was increased but upto accepted limit which may explained that Nanoparticles may lower the toxicity caused due to pyrazole and fipronil. Additionally, Hendi (2011) demonstrated that silver nanoparticles improve wound healing by reducing inflammation, modulating certain liver and kidney processes and have antibacterial qualities. These findings have shed light on how silver works and offered a latest therapeutic approach for treating wounds in clinical settings (Hendi, 2011). Silver nanoparticles have been shown to boost immune responses and enhance livestock gut microbiota, which may lessen the requirement for antibiotics in animal husbandry (Fripiat et al., 2025).

Histological Examination

In our study, pyrazole and fipronil damaged the kidney tissues. Previously, a research on fish (Qureshi et al., 2016) found that all treatment groups' kidney tissue had substantial histomorphological changes when exposed to sub-acute dosages of fipronil, as compared to the control group. The primary changes seen in the kidneys of animals given dosages of LQFM021 (Pyrazole compound), include glomerular shrinkage, hemorrhagic foci, and a decrease in Bowman's space (Moura et al., 2017). Furthermore, mice given FPN 2.5, 5, and 10 mg/kg body weight, respectively, for 28 days showed notable histological changes in their brain and kidneys (Badgular et al., 2015).

Ascorbic acid supplementation reduced toxicity in the current study. In previous studies neurotoxicity of the pesticide combination and oxidative stress were considerably reduced by the vitamin C supplement (Robea et al., 2023). Ascorbic acid's antioxidant qualities probably lessened inflammation and oxidative damage that was dosage dependent (Reeves et al 2016).

Kidneys from mice who received silver nanoparticles concurrently had little necrosis, decreased inflammatory infiltration, and preserved renal architecture. This is consistent with other research showing protective role of silver nanoparticles as they promote tissue regeneration, hence preserving the structural integrity of renal tissues (Azzi et al., 2024). Recent investigations like Azzi et al. (2024) and Kumar et al. (2023), in which AgNPs made from plant extracts showed anti-nephrotoxic and anti-inflammatory qualities against chemically induced kidney damage, corroborate the findings.

The current study concludes that fipronil and pyrazole induced nephrotoxicity in broiler chicks. Ascorbic acid, alone or combined with fipronil and pyrazole showed

therapeutic strategy. Similarly silver nano particle also produced protective effects against fipronil and pyrazole pesticides. Addition of ascorbic acid to chicken feed is also recommended. It is recommended to extend the duration of exposure with increased number of animals. Use of molecular biology techniques is also suggested to explore the mechanism underlying the toxic effects of the studied pesticides.

Acknowledgements

The authors want to acknowledge Virtual University of Pakistan for providing silver nano particles and Chaudhary Muhammad Hussain Natt trust eye hospital for invaluable support for analysis of Renal Function Test. The study has been completed in histology lab, Zoology Department, Rawalpindi Women University upgraded by Turkish Cooperation and Coordination Agency (TIKA), Islamabad. We are grateful to TIKA for providing digital microscope, used in this study, in Zoology research lab, Rawalpindi Women University, Rawalpindi, Pakistan

REFERENCE

1. Abdelgadir, E. H., Al-Qudsi, J., Al-Saleh, L. N., & Emara, H. A. (2020). Sub-acute exposure of Fipronil induces biochemical and histopathological changes in the liver, kidney, and heart of male albino rats. *Journal of Forensic Toxicology & Pharmacology*, 9(4).
2. Adhikari, D., Agarwal, S. & Chandra, A. (2014). Effect of fipronil toxicity in haematological parameters in white leghorn cockerels. *African Journal of Agricultural Research*, 9(36): 2759- 2764.
3. Alam, M. J., Alam, O., Alam, P. and Naim, M. J. (2015). A review on pyrazole chemical entity and biological activity. *International Journal of Pharma Sciences and Research (IJPSR)*, 6: 1433-1442.
4. Almansour, M. I., Al-Otaibi, N. M., Alarifi, S. A., Ibrahim, S. A. & Jarra, B. M. (2008). Histological and histochemical alterations induced by lead in the kidney of the quail (*Coturnix coturnix*). *Saudi Journal of Biological Sciences*, 15(2): 307-313.
5. Awadalla, E. A. (2012). Efficacy of vitamin C against liver and kidney damage induced by paraquat toxicity. *Experimental and Toxicologic Pathology*, 64(5), 431-434.
6. Azzi, M., Laib, I., Bouafia, A., Medila, I., Tliba, A., Laouini, S. E., Alsaeedi, H., Cornu, D., Bechelany, M., & Barhoum, A. (2024). Antimutagenic and anticoagulant therapeutic effects of Ag/Ag₂O nanoparticles from *Olea europaea* leaf extract: Mitigating metribuzin-induced hepato- and nephrotoxicity. *Frontiers in Pharmacology*, 15, 1485525. <https://doi.org/10.3389/fphar.2024.1485525>
7. Badgular P.C., Pawar N.N., Chandratre G.A., Telang A.G., and Sharma A.K., 2015. Fipronil in duced oxidative stress in kidney and brain of mice: Protective effect of vitamin E and vitamin C. *Pesticide*

- Biochemistry and Physiology, 118, 10–18.
8. Bakke, O. M., Wardell, W. M., and Lasagna, L. (1984). Drug discontinuations in the United Kingdom and the United States, 1964 to 1983: issues of safety. *Clinical Pharmacology and Therapeutics*, 35(5): 559-567.
 9. Bera, A. K., Rana, T., Das, S., Bandyopadhyay, S., Bhattacharya, D., Pan, D., De, S. & Das, S. K. (2010). L-Ascorbate protects rat hepatocytes against sodium arsenite- induced cytotoxicity and oxidative damage. *Human and Experimental Toxicology*, 29(2): 103–111.
 10. Bhatt, P., Gangola, S., Ramola, S., Bilal, M., Bhatt, K., Huang, Y., Zhou, Z., & Chen, S. (2023). Insights into the toxicity and biodegradation of fipronil in contaminated environment. *Microbiological Research*, 266, 127247.
 11. Birla, S. S., Tiwari, V. V., Gade, A. K., Ingle, A. P., Yadav, A. P., & Rai, M. K. (2009). Fabrication of silver nanoparticles by *Phoma glomerata* and its combined effect against *Escherichia coli*, *Pseudomonas aeruginosa* and *Staphylococcus aureus*. *Letters in Applied Microbiology*, 48(2), 173-179.
 12. Chaguri, J. L., Godinho, A. F., Horta, D. F., Goncalves-Rizzi, V. H., Possomato- Vieira, J. S., Nascimento, R. A. & Dias-Junior, C. A. (2016). Exposure to fipronil elevates systolic blood pressure and disturbs related biomarkers in plasma of rats. *Environmental Toxicology and Pharmacology*, 42: 63-68.
 13. Chen, D., Li, J., Zhao, Y. and Wu, Y. (2021). Human exposure of fipronil insecticide and the associated health risk. *Journal of Agricultural and Food Chemistry*, 70(1): 63- 71.
 14. Corrias, F., Atzei, A., Taddeo, R., Arru, N., Casula, M., Salghi, R., Ruso, M. & Angioni, A. (2021). Fipronil and fipronil sulfone distribution in chicken feathers and eggs after oral and dermal exposure. *Foods*, 10(12): 3077-3092.
 15. De Tata, V., Brizzi, S., Saviozzi, M., Lazzarotti, A., Fierabracci, V., Malvaldi, G. and Casini, A. (2005). Protective role of dehydroascorbate in rat liver ischemia-reperfusion injury. *Journal of Surgical Research*, 123(2): 215-221.
 16. Eicher, T., Hauptmann, S. & Speicher, A. (2003). Five-membered heterocycles. *The Chemistry of Heterocycles*, 2: 61-79.
 17. El-Sheshtawy, S. M., Al-Shap, N. F., & Shehab, G. G. (2015). Effect of Vitamin C on gentamicin induced nephrotoxicity in broiler chicks. *Egyptian Journal of Chemistry and Environmental Health*, 1(1): 715-728.
 18. Ferronato, G., Tavakoli, M., Bouyeh, M., Seidavi, A., Suárez Ramírez, L., & Prandini, A. (2024). Effects of combinations of dietary vitamin C and acetylsalicylic acid on growth performance, carcass traits and, serum and immune response parameters in broilers. *Animals*, 14(4): 649.
 19. Fouda, M. M. G., Dosoky, W. M., Radwan, N. S., Abdelsalam, N. R., Taha, A. E., & Khafaga, A. F. (2021). Oral administration of silver nanoparticles–adorned starch as a growth promotor in poultry: Immunological and histopathological study. *International Journal of Biological Macromolecules*, 187, 830–839.
 20. Frippiat, T., Art, T., & Delguste, C. (2025). Silver nanoparticles as antimicrobial agents in veterinary medicine: current applications and future perspectives. *Nanomaterials*, 15(3), 202.
 21. Hassan, M. A., Rahaman, M. T., Parvez, N. H., Al Ferdous, K. & Sarkar, S. (2023) Biochemical and histopathological alterations of liver and kidney of Japanese quails due to lead toxicity and effects of vitamin C. *Journal of Advanced Biotechnology and Experimental Therapeutics*, 7(1): 157-166.
 22. Hendi, A. (2011). Silver nanoparticles mediate differential responses in some of liver and kidney functions during skin wound healing. *Journal of King Saud University-Science*, 23(1), 47-52.
 23. Heriba, S., Alhemmal, E., Ameen, N. & Abudabos, A. (2020). Toxic impact of lead acetate on histopathological alterations of kidney in the local quail (*coturnix sp.*) and the ameliorative role of vitamin C supplementation. *Journal of Veterinary and Marine Sciences*, 3(1): 132-135.
 24. Huy, T. Q., Huyen, P., Le, A. T., and Tonezzer, M. (2020). Recent advances of silver nanoparticles in cancer diagnosis and treatment. *Anti-Cancer Agents in Medicinal Chemistry (Formerly Current Medicinal Chemistry-Anti-Cancer Agents)*, 20(11): 1276-1287.
 25. Khalil, S. R., Mohammed, W. A., Zagloul, A. W., Elhady, W. M. & Farag, M. R. (2019). Inflammatory and oxidative injury is induced in cardiac and pulmonary tissue following fipronil exposure in Japanese quail: mRNA expression of the genes encoding interleukin 6, nuclear factor kappa B, and tumor necrosis factor-alpha. *Environmental Pollution*, 251: 564-572.
 26. Khan, A., Sharaf, R., Zargham Khan, M., Kashif Saleemi, M. & Mahmood, F. (2019). Arsenic toxicity in broiler chicks and its alleviation with ascorbic acid: A Toxic- patho-biochemical study. *International Journal of Agriculture & Biology*, 15(6): 1105-1111.
 27. Korkmaz, A., & Kolankaya, D. (2009). The protective effects of ascorbic acid against renal ischemia-reperfusion injury in male rats. *Renal Failure*, 31(1), 36–43. <https://doi.org/10.1080/08860220802546271>
 28. Kumar, S. R., Anusha, R., Sathish, S., Rugmini, R.,

- Sekhar, K. C., & Ibrahim, A. S. (2023). Anti-nephrotoxic effect of green synthesized *Actinopteria radiata* silver nanoparticles (AR-AgNPs) against gentamicin-induced nephrotoxicity. *Inorganic Chemistry Communications*, 157, 111244.
29. Merwe, D., Jordaan, A. and Berg, M. (2019). Case report: Fipronil contamination of chickens in the Netherlands and surrounding countries. In *Chemical Hazards in Foods of Animal Origin*, 567-584.
30. Molyneux, C. A., Glyn, M. C. and Ward, B. J. (2002). Oxidative stress & cardiac microvascular structure in ischemia/reperfusion: The protective effect of antioxidant vitamins. *Microvascular Research*. 64(2): 265–277.
31. Mossaa, A. H., Swelam, E. S., & Mohafrash, S. M. (2015). Sub-chronic exposure to fipronil induced oxidative stress, biochemical and histopathological changes in the liver and kidney of male albino rats. *Toxicology Reports*, 2, 775–784. <https://doi.org/10.1016/j.toxrep.2015.05.007>
32. Moura, S. S. de, Ávila, R. I. de, Brito, L. B., de Oliveira, R., Oliveira, G. A. R. de, Pazini, F., Menegatti, R., Batista, A. C., Grisolia, C. K., & Valadares, M. C. (2017). In vitro genotoxicity and in vivo subchronic evaluation of the anti-inflammatory pyrazole compound LQFM021. *Chemico-Biological Interactions*, 277, 185–194. <https://doi.org/10.1016/j.cbi.2017.08.012>
33. Muhamad, M., Ab. Rahim, N., Wan Omar, W. A., & Nik Mohamed Kamal, N. N. S. (2022). Cytotoxicity and Genotoxicity of Biogenic Silver Nanoparticles in A549 and BEAS-2B Cell Lines. *Bioinorganic Chemistry and Applications*, 2022(1), 8546079.
34. Qureshi I.Z., Bibi A., Shahid S., & Ghazanfar M., (2016). Exposure to sub-acute doses of fipronil and buprofezin in combination or alone induces biochemical, hematological, histopathological and genotoxic damage in common carp (*Cyprinus carpio* L.), *Aquatic Toxicology* 179:103–114.
35. Ravetti, S., Clemente, C., Brignone, S., Hergert, L., Allemandi, D., & Palma, S. (2019). Ascorbic acid in skin health. *Cosmetics*, 6(4), 58.
36. Reeves, D. J., Saum, L. M., & Birhiray, R. (2016). IV ascorbic acid for treatment of apparent rasburicase-induced methemoglobinemia in a patient with acute kidney injury and assumed glucose-6-phosphate dehydrogenase deficiency. *American Journal of Health-System Pharmacy*, 73(9), 238–242.
37. Ruzza, M., Tiozzo, B., Rizzoli, V., Giaretta, M., D'Este, L. & Ravarotto, L. (2020). Food risks on the web: Analysis of the 2017 fipronil alert in the Italian online information sources. *Risk Analysis*, 40(10): 2071–2092.
38. Taha, M. O., Souza, H. S., Carvalho, C. A., Fagundes, D. J., Simoes, M. J., Novo, N. F. & Caricati-Neto, A. (2004). Cytoprotective effects of ascorbic acid on the ischemia-reperfusion injury of rat liver. In *Transplantation Proceedings*, 36(2): 296-300.
39. Takáč, P., Michalková, R., Čižmáriková, M., Bedlovičová, Z., Balážová, L., & Takáčová, G. (2023). The role of silver nanoparticles in the diagnosis and treatment of cancer: Are there any perspectives for the future?. *Life*, 13(2), 466.
40. Tavakoli, R., Hashemi, S. R., Davoodi, D., Jafari, Y., & Hassani, S. (2020). Histopathologic investigation of liver and kidney tissues in broiler chickens fed silver nanoparticles coated on zeolite. *Animal Science Research*, 30(2), 15-23.
41. Traikovitch, S. S. (1999). Use of topical ascorbic acid and its effects on photodamaged skin topography. *Archives of Otolaryngology–Head & Neck Surgery*, 125(10), 1091–1098.
42. Unal, D., Yeni, E., Erel, O., Bitiren, M., & Vural, H. (2002). Antioxidative effects of exogenous nitric oxide versus antioxidant vitamins on renal ischemia reperfusion injury. *Urological Research*, 30(3), 190–194.
43. Uzunhisarcikli, M., Apaydin, F. G., Bas, H., & Kalender, Y. (2023). The ameliorative effects of quercetin and curcumin against subacute nephrotoxicity of fipronil induced in Wistar rats. *Toxicology Research*, 12(3), 493-502.
44. Wright, J. B., Lam, K., Hansen, D., & Burrell, R. E. (1999). Efficacy of topical silver against fungal burn wound pathogens. *American journal of infection control*, 27(4), 344-350.
45. Yu, S. J., Yin, Y. G., and Liu, J. F. (2013). Silver nanoparticles in the environment. *Environmental Science: Processes & Impacts*, 15(1), 78-92.
46. Zhang, Q., Wang, X., Wang, Q., Qi, D., Huang, Y., Chen, R., Shan, Y. & Fang, W. (2023). Toxicological effects of fipronil on laying hens and its residue elimination in eggs. *Environmental Science and Pollution Research*, 30(7): 19304-19312