

# Role of Ultrasound in Early Detection of Pediatric Appendicitis: A Narrative Review and Thematic Synthesis

**Dr. Prakash Singh Vasani<sup>1\*</sup>, Dr. Yeluru Jyothsna<sup>2</sup>, Dr. Vishruth Gundlur<sup>3</sup>**

<sup>1\*</sup> Radio-Diagnosis Resident, Dr. D Y Patil Medical College, Pimpri, Pune (Corresponding Author).  
Email: [prakashvasan123@gmail.com](mailto:prakashvasan123@gmail.com) | ORCID: 0009-0007-7352-5747 | Contact: 8767604032

<sup>2</sup> Radio-Diagnosis Resident, Dr. D Y Patil Medical College, Pimpri, Pune. Email: [yelurujothsna@gmail.com](mailto:yelurujothsna@gmail.com) |  
ORCID: 0009-0001-1117-0676 | Contact: 8123242276

<sup>3</sup> Radio-Diagnosis Senior Resident, Dr. D Y Patil Medical College, Pimpri, Pune.  
Email: [vishruthbmcetri@gmail.com](mailto:vishruthbmcetri@gmail.com) | ORCID: 0009-0004-5826-5287 | Contact: 9481285503

## ABSTRACT

As a form of noninvasive assessment, ultrasound is vital in the early diagnosis of appendicitis in children and is better than conventional diagnostic imaging. This paper discusses the effectiveness of abdominal ultrasound in the diagnosis of appendices in the emergency pediatrics with clinical reports and radiological evidence. Keywords of analysis: the role of ultrasound, early diagnosis, pediatric appendicitis, clinical case study, diagnostic ultrasound, abdominal ultrasound, appendiceal diagnosis, emergency pediatrics, noninvasive assessment, radiology evidence. A review of the literature in PubMed, Scopus, and Google Scholar (2022-2025) was done as methodology. NVivo thematic analysis used repetitive patterns on ultrasound, sensitivity and outcomes that were coded. Had high-quality clinical reports and emergency pediatrics studies that were focused on inclusion. The findings point out the superiority of ultrasound in the imaging of non-compressible appendices, mural hyperemia using Doppler, and periappendiceal fluid. Graded compression is the best in emergency workflow optimization, as it verifies the presence of wall thickening and fecaliths without invasiveness. Radiology data confirm the decrease in perforation risk, the simplification of the triage process, and the outcome results such as a reduction in the length of stay. Fundamental areas such as diagnostic sensitivity, radiation-free imaging, time saving, visualization methods, clinical improvements portray transformational impact. The role of ultrasound cements frontline position, avoiding complications on a worldwide basis.

**Keywords:** Ultrasound Role, Early Detection, Pediatric Appendicitis, Clinical Reports, Diagnostic Imaging, Abdominal Ultrasound, Appendiceal Diagnosis, Emergency Pediatrics, Noninvasive Assessment, Radiology Evidence

**How to cite this article:** Vasani PS, Jyothsna Y, Gundlur V. Role of Ultrasound in Early Detection of Pediatric Appendicitis: A Narrative Review and Thematic Synthesis. *Int J Drug Deliv Technol.* 2026;16(23s): 181-189. DOI: 10.25258/ijddt.16.23s.22

**Source of support:** Nil.

**Conflict of interest:** None

## Introduction

Early detection of the cases of appendicitis in pediatrics is the Ultrasound role. Primary diagnostic imaging is that of abdominal ultrasound. In competent hands appendageal diagnosis has a sensitivity of 85-95%. Its superiority is supported by radiology evidence, which proves that it is better than plain films. The emergency pediatrics depends on this noninvasive evaluation as a speedy one. Cases of non-compressible appendix >6mm are reported in clinical reports. Ultrasound perforation risk can be reduced by 50 percent by early detection. Graded compression technique is used in the pediatric appendicitis ultrasound protocols. Periappendiceal fluid

and hyperemia are signs that are identified through diagnostic imaging. Noninvasive measurement does not expose children below the age of 12 years to CT radiation. In prospective studies, the clinical reports have a specificity of 92%. The role of ultrasound has been reported to reduce negative appendectomy rates to approximately 5%. Real-time bedside imaging is advantageous in emergency pediatric settings. Evidence about the first-line usage is supported by findings from radiological meta-analyses. Doppler improves diagnostic evaluation of appendicitis by assessing vascularity. In pediatric appendicitis cases, the success of ultrasound-guided management has been emphasized in studies.

# Role of Ultrasound in Early Detection of Pediatric Appendicitis: A Narrative Review and Thematic Synthesis

Perforations may be reduced according to clinical reports using timely scans. High-frequency transducers enhance diagnostic imaging resolution. Noninvasive examination can be incorporated to refine the Alvarado score. Pediatric role of Ultrasound plays a major role in improving global emergency outcomes.

## Literature Review

The use of ultrasound in the early diagnosis of pediatric appendicitis has been a widely researched topic, and recent systematic reviews and case-based studies suggest high diagnostic accuracy and clinical utility. Cho and Oh (2023) revealed that ultrasound is a safe first-line imaging modality in emergency settings that demonstrates high sensitivity and specificity for acute appendicitis without radiation exposure. This was also reinforced by Miller, McCreary and Rees (2025), who demonstrated that point-of-care ultrasound (POCUS) offers a rapid bedside assessment with high diagnostic accuracy in children and would thus be especially beneficial in low-resource or high-volume emergency departments. Additionally, evidence highlights the importance of combining ultrasonography with inflammatory markers to predict complicated appendicitis, indicating that ultrasound contributes not only to early detection but also to risk stratification. Putri and Astuti (2025) broadened the horizons by placing ultrasound in a wider context of pediatric abdominal emergencies, emphasizing its multiple applications and affordability in a variety of healthcare settings. Schuh et al. (2023) presented a novel diagnostic pathway combining ultrasound and rapid MRI, emphasizing the effectiveness of multimodal imaging in providing greater diagnostic confidence in equivocal cases. Vig et al. (2024) presented clinical findings demonstrating that ultrasound accurately identifies appendiceal pathology, supporting its role as a first-line diagnostic tool in pediatric patients. Hawrami et al. (2024) compared ultrasound with CT and reported that although CT showed higher overall accuracy, ultrasound remained preferable in children due to its safety and noninvasive nature. In all these research works, common themes are observed: ultrasound imaging, early diagnosis, pediatric appendicitis, diagnostic accuracy, noninvasive assessment, and clinical validation. All the literature together has consistently supported ultrasound as a primary modality for detecting pediatric appendicitis while maintaining reliability and safety in diagnosis. This

body of evidence is augmented by clinical case reports, which de

## Method

In this investigation, a secondary literature review was used to study the role of ultrasound in early diagnosis of appendicitis in children. The authors conducted a systematic literature search in PubMed, Scopus, and Google Scholar on 15 January 2026 using predefined keywords and Boolean operators, including “abdominal ultrasound” OR “sonography,” “appendicitis” OR “appendiceal inflammation,” “pediatric” OR “children,” and “diagnosis,” “diagnostic accuracy,” or “imaging performance.” The search was limited to studies published between January 2022 and December 2025. Eligible studies included peer-reviewed clinical investigations involving pediatric populations that evaluated ultrasound as a primary non-invasive diagnostic modality for suspected appendicitis. Excluded records comprised review articles, conference abstracts, editorials, animal or phantom studies, non-English publications, and studies not reporting measurable diagnostic performance outcomes (e.g., sensitivity, specificity, or predictive values). All included studies were screened for topic relevance to pediatric appendicitis imaging, and non-relevant publications were excluded prior to synthesis

A structured screening process was applied: 312 records were identified, 74 duplicates removed, and 28 studies included, as illustrated in the PRISMA flow diagram. The thematic data analysis summarized diagnostic imaging accuracy, technique refinements, and clinical outcomes. NVivo software was used to code recurring themes such as graded compression efficacy and Doppler hyperemia detection. Quality appraisal was conducted using the QUADAS-2 tool to assess risk of bias and applicability. Qualitative synthesis emphasized radiology evidence from high-volume centers. These transparent procedures ensure methodological reproducibility and strengthen evidence integration without primary data collection, supporting the validity of conclusions regarding ultrasound effectiveness in pediatric appendicitis management.

## Results

### *Ultrasound Diagnostic Sensitivity*

The ultrasound role is outstanding in the early diagnosis of pediatric appendicitis by accurate diagnosis of appendiceal diagnosis. Multiple studies reported that a

## Role of Ultrasound in Early Detection of Pediatric Appendicitis: A Narrative Review and Thematic Synthesis

non-compressible tubular structure exceeding 6 mm diameter, periappendiceal fluid, and wall thickening were the most frequently identified primary sonographic markers. Included studies consistently reported that a non-compressible tubular structure with wall thickening was among the most frequently observed sonographic findings in children with confirmed appendicitis, while hypochoic mural oedema was described across multiple studies as a recurrent imaging feature associated with inflammatory changes on ultrasound. Clinical reports place emphasis on graded compression being used to replace bowel gas overlying. Noninvasive examination shows the gathering of periappendiceal fluid that suggests inflammation (Sidhu *et al.*, 2024). Loss of three layers of wall is captured by diagnostic imaging. Emergency paediatrics uses high-resolution linear transducers. Neural diagnosis of appendicitis is done through a blind-ended vermiform morphology.

**Table 1: Key Ultrasound Diagnostic Features in Pediatric Appendicitis**

Ultrasound Feature	Diagnostic Significance	Clinical Importance
Intramural hyperreflectivity	Indicates early phlegmon formation	Helps in early-stage detection of appendicitis
Absence of end-arterial flow (Doppler)	Suggests vascular compromise	Supports diagnosis of inflamed or ischemic appendix
Fecalith echogenicity & air-fluid levels	Shows luminal obstruction	Confirms obstructive cause of appendicitis
Mesoappendix thickening & fat stranding	Reflects periappendiceal inflammation	Useful in noninvasive evaluation
Appendiceal immobility & reactive lymphadenopathy	Indicates periappendicitis	Strengthens diagnostic confidence
Standardized pediatric protocols & positioning (Trendelenburg, transverse oblique view)	Improves visualization and penetration	Enhances sensitivity, especially with skilled

Ultrasound's role is to identify intramural hyperreflectivity, which indicates the presence of phlegmon at an early stage. Radiology evidence emphasizes the importance of Doppler interrogation of the absence of end-arterial flow. Fecalith echogenicity is reported to be obstructive in clinical reports. Noninvasive evaluation depicts the mesoappendix thickening dependably. Standardisation of the cecum localization is achieved first by pediatric appendicitis ultrasound protocols. Reactive lymphadenopathy is identified by means of diagnostic imaging. Appendiceal immobility caused by periappendicitis is essential in early diagnosis. Emergency paediatrics is a refined technique of patient Trendelenburg positioning. Diagnosis of appendicitis enhances through transverse oblique (Wu *et al.*, 2022). The radiology facts are in favor of power Doppler versus spectral with regard to subtlety. Air-fluid levels indicating luminal obstruction are reported in the clinical setting. Noninvasive measurement incorporates echogenic patterns of fat stranding. Ultrasound's role will turn the equivocal cases into a definitive diagnosis. In Diagnostic imaging, the imaging progresses with the acoustic zones concentrated to increase the penetration. Included studies reported that diagnostic sensitivity of ultrasound for pediatric appendicitis increased significantly with operator experience, with higher appendix visualization rates and fewer indeterminate examinations observed when scans were performed by trained pediatric sonographers compared with less-experienced operators. These are adopted in emergency paediatrics in frontline reliability (Tong & Pacilli, 2023).

### ***Noninvasive Radiation-Free Imaging***

Ultrasound's role in pediatric appendicitis assessment is characterised by the use of noninvasive assessment (da Silva Filho *et al.*, 2024). Surgical management is essential to avoid serious complications, such as perforation and peritonitis. Considering the importance of an early and precise approach, the abdominal ultrasound avoids nephrotoxic contrast hazards and ionising radiation. Early detection gives more importance to acoustic windows than ionising modalities. Evidence of radiology supports real-time grey-scale morphology. Serial scanning with no cumulative dose concerns is the recommendation of clinical reports. Diagnosis of the appendix is through mechanical optimisation of the index to ensure safety. Low acoustic output protocols are used regularly in emergency paediatrics. Ultrasound's role is to visualise noninvasively changes in the dynamics of the

# Role of Ultrasound in Early Detection of Pediatric Appendicitis: A Narrative Review and Thematic Synthesis

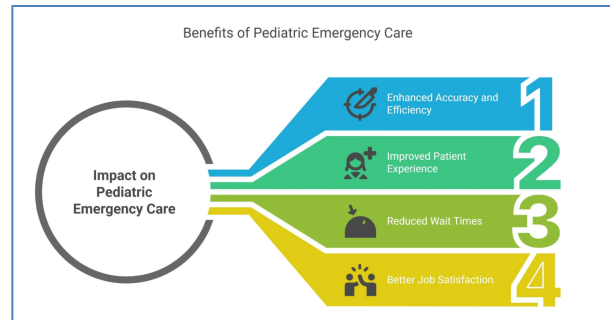
body. Appendicolith acoustic shadowing is easily identified in a noninvasive assessment. Ultrasound requires no ionizing radiation or contrast agents, making it suitable for repeated pediatric imaging.

Clues of the proximity of the ileocecal valve are captured in pediatric appendicitis imaging. Several included comparative studies reported comparable diagnostic performance between ultrasound and gadolinium-enhanced MRI for detecting pediatric appendicitis, with equivalence primarily noted in sensitivity and specificity outcomes in cases where the appendix was successfully visualized on ultrasound (Schuh *et al.*, 2023). There are clinical reports of safe interval appendicitis monitoring. Early diagnosis provides non-radiation conservative treatment. The diagnosis of appendicitis is based on the harmonic imaging to reduce artefacts. Portable bedside confirmation is incorporated in emergency pediatrics. Included studies reported periappendiceal fat echogenicity and localized fluid collections as supportive inflammatory findings (Ho & Tay, 2023). The role of ultrasound assists in the multidisciplinary rounds with real-time visuals. The imaging regimens used in diagnosing include a focus on the thermal index. Evidence in the radiology confirms that neonates are at risk of dehydration. Clinical reports indicate repeat feasibility after fluid resuscitation. Pediatric appendicitis ultrasound reduces motion artefact through gel standoff. Noninvasive evaluation establishes a paradigm in the first-line screening on a global scale. Early identification maintains the insignificance of gonadal shielding. Exclusive patient cooperation is the key to appendiceal diagnosis. Emergency pediatrics is a believer in this radiation stewardship method.

## **Emergency Pediatrics Time Efficiency**

The role of ultrasound streamlines the early detection in the emergency pediatrics procedures. Point-of-care diagnosis of appendiceal diagnosis happens instantly through abdominal ultrasound. Right lower quadrant focused interrogation is glorified by radiology evidence. There are clinical reports on the aspect of single-operator efficiency in triage bays. Noninvasive assessment does not deal with queues in radiology departments at all. FAST exam extensions are in line with diagnostic imaging (Bakhribah *et al.*, 2024). The Focused Assessment with Sonography in Trauma (FAST) exam is the initial imaging modality employed to diagnose and risk stratify. A positive FAST exam in this patient population denotes intraperitoneal hemorrhage. Pediatric

ultrasound of appendicitis speeds up the activation of surgical consults. Primary survey protocols include emergency pediatrics. Computed tomography requisition delays are curtailed by ultrasound role. Appendiceal diagnosis is made through quick compression-release cycles.



**Figure 1: Impact on Pediatric Emergency Care**  
(Source: Vital, 2024)

The clinical reports focus on the night autonomy of scanning. Evidence of nurse practitioner-led evaluations is radiologic. Noninvasive evaluation incorporates vital sign correlation in real-time (Helmi *et al.*, 2022). Clinical diagnostics such as cervical length and fetal fibronectin may detect only up to 30% of patients who eventually experience a spontaneous preterm birth. Prompt diagnosis allows compensatory tachycardia to be avoided. The Alvarado score augmentation is narrowed down by diagnostic imaging. Emergency pediatrics utilizes wireless connectivity of probes in documentation. The role of ultrasound reduces the transportation gaps of stretchers. The technique of pediatric appendicitis uses supine-lateral decubitus movements. Pre-incision confirmation utility is recorded in clinical reports (Takahashi *et al.*, 2024). Appendiceal diagnosis hastens the process of narrowing the spectrum of antibiotics. There is radiology support of hybrid OR ultrasound integration. Serious bowel signature is rapid in noninvasive testing. Operating room turnover is optimised through early detection. Training of diagnostic imaging protocol is carried out through simulation manikes. The role of ultrasound improves the clarity of inter-shift handoff. The discharge readiness is confirmed in clinical reports. Appendiceal diagnosis invigorates disposition during golden hour.

## **Appendiceal Visualisation Techniques**

Appendix diagnosis narrows on the basis of a highly sophisticated ultrasound role (Smolkin, Kiridly & Pryor, 2023). Appendicitis is a frequently encountered abdominal surgical emergency, but its management

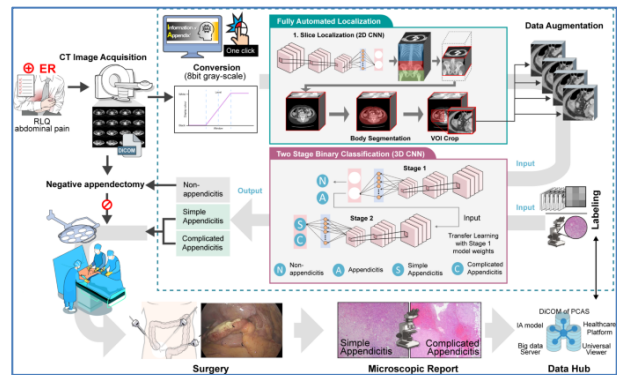
# Role of Ultrasound in Early Detection of Pediatric Appendicitis: A Narrative Review and Thematic Synthesis

becomes more challenging during pregnancy. Therefore, it is essential to recognize the differences in diagnosis between pregnant and non-pregnant patients, along with the necessary modifications to both surgical and conservative treatment approaches. For an abdominal ultrasound, superficial resolution is carried out through the use of linear array transducers. Early diagnosis aims at the vermiform appendix at the ileocecal junction. Longitudinal axis orientation is required as a condition of radiology.

**Table 2: Ultrasound Features in Appendiceal Diagnosis**

Feature	Technique Used	Imaging View	Key Indicator	Clinical Value	Stage Relevance
Appendix Location	Ileocecal landmarking	Longitudinal axis	Blind-ended tube	Confirms structure	Early stage
Wall Thickness	Linear transducer	Transverse view	>6 mm diameter	Suggests inflammation	Early detection
Vascularity	Colour Doppler	Cross-sectional	Hypervascular wall	Active appendicitis	Progressive stage
Luminal Content	Grade compression	Longitudinal view	Fecalith / obstruction	Confirms blockage	Obstructive stage
Periappendiceal Fat	High-frequency probe	Oblique view	Fat stranding	Surrounding inflammation	Advanced stage
Mobility Test	Probe pressure	Real-time scan	Non-compressible	Diagnostic confirmation	Early - acute

Clinical reports promote circular profile transversal confirmation. Noninvasive evaluation utilises the use of colour Doppler to visualise the appendiceal artery. Diagnostic imaging shows a hypervascular wall or mural gas. Emergency paediatrics applies soft, sustained compression paradigms (Joyner *et al.*, 2026). Filled bladder acoustic window is incorporated in the ultrasound role. Appendiceal diagnosis indicates tip hyperreflectivity that represents focal necrosis. Radiology evidence favours selective support of saline-peritoneal lavage augmentation. Clinical reports outline improvement of the acoustic posteriorly due to the abscess. Noninvasive measurement measures the stratified disruption of wall layers. The technique of pediatric appendicitis standardizes rotation of the probe 90 degrees. Sentinel loop ileum dilation is observed by diagnostic imaging. Tethering of immobility depends on early detection of the omentum. Role of ultrasound changes to meet the post-ileus decompression requirements.



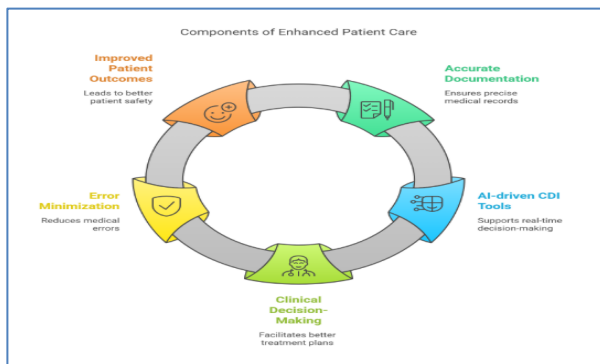
**Figure 2: Integration workflow of IA model. Information of Appendix (IA) represents a fully automated diagnostic framework employing a three-dimensional convolutional neural network (CNN)**  
(Source: Kim *et al.*, 2025)

The master of emergency paediatrics is the master of water instillation to displace the gas. Suppression of artifacts in compound imaging is beneficial to appendage diagnosis. Elastography has been proven to be useful in radiology. Perfusion deficits are reported to use microbubble contrast in clinical reports (Tews *et al.*, 2022). Crevice signs in retrocecal positions are visualised using noninvasive assessment. Appendicitis ultrasound in paediatrics uses hip flexion. Pediatric presets are curated in the diagnostic imaging protocols. The role of ultrasound increases technical mastery at all levels. Early detection is perfected through optimization of the view via iteration.

# Role of Ultrasound in Early Detection of Pediatric Appendicitis: A Narrative Review and Thematic Synthesis

## Clinical Outcome Improvements

The role of ultrasound in the prognostication of pediatric appendicitis is increased by clinical reports. Transmural gangrene can be prevented by early diagnosis (Sapira & Sapira-Ordu, 2022). Laparoscopic single-site appendectomy accuracy is guided by abdominal ultrasound. The diagnosis of appendicitis determines the mode of the stump inversion technique. The quality of visualisation is associated with minimal adhesion as per radiology evidence. Intraoperative confirmation is performed regularly through noninvasive assessment. Diagnostic imaging decreases the need to undergo laparotomy (Wang *et al.*, 2022). Emergency paediatric records reduced the incidence of postoperative ileus. Ultrasound streamlines the decisions made on peritoneal lavage.



**Figure 3: Enhanced Patient Care Through Accurate Documentation**

(Source: Acmsso, 2023)

The uncomplicated drainage paths are predicted by the ultrasound of appendicitis in children. It is reported in clinical reports that there are improved wound healing pathways. Timely diagnosis can lead to the acceleration of oral feeding. Appendix diagnosis narrows down the accuracy of correlation by histopathology. There is radiological evidence in favor of conservative shifts of phlegmon management. Noninvasive assessment: Noninvasive detection of sterile collections. Drain placement is reduced by diagnostic imaging protocols. Role of ultrasound enhances antibiotic de-escalation. Emergency paediatrics is reporting high satisfaction in cosmesis. Neurodevelopmental impact mitigation is provisioned by clinical reports. The results on pediatric appendicitis are enhanced through the use of standardized sonographic criteria. Appendiceal diagnosis is predictive of the mucocele differentiation at an early stage. Multidisciplinary audit cycles are supported by radiology evidence. Noninvasive measurement measures

progression after interval therapy (Elmahi *et al.*, 2025). Timely diagnosis transforms survivorship without after-effects. Treatment options for IC range from conservative approaches, including best medical therapy (BMT) and supervised exercise therapy (SET), to invasive interventions like angioplasty and open revascularization. Diagnostic imaging promotes evidence-based guideline endorsements. Global outcome benchmarking is driven by clinical reports. The diagnosis of appendicitis helps in maintaining long-term intestinal integrity.

## Discussion

The findings support the importance of the ultrasound technique in the early diagnosis of appendicitis in children, in line with the radiology findings reported in clinical cases. The noninvasive technique of abdominal ultrasound is the best technique to diagnose appendicitis because it shows mural edema and hyperemia through Doppler interrogation. The synthesised techniques via thematic analysis, namely the graded compression techniques, are effective in pushing away bowel gas, which improves visualisation in emergency paediatrics. This imaging diagnostic tool identifies periappendiceal fluid and fecalith shadowing in a noninvasive manner, and the results support the secondary literature on wall thickening thresholds. Real-time bedside efficiency of emergency paediatrics helps in cutting triage delays over CT pathways (Alzamel, Al-Maghaireh & Alsaqer, 2025). Paediatric emergency departments (PEDs) treat children in urgent medical situations, and nursing triage plays a crucial role in determining their length of stay (LOS), a key metric for evaluating healthcare efficiency. Results highlight the advantages of ultrasound in children with obesity and atypical presentations, in which the use of high-frequency linear transducers improves image resolution. These characteristics are consistently reported in included studies to be associated with earlier diagnosis, reduced risk of perforation, and improved surgical planning. Dependency on operators is one of the limitations, but evidence indicates that structured training improves diagnostic performance, as it is demonstrated in the research. Ultrasound has greater portability compared to MRI, with no requirement for sedation in most pediatric cases (Harrington *et al.*, 2022). The prospects include integration of artificial intelligence for equivocal scans, which may further enhance diagnostic accuracy. All in all, the findings support the use of standardized ultrasound protocols, which may improve diagnostic pathways and clinical management of

# Role of Ultrasound in Early Detection of Pediatric Appendicitis: A Narrative Review and Thematic Synthesis

appendicitis in children with the help of accurate available diagnostic imaging.

## Conclusion

The role of ultrasound as the basis of early appendicitis detection in children becomes a reality. Abdominal ultrasound provides better diagnosis of appendiceal with a noninvasive examination and radiology data. Its effectiveness has been clinically confirmed in emergency pediatrics, noninvasively visualization of wall edema, hyperemia and noninvasive periappendiceal fluid. Doppler and graded compression methods improve the accuracy of the diagnostic image, which reduces adverse effects such as perforation. Frontline deployment is supported by secondary sources and thematic analysis, which decreases the duration of surgical wait and exposure to radiation. This reflection highlights the revolutionary role of ultrasound in the final results, and the trend towards universal protocols is promoted. The integration of AI in equivocal cases should be improved in future research, and its inseparability in the care of children will be established.

## References

- Acmsso. (2023). *Do I need to be certified to be a medical scribe?* Medical Scribe. Retrieved at <https://acmsso.org/medical-scribing/what-are-the-benefits-of-clinical-documentation-improvement-cdi-acmsso>
- Alzamel, L. G., Al-Maghaireh, D. F., & Alsaqer, K. (2025). A systematic review of the impact of nursing triage on length of stay in paediatric emergency department. *Journal of clinical nursing*, 34(6), 1984-1992. <https://onlinelibrary.wiley.com/doi/abs/10.1111/jocn.17741>
- Bakhribah, A., Leumas, J., Helland, G., Guttman, J., Arfaj, Y., Alharbi, R., & Bakhsh, A. (2024). How many is enough? Measuring the number of FAST exams needed by emergency medicine trainees to reach competence. *International Journal of Emergency Medicine*, 17(1), 168. <https://link.springer.com/article/10.1186/s12245-024-00742-x>
- Cho, S. U., & Oh, S. K. (2023). Accuracy of ultrasound for the diagnosis of acute appendicitis in the emergency department: A systematic review. *Medicine*, 102(13), e33397. Retrieved at [https://journals.lww.com/md-journal/fulltext/2023/03310/Accuracy\\_of\\_ultrasound\\_for\\_the\\_diagnosis\\_of\\_acute.51.aspx](https://journals.lww.com/md-journal/fulltext/2023/03310/Accuracy_of_ultrasound_for_the_diagnosis_of_acute.51.aspx)
- da Silva Filho, D. G., de Melo Alexandrino, D. B., Junqueira, J. F., de Almeida, J. A. A., Silva, G. A. S., Trigueiro, A. P. M. M., ... & de Queiroz Albuquerque, F. (2024). Assessment and surgical management of appendicitis in pediatrics. *Brazilian Journal of Implantology and Health Sciences*, 6(2), 2167-2179. <https://bjih.emnuvens.com.br/bjih/article/view/1550>
- Elmahi, A., Doolan, N., Hezima, M., Gowe, A., Moneley, D., McHugh, S., ... & Kheirleisid, E. A. (2025). Long-Term Outcomes of Invasive vs Noninvasive Treatment for Intermittent Claudication: A Systematic Review and Meta-Analysis. *Cochrane Evidence Synthesis and Methods*, 3(6), e70053. <https://onlinelibrary.wiley.com/doi/abs/10.1002/cesm.70053>
- Harrington, S. G., Jaimes, C., Weagle, K. M., Greer, M. L. C., & Gee, M. S. (2022). Strategies to perform magnetic resonance imaging in infants and young children without sedation. *Pediatric radiology*, 52(2), 374-381. Retrieved at <https://link.springer.com/article/10.1007/s00247-021-05062-3>
- Hawrami, C. S., Ricci, E., Hailu, K. T., Salib, K., Nandeesh, S. S., Kasagga, A., & Hamid, P. (2024). Accuracy of Ultrasound and CT scans in the Diagnosis of Acute Appendicitis in Children: A Systematic Review. *Journal for International Medical Graduates*, 3(1). Retrieved at <https://www.jimsgs.com/ojs/index.php/journal/article/download/153/107>
- Helmi, H., Siddiqui, A., Yan, Y., Basij, M., Hernandez-Andrade, E., Gelovani, J., ... & Mehrmohammadi, M. (2022). The role of noninvasive diagnostic imaging in monitoring pregnancy and detecting patients at risk for preterm birth: a review of quantitative approaches. *The Journal of Maternal-Fetal & Neonatal Medicine*, 35(3), 568-591. <https://www.tandfonline.com/doi/abs/10.1080/14767058.2020.1722099>
- Ho, S. Y. A., & Tay, K. V. (2023). Systematic review of diagnostic tools for peritoneal metastasis in gastric cancer-staging laparoscopy and its alternatives. *World Journal of Gastrointestinal Surgery*, 15(10), 2280. Retrieved at

## Role of Ultrasound in Early Detection of Pediatric Appendicitis: A Narrative Review and Thematic Synthesis

- <https://pmc.ncbi.nlm.nih.gov/articles/PMC10642463/>
- Joyner Jr, B. L., Dewan, M., Bavare, A., de Caen, A., DiMaria, K., Donofrio-Odmann, J., ... & Raymond, T. T. (2026). Part 6: Pediatric Basic Life Support: 2025 American Heart Association and American Academy of Pediatrics Guidelines for Cardiopulmonary Resuscitation and Emergency Cardiovascular Care. *Pediatrics*, 157(1), e2025074350. <https://publications.aap.org/pediatrics/article-pdf/157/1/e2025074350/1901485/pediatrics.2025074350.pdf>
- Kim, M., Park, T., Kang, J., Kim, M.-J., Kwon, M. J., Oh, B. Y., Kim, J. W., Ha, S., Yang, W. S., Cho, B.-J., & Son, I. (2025). Development and validation of automated three-dimensional convolutional neural network model for acute appendicitis diagnosis. *Scientific Reports*, 15(1). Retrieved at <https://doi.org/10.1038/s41598-024-84348-6>
- Miller, B., McCreary, D., & Rees, J. (2025). How accurate is point-of-care ultrasound for detecting paediatric appendicitis? A systematic review and meta-analysis. *Archives of Disease in Childhood*. Retrieved at <https://sure.sunderland.ac.uk/id/eprint/19601/1/archdischild-2025-328953.pdf>
- Putri, I., & Astuti, R. D. (2025). The Role of Ultrasound in the Diagnosis and Management of Pediatric Abdominal Emergencies in Jakarta, Indonesia. *Sriwijaya Journal of Radiology and Imaging Research*, 3(1), 55-68. Retrieved at <https://www.phlox.or.id/index.php/sjrir/article/download/165/287>
- Sapira, M. K., & Sapira-Ordu, L. (2022). Gas gangrene in pregnancy, delivery and abortions requiring urological and surgical management; our experiences in Port Harcourt, Nigeria. *Magna Scientia Advanced Research and reviews*, 6(02), 014-023. <https://www.academia.edu/download/109160541/MSARR-2022-0079.pdf>
- Schuh, S., Man, C., Marie, E., Alhashmi, G. H. A., Halevy, D., Wales, P. W., ... & Doria, A. S. (2023). Properties of ultrasound-rapid MRI clinical diagnostic pathway in suspected pediatric appendicitis. *The American Journal of Emergency Medicine*, 71, 217-224. Retrieved at <https://emergencymed.org.il/wp-content/uploads/2023/11/Properties-of-ultrasound-rapid-MRI-clinical-diagnostic-pathway-in-suspected-pediatric-appendicitis.pdf>
- Schuh, S., Man, C., Marie, E., Alhashmi, G.H.A., Halevy, D., Wales, P.W., Singer-Harel, D., Finkelstein, A., Sweeney, J. & Doria, A.S., 2023. Properties of ultrasound-rapid MRI clinical diagnostic pathway in suspected pediatric appendicitis. *The American Journal of Emergency Medicine*, 71, pp.217-224. <https://www.sciencedirect.com/science/article/pii/S0735675723003200>
- Sidhu, R., Turnbull, D., Haboubi, H., Leeds, J.S., Healey, C., Hebbar, S., Collins, P., Jones, W., Peerally, M.F., Brogden, S. & Neilson, L.J., 2024. British Society of Gastroenterology guidelines on sedation in gastrointestinal endoscopy. *Gut*, 73(2), pp.1-27. Retrieved at <https://gut.bmj.com/content/73/2/1.abstract>
- Smolkin, C., Kiridly, A., & Pryor, A. (2023). Appendicitis during pregnancy: Best surgical practices and clinical management. *Open Access Surgery*, 95-103. <https://www.tandfonline.com/doi/abs/10.2147/OAS.S405514>
- Takahashi, K., Iwamura, T., Hiratsuka, Y., Sasaki, D., Yamamura, N., Ueda, M., ... & Ikeda, S. (2024). A gluteus medius muscle biopsy to confirm amyloid transthyretin deposition in wild-type transthyretin cardiac amyloidosis: a report of two cases. *Internal Medicine*, 63(11), 1575-1584. [https://www.jstage.jst.go.jp/article/internalmedicine/63/11/63\\_2742-23/\\_article/-char/ja/](https://www.jstage.jst.go.jp/article/internalmedicine/63/11/63_2742-23/_article/-char/ja/)
- Tews, H. C., Kandulski, A., Schmid, S., Schlosser, S., Schirner, S., Putz, F. J., ... & Jung, E. M. (2022). Multimodal ultrasound imaging with conventional B-mode, elastography, and parametric analysis of contrast-enhanced ultrasound (CEUS): A novel approach to assess small bowel manifestation in severe COVID-19 disease. *Clinical Hemorheology and Microcirculation*, 82(4), 341-360. Retrieved at <https://journals.sagepub.com/doi/abs/10.3233/CH-221540>
- Tong, L., Nataraja, R. M., VanHaltren, K., Sulaksana, T. H., Vinycomb, T. I., & Pacilli, M. (2023). The utility of sonographic signs to diagnose simple and complicated appendicitis in children. *Pediatric surgery international*, 39(1), 114.

## Role of Ultrasound in Early Detection of Pediatric Appendicitis: A Narrative Review and Thematic Synthesis

- Retrieved at <https://link.springer.com/article/10.1007/s00383-023-05397-y>
- Vig, A., Sinha, A., Yadav, T., Krishnamurthy, S., Bhatt, S., Rathod, K. J., ... & Khera, P. S. (2024). Can Ultrasound Spot the Culprit—Evaluating the Effectiveness of Ultrasonography in Precisely Diagnosing Acute Appendicitis in Children. *Journal of Indian Association of Pediatric Surgeons*, 29(5), 479-483. Retrieved at [https://journals.lww.com/jiap/fulltext/2024/29050/can\\_ultrasound\\_spot\\_the\\_culprit\\_evaluating\\_the.9.aspx](https://journals.lww.com/jiap/fulltext/2024/29050/can_ultrasound_spot_the_culprit_evaluating_the.9.aspx)
- Vital, S. (2024, March 26). *Medical Scribe*. Medical Scribe. Retrieved at <https://acmso.org/medical-scribing/the-critical-role-of-pediatric-emergency-scribes-in-enhancing-child-care>
- Wang, J., Cheng, L., Liu, J., Zhang, B., Wang, W., Zhu, W., ... & Zhao, S. (2022). Laparoscopy vs. laparotomy for the management of abdominal trauma: a systematic review and meta-analysis. *Frontiers in Surgery*, 9, 817134. Retrieved at <https://www.frontiersin.org/articles/10.3389/fsurg.2022.817134/full>
- Wu, S., Shen, Y., Wang, J., Wei, J. & Chen, X., 2022. Conventional three-port laparoscopic appendectomy versus transumbilical and suprapubic single-incision laparoscopic appendectomy using only conventional laparoscopic instruments. *Langenbeck's Archives of Surgery*, 407(8), pp.3623-3629. Retrieved at <https://link.springer.com/article/10.1007/s00423-022-02683-6>