

# A Retrospective Study On The Role Of Icg Fluorescence Imaging In Achieving The Critical View Of Safety During Laparoscopic Cholecystectomy

Dr. Siddharth Sethiya A<sup>1</sup>, Dr. Imran Thariq Ajmal<sup>2</sup>, Dr. Shahid Ibrahim<sup>3</sup>, Dr. Avinash Annamalai<sup>4\*</sup>

<sup>1</sup> Postgraduate, Department Of General Surgery, Chettinad Hospital And Research Institute, Chettinad Academy Of Research And Education, Kelambakkam-603103, Tamil Nadu, India.

<sup>2</sup> Professor, Department Of General Surgery, Chettinad Hospital And Research Institute, Chettinad Academy Of Research And Education, Kelambakkam-603103, Tamil Nadu, India.

<sup>3</sup> Assistant Professor, Department Of General Surgery, Chettinad Hospital And Research Institute, Chettinad Academy Of Research And Education, Kelambakkam-603103, Tamil Nadu, India.

<sup>4\*</sup> Assistant Professor, Department Of General Surgery, Chettinad Hospital And Research Institute, Chettinad Academy Of Research And Education, Kelambakkam-603103, Tamil Nadu, India.

**Corresponding Author:** Dr. Avinash Annamalai, Assistant Professor, Department Of General Surgery, Chettinad Hospital And Research Institute, Chettinad Academy Of Research And Education, Kelambakkam-603103, Tamil Nadu, India. Email: [dravinashannamalai@gmail.com](mailto:dravinashannamalai@gmail.com)

*Received: 20th Feb, 2026; Revised: 4th Mar, 2026; Accepted: 25th Mar, 2026; Available Online: 10th Apr, 2026*

## Abstract

**Background:** Laparoscopic cholecystectomy is the standard surgical procedure for gallstone disease, in which the bile duct injury remains as a serious complication, due to misidentification of biliary anatomy. Achieving the critical view of safety (cvs) is important to minimize such injuries, though it may be difficult in complicated cases. Indocyanine green (icg) fluorescence imaging improves real-time visualization of biliary structures without radiation exposure and might enhance the achievement of cvs.

**Objectives:** To compare the achievement of the critical view of safety and to assess the impact of icg fluorescence imaging between icg-assisted and conventional laparoscopic cholecystectomy.

**Methodology:** A retrospective cross-sectional study was conducted at a tertiary care teaching hospital in chennai by reviewing medical records of patients who underwent laparoscopic cholecystectomy between january 2023 and december 2025. Patients were categorized into icg-assisted and conventional laparoscopic cholecystectomy groups. Data on demographic variables, achievement of cvs, operative time, intraoperative complications, conversion to open surgery, bile duct injury, and postoperative hospital stay were collected. Statistical analysis was performed using welch's t-test and chi-square or fisher's exact test as appropriate, with significance set at  $p < 0.05$ .

**Results:** A total of 100 patients were included. The achievement of cvs was significantly higher in the icg group compared to the conventional group ( $p = 0.004$ ). The mean operative time and duration of hospital stay in both groups were  $53.44 \pm 9.05$  vs  $66.47 \pm 8.54$  and  $3.06 \pm 0.42$  vs  $4.30 \pm 0.86$  mins respectively, which were statistically significant.

**Conclusion:** Icg fluorescence imaging improves the achievement of the critical view of safety, reduces operative time, and reduces the hospital stay without increasing complications, supporting its role in laparoscopic cholecystectomy.

**Keywords:** Indocyanine Green, Laparoscopic Cholecystectomy, Critical View Of Safety, Bile Duct Injury, Fluorescence Imaging.

**How To Cite This Article:** Siddharth Sethiya A, Imran Thariq Ajmal, Shahid Ibrahim, Avinash Annamalai. A Retrospective Study On The Role Of Icg Fluorescence Imaging In Achieving The Critical View Of Safety During Laparoscopic Cholecystectomy. Int J Drug Deliv Technol. 2026;16(26s):644-651. Doi: 10.25258/ijddt.16.26s.70

## Introduction

Prevalence of gallstone disease is 6 to 20% in India (1). The most commonly used procedure for gall stone

## **A Retrospective Study On The Role Of Icg Fluorescence Imaging In Achieving The Critical View Of Safety During Laparoscopic Cholecystectomy**

disease is open cholecystectomy, but now a day laparoscopic cholecystectomy (LC) has been used as this surgical procedure provides advantages such as decreased postoperative pain, shorter hospitalization, faster resumption of full activity, and lower mortality rates (2). However, bile duct injury (BDI) remains a most complication in cholecystectomy, occurring in 0.3–1.8% of cases, leading to increased mortality rates of up to 20.8% (3). The most common reason for bile duct injury is difficulty in identifying the biliary anatomy (4). Various techniques have been adopted to prevent bile duct injury during LC, including intraoperative cholangiography, bailout surgery in complicating cases, and the establishment of the Critical View of Safety (CVS). The concept of CVS was introduced in the year 1995 (5). The CVS technique involves dissecting the triangle of Calot to remove fibrous and fatty tissue until the cystic artery and cystic duct are clearly identified before clipping and transection. Even though CVS technique has numerous benefits, also it has some disadvantages, such as limited experience among general surgeons, challenges in seeing the Calot's triangle in inflamed gallbladders, and occasional inability to establish CVS in such cases, Indocyanine green (ICG) is a water soluble tricarboyanine molecule approved by the US Food and Drug Administration (FDA) since the 1960s for safe administration without any adverse reaction. When exposed to near-infrared (NIR) light at 820 nanometres, ICG fluoresces, making it useful in gastrointestinal surgeries to minimize postoperative complications (3). After intravenous administration, ICG is excreted into bile and emits fluorescence when illuminated by near-infrared light, enabling a clear view of biliary structures without radiation exposure. Although several studies have been done across globally to evaluate the safety of ICG fluorescence imaging with critical view of safety, only very studies have been done in India, hence a retrospective cross sectional is done to compare the achievement of the Critical View of Safety between ICG assisted and conventional laparoscopic cholecystectomy and to assess the impact of ICG fluorescence imaging and its complications during ICG assisted and conventional laparoscopic cholecystectomy.

### **Methodology**

#### **Study Design**

A retrospective cross-sectional study was done to assess the role of indocyanine green (ICG) fluorescence imaging in achieving the Critical View of Safety (CVS) during laparoscopic cholecystectomy. Medical records of patients were reviewed over a

defined study period from January 2023 to December 2025.

#### **Study Setting**

This study was done in the Department of General Surgery of a tertiary care teaching medical college and hospital in Chennai

#### **Study Period**

Surgical data collected and stored during the period January 2023 – January 2026 were used for this research

#### **Study Population**

Data recorded and maintained from patients who underwent treatment in a tertiary care teaching medical college and hospital in Chennai, over the past couple of years (2023 - 2025).

#### **Inclusion Criteria**

- Adult patients more than 18 years of age underwent laparoscopic cholecystectomy for gallbladder disease using either ICG fluorescence or conventional white-light imaging

#### **Exclusion Criteria**

- Patients with missing or incomplete medical records relevant to the study variables
- Patients with acute cholecystitis, biliary pancreatitis, suspected bile duct stones and with abnormal liver function tests
- Patients with a history of previous upper abdominal open surgery, severe systemic illness, known adverse reaction to indocyanine green and pregnant women

#### **Sampling Method**

After obtaining approval from the institutional human ethics committee, we will retrieve the details of all patients who underwent ICG-assisted laparoscopic cholecystectomy and conventional laparoscopic cholecystectomy from hospital registers. All eligible records of patients which fulfilled the inclusion criteria and exclusion criteria were included in the study. Hospital records of those patients were retrospectively assessed for a period of one year. Patient data were obtained retrospectively from hospital records and surgical registers, with procedures identified using ICD-10 codes. Demographic details, operative findings, use of ICG fluorescence imaging, achievement of the Critical View of Safety, intraoperative complications, and postoperative outcomes were reviewed and recorded. Patients were categorized into two groups, ICG assisted laparoscopic cholecystectomy and conventional laparoscopic cholecystectomy. The postoperative outcomes of each

## A Retrospective Study On The Role Of Icg Fluorescence Imaging In Achieving The Critical View Of Safety During Laparoscopic Cholecystectomy

groups were compared and appropriate statistics were applied

### Surgical Technique

All patients underwent a standard four-port laparoscopic cholecystectomy under general anaesthesia. All patients were assessed for preoperative evaluation, which included: Complete blood count, liver function tests, renal function tests, Ultrasound abdomen for gallbladder and biliary anatomy, and a routine anaesthesia fitness assessment was done. Patients in Group A (ICG group) was given an intravenous injection of 2.5 mg (0.05 mg/kg) of Indocyanine Green (ICG) diluted in 10 mL of normal saline 45–60 minutes before skin incision to allow hepatic uptake and biliary excretion. A near-infrared (NIR) fluorescence imaging system was used to view the biliary anatomy. The cystic duct, common hepatic duct, and common bile duct were identified under fluorescence. The Critical View of Safety (CVS) was documented as achieved when: 1. Hepatocystic triangle was cleared of fat and fibrous tissue 2. Lower third of the gallbladder was separated from the liver bed 3. Only two structures (cystic duct and cystic artery) entered the gallbladder. Operative time, bile duct visualization rate, and complications that occurred were recorded and will be analysed and compared between the groups

### Data Collection

Data were collected retrospectively from hospital medical records, operative notes, and which included patient demographic details such as age and sex, indication for laparoscopic cholecystectomy, and imaging modality (ICG fluorescence or conventional white light) used during surgery. Intraoperative variables assessed included visualization of biliary anatomy, achievement of the Critical View of Safety, operative time, and intraoperative complications such as bile duct injury or bleeding. Postoperative variables which include duration of hospital stay, complications such as bile leak, surgical site infection, and pain

### Statistical Analysis

The data were arranged in excel sheet (MS365) and coded for analysis, which was carried out using SPSS software v.26. The descriptive results of the participants were tabulated in tables shown in frequency and percentages or means and standard deviation whichever relevant. The data when checked for normality between the groups using Shapiro wilk test showed significant p-value indicating non-normal distribution between the study groups. So further analysis for comparison between the groups were done using Welch's T Test and Chi-Square Test.

### Ethical Considerations

Ethical approval was obtained from the Institutional Human Ethics Committee. Patient confidentiality was strictly maintained, and data were anonymized during analysis.

### Results:

Table 1: The distribution of the participants based on their recorded values (n = 100)

Groups	Mean	Standard Deviation (SD)
Age (years)	55.23	±15.52
BMI	28.67	±4.81
Duration of Procedure (minutes)	59.96	±10.93
ASA Score	1.76	±0.62
Duration of Hospital Stay (days)	3.68	±0.92

Table 1 shows the distribution of study participants based on their age, BMI, mean surgery time, ASA score and their stay in the hospital.

Table 2: Distribution of participants based on their post-op history (n = 100)

Post-op Complaints	Outcome	Frequency	Percentage
Critical View of Safety (CVS) Achieved	No	14	14.0 %
	Yes	86	86.0 %
Conversion to Open	No	93	93.0 %
	Yes	7	7.0 %
Bile Duct Injury	No	98	98.0 %
	Yes	2	2.0 %

The above table shows the distribution of patients based on bile duct injury, conversion of surgery and achievement of critical view of safety (Table 2)

## A Retrospective Study On The Role Of Icg Fluorescence Imaging In Achieving The Critical View Of Safety During Laparoscopic Cholecystectomy

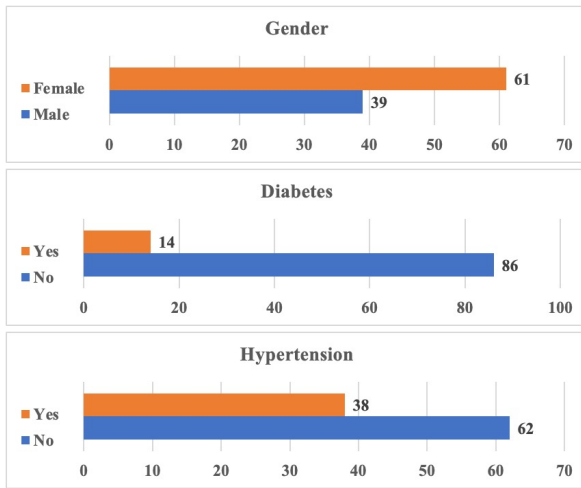


Figure 2: Distribution of the participants based on their gender, diabetes and hypertension among the participants (n = 100)

The above figure shows the distribution of the participants based on their co morbidities, which show that 14% are diabetic and 38% are hypertensive(Figure 2)

Table 3: Association between groups and operative parameters measured among the participants (n = 100)

Post-Op Complications			Group			p-value
			ICG Fluorescence	Conventional Method	Total	
CVS Achieved	No	N	2	12	14	.004
		%	14.3%	85.7%	100.0%	
	Yes	N	48	38	86	
		%	55.8%	44.2%	100.0%	
Conversion to Open	No	N	48	45	93	.218
		%	51.6%	48.4%	100.0%	
	Yes	N	2	5	7	
		%	28.6%	71.4%	100.0%	
		N	50	49	99	1

Bile Duct Injury	Yes	No	ICG Fluorescence	Conventional Method	Total
			N	N	N
			0	1	1
			0.0%	100.0%	100.0%

Fisher's Exact Test; Significant if p-value < 0.05

Table 3 reveals that CVS was achieved more in (48/50), also conversion to open surgery was observed in very few patients and bile duct injury was not observed in ICG assisted laparoscopic cholecystectomy

Table 4 shows that the time taken to do surgery and duration of stay in hospital is less in laparoscopic cholecystectomy in ICG group is less when compared with conventional laparoscopic cholecystectomy

Table 4: Comparison between the groups for difference in factors and outcomes (n = 100)

Score	Group	Mean	SD	p-value
Age	ICG Fluorescence	52.56	±14.82	.085
	Conventional Method	57.90	±15.89	
BMI	ICG Fluorescence	28.82	±4.63	.757
	Conventional Method	28.52	±5.02	
ASA Score	ICG Fluorescence	1.82	±0.62	.337
	Conventional Method	1.70	±0.61	
Duration of Procedure (Mins)	ICG Fluorescence	53.44	±9.05	<.001
	Conventional Method	66.47	±8.54	
Duration of Stay	ICG Fluorescence	3.06	±0.42	<.001
	Conventional Method	4.30	±0.86	

Welch's T Test; Significant if p-value < 0.05

## A Retrospective Study On The Role Of Icg Fluorescence Imaging In Achieving The Critical View Of Safety During Laparoscopic Cholecystectomy

### Discussion

Our study shows the mean age of patients who underwent surgery  $55.23 \pm 15.52$  years, mean BMI as  $28.67 \pm 4.81$  kg/m<sup>2</sup>, and the mean operative time as  $59.96 \pm 10.93$  minutes. On comparing our study results with the study done by Keeratbarat et al which reported the mean age as  $49.8 \pm 12.4$  years, mean BMI as  $24.9 \pm 2.9$  kg/m<sup>2</sup>, and mean operative time as  $61.7 \pm 20.6$  minutes. Similarly, Nouh et al. reported a lower mean age of  $40.5 \pm 11.5$  years, a higher mean BMI of  $31.92 \pm 3.94$  kg/m<sup>2</sup>, and a longer mean operative time of  $82.5 \pm 35.37$  minute<sup>(6,7)</sup>. The variation in BMI across studies may be due lifestyle factors, dietary habits, genetic predisposition, and population characteristics. Also the variation in operative time observed may be due to severity of the disease and experience of the surgeons. Our study shows that the mean age of patients who underwent ICG-assisted laparoscopic cholecystectomy was  $52.56 \pm 14.82$  years, whereas that of patients undergoing conventional laparoscopic cholecystectomy was  $57.90 \pm 15.89$  years. When compared with the studies done by A. Gangemi also showed the low mean age as  $40.75 \pm 15.44$  years in the laparoscopic cholecystectomy group and  $43.91 \pm 16.12$  years in the ICG-assisted group, also the study done by Nicholas C. Buhus et al shows it as  $47.3 \pm 11$  years in the ICG group and  $48.0 \pm 11.7$  years in the conventional group, similarly the study done by Ravikumar et al showed the mean age as  $47.8 \pm 17.3$  years for conventional laparoscopic cholecystectomy and  $43.6 \pm 16.4$  years for cholecystectomy with ICG assistance, whereas the study done by Symeonidis et al which shows the mean age in the ICG group as  $49.9 \pm 10.7$  years and the mean age in the non-ICG group as  $56.1 \pm 12.9$  years<sup>(8-11)</sup>. The higher mean age observed in our study when compared with other studies may be due to delayed health-seeking behaviour, prolonged conservative management, and limited awareness among the population surgery care in the Indian population, better health awareness, and routine ultrasonographic screening, resulting in cholecystectomy being performed at a later age.

On comparing the mean age of our study participants with the studies done by Jin et al which reported a higher mean ages in both groups ICG  $56.6 \pm 9.2$  years, conventional LC  $56.5 \pm 13.3$  years, and the study done by Losurdo et al also observed a higher mean age in ICG and non ICG group respectively ( $62 \pm 16$ ,  $62 \pm 15$  years)<sup>(12,13)</sup>. The higher mean age observed in these studies is due to differences in population demographics, including more geriatric patients,

referral patterns at tertiary care centers, and variations in healthcare systems.

Our study shows the mean body mass index (BMI) of patients undergoing ICG-assisted laparoscopic cholecystectomy and standard laparoscopic cholecystectomy  $28.82 \pm 4.63$  kg/m<sup>2</sup> and  $28.52 \pm 5.02$  kg/m<sup>2</sup> respectively. These findings of our study are in line with the studies done by Nicholas C. Buhus et al, which shows similar BMI values in both groups ( $27 \pm 4.7$  kg/m<sup>2</sup> in the ICG group and  $27 \pm 3.4$  kg/m<sup>2</sup> in the conventional group). In contrast, the studies done by A. Gangemi shows the mean BMI values as  $31.19 \pm 7.76$  kg/m<sup>2</sup> in the standard laparoscopic cholecystectomy group and  $32.28 \pm 8.57$  kg/m<sup>2</sup> in the ICG-assisted group, similarly the study done Ravikumar et al found the BMI values as  $32.0 \pm 7.3$  kg/m<sup>2</sup> for conventional laparoscopic cholecystectomy and  $31.1 \pm 7.3$  kg/m<sup>2</sup> for the group which used ICG during the surgery<sup>(8-10)</sup>. The difference in BMI variation noticed in our study and other published studies may be due to differences in demographics, lifestyle, and prevalence of obesity in the region, as well as differences in the dietary habits and activity levels of the population, with obese patients possibly being preferentially referred to the robotic centers.

Our study, shows the mean duration of surgery in ICG assisted laparoscopy group as  $53.44 \pm 9.05$  minutes and in conventional laparoscopy group as  $66.47 \pm 8.54$  minutes. Whereas the study done by by Nicholas C. Buhus et al shows the mean surgery time in the ICG group as  $85.2 \pm 21.5$  minutes and in conventional laparoscopy surgery as  $91.5 \pm 26$  minutes. Similarly, the study by Zhan Feng et al. (2025) showed an operative time of  $74.2 \pm 22.9$  minutes in the ICG group and  $69.9 \pm 18.3$  minutes in the non-ICG group<sup>(9,14)</sup>. The differences in mean operative times may be due to differences in case complexity, surgeon experience, and learning curve with ICG technology, surgical practices and patient selection, and the time required for injection of dye and fluorescence imaging setup in complicated case

In contrast comparing the result of our study with the studies done by Akeel et al showed the operative time in the ICG group as  $44.6 \pm 2.1$  minutes and in the non-ICG group as  $53.9 \pm 8.01$  minutes. Similarly the study done by Riya Shah et al showed the duration of surgery with ICG assistance as  $43.39 \pm 2.71$  minutes and without ICG as  $56.78 \pm 5.06$  minutes while the study done by Ravikumar et al also showed similar results as  $42.6 \pm 5.2$  minutes in the ICG group and  $48.3 \pm 6.1$  minutes in non ICG group<sup>(10,15,16)</sup>. The variations in operative time that have been observed in these studies

## A Retrospective Study On The Role Of Icg Fluorescence Imaging In Achieving The Critical View Of Safety During Laparoscopic Cholecystectomy

may be due to the better visualization of anatomical structures and the better definition of tissue planes, as well as the greater experience of the surgeons. In addition to these above mentioned studies have been performed in developed nations which might have led to variations in operative time due to increased access to advanced technology and innovative surgical instruments.

In our study, the mean duration of postoperative hospital stay following ICG-assisted laparoscopic cholecystectomy was  $3.06 \pm 0.42$  days, and in the conventional laparoscopy group it was  $4.30 \pm 0.86$  days. Whereas our study results are in line with the study done by Zhan Feng et al in China which showed the duration of stay in hospital in the ICG group as  $2.6 \pm 0.7$  days and in the non-ICG group as  $4.2 \pm 0.9$  days. Also the study done by Riya Shah et al in Nagpur showed the hospital stay in the ICG group as  $2.8 \pm 0.71$  days and in the non-ICG group as  $4.37 \pm 1.51$  days which are similar to our study. In contrast to our results the study done by Akeel et al which shows the hospital stay in the ICG group as  $1.25 \pm 0.3$  days and in the non-ICG group as  $1.39 \pm 0.7$  days. Similarly, the study done by Ravikumar et al also showed the length of stay with ICG assistance as  $1.6 \pm 4.3$  days and in conventional group as  $3.0 \pm 4.1$  days, which is very shorter stay in the hospital when compared with our study. Also the study done in Switzerland by Nicholas C. Buhus et al showed that hospital stay in ICG-assisted and conventional groups as  $1.1 \pm 0.6$  and  $1.1 \pm 0.8$  days respectively<sup>(9,14-16)</sup>. Overall on comparing all the studies it was found that the duration of stay in the hospital post-surgery has been reduced in ICG group, which supports the role of ICG-assisted techniques in facilitating earlier recovery and discharge, although some variability exists across studies. The longer postoperative hospital stay observed in our study may be due to discharge protocols followed in the hospitals, complications that patient develop following surgery, patient comorbidities, and might be due inclusion of more complicated cases

Only a limited number of studies have reported or compared ASA scores in patients undergoing ICG-assisted versus conventional laparoscopic cholecystectomy. In our study, the mean ASA score was  $1.82 \pm 0.62$  in the ICG-assisted group and  $1.70 \pm 0.61$  in the conventional group, indicating comparable preoperative anaesthetic risk between the two cohorts. These findings are consistent with those reported by Nicholas C. Buhus et al from Switzerland, who observed similar ASA scores in the ICG group ( $1.7 \pm 0.6$ ) and the conventional group ( $1.8 \pm 0.4$ )<sup>(9)</sup>. The fact

that the ASA scores are similar in both groups indicates that the perioperative outcomes are not likely to be affected by the differences in the comorbidity status, thus increasing the validity of the comparisons with respect to operative time, complications, and recovery. Furthermore, the fact that there is limited information on the ASA classification in the current literature highlights the importance of documenting the anaesthetic risk status in future studies.

Our study shows that conversion to open surgery was observed in 2 cases in the ICG-assisted group and in 5 cases in the conventional group, which shows that a lower conversion rate was seen in ICG group. On comparing our results with the study done by Akeel et al in Iraq, which showed that there were no conversions in the ICG group, while it was 4% in the conventional group. In contrast, the study done by Nicholas C. Buhus et al in Switzerland showed that there was no conversions in either group<sup>(9,15)</sup>. A slight increase in the conversion rate found in our study may be due to dense adhesions, chronic inflammation, and unclear biliary anatomy, late presentation of symptoms, advanced patient age and presence of comorbidities.

In our study, bile duct injury was observed in one case in the conventional laparoscopic cholecystectomy group, while no such injury has been reported in the ICG assisted group. On comparing with our study the studies done by Akeel et al and Zhan Feng et al reported zero bile duct injury rates in both the ICG and non-ICG groups<sup>(14,15)</sup>. Standardized surgical procedures, periodical surgical training, and enhanced intraoperative biliary mapping using ICG fluorescence or cholangiography appear to be the reason for absence of bile duct injury across all studies. Our study results recommend that the ICG assisted laparoscopic cholecystectomy has a better outcome than conventional methods as the ICG assisted laparoscopic cholecystectomy reduce the operative time, stay in hospital post surgery, reduced post operative complication and reduces conversion to open surgery

### Conclusion

Our study shows that ICG fluorescence imaging in laparoscopic cholecystectomy improves the achievement of the Critical View of Safety with shorter duration for surgery and reduced hospital stay when compared with conventional laparoscopic surgery. ICG use enhances biliary visualization without increasing complications, which suggest that ICG is a safe and effective for improving patient safety in laparoscopic cholecystectomy.

### References

## A Retrospective Study On The Role Of Icg Fluorescence Imaging In Achieving The Critical View Of Safety During Laparoscopic Cholecystectomy

1. Department of Health Research, Government of India. Health Technology Assessment on clinical effectiveness and cost-effectiveness of cholecystectomy. New Delhi: Health Technology Assessment in India (HTAI), Department of Health Research, Ministry of Health and Family Welfare; 2025. Available from: [https://htain.dhr.gov.in/images/pdf/Policy\\_Documents/25.HTA\\_on\\_clinical\\_effectiveness\\_and\\_cost-effectiveness\\_of\\_Cholecystectomy.pdf](https://htain.dhr.gov.in/images/pdf/Policy_Documents/25.HTA_on_clinical_effectiveness_and_cost-effectiveness_of_Cholecystectomy.pdf)
2. Chartkitchareon A, Tullavardhana T. Integrating critical view of safety and indocyanine green cholangiography to enhance safety in laparoscopic cholecystectomy: a retrospective cross-sectional study. *Sci Rep*. 2025 Jul 2;15(1):22566.
3. Tullavardhana T. The Integration of Critical View of Safety and Indocyanine Green Fluorescent Cholangiography to Enhance Patient Safety During Laparoscopic Cholecystectomy [Internet]. Preprints; 2024 [cited 2026 Jan 17]. Available from: <https://www.preprints.org/manuscript/202411.1561>
4. Patankar R, Mishra RK, Bindal V, Kothari CP, Rahate P, Patnaik S, et al. Efficacy of near-infrared fluorescence cholangiography using indocyanine green in laparoscopic cholecystectomy: A retrospective study. *Journal of Minimal Access Surgery*. 2023 Mar;19(1):57.
5. Cai Y, Chen Q, Cheng K, Chen Z, Wu S, Wu Z, et al. Intragallbladder versus intravenous indocyanine green (ICG) injection for enhanced bile duct visualization by fluorescent cholangiography during laparoscopic cholecystectomy: a retrospective cohort study. *Gland Surg*. 2024 Sep 30;13(9):1628–38.
6. Keeratibharat N. Initial experience of intraoperative fluorescent cholangiography during laparoscopic cholecystectomy: A retrospective study. *Annals of Medicine and Surgery* [Internet]. 2021 Aug [cited 2026 Feb 11];68. Available from: [https://journals.lww.com/annals-of-medicine-and-surgery/fulltext/2021/08000/initial\\_experience\\_of\\_intraoperative\\_fluorescent.27.aspx](https://journals.lww.com/annals-of-medicine-and-surgery/fulltext/2021/08000/initial_experience_of_intraoperative_fluorescent.27.aspx)
7. Nouh MA, Helmy AS, Abbas M, Nasr M, Esmat ME, Aziz SA, et al. Indocyanine Green as an Alternative to Intraoperative Cholangiogram to Delineate Extrahepatic Biliary Tract in Laparoscopic Cholecystectomy. *Surgery, Gastroenterology and Oncology*. 2024 Sep 30;29(3):219.
8. Gangemi A, Danilkowicz R, Elli FE, Bianco F, Masrur M, Giulianotti PC. Could ICG-aided robotic cholecystectomy reduce the rate of open conversion reported with laparoscopic approach? A head to head comparison of the largest single institution studies. *J Robotic Surg*. 2017 Mar;11(1):77–82.
9. Buchs NC, Pugin F, Azagury DE, Jung M, Volonte F, Hagen ME, et al. Real-time near-infrared fluorescent cholangiography could shorten operative time during robotic single-site cholecystectomy. *Surg Endosc*. 2013 Oct;27(10):3897–901.
10. Ravikumar S, Musham R, Rao GVV, Eppa VR, Ravikumar S, Musham R, et al. Impact of Indocyanine Green (ICG) Fluorescence Cholangiography on Operative Time and Safety in Laparoscopic Cholecystectomy: A Prospective Randomized Controlled Study. *Cureus* [Internet]. 2025 Jul 24 [cited 2026 Feb 1];17. Available from: <https://cureus.com/articles/378002-impact-of-indocyanine-green-icg-fluorescence-cholangiography-on-operative-time-and-safety-in-laparoscopic-cholecystectomy-a-prospective-randomized-controlled-study>
11. Symeonidis S, Mantzoros I, Anestiadou E, Ioannidis O, Christidis P, Bitsianis S, et al. Biliary Anatomy Visualization and Surgeon Satisfaction Using Standard Cholangiography versus Indocyanine Green Fluorescent Cholangiography during Elective Laparoscopic Cholecystectomy: A Randomized Controlled Trial. *Journal of Clinical Medicine* [Internet]. 2024 Feb 1 [cited 2026 Feb 10];13(3). Available from: <https://www.mdpi.com/2077-0383/13/3/864>
12. Jin H, Yang J, Lu L, Cui M. Propensity score matching between conventional laparoscopic cholecystectomy and indocyanine green cholangiography-guided laparoscopic cholecystectomy: observational study. *Lasers Med Sci*. 2022 Mar;37(2):1351–9.
13. Losurdo P, Giunta C, Modica A, de Manzini N, Bortul M. Near-infrared indocyanine green fluorescent cholangiography in urgent and emergency laparoscopic cholecystectomy: a preliminary study after propensity score-matched study. *Eur J Trauma Emerg Surg*. 2024 Feb 1;50(1):275–81.
14. Zhan F, Yang L, Zhang Y, Zhang Y, Zhang K, Jiang C. Single-port laparoscopic cholecystectomy with indocyanine green: A propensity score study. *Journal of Minimal Access Surgery*. :10.4103/jmas.jmas\_287\_24.
15. Akeel M, Al-Najjari I, Dawood A. Clinical Evaluation of Intraoperative Indocyanine Green (ICG) Fluorescent Cholangiography During

## **A Retrospective Study On The Role Of Icg Fluorescence Imaging In Achieving The Critical View Of Safety During Laparoscopic Cholecystectomy**

Laparoscopic Cholecystectomy: A Comparative Study. Iraqi National Journal of Medicine. 2026 Jan 15;8(1):1-6.

16. Shah R, Mitra A. Laparoscopic cholecystectomy with and without the use of indocyanine green fluoroscopy – a randomised controlled trial. Int J Med Sci Curr Res. 2025;8(3):408-417.