

Left Temporal Lobar Intracerebral Hemorrhage with Concomitant Subdural Hemorrhage and Negative Cerebral Angiography: A Case Report

Zavira Pramasita Widyanti Putri^{1,2}, Mohammad Saiful Ardhi^{1,2*}

¹ Department of Neurology, Faculty of Medicine, Universitas Airlangga, Surabaya, Indonesia.

² Department of Neurology, Dr. Soetomo General Academic Hospital, Surabaya, Indonesia.

* Corresponding Author: Mohammad Saiful Ardhi, Department of Neurology, Faculty of Medicine, Universitas Airlangga / Department of Neurology, Dr Soetomo General Academic Hospital, Jalan Prof. Dr. Moestopo No. 6-8, Surabaya, Indonesia 60286. Email: saifulardhie@fk.unair.ac.id
ORCID: Mohammad Saiful Ardhi - 0000-0002-8699-2631

Received: 28th Feb, 2026 | Revised: 14th Mar, 2026 | Accepted: 4th Apr, 2026 | Available Online: 20th Apr, 2026

ABSTRACT

Introduction: Intracerebral hemorrhage (ICH) is a neurological emergency associated with high morbidity and mortality. While hypertension remains the most common cause, atypical presentations—particularly in younger patients with lobar hemorrhage—require thorough evaluation to exclude secondary causes such as vascular malformations, coagulopathy, or trauma.

Case Report: We report a 44-year-old woman who was referred to Dr. Soetomo General Hospital with sudden decreased consciousness, accompanied by headache, nausea, and vomiting. Neurological examination on admission was unremarkable with a Glasgow Coma Scale score of 15. Initial non-contrast head computed tomography revealed a left temporal intracerebral hemorrhage with surrounding edema. Further evaluation with computed tomography angiography demonstrated lobar hemorrhage with perifocal edema causing midline shift, along with multiple subdural hemorrhages involving the temporo-occipital region and cerebellum, without evidence of aneurysm or arteriovenous malformation. Given the atypical location and imaging findings, digital subtraction angiography was performed and showed no vascular abnormalities. A detailed history later revealed a prior unwitnessed fall 15 days before admission, raising suspicion for traumatic etiology.

Discussion: Lobar ICH in younger patients without clear vascular abnormalities presents a diagnostic challenge. The coexistence of subdural hemorrhage and negative vascular imaging strongly suggests a traumatic mechanism, even in the absence of a clear history at initial presentation. Comprehensive evaluation using multimodal imaging, including CTA and DSA, is essential to exclude underlying vascular lesions. This case highlights the importance of integrating clinical history and radiological findings to determine the most probable etiology.

Keywords: Intracerebral hemorrhage, traumatic brain injury, lobar hemorrhage, subdural hemorrhage, cerebral angiography.

How to cite this article: Putri ZPW, Ardhi MS. Left Temporal Lobar Intracerebral Hemorrhage with Concomitant Subdural Hemorrhage and Negative Cerebral Angiography: A Case Report. *Int J Drug Deliv Technol.* 2026;16(30s):710-712. DOI: 10.25258/ijddt.16.30s.68

Source of support: Nil.

Conflict of interest: The authors declare no conflict of interest.

Introduction

Intracerebral hemorrhage (ICH) is a major subtype of stroke and remains one of the most devastating cerebrovascular emergencies because of its high rates of disability and mortality. Although it accounts for a smaller proportion of all strokes compared to ischemic stroke, ICH carries a disproportionately high case fatality rate, reaching up to 50% within the first 30 days. The incidence is estimated at approximately 10–30 per 100,000 persons annually worldwide(1).

Rapid etiologic assessment is essential because treatment and prognosis depend on the underlying cause. Non-contrast computed tomography is the first-line modality for confirming acute hemorrhage, while computed tomography angiography is commonly performed to identify an underlying vascular lesion. When CTA is unrevealing or when the hemorrhage pattern is atypical, magnetic resonance imaging and, in selected cases, digital subtraction angiography are useful to further clarify the etiology. In younger patients with lobar ICH, especially

Left Temporal Lobar Intracerebral Hemorrhage with Concomitant Subdural Hemorrhage and Negative Cerebral Angiography: A Case Report

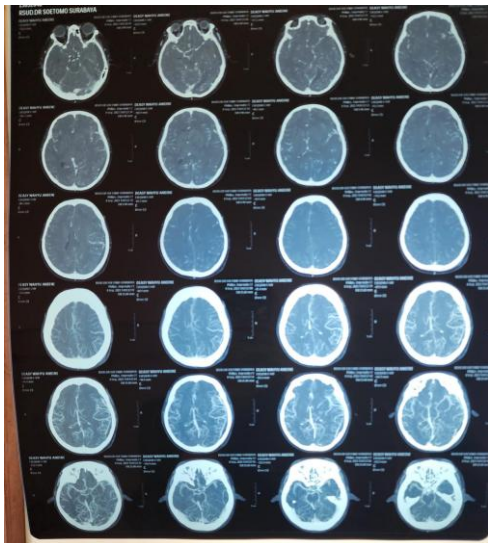
when extra-axial blood or a history of trauma is present, distinguishing spontaneous from traumatic hemorrhage is critical for accurate diagnosis and management. (2).

Case

A 44-year-old woman was referred to Dr. Soetomo General Hospital with sudden decreased consciousness. She had experienced an unwitnessed fall in the bathroom 15 days prior to admission. Associated symptoms included headache, nausea, and vomiting. There were no complaints of limb weakness, facial asymmetry, or speech disturbance. She had no prior history of hypertension, diabetes mellitus, stroke, trauma, infection, or malignancy.

On admission, vital signs were stable, with blood pressure 148/96 mmHg. Neurological examination revealed a Glasgow Coma Scale score of E4V5M6, with no focal neurological deficits. Cranial nerve, motor, sensory, cerebellar, and meningeal examinations were unremarkable.

Laboratory findings were largely within normal limits, except for leukocytosis ($14.41 \times 10^3/\mu\text{L}$) and thrombocytosis ($501 \times 10^3/\mu\text{L}$). Coagulation profile, renal function, liver enzymes, electrolytes, and arterial blood gas analysis were normal.



Non-contrast head computed tomography demonstrated a left temporal intracerebral hemorrhage with surrounding edema. Subsequent computed tomography angiography revealed a lobar hemorrhage measuring approximately $1.9 \times 1.0 \times 0.6 \text{ cm}$ (volume $\sim 0.59 \text{ cm}^3$), with perifocal edema causing a midline shift of 0.8 cm. Multiple subdural hemorrhages were also identified in the bilateral tentorium cerebelli, left temporo-occipital region, and left cerebellum. No aneurysm or arteriovenous malformation was detected. The secondary ICH (sICH) score was 5, suggesting a high probability of a vascular etiology.

Digital subtraction angiography was performed and showed normal cerebral vasculature without evidence of vascular malformation.

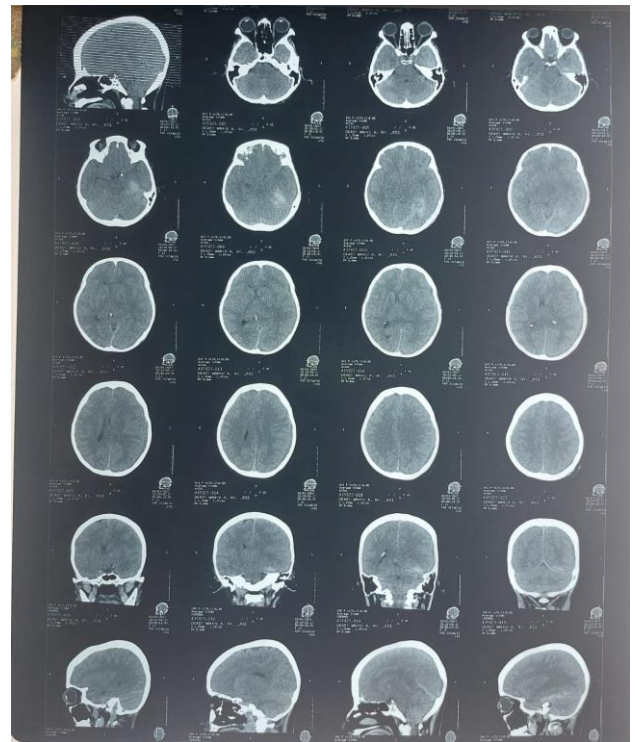


Figure 1. Non Contrast Head CT Scan

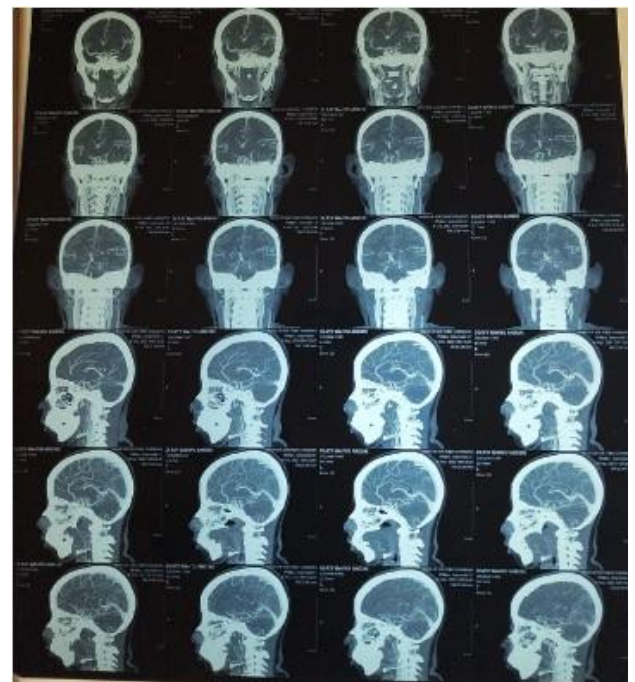

Figure 2. CT Angiography of the Head and Neck

Discussion

Intracerebral hemorrhage (ICH) can be broadly classified as spontaneous or secondary, including traumatic causes. Differentiating between these entities is clinically important, as the underlying etiology determines further

Left Temporal Lobar Intracerebral Hemorrhage with Concomitant Subdural Hemorrhage and Negative Cerebral Angiography: A Case Report

diagnostic evaluation and management. Spontaneous ICH is most commonly related to hypertension and typically involves deep brain structures, whereas lobar hemorrhage in younger patients should prompt evaluation for secondary causes such as vascular malformations or trauma (2–4).

In the present case, several findings were atypical for primary hypertensive ICH. The patient was relatively young, had no known history of hypertension, and presented with a lobar hemorrhage in the temporal region. In addition, the presence of multiple subdural hemorrhages suggested a traumatic mechanism. Although the history of trauma was not initially apparent, further history-taking revealed a prior unwitnessed fall, which became a key element in interpreting the clinical and radiological findings (2,3).

Neuroimaging plays a central role in the diagnostic work-up of ICH. Non-contrast CT remains the first-line modality for detecting acute hemorrhage, while CTA is commonly used to identify underlying vascular abnormalities. In cases with atypical features or high suspicion of secondary causes, further evaluation with digital subtraction angiography (DSA) is recommended due to its high sensitivity for detecting vascular lesions (2,4). In this patient, CTA did not demonstrate any aneurysm or arteriovenous malformation, and subsequent DSA revealed normal cerebral vasculature, making a macrovascular etiology unlikely.

This case is particularly instructive because the hemorrhage pattern did not fit well with classic hypertensive ICH. A left temporal lobar hematoma in a relatively young patient, together with concomitant subdural hemorrhages, should prompt consideration of a secondary cause rather than primary hypertensive bleeding. In this context, neuroimaging is not only confirmatory but also etiologically informative. While non-contrast CT establishes the diagnosis and CTA serves as an initial screening tool, negative findings on CTA and DSA should redirect attention toward alternative causes. MRI may further contribute by identifying occult etiologies such as cavernous malformation, venous thrombosis, hemorrhagic infarction, or underlying tumor (1,2).

Taken together, the combination of lobar hemorrhage, concomitant subdural bleeding, negative vascular imaging, and a compatible history supports traumatic intracerebral hemorrhage as the most probable diagnosis. This case underscores the importance of a systematic and integrative approach in evaluating atypical ICH, where careful clinicoradiological correlation is essential to avoid misclassification and ensure appropriate management.

Conclusion

Lobar intracerebral hemorrhage in younger patients requires careful evaluation for secondary causes,

particularly when imaging findings are atypical for hypertensive bleeding. A stepwise neuroimaging approach, combined with thorough clinical assessment, is essential to establish the most probable etiology. This case highlights the importance of clinicoradiological correlation in identifying traumatic ICH, especially when the history is initially unclear.

ACKNOWLEDGMENTS

Data availability statement

The data used to support the results are included in the study.

Funding

The authors received no financial support for the study, authorship, or publication of this case report.

Consent

Written informed consent was obtained from the patient for submission and publication of this case report and accompanying images.

Conflict of interest

The authors declared no conflict of interest.

REFERENCES

1. Magid-Bernstein J, Girard R, Polster S, Srinath A, Romanos S, Awad IA, dkk. Cerebral hemorrhage: Pathophysiology, treatment, and future directions. *Circ Res.* 2022;130(8):1204–29.
2. Schaefer PW, Edjlali M. Nontraumatic Intracranial Hemorrhage. 2024 Feb 11. In: Hodler J, Kubik-Huch RA, Roos JE, editors. *Diseases of the Brain, Head and Neck, Spine 2024-2027: Diagnostic Imaging* [Internet]. Cham (CH): Springer; 2024. Chapter 5. Available from: <https://www.ncbi.nlm.nih.gov/books/NBK608612/> doi: 10.1007/978-3-031-50675-8_5
3. Rocha E, Rouanet C, Reges D, Gagliardi V, Singhal AB, Silva GS. Intracerebral hemorrhage: Update and future directions. *Arq Neuropsiquiatr.* 2020;78(10):651–9.
4. Jain A, Malhotra A, Payabvash S. Imaging of Spontaneous Intracerebral Hemorrhage. *Neuroimaging Clin N Am.* 2021;31(2):193–203.
5. Powers WJ. Intracerebral hemorrhage and head trauma: Common effects and common mechanisms of injury. *Stroke.* 2010;41(10 SUPPL. 1):107–10.