

# Curvilinear Pericallosal Lipoma Presenting with Seizure: A CT-Based Diagnosis in a Resource-Limited Setting

Dr. Vijmohan Reddy Polureddy<sup>1</sup>, Dr. Sai Shankar M.G<sup>2</sup>, Dr. Harshavardhan Balaganesan<sup>3</sup>, Dr. Remya R<sup>4</sup>

<sup>1</sup>Junior Resident, Department of Radiodiagnosis, Shri Sathya Sai Medical College and Research Institute, Sri Balaji Vidyapeeth (Deemed to be University), Puducherry, India, ORCID: <https://orcid.org/0009-0009-6177-5540>, Email: [Vijmohan.reddy.polureddy@gmail.com](mailto:Vijmohan.reddy.polureddy@gmail.com)

<sup>2</sup>Associate professor, Department of Radiodiagnosis, Shri Sathya Sai Medical College and Research Institute, Sri Balaji Vidyapeeth (Deemed to be University), Puducherry, India, ORCID: <https://orcid.org/0000-0002-2420-1240>, Email: [vanhelsing250@gmail.com](mailto:vanhelsing250@gmail.com)

<sup>3</sup>Assistant Professor, Department of Radiodiagnosis, Shri Sathya Sai Medical College and Research Institute, Sri Balaji Vidyapeeth (Deemed to be University), Puducherry, India, ORCID: <https://orcid.org/0000-0001-7738-5154>, Email: [harshavardhanb@sssmcri.ac.in](mailto:harshavardhanb@sssmcri.ac.in)

<sup>4</sup>Assistant Professor, Department of Radiodiagnosis, Shri Sathya Sai Medical College and Research Institute, Sri Balaji Vidyapeeth (Deemed to be University), Puducherry, India, ORCID: <https://orcid.org/0000-0002-3893-0022>, Email: [drremya1986@gmail.com](mailto:drremya1986@gmail.com)

## Corresponding Author

Dr. Vijmohan Reddy Polureddy

Email ID: [Vijmohan.reddy.polureddy@gmail.com](mailto:Vijmohan.reddy.polureddy@gmail.com)

## Abstract

**Background:** Pericallosal lipomas are rare congenital malformations characterized by ectopic fat deposition adjacent to the corpus callosum. They are typically asymptomatic and incidentally detected on neuroimaging. Symptomatic presentation, particularly with seizures, is uncommon.

**Case Presentation:** A 62-year-old woman with a history of atrioventricular block presented with a generalized tonic-clonic seizure following a syncopal episode and minor head trauma. Non-contrast computed tomography (CT) of the brain revealed a curvilinear hypodense lesion in the pericallosal region with attenuation of approximately -70 Hounsfield units, consistent with fat. There was no associated corpus callosum dysgenesis or parenchymal abnormality. The patient was managed conservatively with antiepileptic therapy and remained seizure-free on follow-up.

**Conclusion:** Curvilinear pericallosal lipomas are rare benign lesions that can be confidently diagnosed on non-contrast CT based on their characteristic location and fat attenuation. Although typically asymptomatic, they may rarely present with seizures. Early recognition of this entity is essential to avoid unnecessary investigations and interventions, particularly in resource-limited settings where MRI may not be readily available. Conservative management remains the standard of care.

**Keywords:** Pericallosal lipoma, curvilinear lipoma, intracranial lipoma, seizure, CT brain, neuroimaging

**How to cite this article:** Polureddy VR, M.G SS, Balaganesan H, R R. Curvilinear Pericallosal Lipoma Presenting with Seizure: A CT-Based Diagnosis in a Resource-Limited Setting. *Int J Drug Deliv Technol.* 2026;16(34s):401-404. DOI: 10.25258/ijddt.16.34s.51

## INTRODUCTION

Intracranial lipomas are rare congenital lesions, accounting for less than 0.5% of all primary brain tumors. Among these, pericallosal lipomas represent the most common subtype and are frequently associated with abnormalities of the corpus callosum.

Two morphological variants are recognized:

- Tubulonodular type: bulky, anterior, and commonly associated with callosal dysgenesis
- Curvilinear type: thin, elongated, typically posterior, and less frequently associated with structural anomalies

Although most pericallosal lipomas are incidental findings, they may rarely present with seizures, headache, or neurodevelopmental abnormalities. While

magnetic resonance imaging (MRI) is considered the gold standard for evaluating intracranial lipomas, computed tomography (CT) plays a crucial role in their diagnosis, particularly in emergency and resource-limited settings. The presence of characteristic fat attenuation values on CT allows for confident identification, often obviating the need for further imaging. This case highlights the value of CT as a reliable standalone diagnostic modality in such scenarios.

## Case Report

A 62-year-old woman with a known history of atrioventricular block presented to the emergency department following a syncopal episode at home,

\*Author for Correspondence: [Vijmohan.reddy.polureddy@gmail.com](mailto:Vijmohan.reddy.polureddy@gmail.com)

# Curvilinear Pericallosal Lipoma Presenting with Seizure: A CT-Based Diagnosis in a Resource-Limited Setting

associated with minor head trauma. Subsequently, she developed a generalized tonic-clonic seizure witnessed by family members. There was no prior history of seizures.

On examination, the patient was hemodynamically stable, alert, and oriented. Neurological examination was unremarkable.

A non-contrast CT scan of the brain demonstrated :

- A well-defined, curvilinear hypodense lesion along the dorsal aspect of the corpus callosum
- Location within the interhemispheric fissure
- Attenuation of approximately -90 Hounsfield units, consistent with fat
- No evidence of hemorrhage, mass effect, midline shift, or hydrocephalus

The corpus callosum appeared morphologically normal, with no evidence of dysgenesis. No cortical malformations or other parenchymal abnormalities were identified.

The attenuation value of approximately -90 Hounsfield units was highly suggestive of fat, confirming the diagnosis on CT without the need for further imaging. Based on the characteristic imaging findings, a diagnosis of curvilinear pericallosal lipoma was made.

The patient was treated conservatively with levetiracetam. Her symptoms resolved, and she remained seizure-free at 3-month follow-up.

## Discussion

Intracranial lipomas are developmental anomalies arising from abnormal persistence and differentiation of the meninx primitiva during embryogenesis, rather than true neoplasms.

The pericallosal region is the most common location for intracranial lipomas. These lesions are frequently associated with corpus callosum abnormalities, particularly in the tubulonodular variant.

Curvilinear pericallosal lipomas are typically asymptomatic and are most often detected incidentally. Symptomatic presentation with seizures, as seen in this case, is rare and sparsely reported in the literature. When present, seizures are thought to result from associated cortical irritation or subtle cortical dysplasia, which may not always be evident on CT imaging.

While MRI provides superior soft tissue characterization and better delineation of associated anomalies, CT remains highly sensitive for detecting fat due to its characteristic negative attenuation values. In cases with typical imaging features, CT alone is sufficient for

diagnosis, thereby avoiding additional imaging costs and delays.

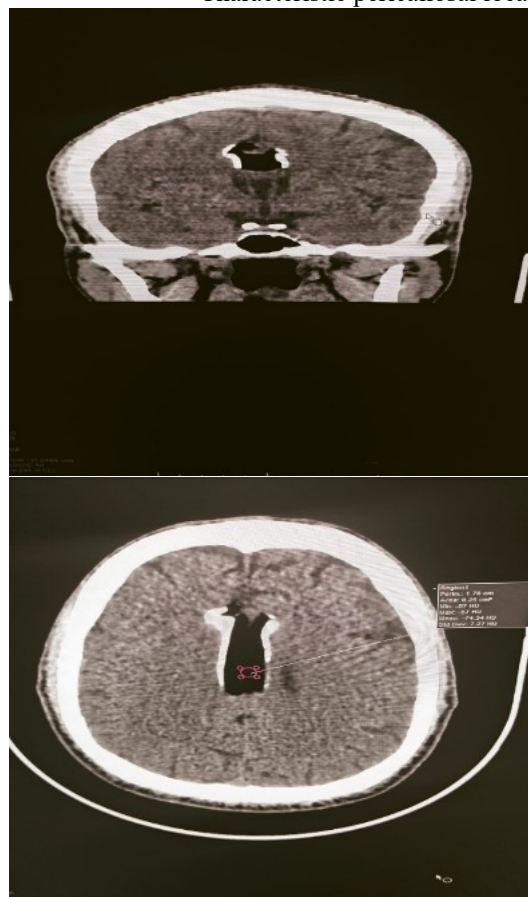The curvilinear variant, as observed in this case, is characterized by:

- Thin, elongated morphology
- Typical location along the dorsal/posterior corpus callosum
- Lower incidence of associated congenital anomalies
- Predominantly asymptomatic presentation

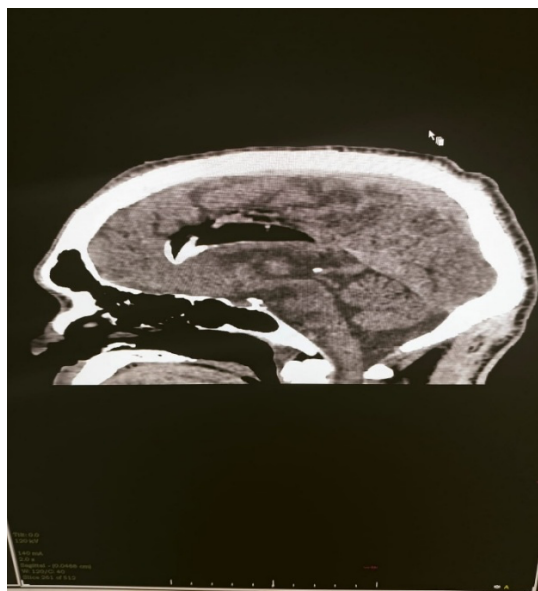
## Imaging Features

Computed Tomography (CT):

- Homogeneous hypodense lesion
- Fat attenuation ranging from -50 to -100 Hounsfield units
- Characteristic pericallosal location



## Curvilinear Pericallosal Lipoma Presenting with Seizure: A CT-Based Diagnosis in a Resource-Limited Setting



### Discussion

Intracranial lipomas are rare congenital malformations that arise due to abnormal persistence and differentiation of the meninx primitiva during embryogenesis, rather than representing true neoplastic processes [1]. This developmental origin has been consistently supported by radiological and pathological studies, which classify these lesions as malformative rather than proliferative in nature [2,4].

The pericallosal region is the most common site for intracranial lipomas, accounting for a significant proportion of reported cases [2]. These lesions are frequently associated with anomalies of the corpus callosum, particularly in the tubulonodular subtype, which is typically anterior and bulky [3,7]. In contrast, the curvilinear variant, as observed in the present case, is characterized by a thin, elongated morphology along the dorsal aspect of the corpus callosum and is less commonly associated with structural abnormalities [3].

Most pericallosal lipomas are asymptomatic and incidentally detected during neuroimaging performed for unrelated conditions [2,6]. Symptomatic presentation, particularly with seizures, is uncommon but has been documented in isolated case reports and small series [10,13]. In the present case, the patient presented with a generalized tonic-clonic seizure, highlighting a rare but clinically significant manifestation. The mechanism of seizure activity remains incompletely understood but is thought to be related to cortical irritation or associated subtle cortical dysplasia, which may not always be detectable on routine imaging [9,20].

Imaging plays a central role in the diagnosis of intracranial lipomas. Computed tomography (CT) is highly sensitive in identifying fat due to its characteristic negative attenuation values, typically ranging from  $-50$  to  $-100$  Hounsfield units [5,12]. In this case, the lesion demonstrated an attenuation value of approximately  $-70$  HU, which is diagnostic of fat and sufficient to establish the diagnosis. Studies have emphasized that CT alone can reliably confirm intracranial lipomas when characteristic features are present, particularly in

resource-limited settings where MRI may not be readily available [6,12].

Magnetic resonance imaging (MRI), while superior for soft tissue characterization, is primarily useful for evaluating associated anomalies such as corpus callosum dysgenesis or cortical malformations [8]. However, in cases with classical CT findings and no clinical suspicion of associated abnormalities, additional imaging may not be necessary. This reinforces the practical utility of CT as a standalone diagnostic modality in emergency and low-resource environments.

The differential diagnosis of fat-containing intracranial lesions includes dermoid cysts, lipomatous transformation of neoplasms, and subacute hemorrhage. Dermoid cysts typically demonstrate heterogeneous appearance with calcifications and may rupture, resulting in fat dissemination within subarachnoid spaces [5]. Lipomatous tumors usually contain mixed tissue components with enhancement, unlike the homogeneous fat attenuation seen in lipomas. Subacute hemorrhage, although occasionally hypodense, lacks the characteristic negative attenuation values and demonstrates temporal evolution on follow-up imaging [12]. Careful assessment of imaging characteristics allows reliable differentiation. Recent literature has expanded the clinical and radiological spectrum of intracranial lipomas, including rare presentations at atypical locations and associations with other congenital anomalies such as spinal dysraphism [17,18]. Larger clinical series have shown that the majority of intracranial lipomas remain asymptomatic and are managed conservatively [19]. Nevertheless, symptomatic cases presenting with seizures or headache continue to be reported, emphasizing the need for awareness among clinicians [15,16].

Management of intracranial lipomas is predominantly conservative due to their benign and non-progressive nature. Surgical intervention is generally avoided because of the lesion's proximity to critical neurovascular structures and the risk of complications [9]. In symptomatic patients, treatment is directed toward symptom control, particularly with antiepileptic medications in cases presenting with seizures [10]. The favorable clinical outcome observed in this case, with complete seizure control on medical therapy, is consistent with previously reported findings.

In summary, curvilinear pericallosal lipomas are rare benign congenital lesions that can be accurately diagnosed using CT when characteristic imaging features are present. Although typically incidental, they may rarely present with seizures. Early recognition of this entity is essential to avoid misdiagnosis, unnecessary investigations, and unwarranted surgical intervention, particularly in resource-limited settings. Conservative management remains the cornerstone of treatment with excellent clinical outcomes.

### Conclusion

Curvilinear pericallosal lipomas are rare congenital malformations that can be reliably identified on non-

# Curvilinear Pericallosal Lipoma Presenting with Seizure: A CT-Based Diagnosis in a Resource-Limited Setting

contrast CT based on their characteristic location and fat attenuation values [5,12]. Although most lesions remain asymptomatic and are incidentally detected, they may rarely present with seizures, as observed in the present case [10,13]. Recognition of this entity is essential to differentiate it from other fat-containing intracranial lesions and to prevent unnecessary diagnostic interventions [12].

In resource-limited settings, CT serves as a valuable and sufficient diagnostic modality, enabling prompt and accurate diagnosis without the need for advanced imaging [6]. Management is predominantly conservative, with antiepileptic therapy indicated for symptomatic cases, while surgical intervention is generally avoided due to the benign and non-progressive nature of the lesion [9].

Overall, early identification and appropriate interpretation of imaging findings facilitate optimal patient management and ensure favorable clinical outcomes.

## Patient Consent

Written informed consent was obtained from the patient for publication of this case report and associated images.

## Conflict of Interest

The authors declare no conflict of interest.

## Funding

No funding was received for this study.

## References

1. Truwit CL, Barkovich AJ. Pathogenesis of intracranial lipoma: an MR study in 42 patients. *AJR Am J Roentgenol.* 1990;155(4):855–864.
2. Yilmaz MB, et al. Intracranial lipomas: clinical and radiological findings. *Clin Imaging.* 2006;30(6):377–381.
3. Yildiz H, et al. Curvilinear pericallosal lipoma: a case report and review of the literature. *Turk Neurosurg.* 2009;19(2):183–186.
4. Maiuri F, et al. Intracranial lipomas: clinical and neuroradiological features. *Acta Neurochir (Wien).* 1988;92(1–4):33–37.
5. Patel MR, et al. Fat-containing lesions of the central nervous system: part 1. *Radiographics.* 2002;22(2):319–333.
6. Kassimi M, et al. Curvilinear pericallosal lipomas diagnosed incidentally during trauma evaluation: clinical and radiological features. *Radiol Case Rep.* 2020;15(12):2580–2584.
7. Taydaş O, Oğul H, Kantarcı M. Clinical and radiological features of pericallosal lipomas. *Acta Neurol Belg.* 2020;120(1):65–70.

8. Patel N, et al. Intracranial lipomas: imaging features and clinical significance. *Clin Imaging.* 2020;66:178–184.
9. Yadav YR, et al. Intracranial lipomas: a review of pathogenesis and management. *World Neurosurg.* 2021;146:245–252.
10. Sharma P, et al. Pericallosal lipoma presenting with seizures: case report and review. *J Clin Neurosci.* 2021;89:232–235.
11. Nasri S, et al. Pericallosal lipoma: a case report. *Radiol Case Rep.* 2022;17(6):2100–2103.
12. Singh AK, et al. Intracranial lipomas: CT and MRI spectrum with emphasis on differential diagnosis. *Indian J Radiol Imaging.* 2022;32(3):389–395.
13. El-Bahy K, et al. Corpus callosum lipoma presenting with epilepsy: case report. *Egypt J Neurol Psychiatry Neurosurg.* 2022;58:101.
14. Januário G. A clinical case report about an intracranial lipoma. *Int J Clin Oncol Cancer Res.* 2023;8(1):5–10.
15. Diani A, et al. Pericallosal lipoma revealed by headache: a case report. *Sch J Med Case Rep.* 2023;11(5):765–768.
16. Bansal A, et al. Imaging spectrum of intracranial lipomas with emphasis on corpus callosum lesions. *Cureus.* 2023;15(4):e37211.
17. Wardhana DPW, et al. Intracranial lipoma in cerebral convexity: case report and literature review. *Int J Surg Open.* 2024;60:100789.
18. El Marrakchi M, et al. Corpus callosum lipoma associated with spinal dysraphism: case report and review. *Surg Neurol Int.* 2024;15:151.
19. Singh R, et al. Intracranial lipomas: clinical profile and imaging findings in a tertiary center. *Neurol India.* 2024;72(2):190–195.
20. García-Muñoz R, et al. Intracranial lipomas and epilepsy: imaging and clinical correlation. *Seizure.* 2024;115:45–52.