

# Maternal Ischemic Stroke with Communicating Hydrocephalus in Pregnancy: A Multidisciplinary Management Challenge

Aulia Irfatul Ilmi<sup>1\*</sup>, Khoirunnisa Novitasari<sup>2</sup>

<sup>1,2</sup> Department of Obstetrics and Gynecology, Faculty of Medicine, Universitas Airlangga, Dr. Soetomo General Academic Hospital, Surabaya, Indonesia

<sup>1\*</sup> Correspondence Author. Email: [auliairfatulilmi@gmail.com](mailto:auliairfatulilmi@gmail.com)

**Received:** 2nd Mar, 2026 | **Revised:** 14th Mar, 2026 | **Accepted:** 4th Apr, 2026 | **Available Online:** 20th Apr, 2026

## ABSTRACT

**Introduction:** Pregnancy-associated stroke, defined as any cerebrovascular event occurring during gestation, delivery, or within the six-week postpartum period, represents a rare but potentially devastating obstetric complication with significant maternal and neonatal morbidity<sup>1</sup>. The coexistence of cerebral edema and communicating hydrocephalus in our patient further complicates management and worsens prognosis. Pregnancy-associated stroke often presents diagnostic challenges due to the nonspecific overlap of symptoms with typical pregnancy-related physiological changes, underscoring the critical need for a high index of suspicion for early intervention<sup>2</sup>.

**Case Presentation:** We report a case of a 32-year-old gravida 3 para 2 at 29–30 weeks of gestation presenting with a two-week history of headache, fever, and dyspnea. Previous pregnancy was notably normal. Initial evaluation suggested pneumonia with stable hemodynamics and no neurological deficit. During hospitalization, the patient developed fetal distress requiring emergency cesarean section. Two days postoperatively, she experienced decreased consciousness and right-sided neurological deficits. Brain CT scan revealed an acute left basal ganglia infarction, cerebral edema, and communicating hydrocephalus. The patient underwent urgent ventriculoperitoneal (VP) shunt placement. Despite multidisciplinary management, her condition deteriorated, and she died on day 9 of hospitalization. The neonate, born preterm with very low birth weight and respiratory distress, died on day 5 of life.

**Conclusion:** This case highlights the complexity of managing ischemic stroke in pregnancy complicated by hydrocephalus and emphasizes the importance of early recognition, multidisciplinary care, and vigilant neurological monitoring in high-risk obstetric patients.

**Keywords:** Ischemic stroke, pregnancy, basal ganglia infarction, communicating hydrocephalus.

**How to cite this article:** Ilmi AI, Novitasari K. Maternal Ischemic Stroke with Communicating Hydrocephalus in Pregnancy: A Multidisciplinary Management Challenge. *Int J Drug Deliv Technol.* 2026;16(34s):439-442. DOI: 10.25258/ijddt.16.34s.57

**Source of support:** Nil.

**Conflict of interest:** The authors declare no conflict of interest.

## INTRODUCTION

Stroke during pregnancy is an uncommon but severe complication, with an estimated incidence of approximately 12.2 per 100,000 pregnancies<sup>3</sup>. Physiological adaptations in pregnancy—including a hypercoagulable state, increased plasma volume, and endothelial changes—predispose women to thromboembolic events.<sup>4</sup> Ischemic stroke involving the basal ganglia is clinically significant due to its association with motor deficits and poor neurological recovery. The coexistence of cerebral edema and communicating hydrocephalus represents a rare and severe manifestation that further increases intracranial pressure and worsens

prognosis. Diagnosis is often delayed because early symptoms, such as headache, are nonspecific and may overlap with common conditions in pregnancy.<sup>5</sup> Furthermore, management requires balancing maternal neurological stabilization and fetal well-being, making clinical decision-making particularly complex. We report a case of acute basal ganglia infarction with communicating hydrocephalus in late second trimester pregnancy, emphasizing diagnostic challenges, multidisciplinary management, and clinical outcomes.

## CASE PRESENTATION

A 32-year-old woman, gravida 3 para 2 at 29–30 weeks of gestation with a singleton intrauterine pregnancy in

## Maternal Ischemic Stroke with Communicating Hydrocephalus in Pregnancy: A Multidisciplinary Management Challenge

cephalic presentation, was admitted with a two-week history of persistent headache accompanied by fever and dyspnea. The previous pregnancy was notably in normal condition. On admission, the patient was fully conscious (Glasgow Coma Scale score 15) with stable vital signs: with respiratory rate 24–26 breaths per minute, and oxygen saturation 100% with oxygen supplementation via a simple mask (8 L/min). Pulmonary examination demonstrated vesicular breath sounds with basal rhonchi on the left side. No neurological deficits were observed. Obstetric evaluation showed fetal heart rate of 141 beats per minute. Ultrasonography confirmed an estimated fetal weight of 1420 g. Chest x-ray suggested pneumonia. During hospitalization, the patient developed fetal distress characterized by persistent fetal bradycardia (92–98 beats per minute), necessitating emergency cesarean section. A preterm neonate weighing 1300 g was delivered, with Apgar scores of 5 and 7. The amniotic fluid was clear, and a single nuchal cord was observed. The neonate required respiratory support with continuous positive airway pressure.

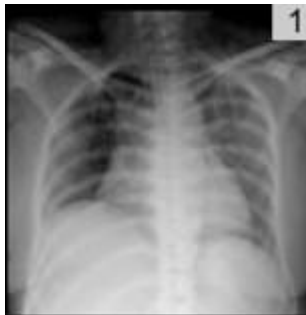

Figure 1. Chest x-ray suggested pneumonia

Following the cesarean section, the patient was successfully extubated and initially demonstrated a stable postoperative condition without apparent neurological deficits. However, on postoperative day 2, the patient developed decreased consciousness, spatial disorientation, and impaired communication. Neurological examination revealed right-sided lateralizing signs. Brain computed tomography showed: an acute infarction in the left basal ganglia, cerebral edema, communicating hydrocephalus, no evidence of intracranial hemorrhage or mass lesion. Neurosurgical evaluation confirmed ischemic stroke involving the left basal ganglia complicated by cerebral edema and communicating hydrocephalus. Laboratory findings revealed hyponatremia, hypokalemia, and hypoalbuminemia, D-dimer was elevated at 1270 ng/mL. The patient underwent urgent ventriculoperitoneal (VP) shunt placement using a medium-pressure system via the

right Kocher's point. Postoperatively, she remained with decreased consciousness and right-sided hemiparesis.

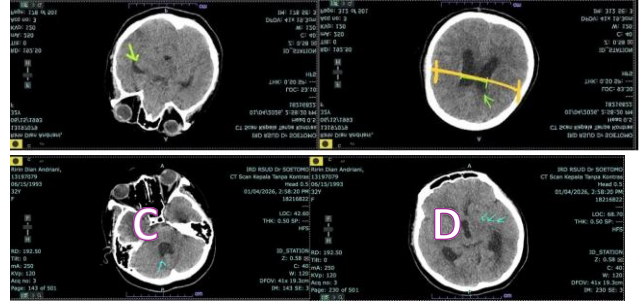


Figure 2. Non-contrast brain computed tomography (CT) scan. (A) Dilatation of the temporal horn ( $>2$  mm), suggestive of hydrocephalus. (B) Increased frontal horn to internal diameter ratio ( $>50\%$ ), indicative of hydrocephalus. (C) Imaging features consistent with communicating hydrocephalus. (D) Hypodense lesion in the left basal ganglia consistent with acute infarction.

Despite intensive care management, including broad-spectrum antibiotics, electrolyte correction, and supportive therapy, the patient's condition progressively deteriorated. She developed respiratory compromise with a high risk of airway obstruction and secretion retention. The patient died on day 9 of hospitalization. The neonate was diagnosed with very preterm birth, very low birth weight, respiratory distress syndrome, early-onset sepsis, neonatal anemia, and jaundice, and died on day 5 of life.

### DISCUSSION

This case highlights a rare and severe presentation of ischemic stroke in pregnancy complicated by communicating hydrocephalus and cerebral edema, resulting in fatal maternal and neonatal outcomes. The incidence of stroke during pregnancy is estimated to be between 10 and 30 cases per 100,000 deliveries, with ischemic strokes accounting for approximately half of these events.<sup>6</sup>

Pregnancy significantly increases the risk of cerebrovascular events such as ischemic stroke, intracerebral hemorrhage, subarachnoid hemorrhage, and cerebral venous sinus thrombosis, attributed to the unique physiological adaptations of gestation<sup>7</sup>. Specifically, the hypercoagulable state, fluctuating hemodynamic profiles, and endothelial dysfunction common in pregnancy contribute to an elevated susceptibility to thrombotic and embolic events<sup>8</sup>. In our case, additional contributing factors may include systemic infection, inflammatory processes, and metabolic disturbances such as electrolyte imbalance and hypoalbuminemia. Systemic infection may have contributed to a prothrombotic and

## Maternal Ischemic Stroke with Communicating Hydrocephalus in Pregnancy: A Multidisciplinary Management Challenge

inflammatory milieu, further increasing the risk of cerebrovascular events.<sup>9</sup>

The initial absence of neurological deficits illustrates the diagnostic challenge, as early symptoms such as persistent headache may be overlooked or misattributed to more common conditions in pregnancy, including tension-type headache, migraine, anemia, preeclampsia, or systemic infections such as pneumonia. This case underscores the diagnostic pitfall of persistent headache without focal neurological deficits, which may delay recognition of underlying cerebrovascular pathology in pregnancy. The concomitant pneumonia may have contributed to delayed neurological evaluation. The occurrence of fetal distress necessitated emergency delivery, reflecting the complex interplay between maternal deterioration and fetal compromise. Cesarean section was found to be strongly and independently associated with an increased risk of stroke during both the peripartum and postpartum periods<sup>10</sup>. Management required rapid coordination between obstetric, neurological, and neurosurgical teams.

Basal ganglia infarction is typically associated with occlusion of small penetrating arteries, leading to motor deficits. The subsequent development of cerebral edema and communicating hydrocephalus suggests disruption of cerebrospinal fluid circulation and increased intracranial pressure, further exacerbating neurological injury. Although ventriculoperitoneal shunting is an established intervention for hydrocephalus, the prognosis remains poor in cases with extensive infarction and delayed diagnosis. Despite timely neurosurgical intervention, the clinical course remained unfavorable, emphasizing the severity of combined ischemic injury and hydrocephalus. This case emphasizes the importance of early neurological assessment in pregnant patients presenting with persistent or atypical symptoms. Multidisciplinary care is crucial in managing stroke during pregnancy, and prompt recognition of headache as a potential cerebrovascular symptom is essential in emergency settings<sup>11</sup>

### CONCLUSION

Ischemic stroke during pregnancy complicated by cerebral edema and communicating hydrocephalus is a rare but catastrophic condition. Nonspecific symptoms, such as persistent headache without focal deficits, may delay diagnosis due to misattribution to common benign conditions in pregnancy. Early recognition of neurological symptoms and prompt multidisciplinary management are essential. It should be emphasized that

pregnancy-related physiological changes may alter neurological status and increase vulnerability to cerebrovascular events. Clinicians should therefore maintain heightened vigilance when evaluating pregnant patients presenting with nonspecific or persistent neurological symptoms. The unfavorable maternal and neonatal outcomes in this case highlight the necessity of early detection, prompt intervention, and close multidisciplinary collaboration to optimize clinical outcomes.

### CONFLICT OF INTEREST

The authors declare no conflict of interest.

### REFERENCES

1. Fang M, Wang J, Wang Z, Chen Y, Xu W, Tao C, Ma L, You C, Hu X and Xia F (2023) Impact of hypertensive disorders of pregnancy on short- and long-term outcomes of pregnancy-associated hemorrhagic stroke. *Front. Neurol.* 14:1097183. doi: 10.3389/fneur.2023.1097183
2. Wang C, Hu X, Lio KU, Lin J, Zhang N. Cerebral venous thrombosis as a rare cause of nausea and vomiting in early pregnancy: Case series in a single referral center and literature review. *Front Neurol.* 2022 Sep 22;13:912419. doi: 10.3389/fneur.2022.912419. PMID: 36212667; PMCID: PMC9536175.
3. Swartz RH, Cayley ML, Foley N, Ladhani NNN, Leffert L, Bushnell C, McClure JA, Lindsay MP. The incidence of pregnancy-related stroke: A systematic review and meta-analysis. *Int J Stroke.* 2017 Oct;12(7):687-697. doi: 10.1177/1747493017723271. PMID: 28884652.
4. Sanders BD, Davis MG, Holley SL, Phillippi JC. Pregnancy-Associated Stroke. *J Midwifery Womens Health.* 2018 Jan;63(1):23-32. doi: 10.1111/jmwh.12720. Epub 2018 Jan 25. PMID: 29369478; PMCID: PMC7608605.
5. Miller EC, Leffert L. Stroke in Pregnancy: A Focused Update. *Anesth Analg.* 2020 Apr;130(4):1085-1096. doi: 10.1213/ANE.0000000000004203. PMID: 31124843; PMCID: PMC7035913.
6. Miller EC, Leffert L. Stroke in Pregnancy: A Focused Update. *Anesth Analg.* 2020 Apr;130(4):1085-1096. doi: 10.1213/ANE.0000000000004203. PMID: 31124843; PMCID: PMC7035913.
7. Mittal S, Alsbrook D, Okwechime RT, Iqbal F, Nobleza COS. The landscape of disparities in obstetric neurocritical care and a path forward. *Front Neurol.* 2023 Jan 6;13:1008544. doi: 10.3389/fneur.2022.1008544. PMID: 36686512; PMCID: PMC9853894.

## Maternal Ischemic Stroke with Communicating Hydrocephalus in Pregnancy: A Multidisciplinary Management Challenge

8. Sariyeva M, Haghighi N, Mitchell A, Booker WA, Petersen NH, Shields AD, Ghoshal S, Agarwal S, Park S, Claassen J, Connolly ES, Roh DJ, Miller EC. Primary and Secondary Intracerebral Hemorrhage in Pregnant and Nonpregnant Young Adults by SMASH-UP Criteria. *J Am Heart Assoc.* 2024 Apr 2;13(7):e034032. doi: 10.1161/JAHA.123.034032. Epub 2024 Mar 27. PMID: 38533990; PMCID: PMC11179753.
9. Behzadnia H, Omrani SN, Nozari-Golsefid H, Moslemi S, Alijani B, Reyhanian Z, et al. Ischemic stroke and intracerebral hemorrhage in patients with COVID-19. *Romanian Journal of Neurology [Internet].* 2020 Sep 30;19(3):166. Available from: <https://doi.org/10.37897/rjn.2020.3.5>
10. Lanska DJ, Kryscio RJ. Risk factors for peripartum and postpartum stroke and intracranial venous thrombosis. *Stroke.* 2000 Jun;31(6):1274-82. doi: 10.1161/01.str.31.6.1274. PMID: 10835444.
11. Camargo EC, Singhal AB. Stroke in Pregnancy: A Multidisciplinary Approach. *Obstet Gynecol Clin North Am.* 2021 Mar;48(1):75-96. doi: 10.1016/j.ogc.2020.11.004. PMID: 33573791; PMCID: PMC7888384