

## Case series on surgical management of ectopic pregnancy

Rakhee Srinivasalu<sup>1</sup>, R. Jayanthi<sup>2</sup>, Shanma<sup>3</sup>

<sup>1</sup> Post Graduate, <sup>2</sup> HOD and Professor, <sup>3</sup> Assistant Professor

Department of Obstetrics and Gynaecology, Meenakshi Medical College Hospital and Research Institute, Eathur, Kanchipuram, Meenakshi Academy of Higher Education and Research (MAHER), Chennai

. Email: [drakheesrinivasalu@gmail.com](mailto:drakheesrinivasalu@gmail.com)

Received: 12th Mar, 2026 | Revised: 24th Mar, 2026 | Accepted: 14th Apr, 2026 | Available Online: 30th Apr, 2026

### ABSTRACT

Ectopic pregnancy is defined as implantation of the fertilized ovum other than the endometrial cavity. It constitutes 1-2% of pregnancies in India, ranking among leading first-trimester maternal emergencies with rupture rates of 70-90% due to delayed diagnosis. Common risk factors include prior tubal surgery, infections, and sterilization failures, prevalent in developing settings. This case series examines four surgically managed EPs at a tertiary center, aggregating demographics, presentations, interventions, and outcomes to highlight diagnostic challenges and management efficacy in resource-limited contexts.

**Key words:** Ectopic pregnancy (EP), beta-human chorionic gonadotropin

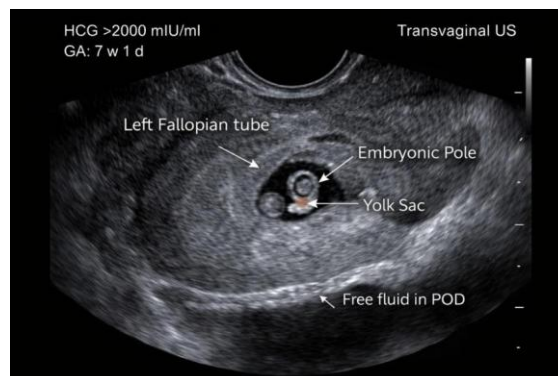
**How to cite this article:** Srinivasalu R, Jayanthi R, Shanma. Case series on surgical management of ectopic pregnancy. *Int J Drug Deliv Technol.* 2026;16(39s): 833-834. DOI: 10.25258/ijddt.16.39s.102

**Source of support:** Nil.

**Conflict of interest:** None

### CASE 1

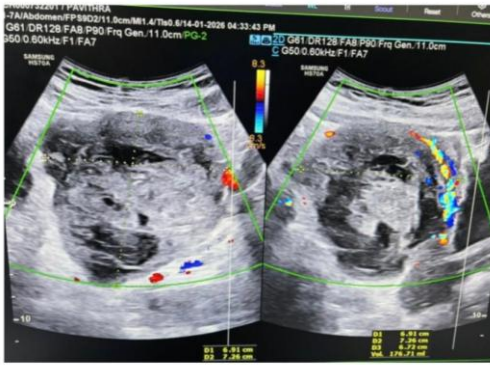
A 25-year-old G2P1L1 woman, married for 4 years, LMP: 3/11/25, GA- 7 weeks 1 day presented with complaints of lower abdomen pain and bleeding per vaginum since 1 day. BP- 90/70mmHg, PR- 120 bpm, P/A- tenderness present in left iliac fossa, P/V- cervical motion tenderness noted. Beta HCG- >2000mIU/ml Ultrasound-confirmed left unruptured tubal ectopic pregnancy at 7 weeks 1 day, free fluid in POD. She had regular menses (3/28 days), unremarkable medical/family history, and prior normal vaginal delivery of a healthy 3.74 kg girl. Hb dropped from 12.4 to 10.4 g/dl. Blood grouping and cross matching done. She was taken up for emergencies left partial salpingectomy under spinal anesthesia on 3.11.25, with intraoperative 100 ml hemoperitoneum and ampullary conceptus (5x6 cm) sent for histopathology. Patient was discharged on POD4 with antibiotics, supplements, and contraception advice and showed no complications at 6 weeks follow up.



### CASE 2

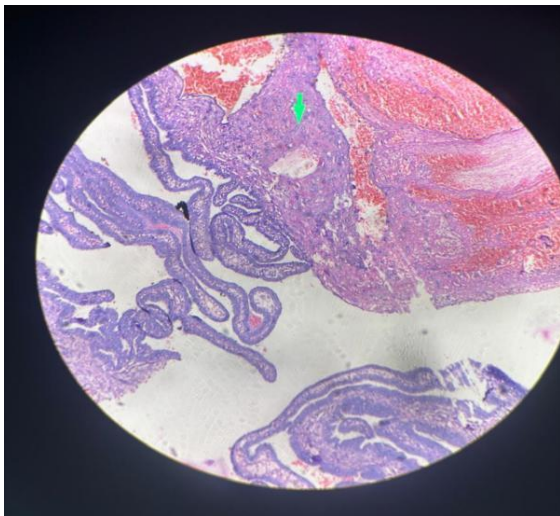
A 22-year-old G2P1L1 woman, married for 2 years, LMP 24/12/25, came with complaints of vague lower abdominal pain on and off since 2 months. Menstrual history revealed reduced flow in last 2 cycles. Vital BP- 120/70mmHg, PR- 90bpm, per abdomen – soft, mild tenderness in left iliac fossa on deep palpation, per vaginal examination showed uterus ~10 weeks size, firm, fixed with left fornical fullness and tenderness. Lab values: Hb 10.9 g/dL,  $\beta$ -hCG 152 mIU/mL, normal tumor markers. MRI confirmed 7x6 cm left adnexal cyst. Emergency laparotomy (20/1/26) revealed chronic ectopic pregnancy in left ovary (7x7 cm) with organized clots and dense bowel adhesions (released). Left salpingo-oophorectomy performed; right adnexa normal. Uneventful post-op recovery; discharged on 24/1/26.

## ULTRASOUND FINDINGS



### CASE 3

A 28-year-old G3P2L2 woman with failed tubectomy done 2 years back, LMP- 30.1.26, presented with 3 days of abdominal pain, vomiting, vaginal bleeding, loose stools, and positive UPT suggesting ectopic pregnancy. Examination revealed pallor (++), hypotension BP 90/60mmHg, PR 120bpm, per abdomen- soft, shifting dullness present, tenderness present in left iliac fossa, per vaginal examination- uterus 8 weeks size, left adnexal mass (5x5 cm) with cervical motion tenderness present. Hb was 7.2 g/dL (O+ve). Emergency laparotomy under SA on 11/03/25 confirmed ruptured ectopic pregnancy; bilateral fimbriectomy performed with 3 units PRBC transfused. Postoperative recovery was uneventful with IV antibiotics.



### CASE 4

A 30-year-old primigravida LMP 28/12/25, GA 6 weeks 8 days, presented with ectopic pregnancy diagnosed by USG showing unruptured right tubal ectopic with viable embryo (5 weeks 2 days),  $\beta$ -hCG 891.1 mIU/mL, Hb 11.9 g/dL. Examination revealed no pallor (++), BP 120/80mmHg, PR 88bpm, per abdomen- soft, non tender, per vaginal examination- uterus normal size, mild tenderness in right fornix. No comorbidities noted. Emergency laparotomy under SA on 14/2/26 revealed 2x2 cm ectopic mass in right ampullary region; right tubal segmental resection performed. Left adnexa and uterus normal. Postoperative course uneventful with IV antibiotics transitioned to oral.

### CASE 5

A 22-year-old primi, married for 2 years, presented to the O&G OPD on January 14, 2026, with sudden-onset left lower abdominal pain for 1 day, nausea, and vomiting. Her last menstrual period was December 24, 2025 (LCB 1 year prior via NVD). PR 104bpm, BP 130/80 mmHg, per abdomen- soft, tenderness present in left iliac fossa, per vagina- uterus 10 weeks size, left fornical fullness, tenderness present, no bleeding noted. Labs: Hb 10.9 g/dL,  $\beta$ -hCG 152 mIU/mL, normal tumor markers. USG revealed a 7.2x6.9x6.7 cm heterogeneous left adnexal cyst with peripheral vascularity and minimal POD fluid.

Laparotomy on 14.1.26 confirmed left ovarian ectopic pregnancy (100g clots, adhesions released). Left salpingo-oophorectomy performed; post-op  $\beta$ -hCG dropped to 5 mIU/mL. Histopathology: ovarian ectopic gestation with infarction. Ovarian ectopics (0.5-3% of ectopics) follow Spiegelberg's criteria; risk factors include PID, ART, IUCD.

#### Prognosis

Prognosis for ectopic pregnancy (EP) has improved markedly with early diagnosis via  $\beta$ -hCG and transvaginal USG, reducing maternal mortality from historical 3.5-7% to near 0% in modern series. In India, where rupture rates remain 60-80% due to delayed presentations, timely surgical intervention (salpingectomy/resection) yields excellent short-term outcomes: 92-100% uneventful recoveries, minimal complications, and discharge by POD 4-7, as in this series.

#### Fertility Outcomes

Post-salpingectomy, subsequent intrauterine pregnancy rates reach 40-60% within 1-2 years, higher (65-75%) with conservative tubal resection. Recurrent EP risk is 10-15%, mitigated by counseling. Ovarian EP (rare, 25% here) carries similar fertility prospects if unilateral oophorectomy avoids.

#### Long-term Prognosis

No mortality in this cohort aligns with tertiary center data; anemia resolves with transfusions/supplements. FOGSI emphasizes contraception post-op (6 months) to optimize healing and future pregnancies. Early screening in at-risk groups (multigravidae, tubal history) further enhances prospects

#### DISCUSSION

This case series of four ectopic pregnancies at a tertiary Indian center aligns closely with national epidemiology, where EP comprises 1-2% of pregnancies and peaks in the 20-30s among multigravidae (68-91%), as seen here (mean age 26.3 years, 75% G2P1L1). All patients presented at 6-7 weeks with pain (100%), reflecting late diagnosis common in resource-limited settings, leading to rupture in 25% (Case 3) and mimicking adnexal pathology in the chronic ovarian variant (Case 2).

Presentations mirrored regional patterns: lower abdominal pain, bleeding (50%), and instability in ruptured cases with severe anemia (Hb 7.2 g/dL). The ruptured ampullary EP post-failed tubectomy (Case 3) underscores sterilization failure risks, with relative odds 4-16 times higher for EP in such conceptions, prevalent due to procedural errors in India (up to 18%

cases). Ovarian EP (Case 2, 0.15-3% of ectopics) posed diagnostic challenges, confirmed by MRI amid adhesions, consistent with its vascularity and rupture propensity.

Management via emergency laparotomy (100%) with spinal anesthesia was apt for hemodynamic instability/rupture, per FOGSI guidelines prioritizing surgery over methotrexate (contraindicated by size >3.5 cm, bleeding). Partial salpingectomy/segmental resection preserved fertility in 75% (Cases 1,4), akin to conservative rates of 46.5% in laparoscopy series, though laparotomy dominated nationally (78%) due to infrastructure limits. Intraoperative hemoperitoneum (100-500 mL), transfusions (3 units in rupture), and antibiotics yielded uneventful recoveries (POD 4-7 discharge), with no morbidity/mortality—better than historical 3.5-7% rates from improved imaging (USG/MRI).

$\beta$ -hCG variability (152-2000 mIU/mL) highlighted non-correlation with rupture, emphasizing serial USG; low levels in chronic ovarian EP reinforced expectant criteria ( $\leq 200$  mIU/mL, <6 weeks). Compared to laparoscopy (shorter stay, less blood loss), laparotomy remains feasible in unstable patients, though expansion could reduce salpingectomy needs.

Limitations include small sample and pending histopathology; strengths lie in diverse subtypes (tubal 75%, ovarian 25%; unruptured 50%, ruptured/chronic 50%). Timely intervention averted catastrophe, advocating early screening for at-risk groups (prior tubal procedures, multigravidae) and primary referrals. Multicenter trials on hybrids (methotrexate+surgery) for stable unruptured EPs could optimize outcomes in India.

## CONCLUSION

This case series underscores the efficacy of timely surgical intervention in managing ectopic pregnancies at a tertiary Indian center, achieving uneventful recoveries in all four diverse cases (tubal ampullary 75%, ovarian 25%) despite high rupture risks from delayed presentations. Aligning with national epidemiology, it highlights persistent challenges like failed sterilization and diagnostic delays, avertable through early USG screening in multigravidae and at-risk groups. Advocating enhanced primary referrals, community awareness, and laparoscopy expansion could reduce salpingectomy rates and morbidity below historical 3.5-7%. Multicenter trials on medical-surgical hybrids promise optimized fertility-preserving care in resource-limited settings.

## REFERENCES

1. Shaw JLV, Dey SK, Critchley HOD, Horne AW. Current knowledge of the aetiology of human tubal ectopic pregnancy. *Hum Reprod Update*. 2010;16(4):432–444.
2. ACOG Practice Bulletin No. 193. Tubal ectopic pregnancy. *Obstet Gynecol*. 2018;131(3):e91–e103.
3. Paul C, Swathy S. Fetomaternal Outcomes in Low-Risk Primigravida Women: Expectant Management Versus Elective Induction at 39 Weeks in a Tertiary Hospital. *Nurexus; Journal of MedVerse Research & Practice*. 2025;3(12):19-25. doi: 10.65188/nurexus.1059. Available from: <https://www.nurexus.com/journals/published/JMRP-12-2025-87>
4. Royal College of Obstetricians and Gynaecologists. Diagnosis and Management of Ectopic Pregnancy. Green-top Guideline No. 21. London: RCOG; 2016.
5. American College of Obstetricians and Gynecologists. Early pregnancy loss and ectopic pregnancy. *Obstet Gynecol Clin North Am*. 2020;47(3):593–607.
6. Bouyer J, Coste J, Fernandez H, Pouly JL, Job-Spira N. Sites of ectopic pregnancy: A 10-year population-based study. *Hum Reprod*. 2002;17(12):3224–3230.
7. Hoover KW, Tao G, Kent CK. Trends in the diagnosis and treatment of ectopic pregnancy in the United States. *Obstet Gynecol*. 2010;115(3):495–502.
8. Murray H, Baakdah H, Bardell T, Tulandi T. Diagnosis and treatment of ectopic pregnancy. *CMAJ*. 2005;173(8):905–912.
9. R D, S . Spinal Anesthesia for Emergency Cesarean Section in a Patient with Prior Thoracic Scoliosis Surgery: A Case Report . *Nurexus; Journal of MedVerse Research & Practice*. 2025;3(7):7-12. doi: 10.65188/nurexus.1033. Available from: <https://www.nurexus.com/journals/published/JMRP-07-2025-54>
10. Barnhart KT. Clinical practice. Ectopic pregnancy. *N Engl J Med*. 2009;361(4):379–387.
11. Ankum WM, Mol BW, Van der Veen F, Bossuyt PM. Risk factors for ectopic pregnancy: A meta-analysis. *Fertil Steril*. 1996;65(6):1093–1099.
12. FOGSI. Good Clinical Practice Recommendations on Ectopic Pregnancy. Mumbai: Federation of Obstetric and Gynaecological Societies of India; 2020.
13. Swetha S, Indhira A. Burden and Feto-Maternal Effects of Gestational Glucose Intolerance Among Expectant Mothers. *Nurexus; Journal of MedVerse Research & Practice*. 2025;3(11):9-15. doi: 10.65188/nurexus.1052. Available from: <https://www.nurexus.com/journals/published/JMRP-11-2025-75>
14. Lipscomb GH, Stovall TG, Ling FW. Nonsurgical treatment of ectopic pregnancy. *N Engl J Med*. 2000;343(18):1325–1329.
15. Practice Committee of the American Society for Reproductive Medicine. Medical treatment of ectopic pregnancy. *Fertil Steril*. 2013;100(3):638–644.

16. Jurkovic D, Wilkinson H. Diagnosis and management of ectopic pregnancy. *BMJ*. 2011;342:d3397.
17. Raziel A, Mordechai E, Friedler S, et al. Ovarian pregnancy—A report of twenty cases. *Fertil Steril*. 2004;82(2):529–533.
18. Dr. Navya , Dr. Meenakumari . Evaluation of IL-

6, TGF- $\beta$ 1, CRP, and Vitamin D Levels in Women with Uterine Fibroids . *Nurexus; Journal of MedVerse Research & Practice*. 2025;3(3):1-6. doi: 10.65188/nurexus.1017. Available from: <https://www.nurexus.com/journals/published/JMRP-03-2025-32>

**Case series on surgical management of  
ectopic pregnancy**