

Comparative evaluation of dentin removal and taper of root canal preparation by using one hand protaper and two rotary file systems in primary molars using cone-beam computed tomography: An in-vitro study

Dr Sanhati Biswas MDS*¹, Dr Snehi², Dr Komal Rajurkarr MDS³, Dr Anushree Koyande⁴

¹* Assistant professor, Department of Paediatric and Preventive Dentistry, Gitam Dental College and Hospital, Visakhapatnam, sanhatibiswas90@gmail.com

², MDS, Private practitioner, dr.snehi22@gmail.com

³Senior lecturer, Department of conservative dentistry and endodontics, VYWS Dental College and Hospital, Amravati, komalrajurkar1995@gmail.com

⁴MDS, Private practitioner, Mumbai, koyandeanushree95@gmail.com

Abstract:

Aim and Background: The present study is aimed at evaluation of residual radicular dentinal thickness and taper by using Universal Hand Protaper, Protaper Gold and Kedo-S Plus in Deciduous Molars Using Three-dimensional Cone-beam Computed tomography.

Method: 66 molars which were freshly extracted and included only primary teeth were selected for this in-vitro study. Random allocation of the molars was done into three groups named as, A Group: Protaper Universal, B Group: Protaper Gold and C Group: Kedo S Plus with 22 teeth in each group. The extracted teeth were mounted on wax blocks and subjected to CBCT examination for pre-instrumentation dentinal thickness. After instrumentation with respective file system for each groups the samples were then subjected to CBCT examination for post-instrumentation dentinal thickness. **Results:** The post-treatment dentin was greatest in Kedo S plus group followed by Protaper gold and Protaper Universal. Significantly greater tapering was seen in Kedo-S plus in comparison to Protaper Universal and Protaper gold.

Conclusion: Dentin removal was least in Kedo S Plus group as compared to other two groups. There was significantly greater tapering in Kedo-S plus in comparison to Universal Hand Protaper and Protaper gold.

Clinical Significance: This research helps us to determine an efficient endodontic file for the proper preparation of primary root canals for endodontic procedure which has minimal dentin removal and better taper for avoiding fracture of root canal during instrumentation.

Keywords: Cone-Beam computed tomography, root canal treatment, primary molars, rotary files, dentin

How to cite this article: Biswas S, Snehi, Rajurkarr K, Koyande A, Comparative evaluation of dentin removal and taper of root canal preparation by using one hand protaper and two rotary file systems in primary molars using cone-beam computed tomography: An in-vitro study. Int J Drug Deliv Technol. 2026;16(4s): 882-887; DOI: 10.25258/ijddt.16.4s.102

Introduction

Deciduous teeth in children often undergo trauma and carious lesions which leads to pulp necrosis which requires adequate endodontic intervention which commonly involves the procedure of non-vital pulp therapy also known as pulpectomy. Space loss is one of the common consequences of premature exfoliation of infected deciduous molars. Preserving the deciduous teeth is important for space maintenance until physiological resorption and exfoliation for aesthetics and function.¹ Pulpectomy involves infected pulp extirpation along with endodontic preparation of root canal. Instrumentation of canals with complex structure, prolonged instrumentation time and uncooperative behaviour of children problems are some of the obstacles which need modern and updated techniques to avoid the later.²

Hand-Files, hand-reamers, irrigators, Ni-Ti rotary file systems are some of the instruments commonly used for the root canal preparations. Use of manual endodontic

files are time consuming leading to lack of patient cooperation³. It also leads to other iatrogenic flaws such as breakage of the instruments, change in the original morphology of canal shape, widening of apical foramen with over-instrumentation, difficulty in working in curved canals, and unwanted grooves and step formation.⁴ All the later shortcomings of manual files can be reduced by using rotary endodontic files. Dr Elizabeth S. Barr and her team first explained the use of rotary endodontic file in shaping of deciduous root canals.⁵ Their study concluded that Ni-Ti rotary files for instrumentation in primary teeth resulted in uniform preparation and obturation. It was also economical. The lower modulus of elasticity of rotary instruments makes them more pliable than stainless steel files. There are very less chances of separation of instruments because of higher ductility⁶. Preserving a sound peripheral dentin along with uniformity after instrumentation should be the priority in endodontic instrumentation. The rotary files have overtaken the manual files considering the in

*Author for Correspondence: sanhatibiswas90@gmail.com

preservation of the root dentinal thickness.⁷ From the first generation of rotary files till the fifth generation they were all designed for permanent teeth. But in the coming years many pediatric rotary files were introduced with reduced taper for deciduous teeth which made the step of cleaning and shaping much easier.⁸ Recently a lot of advanced diagnostic techniques has come up giving promising results in the field of research on endodontic instruments. Cone Beam Computed Tomography (CBCT) gives an advantage over conventional two-dimensional imaging system by generating three-dimensional image of the desired structure and its accuracy percentage is far better than the two-dimensional methods.⁹

This research will compare and evaluate the residual root-dentinal thickness after instrumentation and taper of the root canal preparation of the Universal Hand Protaper, Protaper Gold and Kedo-S Plus file in deciduous maxillary and mandibular molars by using CBCT.

Sample selection

This randomized in-vitro comparative study was performed in the department of pedodontics and preventive dentistry in India. Sample size calculation performed by using G*POWER 3.1.9.2 SOFTWARE and keeping the alpha error as 5% and power of the study as 90%. 66 primary molar root canals which were collected from patients reporting at departmental OPD and from peripheral private and government dental clinics were used for the study.

For this study freshly extracted deciduous teeth were selected. It included both maxillary and mandibular first and second molars. Roots which had 2/3rd of the total root length without signs of root resorption and no furcation involvement were selected which were determined by using radiovisiography (RVG). The selected teeth were washed with water and stored in 0.5% sodium hypochlorite solution for seven days.

Materials and Methods

Ethical clearance was received for the study from the college ethical committee with reference number RCDSR/SRC/MDS/2021. After disinfection, random allocation of teeth was done into three groups with 22 teeth in each group. A horse-shoe shaped modelling wax (AARC Dental, India) was used to arrange the teeth for the scanning tray of the CBCT (Cone Beam Computed Tomography) machine (NewTom, Cefla, North America). The measurements of the block were kept lower than the FOV of the CBCT machine. The arranged teeth were then exposed to CBCT for evaluation.

The wax models were placed on the arch-shaped CBCT machine tray at the required position. Exposure parameters were 90 kV, 4 mA, and 5.6 seconds and the FOV was set at 10 cm × 7 cm. First initial caries was removed using round shaped diamond bur no.4 (Mani, Japan) along with arotor handpiece (NSK) was used for

access cavity preparation. Safe end diamond tapered fissure bur (Mani, Japan) was used for remaining pulpal removal. A K-file (Mani, Japan) #10 of 21mm was used to determine the working length by putting the file in the canal until it reached the apical foramen of the tooth that could be appreciated visually. The working length was finalized by keeping the length 1mm short from the actual length obtained. Initially cleaning and shaping was done upto #20 K file (Mani, Japan) of 21mm. After that each sample group root canal instrumentation was done according to manufacturer's guidelines in crown down technique with EDTA (Avue, India) as lubricant. All procedure was done by a single operator.

Group A: Universal Hand Protaper 21mm F1 (Dentsply Maillefer, Switzerland) was used for preparation of 22 root canals. Step back technique was used with irrigation with 3% sodium hypochlorite and normal saline (Pentagon Labs, India) for removal of debris. All procedure was done by a single operator.

Group B: ProTaper gold rotary file (Dentsply, USA) was used with the endomotor (Marathon, Saeyang, Korea) for 22 root canals. First SX and S1 was used with 5 Newton per centimeter torque and 300 rotations per minute speed. Then after S2 and F1 was used with 1.5 Newton per centimeter torque and 300 rotations per minute speed. All procedure was done by a single operator.

Group C: Kedo SPlus (Reegans Dental Care, India) was used for instrumentation of 22 canals till the working length using endomotor (Marathon, Saeyang, Korea). Speed and torque were kept as 2.2 Newton per cm and 300 rotations per minute for P1+ file (Figure 2). All procedure was done by a single operator.

Pre-instrumentation and Post-instrumentation CBCT images determined the taper of root canal preparation. Remaining dentinal thickness on the mesial and distal side of the roots were calculated at the occlusal, cervical and the apical third by the CBCT scan using a formula by a single operator.

On the mesial side a1-a2 formula was used where a1 is demarcated as the lowest measurement between the mesial side of the root and mesial side of the canal periphery, where a1 is the pre-instrumentation measurement and a2 is the post instrumentation measurement. Similarly for the distal surface b1-b2 formula was used where b1 is demarcated as the lowest measurement between the distal side of the root and distal side of the canal periphery, where b1 is the pre-instrumentation measurement and b2 is the post instrumentation measurement (Figure

Comparative Evaluation of Dentin Removal and Taper of Root Canal Preparation by Using One Hand Protaper and Two Rotary File Systems in Primary Molars Using Cone-Beam Computed Tomography: An In-Vitro Study

1). Evaluation of canal taper was calculated from the post-instrumentation images (Figure 2). At the occlusal third, cervical third, and apical third the maximum mesiodistal diameter was calculated at center of canal preparations. Gradual reduction of the diameter between the

mesial and distal surface from the occlusal, cervical and apical third proved to be good taper. Any discrepancy in this form of reduction which includes either similar measurement or increase in measurements between the occlusal, cervical and apical third was considered as bad taper.

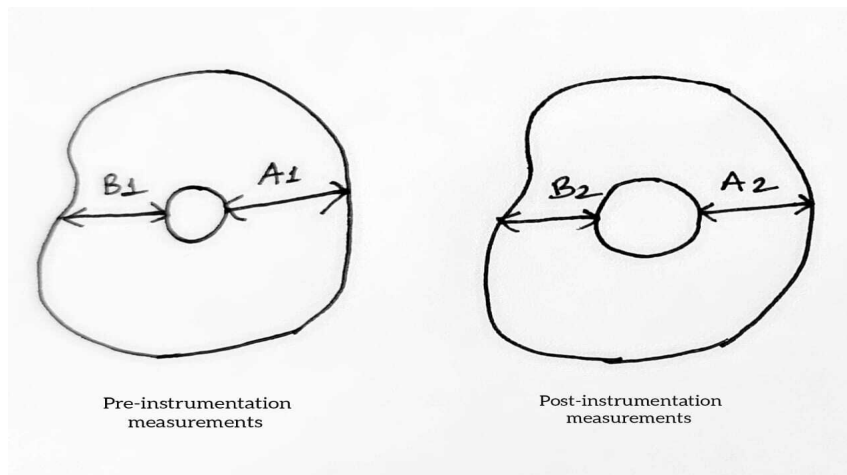


Figure 1 Scale of measurement for the thickness of mesial and distal root dentinal thickness

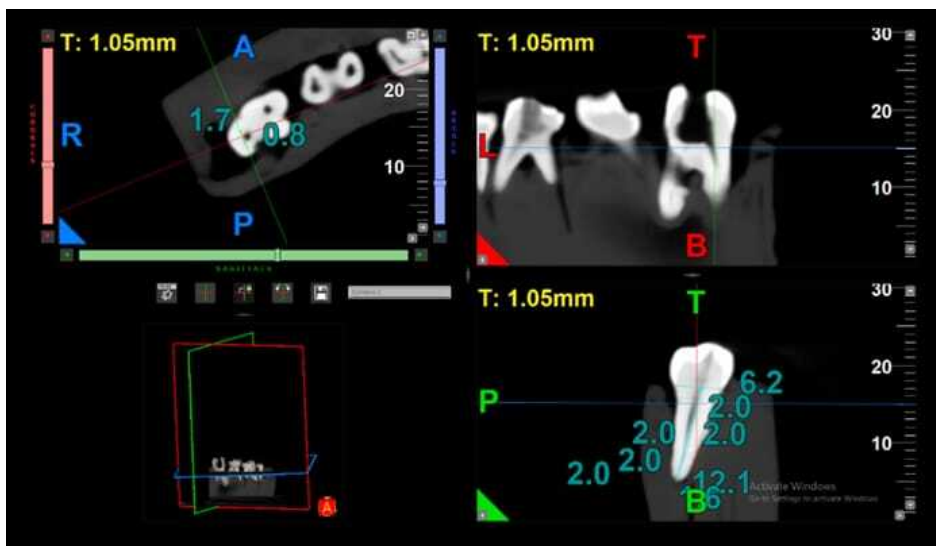


Figure 2 CBCT image of post instrumentation

Statistical Analysis:

One way ANOVA test for dentin removal analysis was done with the obtained values. Discrepancy in the scores root taper analysis and results was done by using and Chi square test using formula $\chi^2 = \frac{\sum(O-E)^2}{E}$. Here, χ^2 is for chi square test value Σ is summation, O is observed frequency, E is expected frequency.

Result

There is significantly higher dentin removal on the mesial side of the coronal segment (Table 1),

followed by Group B and Group C. In the middle and apical third of all the three groups there was no significant difference in the pre and post treatment dentin. On the distal side of apical segment, the pre-treatment dentin was greatest in Group C followed by Group A and Group B with statistically significant differences between them. (Table 2).The result for the taper of preparation was significant considering the reduction in diameter from occlusal to apical section. Significantly greater tapering was in Group in comparison to Group A and Group B (Figure 3).

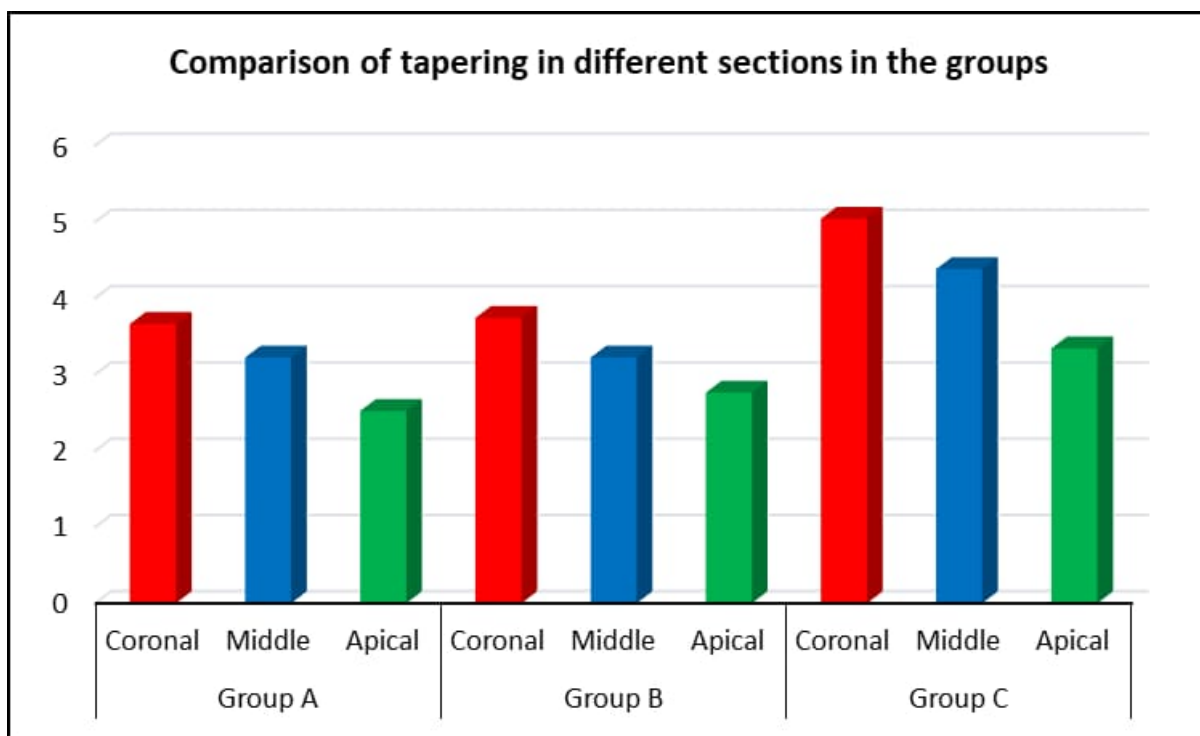


Figure 3 Comparison of Taper of root canals after preparation

Table 1. Pre-treatment and post-treatment dentin in mesial side of coronal segment in the different groups

| Groups | Mesial Coronal Pre-Treatment | Mesial Coronal Post-Treatment | P value for paired t test |
|---------------------------|------------------------------|-------------------------------|---------------------------|
| GROUP A | 1.51 ± 0.36 | 1.31 ± 0.23 | <0.001* |
| GROUP B | 1.68 ± 0.17 | 1.55 ± 0.21 | <0.001* |
| GROUP C | 1.95 ± 0.64 | 1.80 ± 0.66 | <0.001* |
| P-value for one way ANOVA | 0.005* | <0.001* | |

Table 2. Pre-treatment and post-treatment dentin in distal side of apical segment in the different groups

| Groups | DISTAL APICAL PRE-TREATMENT | DISTAL APICAL POST-TREATMENT | P value for paired t test |
|---------|-----------------------------|------------------------------|---------------------------|
| GROUP A | 0.77 ± 0.28 | 0.74 ± 0.27 | 0.001* |
| GROUP B | 0.64 ± 0.18 | 0.57 ± 0.23 | <0.001* |
| GROUP C | 0.83 ± 0.29 | 0.80 ± 0.32 | 0.027* |

| | | | |
|----------------------------------|---------|---------|--|
| P value for one way ANOVA | <0.001* | <0.001* | |
|----------------------------------|---------|---------|--|

Discussion

The most common treatment modality for the management of necrosed pulp is pulpectomy. Debridement of microorganisms and residues from the root canal during instrumentation are important steps for achieving a successful pulpectomy.⁶ Residual dentin thickness is directly proportional to the fracture resistance of the root. 1 mm of radicular dentin is necessary post intra-radicular procedures in the entire root length to prevent root fracture.¹⁰

In our study the dentin removal for the Kedo Splus group showed the least dentin removal on the mesial side of the coronal segment and also at the apical segment. Considering the taper of the root canal preparation, it was better in the Kedo Splus group compared to the other two groups making the pediatric rotary files to be the favorable choice during non-vital pulp therapy. The difficult morphology of the primary tooth roots may arise several other post treatment faults like vertical fracture of roots and perforations on the lateral walls at the danger zones of the primary teeth where the root dentin thickness is very thin.¹¹ Pediatric rotary files reduce these canal perforations and fracture chances.

In a study conducted by Katge *et al*¹² compared two rotary pediatric files and one manual H file in a study. They studied the cleaning efficacy of Prime Pedo, DXL-Pro and H files in root canals of primary molars and concluded that pediatric rotary files proved to be more effective in cleaning and shaping of the root canals than the conventional manual H file which is similar to our present study.

Root canal taper among manual and rotary instruments using CBCT was compared by Musale *et al*. They concluded that in ProTaper has better taper than the manual instrumentattion.¹³ In present study Kedo S-plus showed better taper preparation than Protaper gold and Universal Hand Protaper.

G. Jeevanandan *et al* compared the instrumentation time and quality of obturation between paediatric rotary file (Kedo-S) and hand instrumentation in primary molars.¹⁴ Less instrumentation time was required for Kedo-S and along with better obturation according to the results of the study.

Seema T *et al*. compared the compared manual K files with Rotary Protaper adult files and Kedo files. Differences at middle and apical third were statistically insignificant. Kedo files removed significantly lesser dentin at the coronal third. The results are similar to the

present study where Kedo S Plus showed lesser root dentin removal than Universal Hand Protaper and Protaper Gold rotary files¹⁵.

Systemic review and meta- analysis of seven articles by Fagihian et al has showed that the instrumentation time was 1.79 min lesser than conventional hand filing techniques.¹⁶

In recent times, the Cone Beam Computed tomography (CBCT) has proved to be an effectual tool for the 3D imaging of radicular dentin as it is a non-invasive tool for scanning the specimen without damaging it. Earlier studies by Anil K Tomer *et al*.¹⁷

In a volumetric analysis of the canal preparation in primary molars using CBCT Satish Vishwanathaiah concluded that Kedo Square files showed the least difference in preparation volume and better obturating volume compared to Pro AF baby gold file systems.¹⁸

Conclusions

In the present study within experimental conditions, the conclusions are summarised as In the occlusal segment, KEDO S Plus showed highest residual dentin thickness compared to Universal Hand Protaper and Protaper Gold, however there was not much difference in the cervical and apical segment. There was significantly greater tapering in Kedo-S plus in comparison to Universal Hand Protaper and Protaper gold.

Limitations of the Study

There is an increased chance of root perforation in deciduous molars as the roots are more tortuous and thinner as compared to the permanent teeth roots. NiTi rotary system cannot be used in a dry field as it increases the chances of fracture of the rotary instruments. Use of NiTi rotary system is technique sensitive procedure. The user should be well versed with torque and the rpm systems of the rotary file system. The NiTi rotary files are expensive as compared to conventional files system

Clinical Significance: While instrumentation of deciduous teeth canals, maintaining adequate dentinal thickness is essential to prevent the fracture of roots. This research helps us to determine an efficient endodontic file for the better instrumentation of deciduous root canals with minimal dentin removal and better taper.

References

1. Ahmed HM. Anatomical challenges, electronic working length determination and current developments in root canal preparation of primary molar teeth. *Int Endod J*. 2013 Nov;46(11):1011-22. doi: 10.1111/iej.12134.
2. Ingle JI, Bakland LK, Baumgartner JC. *Ingle's Endodontics*. 6th ed. Ontario: BC Decker Inc; 2008. p. 1417.
3. Babu KLG, Hebbar KG. Determination of the Anxiety and Behavior of Children Undergoing Endodontic Treatment Using Manual and Rotary File Systems: A Comparative Clinical Study. *J South Asian Assoc Paediatr Dent*. 2021;4(3):175-184.
4. El-Kishawi M, Khalaf K. An Update on Root Canal Preparation Techniques and How to Avoid Procedural Errors in Endodontics. *Open Dent J*. 2021;15:204-213. doi: 10.2174/1874210602115010204.
5. Barr ES, Kleier DJ, Barr NV. Use of nickel-titanium rotary files for root canal preparation in primary teeth. *Pediatr Dent*. 2000;22(1):77-8.
6. Pérez-Higueras JJ, Arias A, de la Macorra JC, Peters OA. Differences in cyclic fatigue resistance between ProTaper Next and ProTaper Universal instruments at different levels. *J Endod*. 2014 Sep;40(9):1477-81. doi: 10.1016/j.joen.2014.02.025
7. Mohamed RH, Abdelrahman AM, Sharaf AA. Evaluation of rotary file system (Kedo-S-Square) in root canal preparation of primary anterior teeth using cone beam computed tomography (CBCT)-in vitro study. *BMC Oral Health*. 2022 Jan 18;22(1):13. doi: 10.1186/s12903-021-02021-0.
8. Pitchiah PA, Shivashankarappa PG. Rotary Files in Pediatric Dentistry: From Then Till Now. *J Sci Dent*. 2020;10(2):55-57.
9. Lo Giudice R, Nicita F, Puleio F, Alibrandi A, Cervino G, Lizio AS, et al. Accuracy of Periapical Radiography and CBCT in Endodontic Evaluation. *Int J Dent*. 2018 Oct 16;2018:2514243. doi: 10.1155/2018/2514243.
10. Garala M, Kuttler S, Hardigan P, Steiner-Carmi R, Dorn S. A comparison of the minimum canal wall thickness remaining following preparation using two nickel-titanium rotary systems. *Int Endod J*. 2003 Sep;36(9):636-42. doi: 10.1046/j.1365-2591.2003.00704.x.
11. Tabrizzadeh M, Reuben J, Khalesi M, Mousavinasab M, Ezabadi MG. Evaluation of radicular dentin thickness of danger zone in mandibular first molars. *J Dent (Tehran)*. 2010;7(4):196-9.
12. Ghadge S, Katge F, Poojari M, Jain K, Patil D. Clinical Evaluation and Comparison of Obturation Quality Using Pediatric Rotary File, Rotary Endodontic File and H File in Root Canal of Primary Molars: A Double Blinded Randomized Controlled Trial. *Int J Res Rep Dent*. 2020 Nov 28;3(2):118-25.
13. Musale PK, Jain KR, Kothare SS. Comparative assessment of dentin removal following hand and rotary instrumentation in primary molars using cone-beam computed tomography. *J Indian Soc Pedod Prev Dent*. 2019 Jan-Mar;37(1):80-86. doi: 10.4103/JISPPD.JISPPD_210_18.
14. Jeevanandan G, Govindaraju L. Clinical comparison of Kedo-S paediatric rotary files vs manual instrumentation for root canal preparation in primary molars: a double blinded randomised clinical trial. *Eur Arch Paediatr Dent*. 2018 Aug;19(4):273-278. doi: 10.1007/s40368-018-0356-6.
15. Seema T, Ahammed H, Parul S, Cheranjevi J. Comparative Evaluation of Dentin Removal and Taper of Root Canal Preparation of Hand K File, ProTaper Rotary File, and Kedo S Rotary File in Primary Molars Using Cone-beam Computed Tomography. *Int J Clin Pediatr Dent*. 2020 Jul-Aug;13(4):332-336. doi: 10.5005/jp-journals-10005-1787.
16. Faghihian R, Amini K, Tahririan D. Rotary versus Manual Instrumentation for Root Canal Preparation in Primary Teeth: A Systematic Review and Meta-Analysis of Clinical Trials. *Contemp Clin Dent*. 2022 Jul-Sep;13(3):197-204. doi: 10.4103/ccd.ccd_77_20.
17. Tomer AK, Miglani A, Chauhan P, Nagarjuna P, Rana S, Kumari A. An in-vitro evaluation of remaining dentine thickness through CBCT using different files. *IOSR J Dent Med Sci*. 2017;16(2):121-4.
18. Vishwanathaiah S. Comparison of volumetric analysis between conventional and rotary files in the preparation of root canals in primary molars—an in vitro study. *Front Dent Med*. 2024;5:1489074. doi: 10.3389/fdmed.2024.1489074.