

From Articulator to Operatory: Electrosurgery-Assisted Esthetic Crown Lengthening Using an Acrylic Guide

Dr. Nitin Tomar¹, Dr. Nancy Saxena^{2*}, Dr. Priyanshu Ramuka³, Dr. Mayur Kaushik⁴

¹Professor, Department of Periodontology & Implantology, Subharti Dental College & Hospital, Swami Vivekanand Subharti University, Meerut, Uttar Pradesh - 250005, India. | Email: drnitintomar@gmail.com

^{2*}Postgraduate, Department of Periodontology & Implantology, Subharti Dental College & Hospital, Swami Vivekanand Subharti University, Meerut, Uttar Pradesh - 250005, India. | Email: drnancysaxena15@gmail.com

³Postgraduate, Department of Periodontology & Implantology, Subharti Dental College & Hospital, Swami Vivekanand Subharti University, Meerut, Uttar Pradesh - 250005, India. | Email: ramuka.priyanshu@gmail.com

⁴Professor and Head, Department of Periodontology & Implantology, Subharti Dental College & Hospital, Swami Vivekanand Subharti University, Meerut, Uttar Pradesh - 250005, India. | Email: drmayurkaushik@gmail.com

***Corresponding Author:** Dr. Nancy Saxena, Postgraduate, Department of Periodontology & Implantology, Subharti Dental College & Hospital, Swami Vivekanand Subharti University, Meerut, Uttar Pradesh - 250005, India. Email: drnancysaxena15@gmail.com

ABSTRACT:

Excessive gingival display is a common esthetic concern requiring precise diagnosis and treatment planning for predictable outcomes. This case report describes the management of a gummy smile using an articulator-guided esthetic crown lengthening approach. Prosthodontic planning on an articulator was used to determine ideal tooth proportions and gingival margins, which were accurately transferred clinically using an acrylic surgical guide. Guided electrosurgical gingival recontouring allowed precise soft-tissue management with effective hemostasis while preserving periodontal health. The approach resulted in improved smile esthetics, well-contoured gingival margins, and favorable periodontal response, highlighting the effectiveness of an interdisciplinary prosthodontic–periodontal technique.

KEYWORDS: Crown lengthening, electrosurgery, acrylic guide, gummy smile, prosthodontic–periodontal approach.

How to cite this article: Tomar N, Saxena N, Ramuka P, Kaushik M. From articulator to operatory: electrosurgery-assisted esthetic crown lengthening using an acrylic guide. *Int J Drug Deliv Technol.* 2026;16(4s): 245-250; DOI: 10.25258/ijddt.16.4s.30

INTRODUCTION:

A pleasing smile is the result of a balanced relationship between the teeth, gingiva, and lips. Excessive gingival display (EGD), commonly referred to as a gummy smile, is generally characterized by the exposure of more than 3–4 mm of gingival tissue during smiling and represents a frequent esthetic concern, particularly among young adult female.¹ Although not a pathological condition, excessive gingival display can significantly influence facial harmony and negatively affect an individual's self-esteem and psychosocial well-being.² The etiology of a gummy smile is multifactorial and includes

dentogingival, skeletal, and muscular components.

Dentoalveolar causes such as altered passive eruption (APE) are among the most common, wherein the gingival margin fails to migrate apically to the cemento-enamel junction, resulting in short clinical crowns.³ Other contributing factors include a hyperactive or short upper lip, vertical maxillary excess, and, less frequently, dentoalveolar protrusion.

Management strategies for excessive gingival display vary according to the underlying cause and may involve orthodontic, periodontal, prosthodontic, or surgical interventions. Orthognathic surgery remains the gold standard for severe skeletal discrepancies but is limited by its invasive nature and

From Articulator to Operatory: Electrosurgery-Assisted Esthetic Crown Lengthening Using an Acrylic Guide

associated morbidity.⁴ Minimally invasive alternatives such as botulinum toxin injections and lip repositioning procedures are indicated primarily for muscular etiologies. In contrast, esthetic crown lengthening remains the treatment of choice for dentogingival conditions such as altered passive eruption. Recent advances, including guided crown lengthening techniques, have further enhanced the precision and predictability of esthetic periodontal surgery.⁵

CASE PRESENTATION:

A 38-year-old female patient reported to the Department of Periodontics with the chief complaint of excessive gingival display during smiling, seeking improvement in smile esthetics. The patient expressed dissatisfaction with the short clinical crown height of the maxillary anterior teeth. Medical history was non-contributory, and no deleterious oral habits were reported. Extraoral examination revealed a high smile line with increased gingival exposure [Figure 1]. Intraoral clinical examination demonstrated excessive gingiva [Figure 2] suggestive of a dentogingival etiology, consistent with altered passive eruption. Periodontal examination revealed healthy gingival tissues with adequate attached gingiva and no signs of active periodontal disease.

A comprehensive prosthodontic evaluation was carried out, and diagnostic impressions were made. Casts were mounted on a semi-adjustable articulator to facilitate esthetic analysis and determine the ideal tooth proportions and gingival margin positions [Figure 3]. Based on the articulator-guided planning, an acrylic surgical guide [Figure 4,5] was fabricated to accurately transfer the proposed gingival contours to the clinical setting. Following thorough patient education regarding the procedure, risks, and expected outcomes, written informed consent was obtained.

Esthetic crown lengthening was carried out using a monopolar electrosurgical unit with a fine straight electrode (Younique Dental Innovations R.F. Advance; Motranser, Waipu, Taiwan).

The acrylic surgical guide was positioned intraorally [Figure 6,7,8,9] to guide precise gingival margin placement, and electrosurgical soft-tissue recontouring was performed following the predetermined outline. Continuous saline irrigation was maintained throughout the procedure to prevent thermal tissue damage and ensure patient comfort.

Immediate postoperative [Figure 10] evaluation revealed well-defined gingival margins, improved crown length, and enhanced smile esthetics with minimal bleeding. Postoperative instructions were given, and the patient was recalled for follow-up visits at 3 months postoperatively [Figure 11]. Healing was uneventful, with stable gingival margins, satisfactory periodontal health, and significant improvement in smile esthetics [Figure 12]. No relapse or complications were observed during the follow-up period.

FIGURES:

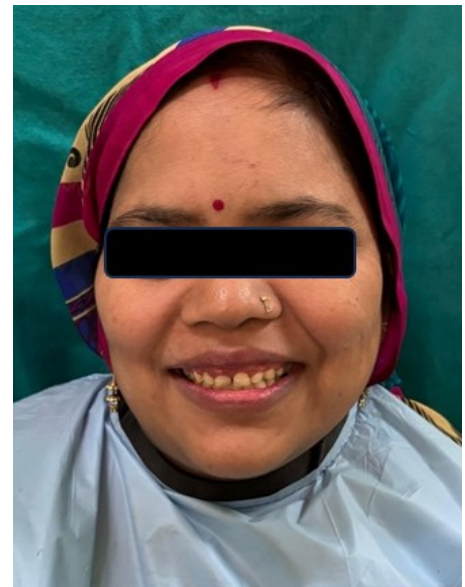

Fig. 1 PRE OPERATIVE EXTRA ORAL VIEW

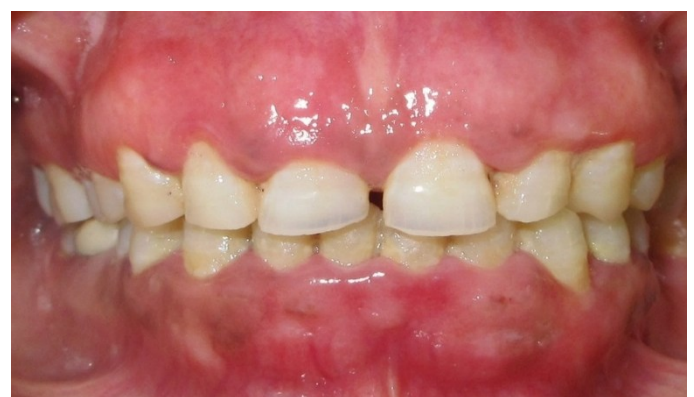

Fig. 2 PRE OPERATIVE INTRA ORAL VIEW

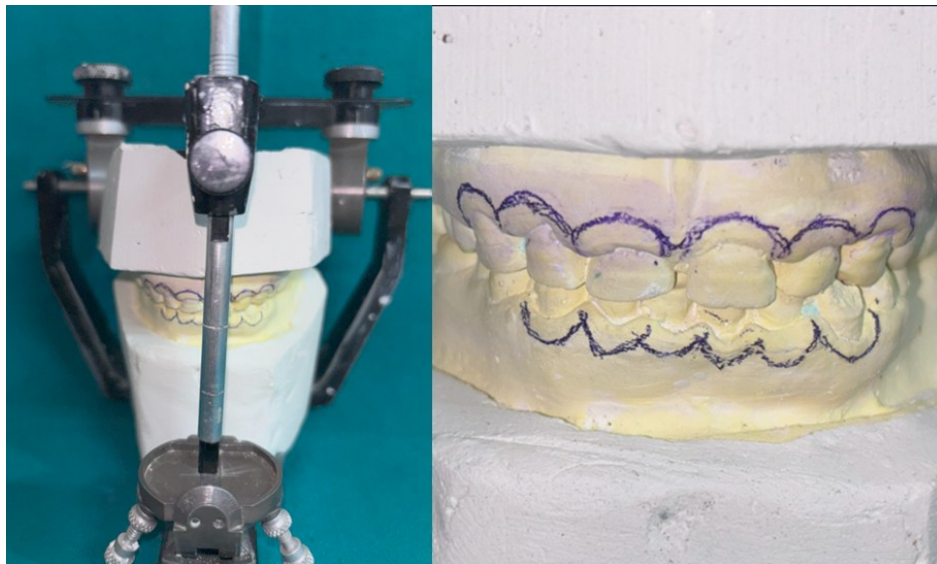


Fig. 3 MARKING DONE ON ARTICULATED CAST

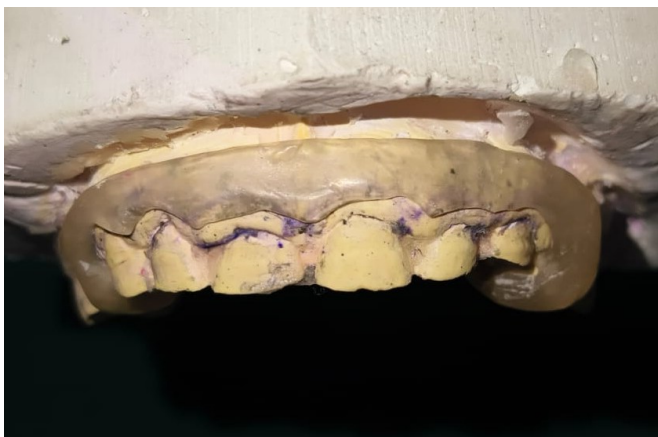

Fig. 4 ACRYLIC SURGICAL GUIDE FOR MAXILLARY ARCH

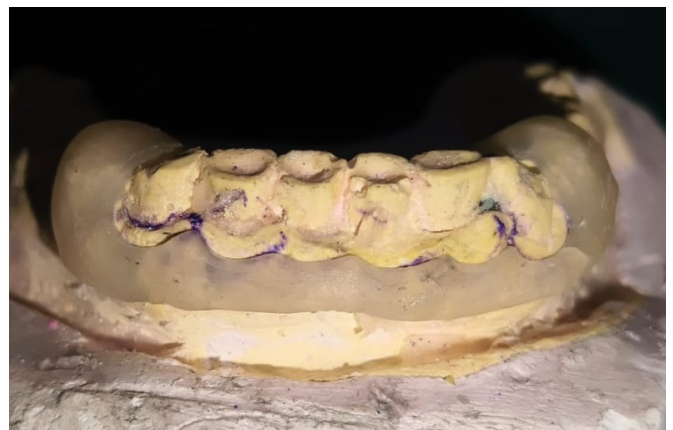

Fig. 5 ACRYLIC SURGICAL GUIDE FOR MANDIBULAR ARCH

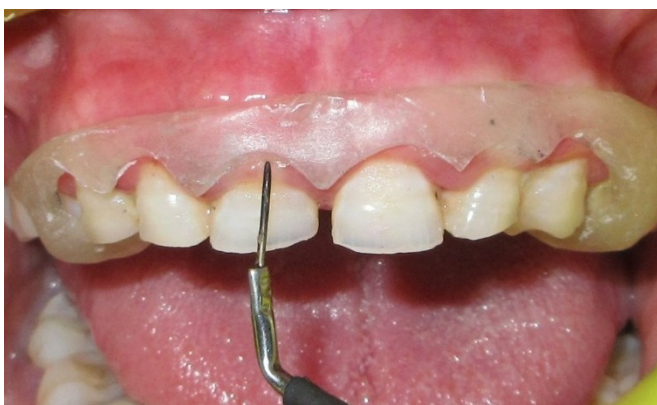

Fig. 6 SURGICAL GUIDE PLACED IN MAXILLARY ARCH

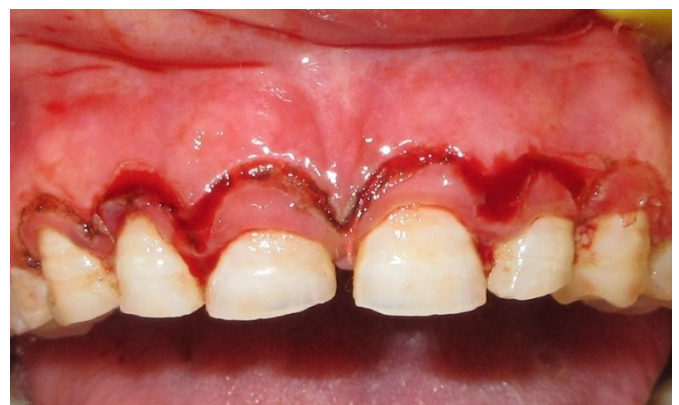

Fig. 7 EXCESS GINGIVA EXCISED IN MAXILLA

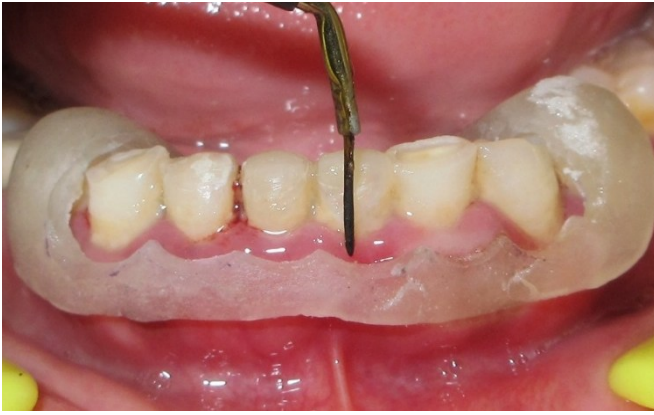

Fig. 8 SURGICAL GUIDE PLACED IN MANDIBULAR ARCH

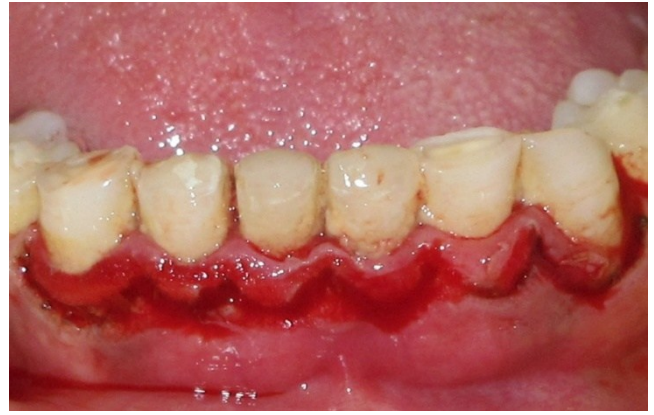

Fig. 9 EXCESS GINGIVA EXCISED IN MANDIBLE

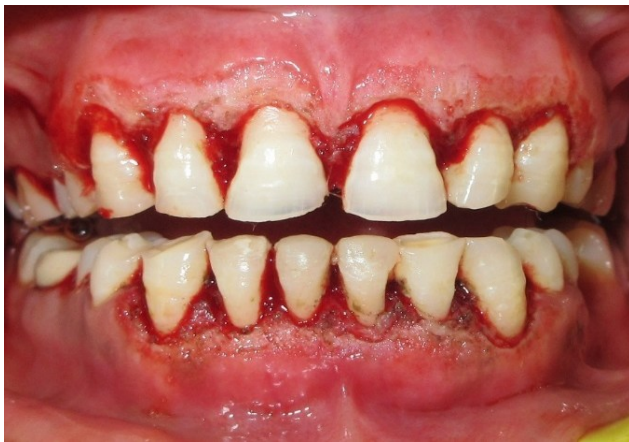

Fig. 10 IMMEDIATE POST OPERATIVE VIEW

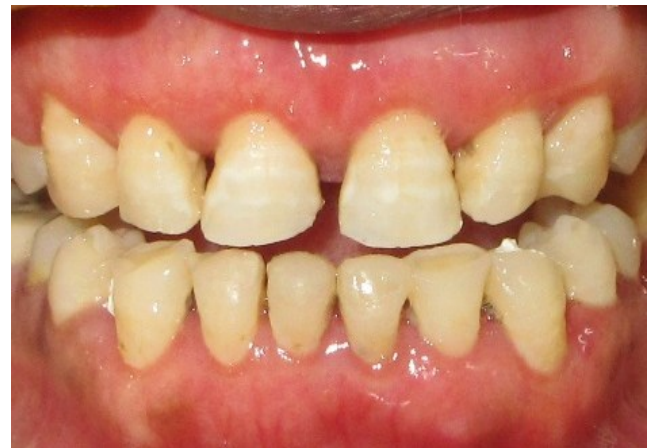

Fig. 11 3 MONTH POST OPERATIVE VIEW

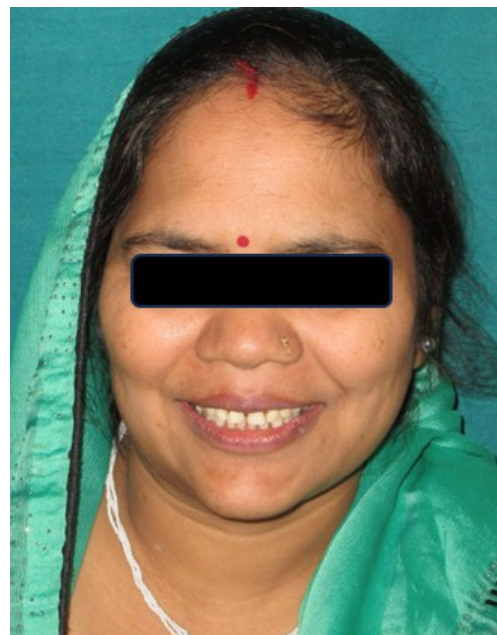

Fig. 12 3 MONTHS POST OPERATIVE EXTRA ORAL VIEW

DISCUSSION:

Esthetic crown lengthening is a periodontal surgical procedure aimed at increasing clinical crown height by repositioning the gingival margin apically, with or without osseous recontouring. This approach is particularly effective in cases of altered passive eruption, where excessive gingival coverage obscures ideal tooth proportions. The primary objectives of crown lengthening include achieving harmonious esthetic proportions, improving smile balance, and maintaining periodontal health by respecting the supracrestal tissue attachment.⁶

The selection of surgical technique depends on the anatomical subtype of altered passive eruption and the relationship between the alveolar bone crest and the cemento-enamel junction. In cases with adequate keratinized tissue and no osseous interference, soft-tissue recontouring alone may be sufficient. However, when the alveolar bone crest is positioned coronally, osseous resection is required to prevent violation of the supracrestal tissue attachment and to ensure long-term gingival stability.⁷ Thorough preoperative assessment, including bone sounding and evaluation of keratinized tissue width, is therefore critical for predictable outcomes.⁶ Conventionally, crown lengthening procedures have been performed using free-hand techniques with scalpel, electrosurgery, or laser modalities. Scalpel surgery provides excellent tactile feedback but may pose challenges in achieving symmetry across multiple teeth.⁸ Electrosurgery offers advantages such as superior hemostasis, improved visibility, and reduced operative time, although careful execution is necessary to prevent thermal tissue injury.⁷ Laser-assisted techniques allow precise soft-tissue ablation with minimal bleeding and postoperative discomfort, albeit with higher equipment costs. Clinical evidence suggests that when biologic principles are respected, long-term gingival margin stability is comparable across these modalities.⁹ Guided crown lengthening techniques represent a significant advancement in esthetic periodontal surgery by minimizing operator-dependent variability and improving surgical accuracy. Surgical guides fabricated from acrylic resin or

vacuum-formed templates are derived from diagnostic wax-ups that serve as a blueprint for ideal gingival contours and tooth dimensions.⁶ These guides facilitate accurate transfer of the planned outcome to the clinical setting, enhancing predictability in both soft- and hard-tissue management. Although minor limitations such as guide thickness and interproximal inaccuracies have been reported, guided approaches consistently demonstrate superior esthetic control compared to free-hand techniques. With ongoing developments in digital workflows, guided crown lengthening is expected to further refine clinical outcomes and patient satisfaction.⁸

CONCLUSION:

Articulator-guided electrosurgical crown lengthening using an acrylic surgical guide represents an effective interdisciplinary approach for the management of excessive gingival display particularly in cases of dentogingival etiology such as altered passive eruption. Conventional crown lengthening procedures continue to provide predictable and stable outcomes when performed according to established periodontal principles. The integration of digital workflows—including intraoral scanning, CBCT imaging, and CAD/CAM-fabricated guides—further enhances surgical precision, allowing accurate control of gingival zeniths and standardized osseous recontouring. While these digital techniques offer notable advantages in complex or multi-tooth esthetic cases, guided electrosurgical crown lengthening remains highly effective for routine clinical scenarios. Future studies should aim to evaluate long-term gingival stability, cost-effectiveness, and the continued refinement of digital workflows to optimize both esthetic and functional outcome.

References:

1. Peck S, Peck L, Kataja M. The gingival smile line. *Angle Orthod* 1992;62:91–100.
2. Tjan AHL, Miller GD, The JG. Some esthetic factors in a smile. *J Prosthet Dent* 1984;51:24–28.
3. Rosenblatt A, Simon Z. Lip repositioning for reduction of excessive gingival display: A clinical report. *Int J Periodontics Restorative Dent* 2006;26:433–437.
4. Garber DA, Salama MA. The aesthetic smile: Diagnosis and treatment. *Periodontol* 2000 1996;11:18–28.
5. Coslet JG, Vanarsdall R, Weisgold A. Diagnosis and classification of delayed passive eruption of the dentogingival junction in the adult. *Alpha Omegan* 1977;70:24–28.
6. Silberberg N, Goldstein M, Smidt A. Excessive gingival display—Etiology, diagnosis, and treatment modalities. *Quintessence Int* 2009;40:809–818.
7. Sarver DM, Ackerman MB. Dynamic smile visualization and quantification: Part 2. Smile analysis and treatment strategies. *Am J Orthod Dentofacial Orthop* 2003;124:116–127.
8. Tomar N, Saxena N, Rout M, Kaushik M. Soft-tissue Augmentation Utilising De-epithelialised Autogenous Free Gingival Graft for the Amelioration of Miller Class I and II Gingival Recession. *Advances in Human Biology* 2025;15:449-453.
9. Tomar N, Bansal T, Kaushik M, Batra M. Smile enhancement with reconstruction of interdental papilla: A case report. *TMU J Dent* 2014;1:33-35.