

The Phantom Perforation: Occult Duodenal Perforation with Adult Midgut Malrotation and Perioperative Myocardial Infarction

Dr. Sujieve Kumar Ravilla^{1*}, Dr. Aravinth Ram M², Dr. Mohammad Zia Kittur³, Dr. Manaazir Rilahasan J⁴

¹Postgraduate, Department of General Surgery, A.C.S. Medical College and Hospital, Velappanchavadi, Chennai – 600077, Tamil Nadu, India. E-mail: rtsujieve@gmail.com ORCID ID: 0009-0003-5902-8155

²Assistant Professor, Department of General Surgery, A.C.S. Medical College and Hospital, Velappanchavadi, Chennai – 600077, Tamil Nadu, India. E-mail: maravinthram1992@gmail.com ORCID ID: 0009-0003-0453-865X

³Senior Resident, Department of General Surgery, A.C.S. Medical College and Hospital, Velappanchavadi, Chennai – 600077, Tamil Nadu, India. E-mail: mohammedzia663@gmail.com ORCID ID: 0009-0001-2310-3876

⁴Senior Resident, Department of General Surgery, A.C.S. Medical College and Hospital, Velappanchavadi, Chennai – 600077, Tamil Nadu, India. E-mail: manaazirrilahasan@gmail.com ORCID ID: 0009-0005-9355-5682

ABSTRACT

Perforated peptic ulcer remains a major surgical emergency associated with significant morbidity and mortality, particularly when diagnosis is delayed or complicated by atypical presentation and systemic complications. We report a rare and challenging case of a 44-year-old male who presented with acute epigastric pain and initially misleading radiological findings. An outside computed tomography report suggested pyloric thickening with features of gastritis, while repeated erect abdominal radiographs failed to demonstrate pneumoperitoneum. The patient initially improved symptomatically with conservative management; however, he subsequently developed worsening abdominal pain, diffuse tenderness, guarding, and rigidity suggestive of evolving peritonitis. Ultrasonography demonstrated free pelvic fluid, and emergency contrast-enhanced computed tomography later confirmed pneumoperitoneum with features of hollow viscus perforation.

While being shifted for emergency exploratory laparotomy, the patient suddenly developed palpitations, breathlessness, and electrocardiographic evidence of acute inferior wall myocardial infarction, creating a major perioperative challenge. Despite the high operative risk, emergency surgery was undertaken with heparin infusion and intensive cardiology support. Intraoperatively, approximately 1.5 liters of toxic intraperitoneal fluid and a 2 × 1 cm perforation in the first part of the duodenum were identified. An incidental congenital intestinal malrotation with abnormal bowel orientation was also noted. Graham's omental patch repair, extensive peritoneal lavage, appendectomy, and drain placement were performed successfully. Postoperatively, the patient required intensive care monitoring but recovered satisfactorily without major surgical complications.

This case represents an unusual “triple-threat” emergency involving occult perforated duodenal ulcer with deceptive imaging, adult congenital midgut malrotation, and acute perioperative myocardial infarction. The case highlights the limitations of plain radiography in early perforation, the importance of serial clinical examination and computed tomography in suspicious cases, and the need for rapid multidisciplinary coordination in managing critically ill surgical patients with concurrent cardiovascular instability. Early recognition and timely surgical intervention remain crucial for improving outcomes in atypical presentations of perforation peritonitis.

Keywords: Perforated peptic ulcer; Duodenal perforation; Pneumoperitoneum; Intestinal malrotation; Graham's patch repair; Perioperative myocardial infarction; Emergency laparotomy; Hollow viscus perforation; Acute abdomen; Deceptive imaging.

How to cite this article: Ravilla SK, Aravinth Ram M, Kittur MZ, Rilahasan J M. The Phantom Perforation: Occult Duodenal Perforation with Adult Midgut Malrotation and Perioperative Myocardial Infarction. *Int J Drug Deliv Technol.* 2026;16(52s): 925-929. DOI: 10.25258/ijddt.16.52s.116

INTRODUCTION

Perforated peptic ulcer (PPU) remains one of the most life-threatening gastrointestinal emergencies encountered in surgical practice, despite advances in acid suppression therapy and minimally invasive surgery.[1] Globally, PPU contributes substantially to emergency surgical admissions and is associated with high morbidity and mortality,

particularly when diagnosis or intervention is delayed.[1] Recent evidence from a systematic review and meta-analysis by Peiffer et al. demonstrated that perioperative mortality in complicated peptic ulcer disease remains significantly elevated in resource-limited and emergency settings, with sepsis, delayed presentation, and associated systemic complications being major predictors of poor

*Author for Correspondence: rtsujieve@gmail.com

The Phantom Perforation: Occult Duodenal Perforation with Adult Midgut Malrotation and Perioperative Myocardial Infarction

outcome.[1] Similarly, Dadfar and Edna, in their 40-year population-based study, observed that although the incidence of peptic ulcer disease has declined with widespread proton pump inhibitor usage and *Helicobacter pylori* eradication, perforation continues to occur frequently among middle-aged men and carries considerable mortality risk.[2]

Diagnosis of perforated peptic ulcer may occasionally be challenging because classical radiological findings such as free air under the diaphragm may initially be absent, leading to deceptive or “phantom” presentations.[3] Bupicha et al. reported that delayed recognition of perforation significantly increased postoperative complications, septic shock, and mortality, emphasizing the importance of repeated clinical assessment and advanced imaging modalities such as computed tomography in suspicious cases.[3] In many patients, abdominal rigidity and worsening peritonitis may precede definitive radiological evidence, thereby creating diagnostic uncertainty and delaying surgical intervention.

Another rare and diagnostically challenging entity is congenital intestinal malrotation presenting in adulthood. Adult malrotation is uncommon and often remains asymptomatic until discovered incidentally during surgery or imaging performed for unrelated abdominal emergencies. The coexistence of intestinal malrotation with perforated peptic ulcer is exceedingly rare and can further complicate operative anatomy and intraoperative decision-making. Such congenital rotational anomalies may alter bowel orientation, anatomical landmarks, and surgical access, thereby increasing procedural complexity during emergency laparotomy.

Perioperative cardiovascular complications further worsen prognosis in emergency abdominal surgery. Acute myocardial infarction occurring during transfer or immediately before surgery represents a catastrophic surgical and anesthetic challenge because the surgeon must simultaneously balance hemorrhagic risk, anticoagulation, septic physiology, and ongoing myocardial ischemia. Gastric and upper gastrointestinal emergencies are particularly associated with profound inflammatory response, hemodynamic instability, and cardiac stress.[4] Rosa et al. demonstrated that emergency gastrointestinal surgical conditions in critically ill patients frequently coexist with systemic complications, including cardiovascular instability, respiratory compromise, and multiorgan dysfunction.[4]

The present case describes an unusual “triple-threat” emergency involving occult perforated duodenal ulcer with initially deceptive imaging, incidental congenital midgut malrotation identified intraoperatively, and acute perioperative myocardial infarction occurring immediately prior to emergency laparotomy. The successful management of this rare combination highlights the importance of serial clinical evaluation, timely CT imaging,

multidisciplinary coordination, and rapid surgical decision-making in critically ill patients.

Case presentation

A 44-year-old male presented to the emergency department with severe epigastric pain of acute onset associated with abdominal discomfort. The patient had previously undergone computed tomography at an outside facility; however, only the written report was available at presentation and the imaging films were unavailable. The outside report described pyloric wall thickening measuring approximately 4 mm with features suggestive of gastritis. On initial evaluation, the patient was hemodynamically stable and abdominal examination revealed epigastric tenderness without generalized rigidity or guarding. An erect abdominal radiograph obtained at admission did not demonstrate free air under the diaphragm or other definitive evidence of perforation.

The patient was managed conservatively with intravenous fluids, proton pump inhibitors, analgesics, and supportive care. Following administration of analgesics, the abdominal pain temporarily subsided. However, approximately six hours later, the patient developed recurrence of severe abdominal pain with diffuse abdominal tenderness, guarding, and rigidity suggestive of evolving peritonitis. A repeat erect abdominal radiograph again failed to demonstrate pneumoperitoneum. In view of worsening clinical findings despite negative radiographs, an urgent ultrasonographic examination of the abdomen was performed, which demonstrated free fluid within the pelvis and bilateral paracolic gutters.

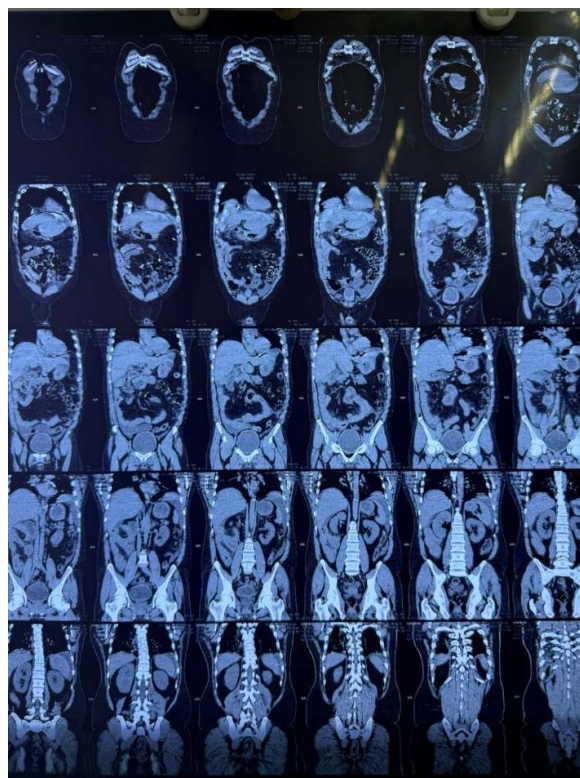
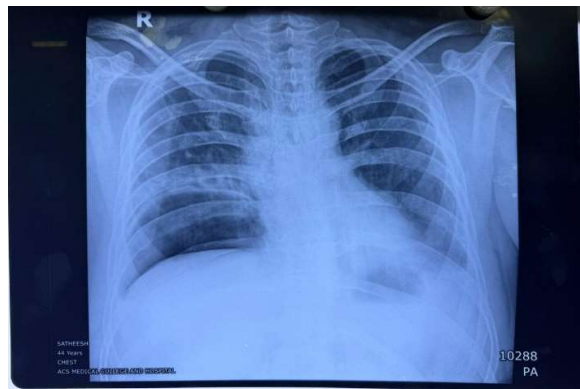
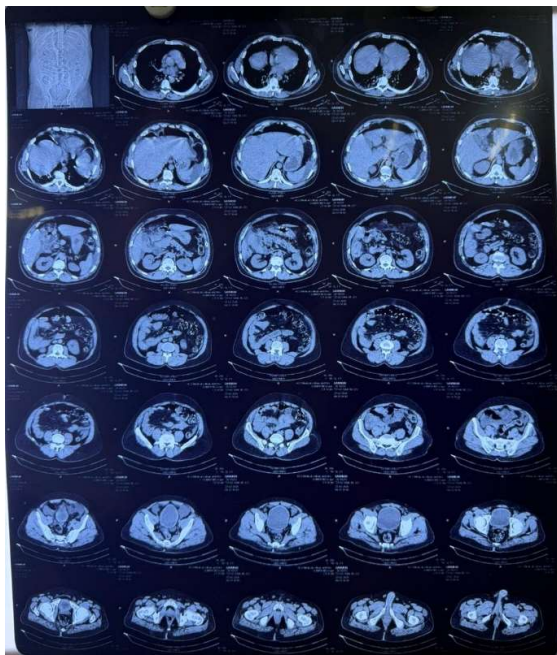
Subsequently, emergency computed tomography of the abdomen was obtained, which revealed moderate pneumoperitoneum with multiple air pockets adjacent to the pyloric antrum and pancreaticoduodenal groove, suggestive of hollow viscus perforation. Associated findings included edematous stomach, duodenum, and proximal jejunal loops with mild-to-moderate intraperitoneal free fluid and mesenteric haziness. Based on these findings, the patient was scheduled for emergency exploratory laparotomy.

While being shifted to the operating theatre, the patient suddenly developed palpitations, tachycardia, chest discomfort, and breathlessness. Electrocardiography demonstrated sinus tachycardia with ST-segment elevation and features suggestive of acute inferior wall myocardial infarction. Urgent cardiology consultation and two-dimensional echocardiography were obtained. Echocardiography revealed preserved left ventricular systolic function with mild concentric left ventricular hypertrophy and mild tricuspid regurgitation. In view of ongoing myocardial ischemia with concurrent perforation peritonitis, the patient was started on heparin infusion and was taken up for emergency surgery under high-risk perioperative monitoring.

The Phantom Perforation: Occult Duodenal Perforation with Adult Midgut Malrotation and Perioperative Myocardial Infarction

Exploratory laparotomy revealed approximately 1.5 liters of toxic intraperitoneal fluid and a perforation measuring approximately 2×1 cm in the first part of the duodenum (D1 region). An incidental congenital intestinal malrotation was also identified intraoperatively, characterized by abnormal bowel orientation with small bowel predominantly on the right side and large bowel on the left side. The ileocecal junction was abnormally positioned toward the left side. A Ryle's tube could not be negotiated beyond the pyloric region due to a hard, indurated, and stenosed antrum. Graham's omental patch repair of the duodenal perforation was performed along with extensive peritoneal lavage. Incidental appendectomy and abdominal drain placement were also carried out.

Postoperatively, the patient was managed in the intensive care unit with continued cardiology monitoring, anticoagulation, antibiotics, and supportive care. The postoperative course was complicated by intermittent oxygen desaturation requiring close monitoring. Despite the severe presentation involving perforation peritonitis, congenital malrotation, and acute perioperative myocardial infarction, the patient recovered satisfactorily following multidisciplinary management.



Discussion

The present case highlights an unusual and life-threatening combination of occult perforated duodenal ulcer, congenital intestinal malrotation, and acute perioperative myocardial infarction. The patient initially demonstrated deceptively benign imaging findings despite progressive clinical deterioration, emphasizing the importance of repeated clinical assessment and high suspicion in suspected hollow viscus perforation. Early diagnosis of perforated peptic ulcer (PPU) remains challenging because classical radiographic findings may be absent during the initial stages of perforation.[5]

The World Society of Emergency Surgery (WSES) guidelines published by Tarasconi et al. emphasized that prompt diagnosis and urgent surgical intervention are the

The Phantom Perforation: Occult Duodenal Perforation with Adult Midgut Malrotation and Perioperative Myocardial Infarction

most important determinants of survival in perforated peptic ulcer disease.[5] The guidelines reported that delayed surgery beyond 24 hours significantly increases mortality due to worsening peritonitis, sepsis, and multiorgan dysfunction.[5] In the present case, initial erect abdominal radiographs were repeatedly negative for pneumoperitoneum despite evolving perforation peritonitis. However, serial clinical examination demonstrated progression from localized epigastric tenderness to diffuse abdominal rigidity and guarding, which prompted repeat imaging and urgent computed tomography. This finding correlates with recommendations from current guidelines advocating CT abdomen as the most sensitive imaging modality when plain radiographs are inconclusive.[5]

Kumar et al., in a recent narrative review on current management of perforated peptic ulcer, observed that free air may be absent in up to 10–20% of patients during early presentation, particularly in sealed or small perforations.[6] The authors further highlighted that worsening clinical signs despite initially normal imaging should never delay surgical exploration.[6] Similar findings were observed in the present case where repeated abdominal radiographs remained normal, while CT abdomen subsequently demonstrated pneumoperitoneum with perigastric air pockets and intraperitoneal fluid collection. The temporary symptomatic relief following analgesic administration further masked the severity of pathology, contributing to the deceptive “phantom” presentation.

Arshad et al. described perforated peptic ulcer as a surgical emergency associated with mortality rates ranging between 6% and 30%, particularly among patients with delayed diagnosis, hemodynamic instability, and associated systemic complications.[7] Their review emphasized that Graham’s omental patch repair continues to remain the standard surgical procedure for most duodenal perforations.[7] In the present patient, emergency exploratory laparotomy revealed a 2 × 1 cm perforation in the first part of the duodenum with approximately 1.5 liters of toxic intraperitoneal fluid. Graham’s patch repair with extensive peritoneal lavage was successfully performed, resulting in favorable postoperative recovery despite significant perioperative risk.

Van Ligten et al. recently reported that perforated peptic ulcer can rapidly progress from localized abdominal pain to severe generalized peritonitis and septic physiology if diagnosis is delayed.[8] Their case report emphasized that early CT imaging and aggressive surgical management substantially improve survival.[8] Similarly, in the current patient, ultrasonographic evidence of pelvic free fluid and subsequent CT confirmation of pneumoperitoneum were critical in establishing the diagnosis after initially misleading investigations.

Mortality prediction in perforated peptic ulcer disease has been extensively studied by Thorsen et al., who demonstrated that delayed presentation, diffuse peritonitis,

septic shock, and associated comorbidities significantly increase mortality risk.[9] The present patient possessed several high-risk features including diffuse peritonitis, delayed radiological diagnosis, and acute perioperative myocardial infarction. Despite these adverse prognostic indicators, rapid multidisciplinary intervention contributed to successful recovery.

An additional rare finding in this case was incidental congenital intestinal malrotation identified intraoperatively. Adult intestinal malrotation is uncommon and frequently discovered incidentally during surgery performed for unrelated abdominal emergencies. The abnormal bowel orientation encountered intraoperatively increased operative complexity and contributed to the unusual anatomical presentation of disease.

Perioperative myocardial infarction represented another major challenge in the present case. Devereaux et al. demonstrated that postoperative myocardial injury significantly increases 30-day mortality following noncardiac surgery.[10] Similarly, Smilowitz and Berger emphasized that emergency abdominal surgeries are associated with substantial cardiovascular stress due to inflammatory response, fluid shifts, and hemodynamic instability.[11] In the present patient, sudden onset palpitations, tachycardia, breathlessness, and electrocardiographic ST-segment elevation occurred during transfer to the operating theatre, necessitating urgent cardiology evaluation and initiation of heparin infusion before surgery. Balancing active myocardial ischemia against the need for immediate laparotomy represented a significant perioperative challenge.

Thus, the present case represents a rare “triple-threat” emergency involving deceptive radiology, congenital intestinal malrotation, and acute perioperative myocardial infarction complicating perforated duodenal ulcer. The successful outcome highlights the importance of serial clinical evaluation, multidisciplinary coordination, repeated imaging, and timely surgical intervention even in the setting of severe systemic complications.

Conclusion

This case highlights a rare and life-threatening “triple-threat” surgical emergency involving occult perforated duodenal ulcer with initially deceptive imaging, incidental adult congenital intestinal malrotation, and acute perioperative myocardial infarction. The absence of pneumoperitoneum on repeated erect abdominal radiographs significantly delayed radiological diagnosis despite progressive clinical deterioration. The case emphasizes that worsening abdominal signs should always outweigh initially negative imaging findings, and early computed tomography should be strongly considered in suspicious cases. The coexistence of congenital malrotation further increased operative complexity, while perioperative myocardial infarction created a major anesthetic and

The Phantom Perforation: Occult Duodenal Perforation with Adult Midgut Malrotation and Perioperative Myocardial Infarction

surgical challenge requiring rapid multidisciplinary coordination. Prompt recognition, repeated clinical assessment, timely CT imaging, aggressive resuscitation, and emergency Graham's patch repair ultimately resulted in successful recovery. This case underlines the critical importance of maintaining high clinical suspicion and individualized multidisciplinary management in atypical presentations of perforation peritonitis.

References

1. Peiffer S, Pelton M, Keeney L, Kwon EG, Ofosu-Okromah R, Acharya Y, et al. Risk factors of perioperative mortality from complicated peptic ulcer disease in Africa: systematic review and meta-analysis. *BMJ Open Gastroenterol.* 2020;7(1):e000402. doi:10.1136/bmjgast-2020-000402.
2. Dadfar A, Edna TH. Epidemiology of perforating peptic ulcer: a population-based retrospective study over 40 years. *World J Gastroenterol.* 2020;26(35):5302-13. doi:10.3748/wjg.v26.i35.5302.
3. Bupicha JA, Gebresellassie HW, Alemayehu A. Pattern and outcome of perforated peptic ulcer disease patients in four teaching hospitals in Addis Ababa, Ethiopia: a prospective cohort multicenter study. *BMC Surg.* 2020;20(1):135. doi:10.1186/s12893-020-00802-x.
4. Rosa F, Covino M, Fransvea P, Cozza V, Quero G, Fiorillo C, et al. Gastric emergencies in older adults: not always the same old story! A tertiary care emergency department observational cohort study. *BMJ Open.* 2022;12(1):e054981. doi:10.1136/bmjopen-2021-054981.
5. Tarasconi A, Coccolini F, Biffi WL, Tomasoni M, Ansaloni L, Picetti E, et al. Perforated and bleeding peptic ulcer: WSES guidelines. *World J Emerg Surg.* 2020;15:3. doi:10.1186/s13017-019-0283-9.
6. Kumar S, Kumar S, Kumar A. Perforated peptic ulcer-current management: a narrative review. *Asian J Med Health.* 2023;21(11):128-36. doi:10.9734/ajmah/2023/v21i11896.
7. Arshad SA, Murphy P, Gould JC. Management of perforated peptic ulcer: a review. *JAMA Surg.* 2024;159(2):197-205. doi:10.1001/jamasurg.2023.5109.
8. Van Ligten MJ, et al. Perforated peptic ulcer: a case report of a dreaded surgical emergency. *Cureus.* 2024;16(5):e60767. doi:10.7759/cureus.60767
9. Thorsen K, Søreide JA, Søreide K. What is the best predictor of mortality in perforated peptic ulcer disease? A population-based study. *World J Surg.* 2021;45(2):439-48. doi:10.1007/s00268-020-05801-6.
10. Devereaux PJ, Biccard BM, Sigamani A, Xavier D, Chan MTV, Srinathan S, et al. Association of postoperative high-sensitivity troponin levels with myocardial injury and 30-day mortality among patients undergoing noncardiac surgery. *JAMA.* 2022;327(16):1642-51. doi:10.1001/jama.2022.4373.
11. Smilowitz NR, Berger JS. Perioperative cardiovascular risk assessment and management for noncardiac surgery. *JAMA.* 2020;324(3):279-90. doi:10.1001/jama.2020.7840.