

Burden and Pattern of Sinonasal Lesions in India: A Systematic Review of Clinicopathological Evidence

Thanishka Nallamothe¹, Suprita Savadatti², Anilkumar S. Harugop³ and Binsi Thomas⁴

^{1, 2, 3, 4} Department of Otorhinolaryngology and Head & Neck Surgery, Jawaharal Nehru Medical College, KAHER, Belgaum

Received: 28th Feb, 2026; Revised: 6th March 2026; Accepted: 7th April, 2026; Available Online: 20th April, 2026

ABSTRACT

Background: Lesions of the nasal cavity and paranasal sinuses represent a heterogeneous group of inflammatory, benign neoplastic and malignant conditions. Although inflammatory lesions are encountered most frequently in routine otorhinolaryngology practice, sinonasal malignancies are clinically important because of nonspecific symptoms, delayed presentation and proximity to the orbit, skull base and cranial cavity.

Objective: To synthesize Indian literature on nasal cavity and paranasal sinus lesions, with particular emphasis on the frequency, clinicopathological profile, anatomical distribution and diagnostic implications of malignant sinonasal tumors.

Methods: A systematic review was conducted according to the PRISMA 2020 framework. PubMed and Google Scholar were searched using combinations of terms related to nasal cavity lesions, paranasal sinus lesions, sinonasal tumors, malignancy, histopathology and India. Original Indian observational, retrospective, prospective, histopathological and clinicopathological studies were included. Case reports, review articles, conference abstracts, non-Indian studies and articles without adequate extractable data were excluded. After removal of duplicate reference entries and repeated citations, eight unique Indian studies were retained for final synthesis.

Results: A total of 178 records were identified, 142 records were screened after duplicate removal, 18 full-text reports were assessed for eligibility and 8 unique studies involving 1,130 patients were included. Non-neoplastic inflammatory lesions formed the dominant diagnostic category. In one 90-case series, 52 of 63 nasal and paranasal sinus masses were non-neoplastic, corresponding to 82.5% of masses in that anatomical group, while inflammatory polyps represented 86.5% of non-neoplastic lesions. In another 50-case series, malignant lesions accounted for 8% of diagnoses; nasal obstruction was reported in 58%, nasal discharge in 34% and postnasal discharge in 22%. Unilateral disease was reported in 68% and bilateral disease in 32% in the same series. Squamous cell carcinoma was the most consistently reported malignant histology across the corrected review.

Conclusion: Indian clinicopathological studies show that sinonasal masses are predominantly inflammatory, but a smaller malignant subset is clinically significant because it may mimic benign disease and present late. Persistent unilateral obstruction, epistaxis, facial swelling, proptosis or radiological evidence of erosion should prompt imaging and histopathological confirmation. The available literature supports descriptive quantitative synthesis, but heterogeneity in reporting precludes formal meta-analysis.

Keywords: Paranasal sinus; nasal cavity; sinonasal malignancy; squamous cell carcinoma; histopathology; India; systematic review; PRISMA

How to cite this article: Nallamothe T, Savadatti S, Harugop AS, Thomas B. Burden and Pattern of Sinonasal Lesions in India: A Systematic Review of Clinicopathological Evidence. Int J Drug Deliv Technol. 2026;16(53s): 923-928. DOI: 10.25258/ijddt.16.53s.147

Source of support: Nil.

Conflict of interest: None

INTRODUCTION

Lesions of the nasal cavity and paranasal sinuses include a wide pathological spectrum ranging from non-neoplastic inflammatory disorders to benign neoplasms and aggressive malignant tumors. This diversity is clinically important because inflammatory polyps, fungal or infective lesions, benign tumors and early malignant tumors may present with overlapping symptoms such as nasal obstruction, discharge, epistaxis or facial discomfort [1,4]. Sinonasal malignancies constitute a relatively small

proportion of head and neck cancers, but their impact is disproportionate because of late presentation and complex regional anatomy. Tumors arising in the nasal cavity or paranasal sinuses may remain clinically silent until they extend into the orbit, pterygopalatine fossa, oral cavity, cranial cavity or facial soft tissues [3,6]. The clinical distinction between benign and malignant sinonasal disease is often difficult at first presentation. Persistent unilateral nasal obstruction, recurrent epistaxis, facial swelling, proptosis, visual disturbance or cranial nerve

*Author for Correspondence: Thanishka Nallamothe

symptoms should increase suspicion for neoplasia, particularly in older patients [3,4]. Histopathological examination remains the diagnostic gold standard. Imaging with computed tomography and magnetic resonance imaging is essential for defining bony destruction, soft tissue extension, orbital or intracranial spread and surgical planning, but imaging alone cannot reliably establish the final histological diagnosis [3,7]. Indian studies are particularly relevant because sinonasal pathology in India includes common inflammatory lesions as well as regionally influenced entities such as rhinosporidiosis. Indian tertiary care series also provide useful information on demographic patterns, clinical presentation and the burden of squamous cell carcinoma among malignant sinonasal tumors [1,7]. This systematic review was therefore recompiled to provide a corrected, deduplicated and quantitatively oriented synthesis of Indian studies on nasal cavity and paranasal sinus lesions, with emphasis on malignancies. The revised manuscript specifically aligns the study count, extracted data, Results, Discussion and reference list with the corrected dataset of eight unique studies.

Materials and Methods

This systematic review was conducted in accordance with the Preferred Reporting Items for Systematic Reviews and Meta-Analyses (PRISMA) 2020 framework. The objective was to identify Indian studies reporting original clinical, histopathological or diagnostic data on lesions of the nasal cavity and paranasal sinuses, with a focused synthesis of malignant lesions.

Search strategy

A structured search was conducted using PubMed and Google Scholar up to April 2024. The search terms included combinations of “nasal cavity lesions,” “paranasal sinus lesions,” “sinonasal tumors,” “sinonasal

malignancy,” “histopathology,” “clinicopathological study” and “India.” Boolean operators were used to combine disease terms with anatomical and geographic terms. Reference lists of eligible articles were also reviewed to identify additional relevant Indian studies.

Eligibility criteria

Studies were eligible if they were conducted in India, reported original patient-level or study-level data, and evaluated histopathological, clinical or diagnostic aspects of nasal cavity and paranasal sinus lesions. Retrospective, prospective, observational, cross-sectional, histopathological and clinicopathological studies were included. Studies focusing on non-neoplastic, benign neoplastic and malignant lesions were considered eligible if they contributed extractable data relevant to the review objective.

Case reports, conference abstracts, editorials, narrative reviews, non-English publications, animal studies, studies involving non-Indian populations and articles without adequate full-text or extractable data were excluded. Duplicate reference entries and repeated citations referring to the same study were removed before final synthesis.

Study selection and data extraction

Titles and abstracts were screened for relevance, followed by full-text assessment of potentially eligible articles. Data were extracted on author, year, study design, anatomical site, lesion spectrum, sample size when available, benign and malignant lesion categories, common histopathological diagnoses, clinical symptoms, demographic pattern, radiological evaluation and diagnostic confirmation. Because the included studies varied in anatomical grouping and reporting format, all extractable numerical data were summarized descriptively rather than pooled through meta-analysis.

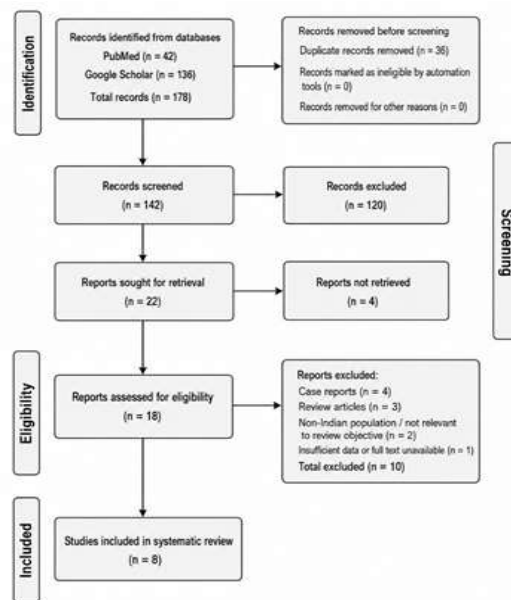


Figure 1. PRISMA 2020 flow diagram for study selection

Quality assessment and synthesis approach

The included studies were assessed descriptively for representativeness of the clinical sample, clarity of diagnostic confirmation, histopathological reporting and availability of quantitative outcome data. The evidence base consisted of observational and clinicopathological studies, so the review was synthesized using descriptive quantitative analysis. Percentages were calculated from extractable numerator and denominator data where available. A formal meta-analysis was not performed because of heterogeneity in study design, inclusion criteria, anatomical grouping and outcome reporting.

RESULTS

The corrected search and selection process identified 178 records, of which 42 were retrieved from PubMed and 136 from Google Scholar. After removal of 36 duplicate records, 142 records were screened. Of these, 120 were excluded at title and abstract screening, leaving 22 reports

sought for retrieval. Four reports could not be retrieved, and 18 full-text reports were assessed for eligibility. Ten full-text reports were excluded because they were case reports, review articles, non-Indian or not relevant to the review objective, or had insufficient data. The final corrected synthesis included 8 unique Indian studies, representing 4.5% of initially identified records and 44.4% of full-text reports assessed for eligibility.

The total sample size across the corrected included dataset was 1,130 patients. As represented in Table 1, the studies were observational, retrospective, prospective, histopathological or clinicopathological in design. All eight studies contributed to qualitative synthesis, while only a subset provided extractable numerical data suitable for descriptive quantitative analysis. The evidence base was therefore summarized as a corrected descriptive synthesis rather than a meta-analysis.

Table 1: Study-wise extraction summary after removal of duplicate references

Ref.	Study	Year	Design / focus	Study population / sample	Main extractable findings
1	Sharma R et al.	2016	Histopathological study	Nasal cavity, paranasal sinus and nasopharyngeal lesions	Reported broad histopathological spectrum, including inflammatory lesions, rhinosporidiosis, benign neoplasms and malignant tumors.
2	Kumar R and Bhattacharjee BK	2021	Retrospective clinical study	Tumors of nose and paranasal sinuses	Contributed clinical tumor data; malignant tumors were described more often in older patients, with male predominance.
3	Ghosh SN et al.	2014	Malignant tumor-focused study	Malignant tumors of nasal cavity and paranasal sinuses	Highlighted diagnostic challenges in sinonasal malignancy; SCC was the dominant malignant histology, with other rare malignant types reported.
4	Narkhede DD and Anvikar AR	2017	Clinicopathological study	90 cases; 63 nasal/PNS masses and 27 nasopharyngeal masses	Among 63 nasal/PNS masses, 52 were non-neoplastic and 11 neoplastic; inflammatory polyps formed 86.5% of non-neoplastic lesions.
5	Singh V et al.	2013	Clinicopathological study	Nasal and paranasal masses	Reported benign and malignant sinonasal masses; maxillary sinus involvement and male predominance were emphasized.
6	Avasthi K et al.	2013	Clinicopathologic study	Tumors and tumor-like conditions of nasal cavity and paranasal sinuses	Included benign entities such as inverted papilloma and malignant tumors such as SCC and other rare histologies.
7	Pandit R and Shinde KJ	2016	Histopathological study	Lesions of nasal cavity, paranasal sinuses and nasopharynx	Reported inflammatory, infective, benign and malignant lesions; rhinosporidiosis and need for histopathological confirmation were emphasized.
8	Jhahhria A et al.	2021	Clinicopathological study	Nasal and paranasal masses	Contributed tertiary-care clinicopathological data on inflammatory lesions, benign tumors and malignant tumors, including SCC.

Non-neoplastic inflammatory lesions were the dominant category wherever lesion-category data were extractable. In one 90-case study, 63 cases involved the nasal cavity and paranasal sinuses and 27 involved the nasopharynx. Among the 63 nasal and paranasal sinus masses, 52 were non-neoplastic, corresponding to 82.5%, while 11 were neoplastic, corresponding to 17.5%. In the same study, inflammatory polyps formed 86.5% of non-neoplastic lesions, supporting the conclusion that inflammatory disease was the major contributor to sinonasal mass lesions [4]. A second 50-case study provided additional quantitative detail. In that series, malignant disease accounted for 8% of histopathological diagnoses, while nasal polyps represented 42% of cases. Squamous cell carcinoma accounted for 4% of all cases, making it the

principal malignant diagnosis reported in that dataset. Across the corrected review, squamous cell carcinoma remained the most consistently reported malignant histology, while adenocarcinoma, adenoid cystic carcinoma, olfactory neuroblastoma and sinonasal undifferentiated carcinoma were reported less frequently [3,4].

As shown in Table 2, the clinical symptom profile was quantitatively dominated by nasal obstruction. In the 50-case series, nasal obstruction was reported in 58% of patients, nasal discharge in 34%, postnasal discharge in 22%, epistaxis in 14% and facial swelling in 12%. These findings show that the most frequent symptoms were nonspecific and overlapped substantially between inflammatory, benign and malignant lesions [4].

Table 2: Quantitative study level data

Domain	Quantitative result	Interpretation
Nasal obstruction	58%	Most common presenting symptom
Nasal discharge	34%	Second frequent symptom
Postnasal discharge	22%	Common associated symptom
Epistaxis	14%	Clinically relevant red-flag symptom when persistent or unilateral
Facial swelling	12%	Suggestive of advanced or expansile disease when present
Unilateral involvement	68%	Unilateral disease was more common than bilateral disease
Bilateral involvement	32%	Often associated with inflammatory disease but not diagnostic alone
Male-to-female ratio	29:21; 1.38:1	Male preponderance in the extractable dataset
Clinico-histopathological correlation	84% correlation; 16% discordance	Supports mandatory tissue diagnosis

Laterality was extractable in the same 50-case dataset.

Unilateral involvement was reported in 68% of patients, while bilateral involvement was present in 32%. Although unilateral disease can occur in benign conditions, persistent unilateral symptoms in association with bleeding, facial swelling, proptosis, radiological erosion or older age were repeatedly emphasized as clinically suspicious features [3,4]. Symptom duration also suggested delayed presentation. In the 50-case series, 42% of patients had symptoms for 2-5 years and 40% had symptoms for 6 months-2 years. Thus, 82% of patients had symptoms persisting for at least 6 months before definitive evaluation, highlighting the chronic and often neglected nature of sinonasal disease in tertiary care cohorts [4]. Demographic data showed a male preponderance in studies reporting sex distribution. The 50-case study included 29 males and 21 females, producing a male-to-female ratio of 1.38:1, with an age range of 11-75 years. The broader corrected synthesis indicated that malignant lesions were encountered more commonly in older age groups, particularly in the fifth to seventh decades, while inflammatory and benign lesions appeared across a wider age range [4,6]. The nasal cavity and maxillary sinus were the most repeatedly emphasized anatomical sites. The 90-case study separated 63 nasal and paranasal sinus masses from 27 nasopharyngeal masses, while other included

studies described maxillary sinus predominance among paranasal sinus tumors. The maxillary sinus was particularly important in malignant disease because tumors may remain clinically occult until local extension has occurred [2,3]. Histopathological examination was the definitive diagnostic modality across the included studies. One 50-case study reported clinico-histopathological correlation in 84% of cases, while 16% showed discordance between clinical impression and final histopathological diagnosis. This finding quantitatively supports the need for tissue diagnosis in all persistent or suspicious sinonasal masses [4].

DISCUSSION

This recompiled systematic review provides a corrected quantitative synthesis of Indian literature on nasal cavity and paranasal sinus lesions after removal of duplicate reference entries. The final evidence base consisted of 8 unique studies involving 1,130 patients. Although this is a modest dataset, it is clinically useful because it represents tertiary-care Indian experience and includes inflammatory, infective, benign neoplastic and malignant sinonasal pathologies. The PRISMA pathway also shows that the included evidence represents a relatively selected subset of the available literature. Only 8 of 178 initially identified records were included, corresponding to an inclusion rate of 4.5%. This low inclusion rate reflects the narrow

eligibility criteria, exclusion of case reports and reviews, removal of duplicates, and the requirement for original Indian data relevant to nasal cavity and paranasal sinus lesions. The strongest quantitative trend is the predominance of non-neoplastic inflammatory disease. In the extractable 90-case clinicopathological study, 52 of 63 nasal and paranasal sinus masses were non-neoplastic, giving a proportion of 82.5%. Inflammatory polyps accounted for 86.5% of non-neoplastic lesions in that dataset, and a separate 50-case series reported nasal polyps in 42% of cases. These values support the overall conclusion that most sinonasal masses encountered in Indian tertiary care practice are inflammatory rather than malignant [4].

However, the smaller malignant fraction remains clinically important. In the 50-case dataset, malignant disease accounted for 8% of histopathological diagnoses, while squamous cell carcinoma accounted for 4% of all cases. Although these percentages appear numerically low, the clinical burden is high because sinonasal malignancies often present late, mimic chronic inflammatory disease and may involve the orbit or skull base at diagnosis [3,4]. Squamous cell carcinoma was the most consistently reported malignant histology across the corrected review. This pattern is consistent with the epithelial lining of the sinonasal tract and with the repeated observation in Indian clinicopathological studies that SCC forms the dominant malignant sinonasal tumor. Less frequent malignant entities such as adenocarcinoma, adenoid cystic carcinoma, olfactory neuroblastoma and sinonasal undifferentiated carcinoma were also represented, but the available data were insufficient for meaningful pooled subtype-specific percentage estimates [3,6]. The quantitative symptom distribution explains why clinical diagnosis is difficult. Nasal obstruction was reported in 58% of patients in the 50-case series, making it the most common symptom, but it is also the commonest symptom of benign inflammatory sinonasal disease. Nasal discharge was reported in 34% and postnasal discharge in 22%, further emphasizing that the presenting profile is often nonspecific [4]. Epistaxis and facial swelling were less frequent but more concerning symptoms. In the same 50-case series, epistaxis occurred in 14% and facial swelling in 12%. These symptoms should be interpreted with greater caution when they are unilateral, persistent, recurrent or associated with radiological bone erosion, proptosis, facial deformity or cranial nerve involvement [3,4]. Laterality is clinically relevant in risk stratification. Unilateral disease was reported in 68% of patients in the extractable 50-case series, while bilateral disease was present in 32%. Since inflammatory polyps can be bilateral and benign or malignant tumors often present unilaterally, laterality alone is not diagnostic; however, unilateral obstruction with bleeding or progressive swelling should prompt endoscopic assessment and biopsy [4]. The duration of symptoms also suggests delayed clinical presentation. In the 50-case series, 42% of patients had symptoms for 2-5 years and 40% had symptoms for 6 months-2 years. Therefore, 82% of patients had symptoms

for at least 6 months, showing that many sinonasal lesions are evaluated only after a prolonged symptomatic period [4]. The demographic data provide additional context but should not be overinterpreted. The 50-case series reported 29 males and 21 females, giving a male-to-female ratio of 1.38:1. Across the broader corrected synthesis, malignant lesions were more commonly described in older age groups, particularly the fifth to seventh decades, while inflammatory and benign lesions had a wider age distribution [4,6]. Anatomical site distribution also has practical implications. The nasal cavity and maxillary sinus were repeatedly emphasized as common sites, and maxillary sinus involvement was particularly relevant in malignant disease. The maxillary sinus can accommodate tumor growth before producing obvious external signs, which may contribute to delayed recognition and advanced local extension [2,3]. The diagnostic correlation data strongly support routine histopathological confirmation. The reported clinico-histopathological correlation of 84% indicates that clinical diagnosis was concordant with histopathology in most cases, but the 16% discordance rate is clinically significant. This means that approximately one in six patients had a final histopathological diagnosis that differed from the clinical impression, reinforcing the need for biopsy of suspicious or persistent lesions [4]. Radiological evaluation remains essential but complementary. Computed tomography is particularly useful for assessing bony erosion, sinus opacification, osteomeatal involvement, orbital wall changes and surgical anatomy. Magnetic resonance imaging is more helpful for soft tissue extension, perineural spread, orbital invasion and intracranial involvement. Nevertheless, neither modality replaces histopathological diagnosis [3,7]. The quantitative synthesis also exposes limitations in the Indian evidence base. Several studies combine nasal cavity, paranasal sinus and nasopharyngeal lesions, making site-specific pooling difficult. Others report broad histopathological categories without standardized denominators for benign, malignant and non-neoplastic subgroups. These inconsistencies prevent formal meta-analysis and limit the precision of pooled prevalence estimates. Despite these limitations, the corrected data support a practical clinical message. Most sinonasal masses in Indian tertiary care settings are inflammatory, but a meaningful minority are neoplastic or malignant. Therefore, persistent unilateral nasal obstruction, epistaxis, facial swelling, proptosis, visual symptoms or radiological erosion should not be treated as routine rhinosinusitis without endoscopic and histopathological evaluation.

Future Indian studies should use standardized reporting templates that separately document nasal cavity, maxillary sinus, ethmoid sinus, frontal sinus, sphenoid sinus and nasopharyngeal lesions. They should also provide exact numbers for inflammatory polyps, infective lesions, benign tumors, malignant tumors, histological subtypes, symptom profile, laterality, imaging findings, treatment and outcomes. Such reporting would allow stronger pooled analysis and more precise estimation of malignancy burden in the Indian population.

CONCLUSION

The recompiled corrected review includes 8 unique Indian studies involving 1,130 patients. Quantitative descriptive synthesis shows that non-neoplastic inflammatory lesions, especially inflammatory nasal polyps, form the dominant category of nasal cavity and paranasal sinus masses. However, sinonasal malignancies remain clinically important because they may present with symptoms similar to benign disease and are often diagnosed late. Squamous cell carcinoma was the most consistently reported malignant histology. Nasal obstruction was the most frequent symptom, but unilateral symptoms, epistaxis, facial swelling, proptosis, visual complaints or radiological erosion should raise suspicion for neoplasia. Histopathological examination remains mandatory for definitive diagnosis, while CT and MRI are essential for mapping disease extent and planning treatment. The current Indian literature supports descriptive quantitative synthesis, but standardized multicentric reporting is needed for future meta-analysis.

LIMITATIONS AND SCOPE FOR FUTURE RESEARCH

The main limitation of this review is the heterogeneity in study design, anatomical grouping, lesion classification, and numerical reporting, which restricted the analysis to descriptive synthesis rather than formal meta-analysis. Future research should include large multicentric Indian studies with standardized clinical, radiological, histopathological, and outcome reporting. Emphasis should be placed on early indicators of malignancy, site-specific tumor patterns, advanced imaging, immunohistochemistry, treatment outcomes, and the development of regional or national sinonasal tumor registries.

REFERENCES

1. Sharma R, Sharma A, Goyal R, Sharma AK. Histopathological study of lesions of nasal cavity, paranasal sinuses and nasopharynx. *Int J Res Med Sci.* 2016;4(8):3312-6.
2. Kumar R, Bhattacharjee BK. Clinical Study of Tumors of Nose and Paranasal Sinuses - A Retrospective Study. *JMSCR.* 2021;9(3):1743-8.
3. Ghosh SN, Bhattacharya A, Chowdhury K, Das A, Banerjee S. Diagnostic challenges in malignant tumors of nasal cavity and paranasal sinuses. *Indian J Otolaryngol Head Neck Surg.* 2014;66(4):382-7.
4. Narkhede DD, Anvikar AR. A clinicopathological study of masses of nasal cavity, paranasal sinuses and nasopharynx. *MVP J Med Sci.* 2017;4(2):147-52.
5. Singh V, Pal US, Harsh M, Kumar A, Singh RK, Mohammad S. A clinicopathological study of nasal and paranasal masses. *Natl J Maxillofac Surg.* 2013;4(2):180-4.
6. Avasthi K, Mehta S, Parikh A. Tumors and tumor-like conditions of the nasal cavity and paranasal sinuses: A clinicopathologic study. *Indian J Otolaryngol Head Neck Surg.* 2013;65(Suppl 1):35-9.
7. Pandit R, Shinde KJ. A histopathological study of lesions of nasal cavity, paranasal sinuses and nasopharynx in a tertiary care center. *Med J DY Patil Univ.* 2016;9(6):727-32.
8. Jhahria A, Kumar S, Singh S, Pareek S. A clinicopathological study of nasal and paranasal masses in a tertiary care hospital. *JMSH.* 2021;7(1):26-30.