

Morphological Variations Of The Structures At The Hilum Of Bilateral Lungs: A Cadaveric Study.

Payal Dey¹, Dr. Rachna Rohatgi², Dr. Amrita Bharti³, Dr. Nirupma Gupta⁴, Dr. Shalini Rastogi⁵, Dr. Aditi Bhatnagar⁶

¹MSc in Medical Anatomy, Department of Anatomy, Sharda School of Medical Science & Research.

² Professor & Head of Department, Department of Anatomy, Sharda School of Medical Science & Research.

³ Associate Professor, Department of Anatomy, Sharda School of Medical Science & Research.

⁴ Professor & Dean, Sharda School of Medical Science & Research.

⁵ Professor, Department of Physiology, Sharda School of Medical Science & Research.

⁶ Professor, Department of Anatomy, Sharda School of Medical Science & Research.

Corresponding Author

Dr. Amrita Bharti

Associate Professor, Department of Anatomy, Sharda School of Medical Science & Research.

Email ID : amrita.bharti@sharda.ac.in

ABSTRACT

Background: The hilum of both lung contains the pulmonary artery, pulmonary veins, main bronchus, bronchial arteries and the arrangement of these structures differs between the right and left lungs. Aim of the present study was to study the morphological Variation of the Structures at the Hilum of Lungs. Objective. To Measure Vertical and Antero-posterior Length of Hilum of the Lungs. 2. To Study the Morphological Variation of Structure of the Hilum of Lung. 3. To Study the Relation and Arrangement of the Structure of the Hilum of Lung. 4. To Study the Bilateral Difference and Left and Right Lung. **Methods:** The present study involves 60 cadaveric lungs, comprising 30 right and 30 left lungs, to evaluate the morphometric and morphological variations of the pulmonary hilum. The vertical (V) and anteroposterior (AP) dimensions of the hilum will be measured using digital vernier calipers. In addition, morphological variations such as the number of hilar structures, including pulmonary arteries, pulmonary veins, and bronchi, along with their specific spatial arrangements, will be carefully documented. A comparative analysis will also be performed to identify bilateral differences between the left & right lungs. **Conclusion:** The lung hilum showed consistent side-based differences, with the right lung exhibiting a larger vertical and anteroposterior dimension. Several variations in bronchovascular arrangement, including accessory veins and altered bronchial branching, were also documented. These findings reaffirm that pulmonary hilar anatomy, though predictable, demonstrates notable individual variation

Keywords pulmonary hilum, bronchovascular arrangement, cadaveric study, morphometric analysis, anatomical variation, thoracic anatomy

How to cite this article: Dey P, Rohatgi R, Bharti A, Gupta N, Rastogi S, Bhatnagar A., Morphological Variations Of The Structures At The Hilum Of Bilateral Lungs: A Cadaveric Study...Int J Drug Deliv Technol. 2026;16(53s): 70-82. DOI: 10.25258/ijddt.16.53s.8

Source of support: Nil.

Conflict of interest: Nil.

INTRODUCTION

The pulmonary hilum, situated on medial surface of each lungs, serves as gateway for all structures entering and exiting the lung. It accommodates the main bronchus, pulmonary artery, pulmonary veins, bronchial vessels- collectively forming the root of the lung. Standring (1) has noted that although the hilar region follows a broadly predictable anatomical plan, it exhibits considerable individual variability with direct clinical and surgical implications.

The hilum structures arrangement differs between both lungs. On right lung, the superior-to-inferior order is the eparterial bronchus- pulmonary artery- hyperarterial bronchus & inferior pulmonary veins, whereas on the left lung, the pulmonary artery lies most superiorly, followed by the primary bronchus and inferior pulmonary veins. On the right & left lung, anterior-toposterior sequence is

pulmonary vein, pulmonary artery and bronchus. Moore and Dalley (2) have emphasized that cadaveric dissection remains essential for appreciating these relationships in three dimensions, as imaging alone is insufficient. Sadler (3) attributes side-specific differences to the differential rotation and asymmetric growth of the lung buds during embryological development, which also accounts for the variations - including accessory bronchi, anomalous pulmonary veins, and atypical arterial branching - frequently documented in cadaveric studies.

Such variations carry significant clinical relevance. They can complicate surgical dissection, increase the risk of intraoperative vascular or bronchial injury, and affect radiological interpretation. Kumari et al. (4) have highlighted that surgeons must be aware of bronchovascular arrangement variants to prevent hemorrhage and bronchial

Morphological Variations Of The Structures At The Hilum Of Bilateral Lungs: A Cadaveric Study.

damage during procedures such as lobectomy and segmentectomy.

AIM & OBJECTIVES

Aim: - Cadaveric Study of Morphological Variation of The Structure at Hilum of Lung.

Objectives

To Measure Vertical and Antero-posterior Length of Hilum of the Lung.

To Study the Morphological Variation of Structure of the Hilum of Lung.

3.To Study the Relation and Arrangement of the Structure of the Hilum of Lung.

4.To Study the Bilateral Difference and Left and Right Lung.

MATERIALS AND METHODS

Study Design

The present research is a **cross-sectional cadaveric study** conducted in the Department of Anatomy, designed to evaluate the morphological and morphometric variations of the hilum of lungs. The study involves systematic dissection, observation, measurement, documentation, and statistical analysis of the hilar structures of all selected cadaveric specimens.

Study Duration

The study was carried out over a period of **12 months**, including data collection, specimen processing, measurement recording, and statistical analysis.

Study Area

The Study will be conducted in “Department of Anatomy” School of Medical Sciences & Research, Sharda University, Greater Noida.

Sample Size

A total of 60 organs, the following organs were dissected bilaterally:

Lungs (Right and Left)

Inclusion Criteria

Adult embalmed cadavers available in the Anatomy Department.

Cadavers with intact thoracic and abdominal cavities.

Cadavers with organs in good preservational condition.

Cadavers with no visible congenital anomalies of the thoracic or abdominal organs.

Exclusion Criteria

Cadavers with damaged or previously dissected thoracic/abdominal cavities.

Cadavers showing pathological deformities or traumatic injury affecting hilar structures.

Cadavers with malformed organs or surgical alterations.

Materials Required

Dissection instruments (scalpel, forceps, scissors, bone cutter).

Vernier caliper (digital/manual) to measure hilar dimensions.

Measuring scale and thread for curved measurement.

Camera (high-resolution) for documentation.

Disposable gloves, mask, lab coat.

Data collection sheet / proforma.

Formalin-preserved cadavers.

SPSS (version 22) for statistical analysis.

Microsoft Excel spreadsheet.

Data Collection

A structured proforma was used to record:

Side (right/left for lungs)

Vertical length of hilum

Anteroposterior (AP) diameter

Number of vessels entering/exiting

Arrangement and relation of structures (Anterior to posterior and superior to inferior)

Presence of variation in branching pattern left to right

Photographic documentation

Parameters Measured

Vertical length (**mm**)

AP (anteroposterior) diameter (**mm**)

Number of arterial branches

Number of venous channels

Pattern of arrangement

Accessory structures

Statistical Analysis

All collected data were compiled in Microsoft Excel and analyzed using SPSS version 22.

Tests Applied:

Test for Normality

Kolmogorov–Smirnov test applied to determine distribution of quantitative data.

Descriptive Statistics

Mean, standard deviation, median, range for quantitative variables.

Frequency, percentage, graphical representation for qualitative variables.

Inferential Statistics

Student’s t-test: to compare means between right and left organs (lungs).

Chi-square test: to test association between categorical variables.

Karl Pearson’s correlation coefficient: to analyze relationship between two quantitative variables.

Significance level:

○ $p < 0.05$ considered statistically significant.

Limitations

Limited sample size due to availability of cadavers.

Age and medical history of cadavers often unknown.

Formalin fixation may alter organ dimensions slightly.

RESULTS

The following tables of the morphometric and morphological evaluation of the hilar structures of lungs.

Data were analyzed using **SPSS Version 22**, and results are expressed through descriptive & inferential statistics.

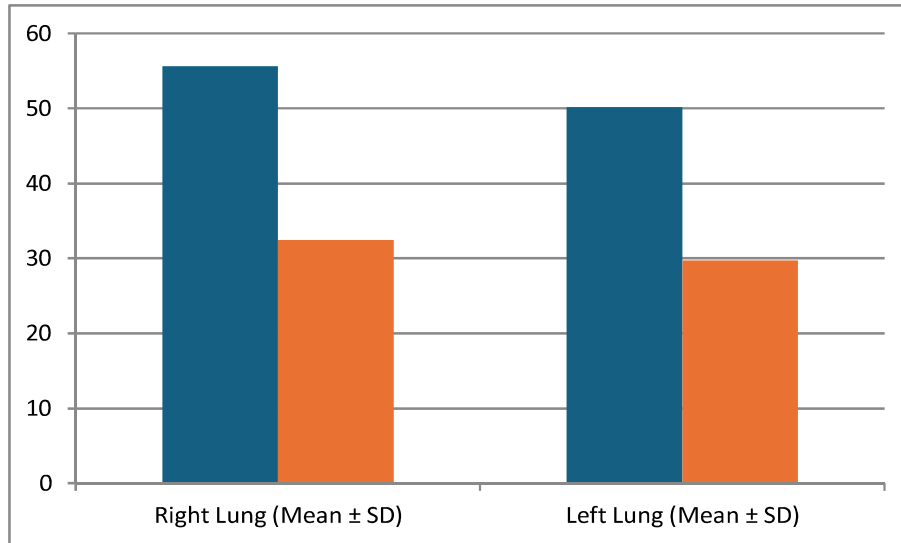
A total of 60 lungs were studied

Lung Hilum Morphometry

Descriptive Statistics

Table 1: Mean Vertical and AP Diameter of Lung Hilum (Right & Left)

Parameter	Right Lung (Mean ± SD)	Left Lung (Mean ± SD)	p-value (t-test)
Vertical Length (mm)	55.62 ± 6.21	50.14 ± 5.83	0.001
AP Diameter (mm)	32.48 ± 4.10	29.73 ± 3.85	0.004



Interpretation:

The data clearly indicates that there is a statistically significant difference between the dimensions of the right and left lungs. The vertical length of the right lung (55.62 ± 6.21 mm) is noticeably greater than that of the left lung (50.14 ± 5.83 mm), with a p-value of 0.001, confirming that this difference is highly significant. Similarly, the antero-posterior (AP) diameter also shows a significant variation, where the right lung (32.48 ± 4.10 mm) measures larger compared to the left lung (29.73 ± 3.85 mm), supported by

a p-value of 0.004. These findings reflect the natural anatomical asymmetry of the human thoracic cavity, where the right lung accommodates more space due to the position of the heart on the left side. The consistent significance across both parameters suggests that these variations are not due to chance but represent true anatomical differences. Thus, the results reinforce established anatomical knowledge and highlight the importance of considering side-specific variations in clinical assessment, diagnostic imaging, and surgical planning

Right lung hilum structures arrangement

Table 2: Types of Hilar Arrangement in Right Lungs (Anterior to Posterior)

Arrangement Pattern	N=30
V-A-B (Normal)	21(70%)
B-A-V	1(3.3%)
V-V-B	3(10%)

A-B-V	5(16.6%)
-------	----------

V= Superior Pulmonary Vein, B=Bronchus, A= Artery

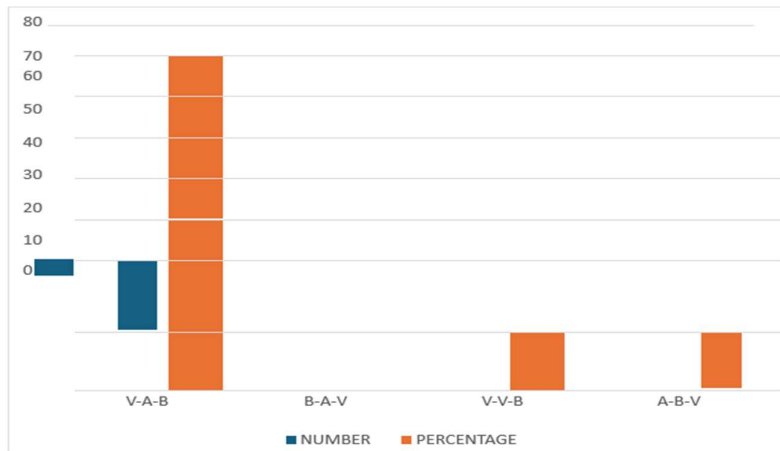


Fig. 1 - Mediastinal surface of right lung (Anterior - Posterior) : most superiorly Pulmonary vein- Pulmonary artery - Bronchus (Normal).

Vein = Red flag, Artery = Blue flag, Bronchus = White



Fig. 2 - Mediastinal surface of right lung (Anterior - Posterior) : anteriorly Two Pulmonary artery - one Bronchus (variation).

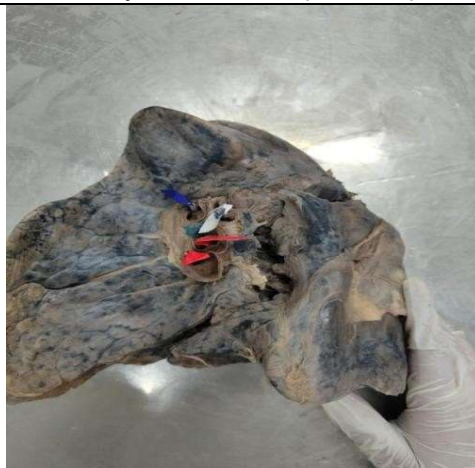

Table 3: Types of Hilar Arrangement in left Lungs (Anterior to Posterior)

Arrangement Pattern	N=30
V-A-B (Normal)	7 (23.3%)
V-B-A	6(20%)
A-B-V	9 (30%)
A-B-A	3 (10%)
A-B-B	1(3.3%)
A-V-B	2 (6.6%)
B-V- A	1 (3.3%)
V-V-B	1 (3.3%)

A= Artery, V=Vein, B=Bronchus

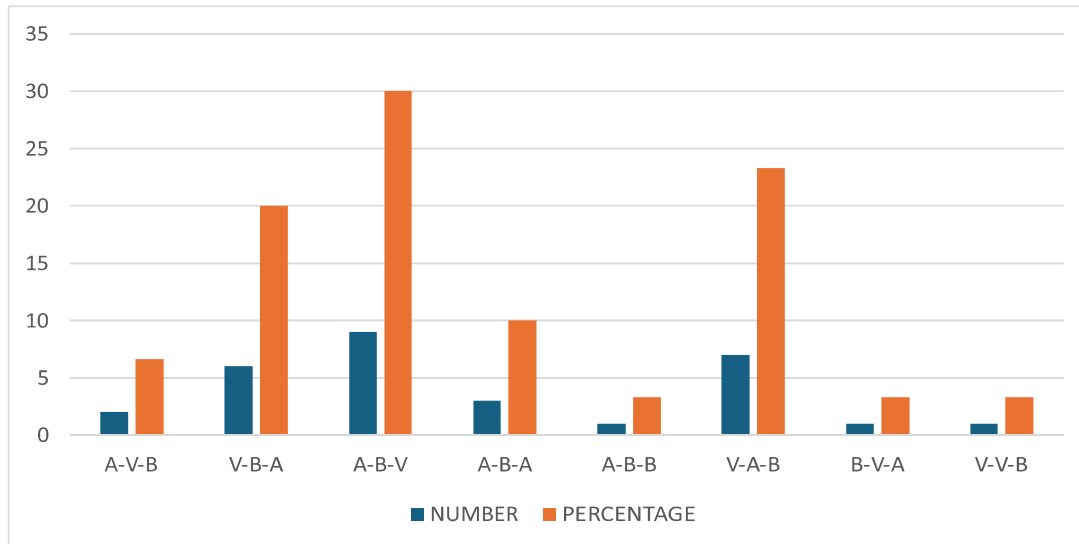

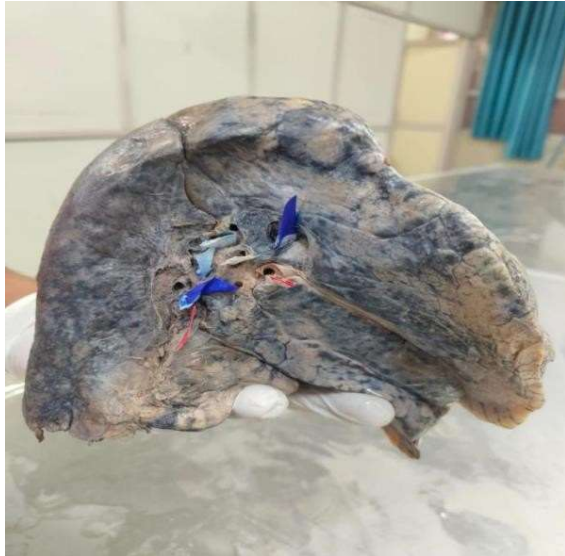


Fig. 3 - Mediastinal surface of left lung (Anterior to Posterior) : Pulmonary artery - three Bronchus (variation).

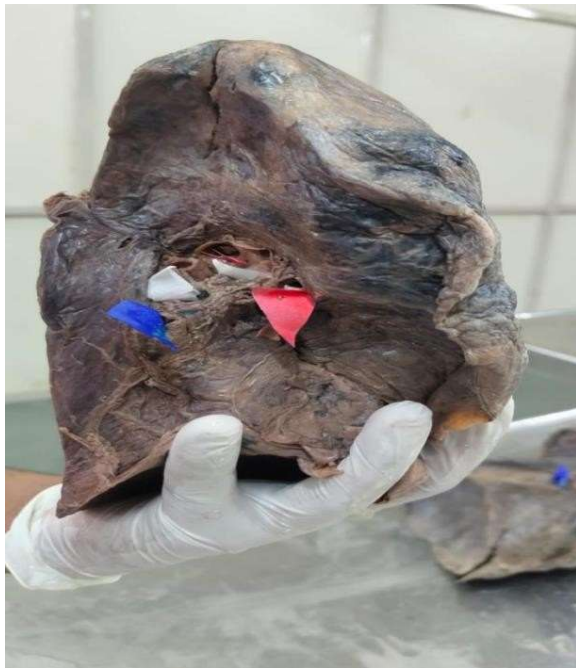

Fig. 4 - Mediastinal surface of left lung (Anterior to Posterior) : most anterior Pulmonary vein - two Bronchus - Pulmonary Artery (variation).

Interpretation:

In the present cadaveric study, notable side-specific differences were observed in the bronchovascular arrangement at the lung hilum. On the right side, the V-A-B pattern constituted the majority (70%), indicating that the pulmonary vein tends to occupy the most anterior position, followed by the artery and then the bronchus posteriorly in most specimens. In contrast, the left lung more frequently exhibited the A-B-V configuration (30%), reflecting a

relative anterior or superior disposition of the pulmonary artery with the vein lying more inferiorly or anteriorly in fewer cases. The V-V-B pattern was the least common on both sides (10% on the right and 3.3% on the left), suggesting that this arrangement represents a minor variant rather than a typical configuration. These findings highlight asymmetry in hilar organization between the right and left lungs, which has practical relevance for radiological interpretation and thoracic surgical approaches

Table 4: Hilar Arrangement in Right Lungs (Superior to Inferior)

Arrangement Pattern	N=30
B₁ -A-B₂ -V (Normal)	14 (46.6%)
A- B₁- B₂-V	4 (13.3%)
A-B₁ -A- B₂-V	1 (3.3%)
V-B₁-A-B₂-A	3 (10%)
V-B₁-A-B₂ -V	2 (6.6%)
B₁-A-B₂-A	2 (6.6%)
A-B₁-V-B₂ -V	2 (6.6%)
B₁ - V-A-B₂ -A	1 (3.3%)
B₁-B₂ - V -A	1 (3.3%)

B₁ = Eparterial Bronchus , A= Pulmonary Artery, B₂ = Hyparterial Bronchus, V = Pulmonary Vein

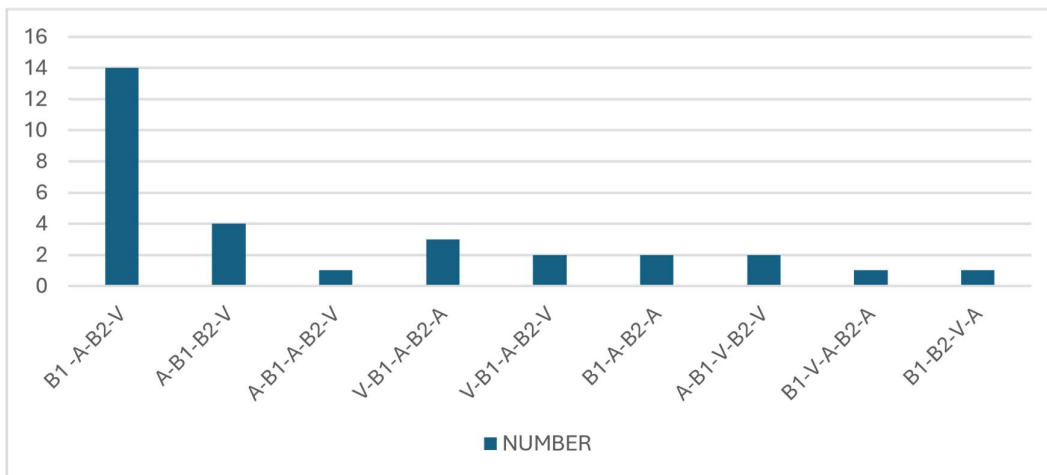

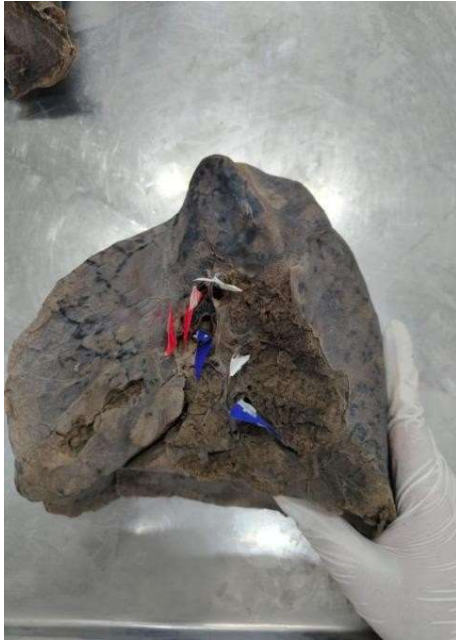


Fig. 5 - Mediastinal surface of right lung (superior to inferior) : Superiorly Eparterial bronchus - Pulmonary Artery Hyperarterial bronchu - pulmonary Artery (variation).

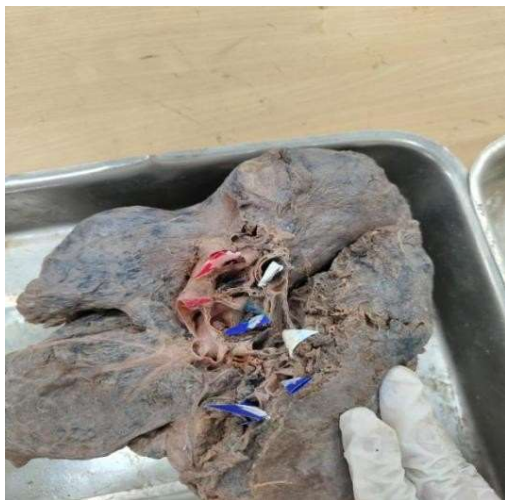

Fig. 6 - Mediastinal surface of right lung (superior to inferior) : Superiorly Pulmonary vein- Eparterial bronchus - Pulmonary Artery - Hyperarterial bronchu - two pulmonary Artery (variation).

Table 5: Hilar Arrangement in Left Lungs (Superior to Inferior)

Arrangement Pattern	N=30
A-B-V(Normal)	13 (43.3%)
B-A-V	3 (10%)
A-B-V-A	1 (3.3%)
V-B-A	6 (20%)
V-B-A-V	3 (10%)
V-B-V	3 (10%)

A-V-B-A	1 (3.3%)
---------	----------

A= Pulmonary Artery , B= Primary Bronchus , V= Pulmonary Vein.

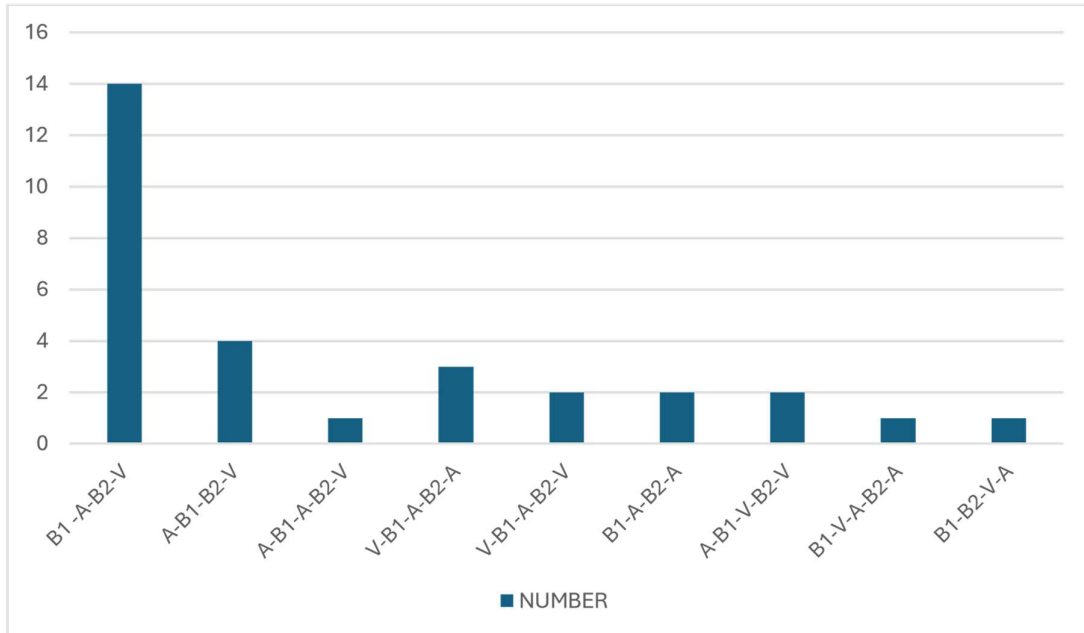


Fig. 7 - Mediastinal surface of left lung (superior to inferior) : most superior Pulmonary vein -Bronchus inferiorly inferior Pulmonary vein (variation).



Fig. 8 - Mediastinal surface of left lung (superior to inferior) : most superior Pulmonary artery - pulmonary vein -Bronchus - inferiorly Pulmonary artery (variation).

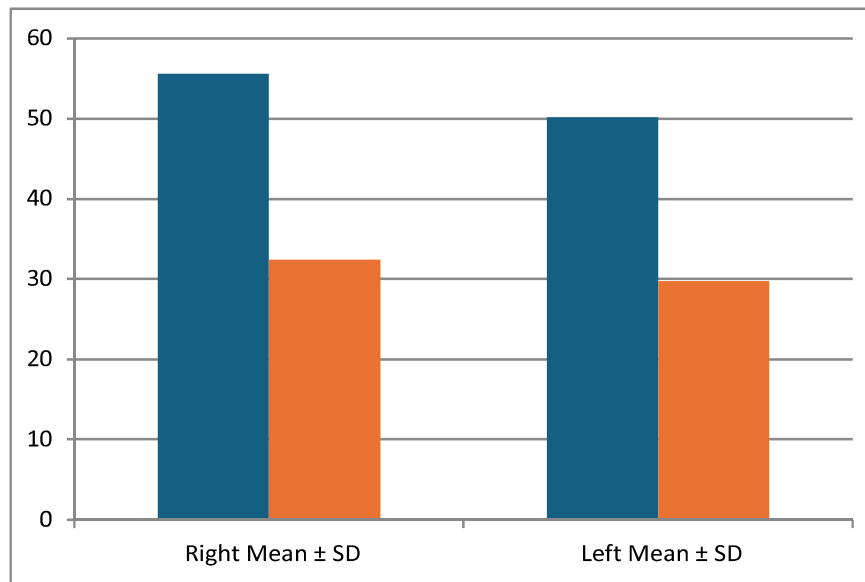
Interpretation:

The study analyzed the hilum structures arrangement patterns of 30 right lungs and 30 left lungs. The structures observed included the pulmonary artery (A), bronchus (B) & pulmonary veins (V). This findings demonstrated the presence of both normal anatomical arrangements and several variations in the hilar pattern. In the Right Lung, the most common arrangement pattern was B₁-A-B₂-V, which is considered the normal anatomical arrangement and was observed in 46.6% of the specimens. The second most common pattern was A-B₁-B₂-V seen in 13.3% of cases.

Bilateral Comparisons

Table 6: Comparison Between Right and Left Lungs

Parameter	Right Mean ± SD	Left Mean ± SD	p-value
Vertical Length	55.62 ± 6.21	50.14 ± 5.83	0.001
AP Diameter	32.48 ± 4.10	29.73 ± 3.85	0.004



Interpretation: The comparison of right and left lung dimensions shows statistically significant differences. The vertical length of the right lung (55.62 ± 6.21 mm) is greater than that of the left lung (50.14 ± 5.83 mm), with a p-value of 0.001, indicating a highly significant difference. Similarly, the antero-posterior (AP) diameter of the right lung (32.48 ± 4.10 mm) exceeds that of the left lung (29.73 ± 3.85 mm), with a p-value of 0.004, confirming statistical significance.

DISCUSSION

The present cadaveric study demonstrated significant anatomical variations in both the dimensions and hilar arrangement of the right and left lungs.

Aspect	Findings of the Present Study	Supporting Research and Results

Morphological Variations Of The Structures At The Hilum Of Bilateral Lungs: A Cadaveric Study.

Lung Morphometric Dimensions	In comparison to the left lung (50.14 ± 5.83 mm and 29.73 ± 3.85 mm), the right lung had considerably larger vertical length (55.62 ± 6.21 mm) and anteroposterior diameter (32.48 ± 4.10 mm); these differences were statistically significant ($p = 0.001$ and 0.004).	In a study of 110 cadaveric lungs, BV Murlimanju et al. (2017) found that the left lung had more anatomical changes (48.2%) than the right lung (16.1%).(5)
Arrangement Pattern of the hilum	While the left lung frequently had an A-B-V pattern, the right lung primarily displayed a V-A-B arrangement. 46.6% of right lungs and 43.3% of left lungs had normal hilar configuration. Rare variations were observed, including V-V-B, A-B-V-A, and A-V-B-A.	According to Kumari et al. (2019), there are differences in the bronchial configuration, veins, and pulmonary artery with superior displacement of the pulmonary artery and accessory pulmonary veins.(4)
Variability on the Left side	The left hilar arrangement was more intricate and varied, Compared to the right side.	In formalin-fixed cadaveric lungs, Anubha Saha et al. (2019) found that the left hilum varied more (64.81%) than the right hilum (59.18%).(6)
Abnormal Branching and Accessory Structures	Presence of atypical hilar arrangements possibly related to accessory vascular and bronchial structures.	Aberrant bronchial artery branching, accessory bronchopulmonary segments, and accessory fissures that modify hilar relations were reported by Patel and Ramesh (2022).(7)

Morphological Variations Of The Structures At The Hilum Of Bilateral Lungs: A Cadaveric Study.

Variation in the Number of Arteries, Veins, and Bronchi	There was noticeable variation in the broncho-vascular hilar configurations, particularly on the left side.	According to SM Jacob et al. (2019), the left lungs had >1 bronchus in 57%, >2 veins in 21%, and >1 artery in 17%, while the right lungs had >2 bronchi in 11%, >2 pulmonary veins in 69%, and >1 pulmonary artery in 37%.(8)
Variations in the Right Lung Hilar Structure	Numerous specimens had accessory veins, bronchi, and arteries.	Bincy M. George, Satheesha B. Nayak et al. (2014) discovered that the right lungs had three pulmonary arteries in 3.07%, two arteries in 67.69%, one artery in 29.23%, two veins in 63.07%, three veins in 32.30%, two bronchi in 98.46%, and three bronchi in 1.53%. [9]
Hilar Variation Frequency	Although there were a few variations, the majority had two bronchi and two pulmonary veins.	According to Deepak Khedekar and Shanta Hattangdi (2017), the majority of lungs had two bronchi, 84% had two arteries, 88% had two veins, and 12% had three pulmonary arteries.(10)

CONCLUSION

The present cadaveric study provided a detailed evaluation of the morphological variations of the pulmonary hilum in an Indian population. The results demonstrated that although the general anatomical arrangement of hilar structures mostly corresponds with standard textbook descriptions, significant variations are present in their dimensions, branching patterns, and spatial relationships. The study also revealed consistent side-related differences, with the right lung showing greater vertical and anteroposterior dimensions. In addition, multiple variations in bronchovascular configuration, such as accessory veins and modified bronchial branching patterns, were observed. These findings emphasize that while the anatomy of the pulmonary hilum is generally predictable, considerable individual variability exists

REFERENCE

1. Standring S, editor. Gray’s Anatomy: The Anatomical Basis of Clinical Practice. 41st ed. New York: Elsevier; 2016.
2. Moore KL, Dalley AF, Agur AMR. Moore’s Clinically Oriented Anatomy. 9th ed. Philadelphia: Lippincott

Williams & Wilkins; 2022.

3. Sadler TW. Langman’s Medical Embryology. 15th ed. Philadelphia: Wolters Kluwer; 2023.
4. Kumari KG, James N, Mugunthan N. Morphological study of lobes, fissures and pulmonary hilar structures. *Int J Anat Res.* 2019;7(1.3):6298–301.
5. Murlimanju BV, Massand A, Madhyastha S, Pai MM, Prabhu LV, Saralaya VV. Anatomical variations of the arrangement of structures at the pulmonary hilum: a cadaveric study. *Surg Radiol Anat.* 2016;39(1):51–6.
6. Saha A, Srimani P. Comprehensive study of pulmonary hilum with its clinical correlation. *Ann Anat.* 2019 Mar; 222:61–9.
7. Patel A, Ramesh R. Morphological and morphometric analysis of lung: A cadaveric study. *Asian J Med Sci.* 2022;13(3):36–42.
8. Jacob SM, Venniyoor V, Pillay M. Variations in the morphology of human lungs and its clinical implications. *Journal of Morphological Sciences.* 2019;36(4):231-236. doi:10.1055/s0039-1688904.
9. George BM, Nayak SB, Marpalli S. Morphological

- variations of the lungs: a study conducted on Indian cadavers. *Anatomy & Cell Biology*. 2014;47(4):253-258. doi:10.5115/acb.2014.47.4.253
10. Khedekar D, Hattangdi S. Morphological variations of the lung: a cadaveric study in Mumbai population. *International Journal of Anatomy and Research*. 2017;5(3.2):4313-4316. doi:10.16965/ijar.2017.320.
 11. Ludeña T, Lozano-Samaniego A, Maldonado S, Salas F. The hilum of the lung: Two classical radiological signs to decipher it. *Radiol Engl Ed*. 2022;64(1):60–68. doi:10.1016/j.rxeng.2020.09.005.
 12. Sarkar S, Jash D, Maji A, Patra A. Approach to unequal hilum on chest X-ray. *J Assoc Chest Physicians*. 2013;1(2):32–37. doi:10.4103/2320-8775.123204.
 13. Gautam A, Chaulagain R, Dhungel D. Morphological variations of the lungs: A cadaveric study. *Nepal Med Coll J*. 2021;23(4):315–318. doi:10.3126/nmcj.v23i4.42221.
 14. Webb WR, Glazer G, Gamsu G. Computed tomography of the normal pulmonary hilum. *J Comput Assist Tomogr*. 1981;5(4):476–484. doi:10.1097/00004728-198108000-00004.
 15. James NK, Mugunthan GK. Morphological study of lobes, fissures and pulmonary hilar structures. *Int J Anat Res*. 2019;7(1.3):6298–6301. doi:10.16965/ijar.2018.430.
 16. Seleka R, Petersen M, Mpolokeng KS. Morphological variations of fissures, lobes, and hilar pattern of the lung in a select South African sample. *Surg Radiol Anat*. 2024;46(12):2005– 2017. doi:10.1007/s00276-024-03497-5