

# CONTRIBUTORS TO PLACENTAL INVASION IN WOMEN WITH UTERI SURGERY

## A PROSPECTIVE STUDY

**Dr. Rida Zafar**

Lecturer, Department of Obstetrics and Gynecology, Sargodha Medical College

Email: [ridazaffar@gmail.com](mailto:ridazaffar@gmail.com)

### ABSTRACT

**Background:** Placental invasion due to abnormal trophoblast adherence and their life threatening impact on maternal outcomes.

**Objectives:** To identify risk factors resulting in adherent placenta in women with previous uterine surgeries, low lying placenta and to asses' maternal outcome.

**Methods:** This prospective study was conducted at Government Mian Mola Bakash Hospital, Sargodha from April 2025 to January 2026, including 85 pregnant women with low lying placenta and previous uterine surgeries. Antenatal patients were divided into adherent (n=27) and non-adherent (n=58) placental groups.

**Results:** Women with adherent placenta were older ( $34.2 \pm 5.1$  vs  $29.8 \pm 4.6$  years; P-value<0.001) and had higher no of previous child births ( $3.6 \pm 1.4$  vs  $2.3 \pm 1.1$ ; P-value<0.001). Total prior cesarean record ( $2.8 \pm 0.9$  vs  $1.6 \pm 0.7$ ; P-value<0.001) with  $\geq 2$  previous uterine surgeries 81.5% vs 37.9% (P-value<0.001) have greater chance of adherent placenta. Low lying placenta was more common in adherent placenta (88.9% vs 58.6%; P-value=0.006). Radiological imagining i.e. loss of interface between myometrium and placenta (74.1%), placental lacunae (81.5%) and abnormal Doppler flow (81.5%) were significantly associated (P-value<0.001). MRI findings including uterine bulging (59.3%) and intra-placental bands (51.9%) were also higher (P-value<0.001). Blood loss was significantly greater in adherent placenta ( $1684.2 \pm 420.6$  vs  $612.5 \pm 180.4$  ml; P-value<0.001), with higher transfusion (81.5%) and cesarean hysterectomy rates (74.1%).

**Conclusion:** Adherent placenta is strongly associated with multiple prior cesarean sections, low lying placenta, and characteristic imaging findings. Early identification of high-risk patients is essential to decrease poor maternal outcomes

**Keywords:** Magnetic Resonance Imaging (MRI), Odds ratio (RZ), Confidence interval (RC)

### INTRODUCTION

Adherent Placenta accreta disorders are a spectrum of abnormal placental invasion including placenta accreta, increta and percreta, caused by the failure of the chorionic villi to separate from the myometrium and invade it abnormally [1]. Adherent Placenta is a life-threatening obstetric complication and one of the most common obstetric haemorrhages that often require large transfusion of blood, cesarean hysterectomy and intensive care support [2]. Adherent Placenta has recently been on the rise, with its rates rising significantly over the last few decades and in the same direction as the rates of cesarean sections all over the world [3]. Of all the risk factors that have been identified the association of a cesarean section in the past and a low-lying placenta is strong indicator of adherent placenta [4]. Risk increases with every subsequent cesarean birth as a result of gradual thinning of the endometrial-myometrial junction and scarring

[5]. This is particularly vulnerable in women with low lying placenta that cover a scar of the uterus as it has been correlated with inadequate decasualization that allows abnormal placental invasion [6]. In cases where placenta previa is associated with previous uterine surgery, it is significantly associated with adherent placenta [7]. Similarly, low level placenta (without the severity of location) is another predisposing factor for abnormal placental attachment especially if the placenta is near the cesarean scar [8]. Such conditions cause pathological environment in favor of further trophoblastic invasion of the myometrium and in extreme cases even beyond the uterine serosa [9].

In early antenatal diagnosis of adherent placenta, it is important to the mother because she is able to obtain better maternal outcomes. The first diagnosis test is ultrasonography, and the characteristics such as loss of interface between myometrium and placenta, placental lacunae and abnormal vascularity will assist in early diagnosis [10]. A selected group of cases may have degree of placental invasion is confirmed by magnetic resonance imaging (MRI) [11]. Multidisciplinary approach in diagnosis and delivery can be time planned in tertiary care centers which resulted in a significant reduction in maternal mortality and morbidity [12]. Other factors that can put women at risk of adherent placenta in addition to previous cesarean section and placental location include maternal age at delivery, increase no of previous child birth, short duration between pregnancies and prior uterine procedures including uterine evacuation or uterine fibroid removal [13]. These factors could play a role in damaging the endometrium which further predisposes to abnormal placentation [14]. In developing/middle income countries like Pakistan, rising cesarean section rates, lack of access to early imaging, and delayed antenatal care compound the burden of adherent placenta [15].

### **OBJECTIVES**

To conclude maternal outcomes, it is important to identify adherent placenta in women with previous uterine surgeries and low lying placenta.

### **MATERIALS AND METHODODS**

This was a prospective study conducted at Government Mian Mola Bakash Hospital, Sargodha from April 2025 to January 2026, including 85 pregnant women with a history of previous uterine surgeries and identification of low lying placenta

#### **Inclusion Criteria:**

- Pregnant women aged 18–45 years
- History of previous uterine intervention
- Confirmation of low lying placenta
- Singleton pregnancy
- Willing to provide informed consent

#### **Exclusion Criteria:**

- Women with no history of cesarean section
- Multiple pregnancies
- Known uterine anomalies
- Patients with incomplete antenatal flow-up or imaging records

#### **Data Collection:**

The study data were compiled in prospective manner with help of well designed collection form. The initial parameters comprised of maternal age of delivery, total prior cesarean record, no of

previous child birth and duration between pregnancies. Past surgical history related to uterine intervention like uterine evacuation or uterine fibroid removal and positive history of chronic illness such as diabetes and hypertension. Ultrasound features were noted such as visualization of placental lacunae, placental site, increased blood flow in doppler, absence of clear margin between myometrium and placenta. Results of (MRI) were documented. The confirmation of adherent placenta was done during procedure and through histopathology results. The patients were divided into presence or absence of adherent placenta. Operative findings contain depth of placental invasion, requirement of blood transfusion, calculated loss of blood and need of hysterectomy during cesarean section. Post operative results contain maternal morbidity and ICU care.

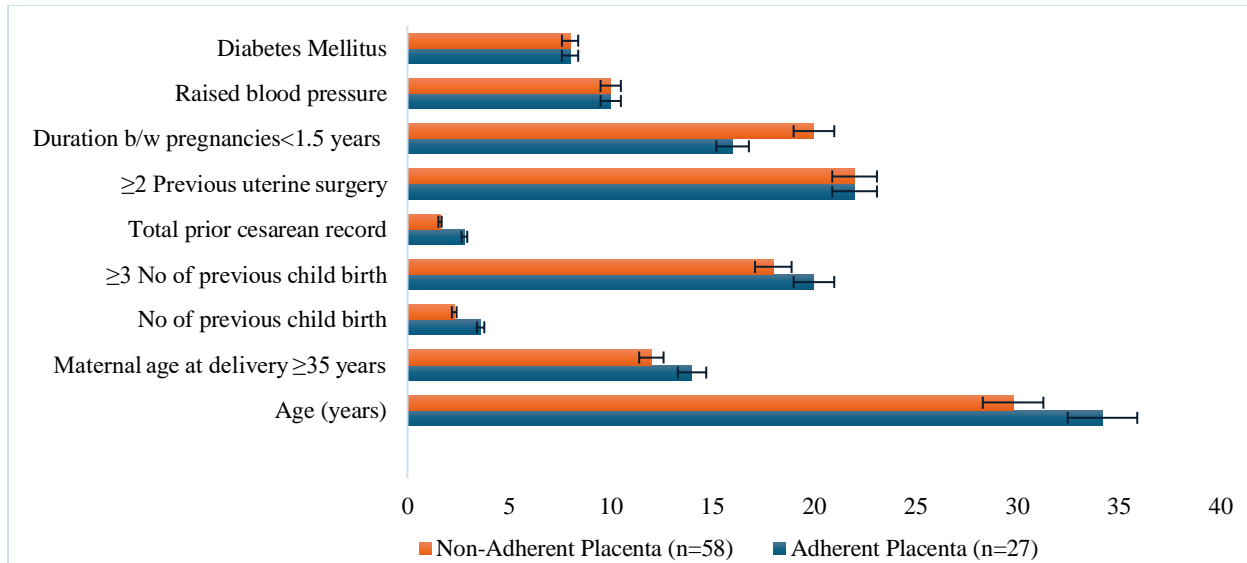
### **STATISTICAL ANALYSIS**

Analysis of data was done by using SPSS (version; 25). Mean and  $\pm$  standard deviation were used to describe quantitative data, while data were formulated as percentages and frequencies. Division of adherent and non-adherent placenta was done by using t-test. Data were analyzed by using chi square test. In order to locate specific factor for adherent placenta multi variable logistic regression were carried out. Odds ratio (RZ) having 93.2% confidence interval was measured when P-value is  $\leq 0.05$  is interpreted as highly significant.

### **RESULTS**

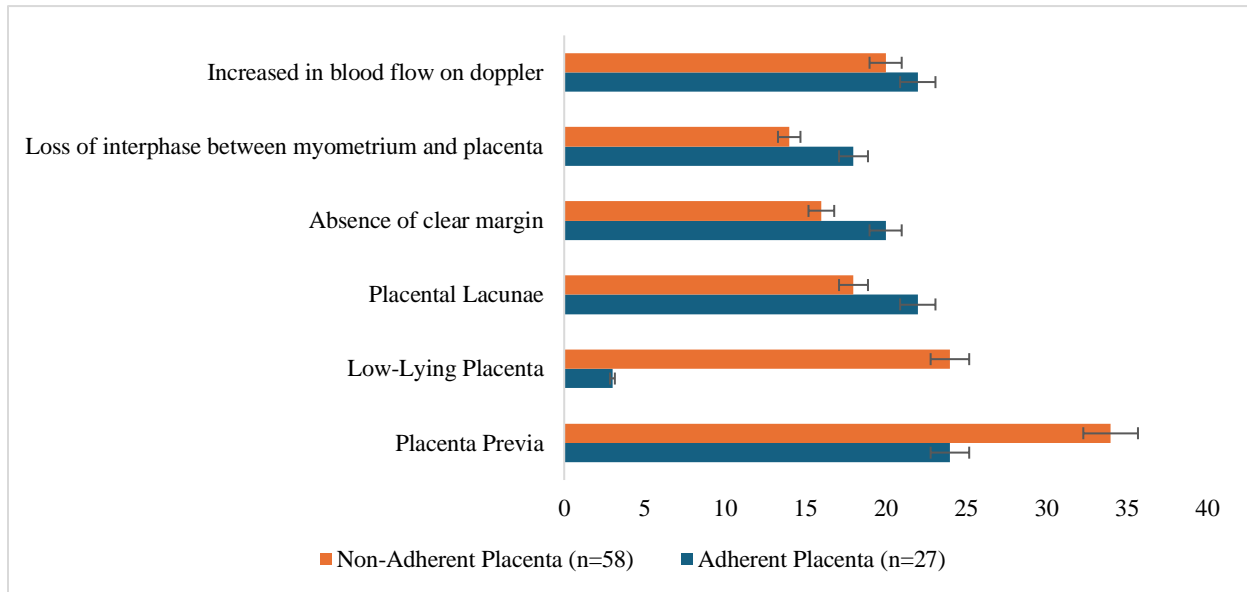
#### **Baseline Maternal and Obstetric Characteristics:**

Women with adherent placenta were older ( $34.2 \pm 5.1$  vs  $29.8 \pm 4.6$  years; P-value $<0.001$  with a higher proportion aged  $\geq 35$  years (51.9% vs 20.7%); P-value=0.005. They had increased no of child birth ( $3.6 \pm 1.4$  vs  $2.3 \pm 1.1$ ); P-value $<0.001$ , with  $\geq 3$  child birth in (74.1% vs 31.0%); P-value $<0.001$ . The number of prior cesarean sections was higher in adherent placenta ( $2.8 \pm 0.9$  vs  $1.6 \pm 0.7$ ); P-value $<0.001$ , with  $\geq 2$  previous uterine surgery in (81.5% vs 37.9%); P-value $<0.001$ . Less duration between pregnancies  $<1.5$  years was significant (57.9% vs 33.2%); P-value=0.027, as were chronic illness i.e. raised blood pressure (36.8% vs 16.9%); P-value=0.034 and diabetes (29.4% vs 13.5%); P-value=0.047 shows significant morbidity.



### Placental Characteristics and Ultrasound Findings:

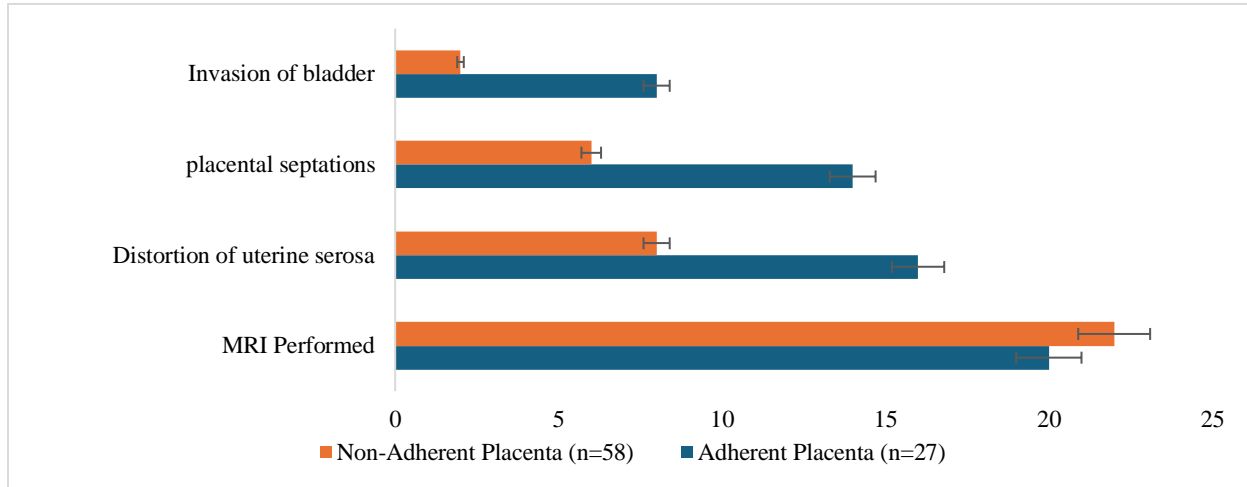
In adherent placental cases placental position (Placenta Previa) was more common (88.3% vs 57.3%);  $P=0.006$ , low-lying placenta was less frequent (10.9% vs 40.8%). Radiological findings were common in adherent placenta including visualization of placental lacunae (81.2% vs 30.7%), absence of clear margin (73.8% vs 27.3%) and loss of interphase between myometrium and placenta (66.2% vs 23.7%);  $P\text{-value}<0.001$ . Significant indicator on scan was increased in blood flow on doppler (81.2% vs 34.1%);  $P\text{-value}<0.001$



### MRI and Advanced Imaging Findings:

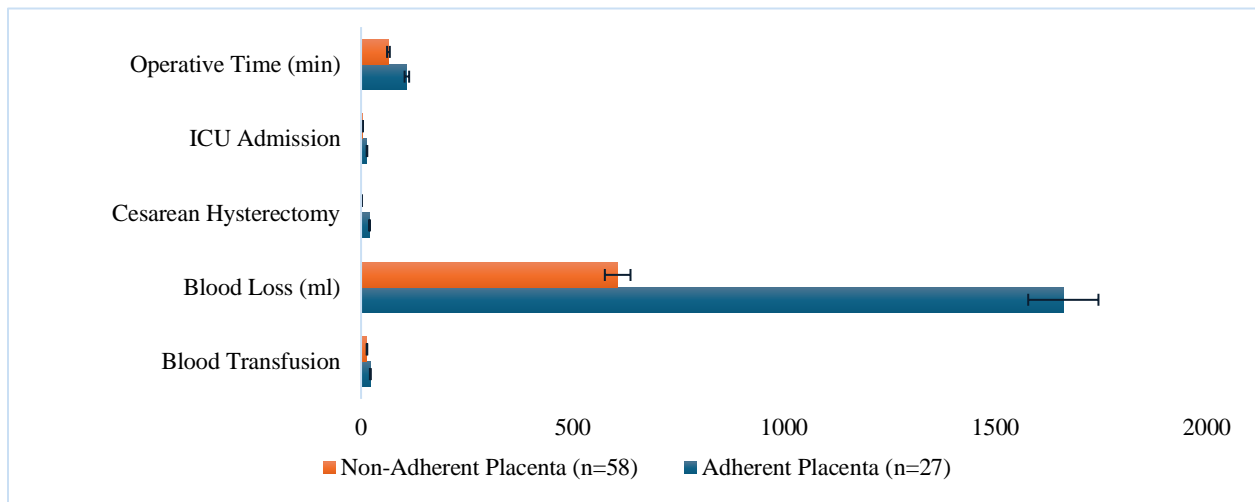
Adherent placenta contains significant radiological findings, the frequent imaging was carried out by MRI (73.7% vs 37.5%);  $P=0.002$ . Distortion of uterine serosa was seen in 58.9% of adherent placenta vs 13.4% in non adherent placenta having  $P\text{-value}<0.001$ , while placental septations were seen in 51.5% compared to 10.1% in non adherent placenta having  $P\text{-value}<0.001$

value<0.001. Invasion of bladder (29.2% vs 3.2%) having P-value<0.001, is serious indicator of maternal morbidity.



**Intraoperative and Maternal Outcomes:**

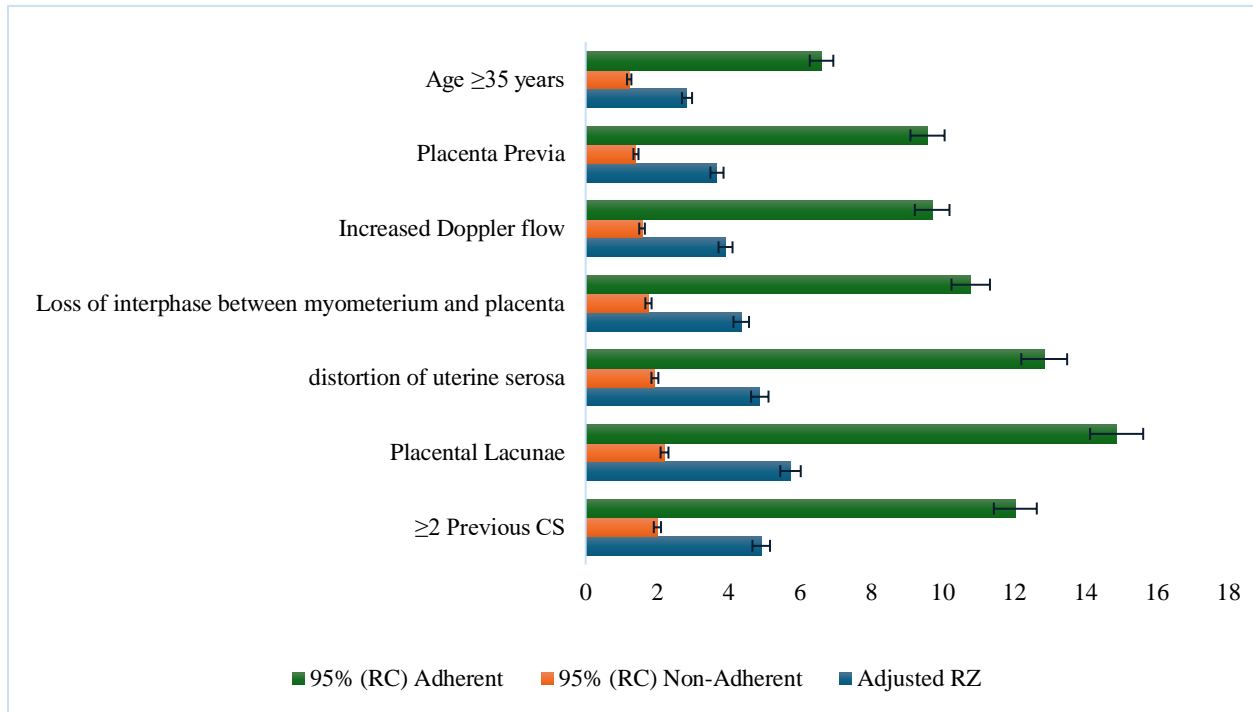
Increased blood transfusion (81.2% vs 23.8%); P-value<0.001 is done in case of increased blood loss (1661.7 ± 415.3 vs 607.2 ± 172.9 ml); P-value<0.001. Cesarean hysterectomy was required in 74.1% cases of adherent placenta compared to 3.4% in non-adherent placenta; P-value<0.001. ICU admission was also higher (51.9% vs 6.9%); P-value<0.001 and operative time was significantly prolonged (108.4 ± 22.1 vs 64.8 ± 12.6 minutes); P-value<0.001, indicating increased surgical complications.



**Comparison of Maternal Outcomes Between adherent and non-adherent placental groups:**

Having ≥2 previous cesarean sections showed the highest risk (RZ 4.92, 95% RC: 2.01–12.04); P-value<0.001, followed by placental lacunae (RZ 5.74, 95%RC 2.21–14.88); P-value<0.001 and distortion of uterine serosa on MRI (RZ 4.88m, 95%RC 1.94–12.25); P-value<0.001, both highly significant (P-value<0.001). Loss of interphase between myometrium and placenta (RZ 4.36, 95%RC 1.76–10.79); P-value=0.001, Increased doppler flow (RZ 3.92, 95%RC 1.58–

9.71); P-value=0.003, and placenta previa (RZ 3.68, 95%RC 1.41–9.58); P-value=0.008 were also significant indicators. Age  $\geq 35$  years (RZ 2.84, 95%RC 1.22–6.61); P-value=0.015.



## DISCUSSION

The current research paper determines the important maternal, imaging, and intraoperative indicators of adherent placenta among women who had a previous cesarean surgery and placenta previa or low-lying placenta. Adherent placenta was more common in older ( $34.2 \pm 5.1$  vs  $29.8 \pm 4.6$  years) and increased number of children ( $3.6 \pm 1.4$  vs  $2.3 \pm 1.1$ ), which shows that increased maternal age and no of children are also significant factors in abnormal placentation. This association is further supported by the higher percentage of women who are 35 years and above (51.9% vs 20.7). One of the past studies has also indicated that maternal age and increased no of children have a significant role in incidence of adherent placenta [16]. There was a significant correlation between previous cesarean sections and adherent placenta with women in the adherent placentation group having increased no of previous cesarean sections ( $2.8 + 0.9$  vs  $1.6 + 0.7$ ) and a higher number of women having 2 or more previous cesarean sections (81.5% vs 37.9%). This result supports the presence of uterine scarring in the pathogenesis of adherent placenta.

An earlier study has also proved that the risk of adherent placenta is related to the number of cesarean sections, especially when it is due to with placenta previa [17]. Placental location and ultrasound results revealed the high predictive value. Placenta previa was much higher in adherent placental cases (88.3% vs 57.3%), and such significant ultrasound features as placenta lacunae (81.2%), loss of clear margin(73.8%) and loss of interphase between myometrium and placenta (66.2%) were much higher. Adherent placenta was also significantly related to

increased doppler flow (81.2% vs 34.1%). These results emphasize the importance of ultrasound in early diagnosis. A prior study has also highlighted that the loss of the clear margin and placental lacunae are some of the strongest radiological markers of adherent placenta [18].

The diagnosis was further supported by MRI results such as distortion of uterine serosa (58.9%), placental septation (51.5%), and invasion of bladder (29.2%) were much more common in adherent placenta. These results indicate increase placental invasion and contribute to the evaluation of the severity of the disease. Another study also mentioned that the characteristics of MRI (distortion of uterine serosa, placental septation) are closely related to invasive placenta and can be used as reference for ultrasound results that are inconclusive [19].

Maternal outcomes were also significantly lower in adherent placenta with increased blood loss ( $1661.7 \pm 415.3$  vs  $607.2 \pm 172.9$  ml) need of blood transfusion (81.2% vs 23.8%) and cesarean hysterectomy (74.1% vs 3.4%). Significant differences were also noted in the ICU admissions (51.9% vs 6.9%) and the operative time ( $108.4+22.1$  vs  $64.8+12.6$  minutes) which demonstrated the severity of adherent placenta. A prior study has also shown that adherent placenta related to obstetric hemorrhage, increased no of transfusion, and hysterectomy is also more likely to be performed [20].

Multivariable analysis was done and significant factors were found as  $\geq 2$  cesarean sections previously (RZ 4.92), placental lacunae (RZ 5.74), distortion of uterine sarosa on MRI (RZ 4.88), and loss of interphase between myometrium and placenta (RZ 4.36). Other significant factors were increased doppler flow (RZ 3.92), placenta previa (RZ 3.68), and age  $\geq 35$  years (RZ 2.84). These results suggest that a combination of clinical history and imaging characteristics are the best predictors of adherent placenta. An earlier study also found that the combination of obstetric history with ultrasound and MRI results is much more effective in enhancing the accuracy of the diagnosis [21].

Radiological images, previous uterine surgeries and placental site is strongly associated with adherent placenta which indicate tertiary care and timely refer to reduce maternal morbidity and mortality.

## **CONCLUSION**

It is stated that adherent placenta is more common in

1. Females with previous uterine intervention
2. Placental location in lower uterine segment
3. Age  $\geq 35$
4. Increased number of child birth
5. Radiological feather of loss of interphase between myometrium and placenta
6. Bladder invasion
7. Bulging of placental vessels through lower uterine segment
8. Increased blood flow on Doppler
9. Thinning of uterine serosa

These patients have high incidence of maternal complications such as obstetric hemorrhage resulted in resuscitative hysterectomy, ICU care (Ventilator support), AKI (acute kidney injury), DVT (deep venous thrombosis) and long term complications such as fistula.

## References

1. Bonanni G, Lopez-Giron MC, Allen L, et al. Guidelines on placenta accreta spectrum disorders: a systematic review. *JAMA Netw Open*. 2025;8:e2521909.
2. White A, Malik M, Pruszynski JE, Do QN, Spong CY, Herrera CL. Contemporary placenta accreta spectrum disorder incidence and risk factors. *Obstet Gynecol*. 2025;145:665–673.
3. ADoPAD (Antenatal Diagnosis of Placental Attachment Disorders) Study Group. Risk factors, prenatal diagnosis, and outcome of posterior placenta accreta spectrum disorders in patients with placenta previa or low-lying placenta: a multicenter study. *Acta Obstet Gynecol Scand*. 2025;104:1328–1338.
4. AbdelAziz S, El-Goly NA, Maged AM, Bassiouny N, El-Demiry N, Shamel A. Diagnostic accuracy of magnetic resonance imaging in the diagnosis of placenta accreta spectrum: a systematic review and meta-analysis. *Matern Fetal Med*. 2025;7:15–21.
5. Garg P, Semwal S, Bansal R. Unexpected placenta accreta spectrum in an unscarred uterus causing catastrophic postpartum hemorrhage: a case report and review of the literature. *BMC Pregnancy Childbirth*. 2025;25(1):14.
6. Ramadan MK, El-Zein N, Jomaa M, et al. Retained non-previa placenta in the era of “placenta accreta spectrum”: a report of two cases managed expectantly and a proposed plan for management. *Front Med (Lausanne)*. 2025;12:1504491.
7. Etori Y, Nagai R, Shimomoto Y, et al. Successful management of first-trimester uterine rupture and placenta previa: a case report. *Cureus*. 2025;17(1):e77857.
8. Huang C, Peng Z, Li L, et al. Application of double-row transfixion suture of the lower uterine segment in cesarean section for pernicious placenta previa complicated by placenta accreta spectrum: a comparative clinical study. *BMC Pregnancy Childbirth*. 2025;25:381.
9. Kayem G, Seco A, Vendittelli F, et al. Risk factors for placenta accreta spectrum disorders in women with any prior cesarean and a placenta previa or low lying: a prospective population-based study. *Sci Rep*. 2024;14:6564.
10. You H, Wang Y, Han R, Gu J, Zeng L, Zhao Y. Risk factors for placenta accreta spectrum without prior cesarean section: a case-control study in China. *Int J Gynaecol Obstet*. 2024;166:1092–1099.
11. Yue Y, Wang X, Zhu L, et al. Placental volume as a novel sign for identifying placenta accreta spectrum in pregnancies with complete placenta previa. *BMC Pregnancy Childbirth*. 2024;24(1):52.
12. Kang Y, Zhong Y, Qian W, Yue Y, Peng L. A prediction model based on MRI and ultrasound to predict the risk of PAS in patient with placenta previa. *Eur J Obstet Gynecol Reprod Biol*. 2024;301:227–233.
13. Shuai X, Gao C, Zhang H, et al. Bladder involvement in placenta accreta spectrum disorders: 2D US combined with the 3D crystal Vue and MRI comparative analysis. *BMC Pregnancy Childbirth*. 2024;24:788.

14. Zhang J, Kong L, Qu F, et al. The predictive value of conventional magnetic resonance imaging combined with intravoxel incoherent motion parameters for evaluating maternal and neonatal clinical outcomes in patients with placenta accreta spectrum disorders. *Placenta*. 2024;151:10–17.
15. Ma Y, Ma J. Interpregnancy interval: attention should be given after conservative treatment of placenta accreta spectrum. *Am J Obstet Gynecol MFM*. 2024;6:101252.
16. Sugai S, Yamawaki K, Sekizuka T, et al. Pathologically diagnosed placenta accreta spectrum without placenta previa: a systematic review and meta-analysis. *Am J Obstet Gynecol MFM*. 2023;5(8):101027.
17. Zhao H, Wang Q, Han M, Xiao X. Current state of interventional procedures to treat pernicious placenta previa accompanied by placenta accreta spectrum: a review. *Medicine (Baltim)*. 2023;102:e34770.
18. Zhao H, Liu C, Fu H, Abeykoon SDI, Zhao X. Subsequent pregnancy outcomes and risk factors following conservative treatment for placenta accreta spectrum: a retrospective cohort study. *Am J Obstet Gynecol MFM*. 2023;5:101189.
19. Maged AM, El-Mazny A, Kamal N, et al. Diagnostic accuracy of ultrasound in the diagnosis of placenta accreta spectrum: systematic review and meta-analysis. *BMC Pregnancy Childbirth*. 2023;23:354.
20. Jariyawattananarat W, Thiravit S, Suvannarerg V, Srisajjakul S, Sutchritpongsa P. Bladder involvement in placenta accreta spectrum disorder with placenta previa: MRI findings and outcomes correlation. *Eur J Radiol*. 2023;160:110695.
21. Zhang J, Li H, Feng D, Wu J, Wang Z, Feng F. Ultrasound scoring system for prenatal diagnosis of placenta accreta spectrum. *BMC Pregnancy Childbirth*. 2023;23:569.