

# Malignant Transformation of Ovarian Mature Cystic Teratoma into Moderately Differentiated Squamous Cell Carcinoma in a Postmenopausal Woman

Dr. Thanmai Sunkani<sup>1</sup>, Dr. Archana Kennedy Rajan<sup>2\*</sup>, Dr. Joydeb Roy Chowdhury<sup>3</sup>, Dr. Harshitha Reddy<sup>4</sup>

<sup>1,2,3,4</sup>Department of Obstetrics and Gynecology, Shri Sathya Sai Medical College & Research Institute, affiliated to SBV deemed to be university, Ammapettai, Chengalpattu, Tamil Nadu, India.

Dr. Thanmai Sunkani Email: [thanvysunkani@gmail.com](mailto:thanvysunkani@gmail.com)  
Dr. Joydeb Roy Chowdhury Email: [rcjoydeb@gmail.com](mailto:rcjoydeb@gmail.com)  
Dr. Harshitha Reddy Email: [Reddyharshitha15@gmail.com](mailto:Reddyharshitha15@gmail.com)

\*Corresponding Author: Dr. Archana Kennedy Rajan

Department of Obstetrics and Gynecology, Shri Sathya Sai Medical College & Research Institute, affiliated to SBV deemed to be university, Ammapettai, Chengalpattu, Tamil Nadu, India.  
Email: [archanakennady@gmail.com](mailto:archanakennady@gmail.com)

## ABSTRACT

Malignant transformation of an ovarian Mature Cystic Teratoma (MCT) is rare, occurring in about 1–2% of cases, with Squamous Cell Carcinoma (SCC) being the most common histological subtype. This report details the case of a 49-year-old postmenopausal woman presenting with an abdominal mass and pain, ultimately confirming the diagnosis of MCT with malignant transformation to moderately differentiated SCC. Even though this transformation is rare, it should be highly suspected in postmenopausal women with rapidly growing or large ovarian masses, as timely surgical intervention and pathology review are vital for favourable patient outcomes.

**Keywords:** Mature cystic teratoma, Squamous cell carcinoma, Malignant transformation, Postmenopausal, Ovarian tumour.

**How to cite this article:** Sunkani T, Rajan AK, Chowdhury JR, Reddy H. Malignant Transformation of Ovarian Mature Cystic Teratoma into Moderately Differentiated Squamous Cell Carcinoma in a Postmenopausal Woman. *Int J Drug Deliv Technol.* 2026;16(59s): 541-545. DOI: 10.25258/ijddt.16.59s.59

**Source of support:** Nil

**Conflict of interest:** None

### Introduction

The Mature Cystic Teratoma is the most prevalent germ cell tumor found in the ovary<sup>2</sup>. Although these tumors are overwhelmingly benign, malignant transformation is infrequent (incidence < 3%), primarily affecting older, postmenopausal individuals.

SCC accounts for roughly 80% of these malignancies<sup>1</sup>. Diagnosis is often delayed because the symptoms are non-specific, leading to presentation at advanced stages and, consequently, a poor prognosis. This report emphasizes the aggressive nature of the disease by detailing the case of SCC transformation in a

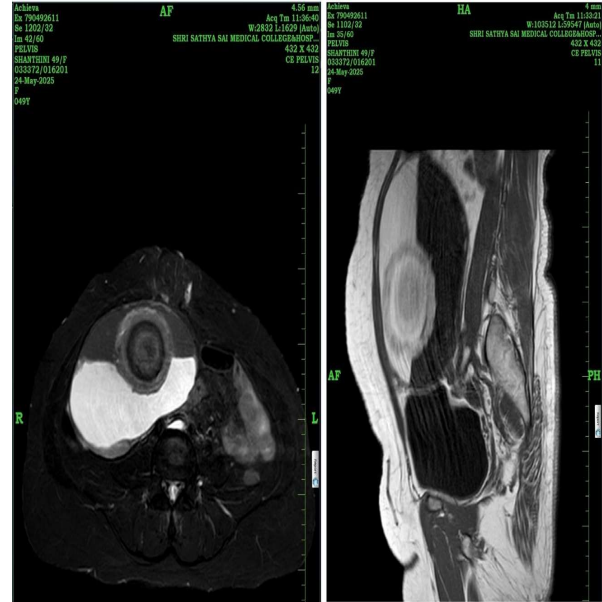
## RESEARCH PAPER

postmenopausal patient with significant comorbidities<sup>5</sup>.

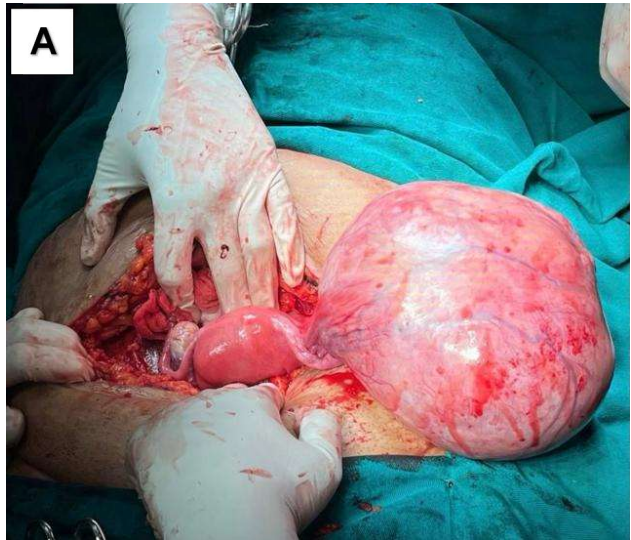
### Case Presentation

49-year-old Indian women, P2L1, post menopausal (attained menopause at age of 48), was admitted in May 2025 with two days of progressively intensifying, spasmodic pain in the loin region. She also reported a palpable mass in her abdomen over the preceding four months. On arrival to the hospital vitals were stable. She had a nine-year history of Systemic Hypertension and on treatment for that. Upon admission she was diagnosed with Type II Diabetes Mellitus (RBS: 473 mg/dl, HbA1C: 9.8%) and managed using oral hypoglycemic drug and insulin. On examination revealed a large, firm, non-tender abdominal mass consistent with a 24-week size uterus. Per Vaginum examination detected a mass through the posterior fornix, with a positive Groove sign. The blood investigations are within normal limit. ECG and ECHO were normal and the chest x ray was normal. Tumour markers showed Beta hCG:<2.0m IU/ml, AFP:3.8 ng/ml, CEA:4.59 ng/ml, CA-125: 31.40 U/ml, CA19-9:178.31 U/ml

Initial USG Abdomen and Pelvis identified a large 13 x 10 x 8 cm lesion, characteristic of an Ovarian Dermoid Cyst, displaying a fat-fluid level and hyperechoic content. A subsequent CECT Abdomen and Pelvis confirmed a massive lesion (9.3 x 13.7 x 16.2 cm) featuring a fat-fluid interface and a large Rokitansky nodule (Pokemon ball sign) as shown in figure. Initial imaging findings, including thickening of the bowel wall and stool occult blood positive, were concerning, but a subsequent negative Colonoscopy and peritoneal fluid cytology ruled out primary gastrointestinal malignancy.



After achieving blood sugar stability with insulin therapy, and informed written consent she underwent a Staging Laparotomy + Herniorrhaphy on 02/06/2025. Intraoperative a 16 x 15 cm cystic mass arising from the left ovary was seen as in figure 1 and the right ovary and fallopian tube were normal. The cyst capsule was intact and there were absence of ascites or peritoneal deposits or palpable lymph nodes, suggesting early-stage disease. The cyst cut section revealed sebaceous material and hair tufts as shown in figure 2

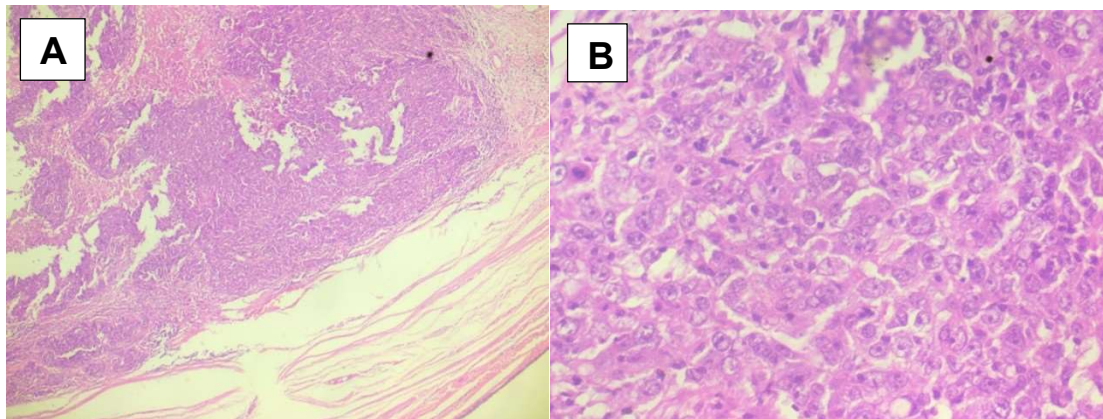


**B** The Histopathology Report confirmed the final diagnosis as Mature Teratoma with malignant transformation to Moderately Differentiated Squamous Cell Carcinoma as shown in figure (). As suggested by multidisciplinary Tumour Board she was given adjuvant chemotherapy (4 cycles) due to the aggressive nature of SCC without any major side effects and presently she is followed by a long-term surveillance protocol as follow: every 3 months for the

**Figure 1(A):** Intraoperative image showing the Left mature ovarian teratoma (Dermoid cyst). Note the right fallopian tube and the ovary appears normal.

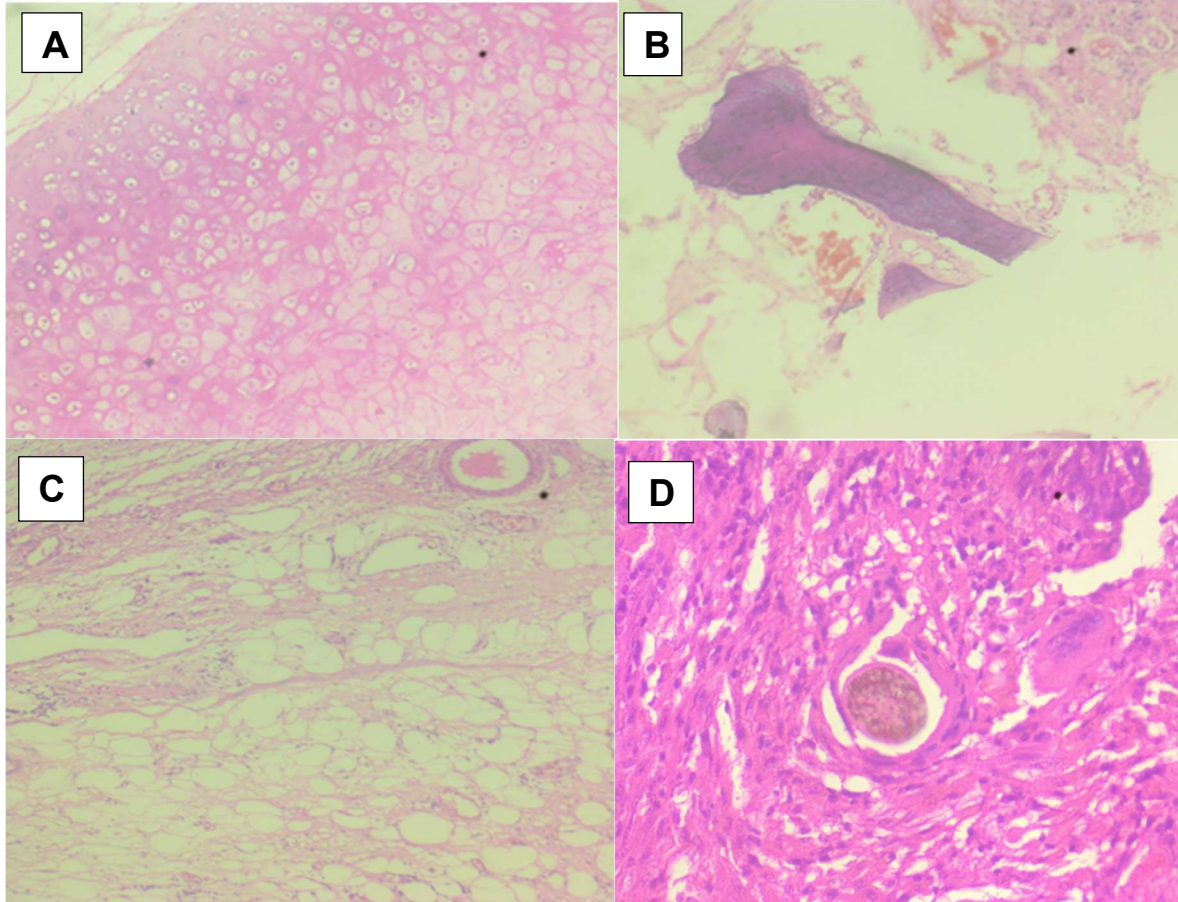
**(B):** Cut section of the cyst showing the sebaceous material (yellow colour) and hair tufts (black colour). The yellow fluid in the kidney tray is the sebaceous secretion drained out while cut opening the cyst

first year, every 6 months for the second year, and annually thereafter, including CT scan, and tumour marker.



**A:** Low Power Malignant Squamous cells (H &E)

**B:** High Power Malignant Squamous cells (H&E)



**A: Cartilage Component ,B: Bony Component ,C: Fatty Adipocytes, D: Hair**

### 3. Discussion:

Mature cystic teratomas (MCTs) is a benign germ cell neoplasm arising from the three germ cell layers (ectoderm, endoderm and mesoderm), and are one of the most common neoplasms of the ovary accounting for 10% in a woman's lifetime. Malignant change in the MCT was rare event (1-2%) and the most common histological type is squamous cell carcinoma (SCC) 80%. The mechanism by which this malignant transformation occurs is poorly understood till know. Preoperative diagnosis of malignant transformation of ovarian mature teratoma is difficult due to nonspecific tumour markers and imaging findings<sup>(1)</sup>. But there are some features which can be used to predict most of the malignant transformations like Post menopausal age, maximum diameter of tumour and raised tumour markers<sup>(3,4,6)</sup>.

Most of the case reports indicate that those with malignant transformation in MCT are usually between 40 and 55 years old, which is on average 10–15years older than women with MCT<sup>(12)</sup>.

Our case had diabetes mellitus and systemic hypertension (medical comorbidities). Diabetes causes chronic inflammation and oxidative stress that may theoretically contribute to carcinogenesis, however current literature does not suggest a direct association between metabolic disorders and malignant transformation of mature cystic teratoma further studies are required to establish or refute such a relationship as these co-morbidities are common in postmenopausal women.

In a systematic review done by Wu Y Sarah et al they found that the size (ranging from 9.7 to 15.6 cm) of SCC-MCT is typically larger than that of benign MCT<sup>(7)</sup>. In our case the maximal diameter of the mass was 16 cm.

Several studies reported that raised level of tumour markers, although nonspecific, may be a predictor for malignant transformation in MCTs<sup>(5,8)</sup>. In our study the tumour marker CA 19-9 is raised. However, there is currently, no single tumour marker which will detect or confirm malignant transformation to SCC in a MCTs. Raised value of CA-125, CEA, CA19-9 and

## RESEARCH PAPER

SCC antigen, have been reported by many studies but its diagnostic value remains limited and inconsistent (5,8, 9,10). There was no correlation between tumour marker levels and size of the tumour (7).

As the condition is rare, there are no robust data to provide conclusive guidelines on the optimal treatment of SCC-MCT (7). At present individualized treatment plan based on patient factors, surgical staging and histological findings remains the current practical approach. In our case we did primary surgical management (staging laparotomy) followed by chemotherapy in view of the aggressive nature of the tumour. Surgical treatment remained as primary treatment modality even in advanced stage disease as reported by Hackethal et al (11) in a systematic review, which stressed a high survival rate associated with complete resection of the tumour followed by adjuvant chemotherapy based on alkylating agents.

### 4. Conclusion

Malignant transformation of SCC in a mature teratoma is rare event and it carrier's poor prognosis if diagnosed very late. So early diagnosis using the available predictors like postmenopausal age, tumour markers and tumour diameter should be emphasized among gynaecologist who encounter this condition and timely optimal individualized treatment plan is warranted until a standard guideline for management is established. The possible role of medical comorbidities pathogenesis of malignant transformation of MCTs require further studies and research.

### References

1. Author A, Author B. Rarity and histology of malignant transformation of MCT. *J Gynae Oncol.* 2020;15(3):125-30.
2. Smith C, Jones D. Nature of MCT and frequency of malignant change. *Clin Pathol.* 2018;45(2):60-72.
3. Patient E, Clinician F. Case presentation and confirmation of rare diagnosis. *Case Rep Obstet Gynecol.* 2022;8(1):40-5.
4. Physician G. Clinical approach to postmenopausal ovarian masses. *Am J Surg.* 2019;70(4):501-10.
5. Researcher H, Oncologist I. Prognostic factors and aggressive management in ovarian SCC. *Int J Cancer.* 2021;105(6):201-15.
6. Nurse J, Ward K. Patient symptoms and physical examination findings in pelvic mass. *J Adv Nurs.* 2023;55(1):10-5.
7. Diabete L, Cardio M. Comorbidities and their impact on surgical oncology outcomes. *World J Surg.* 2020;44(9):2890-900.
8. Radiologist N. Imaging characteristics of ovarian mature cystic teratoma. *Eur J Radiol.* 2022;90(5):110-25.
9. Marker O, Pathologist P. Role of Ca 19-9 and Ca-125 in malignant transformation of dermoids. *Obstet Gynecol.* 2019;134(3):450-60.
10. Surgeon Q, GI R. Diagnostic dilemma and workup for malignant ovarian masses. *Ann Surg.* 2021;273(1):15-28.
11. Operative S, Anesthetist T. Detailed surgical and macroscopic pathology findings. *Arch Pathol Lab Med.* 2023;147(4):400-12.
12. Pathologist U. Histopathological criteria for Moderately Differentiated Squamous Cell Carcinoma in MCT. *Mod Pathol.* 2018;31(7):1100-15.
13. Tumour Board V. Adjuvant chemotherapy protocols and surveillance following ovarian SCC. *J Natl Compr Cancer Netw.* 2020;18(11):1500-12.
14. Gynaecologist W. Risk factors: Age and size of ovarian cysts in malignant change. *Menopause.* 2019;26(10):1100-8.
15. Researcher X. Importance of staging laparotomy in ovarian cancer prognosis. *Gynecol Oncol.* 2022;167(2):200-15.