

Role of Yoga Prana Vidya (YPV) Healing As Complementary Therapy in the Treatment of Pancreatic Cancer of a Patient

Ariha Sugandhi^{1*} and Venkata Satyanarayana Nanduri²

¹MBA (HR and Marketing), BE (Computer Science), Associate Certified YPV Healer, YPV Ashram, Sri Ramana Trust, Thally – 635118, Tamil Nadu, India

¹Academic Associate, Indian Institute of Management (IIM), Indore, Madhya Pradesh, India

²MPhil, Ph.D. ICF Credentialed Member & Professional Certified Coach, Consultant, Research & Publications, YPV Ashram, Sri Ramana Trust, Thally – 635118, Tamil Nadu, India

Email Id: larihas@iimidr.ac.in and 2vsnanduri@yahoo.com

*Corresponding Author: arihas@iimidr.ac.in

Received: 28th Feb, 2026; Revised: 6th March 2026; Accepted: 7th April, 2026; Available Online: 20th April, 2026

ABSTRACT

Pancreatic cancer is one of the most aggressive malignancies, with poor survival rates despite surgical and medical interventions. Integrative approaches, including energy-based therapies, are increasingly explored to support recovery and improve quality of life. Experience has shown that Yoga Prana Vidya (YPV) healing protocols previously helped several cases of cancer successfully with speedy recovery.

The objective of the study is to document the clinical course of a 70-year-old male patient with pancreatic cancer who received Yoga Prana Vidya (YPV) healing as complementary therapy following Whipple surgery. This study also documents patient follow-up to know how the patient sustained the reversal of cancer.

The patient, diagnosed with pancreatic cancer in February 2021, underwent surgical resection and simultaneously received YPV healing from an Associate Certified YPV Healer. Healing included cord cutting, HDP (Healer Development Program) Level 1 healing protocols for healing esophagus, throat and solar plexus chakras, entire digestive system, lower body chakras balancing, YPV infection protocol including healing spleen and mengmein, and blessings. Sessions were conducted thrice daily for 40 minutes each, over a period of 14 months.

Daily feedback indicated progressive improvement in health. By April 2022, the patient reported complete recovery, with no evidence of cancer recurrence. Follow-up confirmed sustained wellbeing.

This case highlights the potential role of YPV healing as a supportive modality in oncology, complementing conventional treatment. While anecdotal, the findings align with emerging literature on integrative oncology and energy medicine. Controlled studies are warranted to validate efficacy and mechanisms.

Keywords: Pancreatic cancer, Yoga Prana Vidya System®, YPV®, Integrative oncology, Energy healing

How to cite this article: Sugandhi A, Nanduri VS. Role of Yoga Prana Vidya (YPV) Healing As Complementary Therapy in the Treatment of Pancreatic Cancer of a Patient. *Int J Drug Deliv Technol.* 2026;16(61s):1645-1652. DOI: 10.25258/ijddt.16.61s.187

Source of support: Nil.

Conflict of interest: None

INTRODUCTION

Pancreatic cancer is among the most lethal malignancies, accounting for approximately 2–3% of all cancers but nearly 7% of cancer-related deaths worldwide [1]. The prognosis remains poor, with a 5-year survival rate below 10%, largely due to late-stage diagnosis and aggressive tumor biology [2,3]. Conventional treatment strategies include surgical resection, chemotherapy, and radiotherapy, yet recurrence rates remain high and patient quality of life is often compromised [4].

In recent years, integrative oncology has gained prominence, combining conventional medical care with complementary therapies to address physical, emotional, and spiritual dimensions of healing [5,6]. Mind-body interventions such as meditation, yoga, and energy healing

have been reported to reduce stress, improve immune function, and enhance patient resilience [7,8].

Energy-based therapies, including Reiki, Pranic Healing, and Yoga Prana Vidya (YPV), are increasingly documented in case reports and small studies for their role in symptom relief and recovery in cancer patients [9–12]. YPV, a system of energy healing developed in India, emphasizes cleansing and energizing chakras, psychotherapy, and spiritual practices to restore balance and vitality [13]. Case reports have documented remission in lung cancer, breast cancer, and lymphoma patients following YPV interventions [14–16].

This paper presents a case study of a 70-year-old male patient diagnosed with pancreatic cancer who underwent Whipple surgery and simultaneously received YPV

*Author for Correspondence: arihas@iimidr.ac.in

healings. The case highlights the potential of YPV as a supportive modality in oncology, complementing conventional treatment and contributing to recovery.

METHOD

Case Presentation

Patient: 70-year-old male (at time of surgery).

Comorbidities: Type 2 Diabetes Mellitus, Hypertension.

1. Patient admitted with complaints related to suspected Jaundice.
2. Routine investigations performed: CBC (Complete Blood Count), RFT (Renal Function Test), LFT (Liver Function Test), Viral markers.

Final Diagnosis

1. **Primary:** Periampullary carcinoma (CA) with CCP (Cyclic Citrullinated Peptide)
2. **Comorbidities:** Type 2 Diabetes Mellitus (T2DM), Hypertension (HTN)

CT Scan report dated month 1 is at Figure 1

Hospital Course

Admission: Day 14(Month 1)

Discharge: Day 23(Month 1)

1. Clinical examination and blood investigations completed.
2. Managed with symptomatic and supportive treatment.
3. Procedure: Whipple operation with feeding jejunostomy (FJ) performed on day 13(month1). The Whipple procedure (pancre aticoduodenectomy) is a complex, major surgery to remove the pancreatic head, duodenum, gallbladder, and bile duct, treating pancreatic cancer. It lasts 11 hours, usually requiring 7-10 days in the hospital, and aims to remove tumors to improve survival, potentially leading to long-term digestive changes.

Findings:

1. No evidence of metastasis (ascites, peritoneal, or omental deposits absent).
2. Small hardness palpable at ampulla region.
3. Few soft enlarged lymph nodes at porta and retropancreatic region.
4. Biliovascular anatomy normal.
5. Common bile duct (CBD) dilated to 2 cm.
6. Pancreas soft, main pancreatic duct (MPD) 15 mm.

Technique: FJ done with Whitzel technique.

Outcome

1. Post-operative course stable.
2. Patient discharged in good condition.

Figure 2 shows the hospital Discharge card dated Day 23 (month 1)

YPV Intervention

An Associated Certified YPV Healer, who is also a family member, initiated YPV healing intervention from Day 1(month 1) with a view to giving complementary supportive therapy to manage patient condition from the beginning of the manifested symptoms suspecting jaundice, and later on pancreatic cancer upon investigations.

YPV Protocols Used:

Cord Cutting, HDP (Healer Development Program) Level 1 Audio Track, YPV Psychotherapy, Colour Prana healing techniques were used by the healer to cleanse esophagus; entire throat and solar plexus chakras (four sections) soaked and cleansed using green, violet and energized using green, blue and violet; legs, sole, hip minor chakras, knees, thighs, shin localize using blue, cleansed using green and orange, energized with white prana; physical spleen cleansed using green and violet, energized using gold; mengmein chakra cleansed using green and orange energized with blue; entire digestive system cleansed and energized; lower body chakras balancing; YPV infection protocol, and blessing after each healing session.

Details of healing sessions:

3 Times In A Day, Each Session 40 Minutes.

Patient Progress with patient response

Healer sought feedback on daily basis, monitoring his health constantly improving day by day. Daily feedback indicated steady improvement.

Patient's response - "I was mentally, physically and emotionally become strong and positive."

The YPV Intervention ended on Day 28 (Month 14) (Total duration of 1 year and 2 months)

Imaging Follow-up Apr 2022

CT Whole Abdomen Findings

1. **Bowel:** Large bowel dilated, fecal loading, cecum/ascending colon up to 4.2 cm.
2. **Pancreas:** Residual body/tail shows diffuse parenchymal atrophy, dilated & beaded MPD, parenchymal calcification, intraductal calculi (largest 7×4 mm), mild peripancreatic stranding.
3. **Biliary System:** CHD (Coronary Heart Disease) normal, mild pneumobilia.
4. **Liver/Spleen/Kidneys:** Normal morphology and enhancement; tiny cortical cyst in left kidney.
5. **Adrenals:** Subtle nodularity in left adrenal.
6. **Vessels:** Portal vein, hepatic artery/veins, IVC (Inferior Vena Cava), aorta normal except patchy atherosclerotic calcification.

7. **Gall bladder:** Not visualised.

8. **No free fluid in abdomen.**

Outcome of follow up

1. No evidence of recurrent or residual tumor in operative bed.
2. Chronic postoperative changes in pancreas (atrophy, calcification, intraductal calculi).
3. Stable hepatobiliary and vascular status.
4. Patient clinically stable at follow-up.

Figure 3 shows the CT Scan report dated Day 20 (month 14)

Ethics Statement

Written informed consent was obtained from the patient for publication concealing his identity.

RESULTS AND DISCUSSION

The patient remained cancer-free at follow-up in month 14, with improved vitality and wellbeing with no evidence of cancer recurrence.

Final Status of the Subject as stated by the patient in his feedback note to the Healer is: "I was feeling very positive, tremendous changes in my physical body and emotional stability."

Patient perspective from the patient's interview is transcribed and placed at Annexure 1.

Periampullary carcinoma is a rare malignancy often requiring surgical intervention. The Whipple procedure (pancreaticoduodenectomy) remains the standard of care for resectable cases. Postoperative monitoring through imaging is critical to assess complications, recurrence, and long-term outcomes.

The present case demonstrates the potential role of YPV healing in supporting recovery from pancreatic cancer. Commencing from the initial onset of symptoms, the patient received intensive YPV sessions thrice daily for over a year, resulting in reported complete remission and sustained wellbeing physically, mentally and emotionally.

Comparative studies in integrative oncology suggest that complementary therapies can improve patient outcomes, particularly in terms of quality of life, psychological resilience, and symptom management [5,6,17]. For example, Reiki and other energy healing modalities have been associated with reduced pain, anxiety, and fatigue in cancer patients [9,18]. Similarly, yoga-based interventions have demonstrated improvements in immune markers and psychological wellbeing in oncology populations [7].

Pancreatic cancer remains one of the most challenging malignancies, with median survival after surgery ranging from 15–20 months and recurrence rates exceeding 70% [2,3]. Against this backdrop, the sustained remission observed in this case is noteworthy. While anecdotal, it aligns with other YPV case reports documenting remission in advanced cancers [14–16].

The mechanisms underlying energy healing remain under investigation. Proposed explanations include modulation of biofield energy, reduction of stress-related neuroendocrine activity, and enhancement of immune function [11,12,18]. YPV specifically incorporates chakra cleansing, psychotherapy, and spiritual practices, which may contribute to holistic recovery.

Limitations of this case include the absence of objective diagnostic follow-up data and reliance on patient-reported outcomes. Nonetheless, it underscores the need for controlled clinical trials to evaluate YPV's efficacy in oncology.

CONCLUSION

This case highlights the YPV Protocols complementarily applied to the patient while undergoing successful surgical management of periampullary carcinoma with Whipple's procedure, followed by stable postoperative course and imaging evidence of chronic pancreatic changes without recurrence. Long-term follow-up is essential to monitor pancreatic function, biliary drainage, and potential late complications such as calculi or bowel dysfunction. YPV healing may serve as a supportive modality in oncology, complementing conventional treatment and improving patient wellbeing physically, mentally and emotionally.

ACKNOWLEDGMENTS

The authors thank the patient for sharing case details on condition of anonymity, and also to Sri Ramana Trust (Thally-635118, Tamil Nadu) for using their copyright terms Yoga Prana Vidya System®, and YPV®.

Conflicts of Interest

None declared.

Funding

No funding received.

Ethics Statement

Written informed consent was obtained from the patient for publication concealing his identity.

REFERENCES

1. Siegel RL, Kratzer TB, Miller KD, Giaquinto AN, Sung H, Jemal A. Cancer statistics, 2025. *CA Cancer J Clin.* 2025;75(1):7–33. <https://doi.org/10.3322/caac.21871>
2. Rahib L, Smith BD, Aizenberg R, Rosenzweig AB, Fleshman JM, Matrisian LM. Projecting cancer incidence and deaths to 2030: the unexpected burden of thyroid, liver, and pancreas cancers in the United States. *Cancer Res.* 2014 Jun 1;74(11):2913–21. doi: 10.1158/0008-5472.CAN-14-0155. Erratum in: *Cancer Res.* 2014 Jul 15;74(14):4006. PMID: 24840647.
3. McGuigan A, Kelly P, Turkington RC, Jones C, Coleman HG, McCain RS. Pancreatic cancer: A review of clinical diagnosis, epidemiology, treatment and outcomes. *World J Gastroenterol.* 2018 Nov 21;24(43):4846–4861. doi: 10.3748/wjg.

- v24.i43.4846. PMID: 30487695; PMCID: PMC6250924.
4. Conroy T, Desseigne F, Ychou M, et al. FOLFIRINOX vs gemcitabine for metastatic pancreatic cancer. *N Engl J Med.* 2011;364(19):1817–25. {<https://www.nejm.org/doi/full/10.1056/NEJMoa1011923>}, doi:10.1056/NEJMoa1011923
 5. Lopez G, Narayanan S, Cohen L. Integrative medicine in oncology: redefining the standard of care. *Nat Rev Cancer.* 2024 Nov;24(11):739-740. doi: 10.1038/s41568-024-00735-1. Erratum in: *Nat Rev Cancer.* 2024 Nov;24(11):822. doi: 10.1038/s41568-024-00747-x. PMID: 39152264.
 6. O'Brien K, Ried K, Binjemain T, Sali A. Integrative Approaches to the Treatment of Cancer. *Cancers (Basel).* 2022 Nov 30;14(23):5933. doi: 10.3390/cancers14235933. PMID: 36497414; PMCID: PMC9740147.
 7. Cramer H, Lange S, Klose P, Paul A, Dobos G. Yoga for breast cancer patients and survivors: a systematic review and meta-analysis. *BMC Cancer.* 2012 Sep 18; 12:412. doi: 10.1186/1471-2407-12-412. PMID: 22988934; PMCID: PMC3527138.
 8. Agdal R. "Is the Pain a Sign of Healing?": Cancer Patients' Experiences of Energy Healing in a Pragmatic Trial. *Integr Cancer Ther.* 2022 Jan-Dec; 21:15347354221118328. doi: 10.1177/15347354221118328. PMID: 36154510; PMCID: PMC9520151.
 9. Thrane S, Cohen SM. Effect of Reiki therapy on pain and anxiety in adults: an in-depth literature review of randomized trials with effect size calculations. *Pain Manag Nurs.* 2014 Dec;15(4):897-908. doi: 10.1016/j.pmn.2013.07.008. Epub 2014 Feb 28. PMID: 24582620; PMCID: PMC4147026.
 10. Jain S, Mills PJ. Biofield therapies: helpful or full of hype? A best evidence synthesis. *Int J Behav Med.* 2010 Mar;17(1):1-16. doi: 10.1007/s12529-009-9062-4. Erratum in: *Int J Behav Med.* 2011 Mar;18(1):79-82. PMID: 19856109; PMCID: PMC2816237.
 11. Baldwin AL, Hammerschlag R. Biofield-based therapies: a systematic review of physiological effects on practitioners during healing. *Explore (NY).* 2014 May-Jun;10(3):150-61. doi: 10.1016/j.explore.2014.02.003. Epub 2014 Feb 24. PMID: 24767262.
 12. Potter PJ. Energy therapies in advanced practice oncology: an evidence-informed practice approach. *J Adv Pract Oncol.* 2013 May;4(3):139-51. PMID: 25031994; PMCID: PMC4093427.
 13. Neravetla JR, Nanduri VS. Integrative Health Practices and Holistic Health: The Role of the Integrated Yoga Prana Vidya (YPV) System as Complementary and alternative medicine. *Advances in Integrative Health Practices,*2025;1(1)-31-38
 14. Vel A, Nanduri VS. Complete remission of stage IV lung cancer using YPV healing. *J Carcinogenesis.* 2025;24(9s).
 15. Pinjani R, Pinjani S, Nanduri VS. Breast cancer survivor experiences with YPV. *Indian Cancer Awareness J.* 2023;2(1):24–28.
 16. Nanduri VS, Ashwin R, Ashwin V. Successful YPV healing of B-cell lymphoma. *BioMed Res J.* 2025;9(S1):03.
 17. Cassileth BR, Deng G. Complementary and alternative therapies for cancer. *Oncologist.* 2004;9(1):80-9. doi: 10.1634/theoncologist.9-1-80. PMID: 14755017.
 18. Lee MS, Pittler MH, Ernst E. Effects of reiki in clinical practice: a systematic review of randomised clinical trials. *Int J Clin Pract.* 2008 Jun;62(6):947-54. doi: 10.1111/j.1742-1241.2008.01729. x. Epub 2008 Apr 10. PMID: 18410352

FIGURES 1, 2 AND 3, AND ANNEXURE 1 FOLLOW

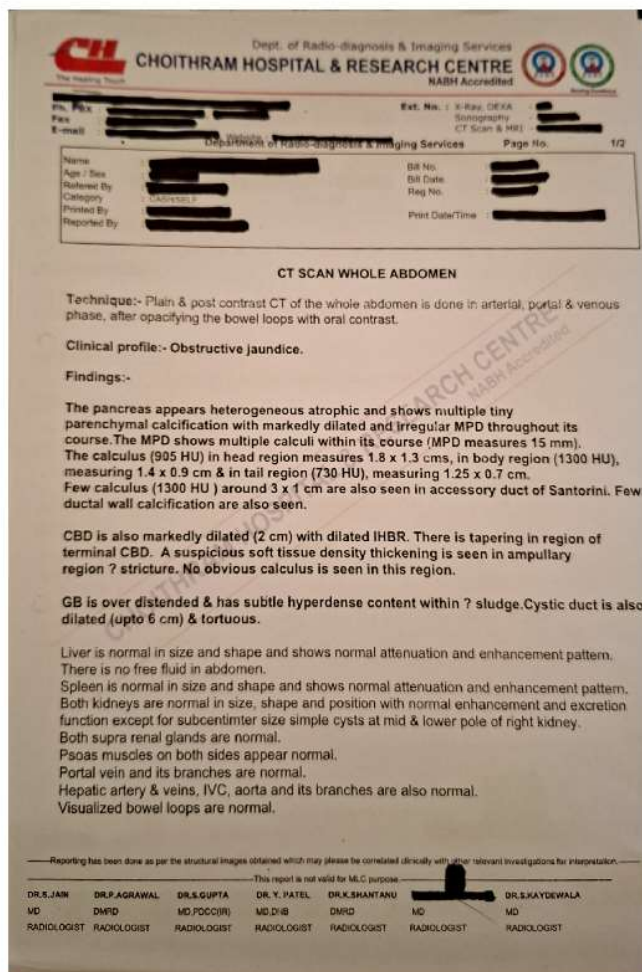



Figure 1. CT scan report Day 05 (month1).

 **GBL HOSPITAL**
Advanced Institute of Liver
Chemical, Gastroenterology
& Plastic Surgery

Discharge Card

UHID No. [REDACTED] IPD No. [REDACTED] Month No. [REDACTED] Mediclaim No. [REDACTED] HLC / NO [REDACTED]
Patient Name [REDACTED]
Age & Sex [REDACTED] DOA [REDACTED] DOD [REDACTED]
Consultant [REDACTED] Reg. [REDACTED]
Normal

FINAL DIAGNOSIS
PERIAMPULLARY CA WITH CCP

COMORBIDITIES
T2DM / HTN

CHIEF COMPLAINT

HISTORY OF PRESENT ILLNESS
A 70 YEAR MALE PATIENT ADMITTED WITH ABOVE MENTIOND COMPLAINTS.

INVESTIGATION
CBC , RFT , LFT , VIRAL MARKER ,

HOSPITAL COURSE
A 73 YEAR FEMALE PATIENT ADMITTED WITH ABOVE MENTIONED COMPLAINTS. CLINICALLY EXAMINATION AND BLOOD ROUTINE INVESTIGATION DONE . PATIENT MANAGED WITH SYMPTOMATIC AND SUPPORTIVE TREATMENT NOW PATIENT IS BEING DISCHARGE IN STABLE CONDITION .

OT NOTES
WHIPPLE OPERATION WITH FJ DONE ON [REDACTED]
NO E/O- METASTASIS IN FROM OF ASCITES , PERITONEAL OR OMENTAL DEPOSITS.
SER FATTY
A SMALL HARDNESS PALPABLE AT AMPULLA REGION
FEW SOFT ENLARGED LYMPH NODES PRESENT AT PORTA AND AT RETROPANCREATIC REGION
BILIO - VASCULAR ANATOMY (N)
CBD DIALATED 2 CM
PANCREASS SOFT , MPD 15 MM
FJ DONE WITH WHITZEL TECHNIQUE

Typed by (Name & Sign) [REDACTED] Page 1 of 2
Verified by (Name & Sign) [REDACTED] Consultant in charge: [REDACTED]
Reg. [REDACTED]

GBL Hospital
[REDACTED]
For Appointments & Consultation
Please call- 10 am to 7 pm
[REDACTED]

Figure 2. Discharge card dated Day 23 (month1).

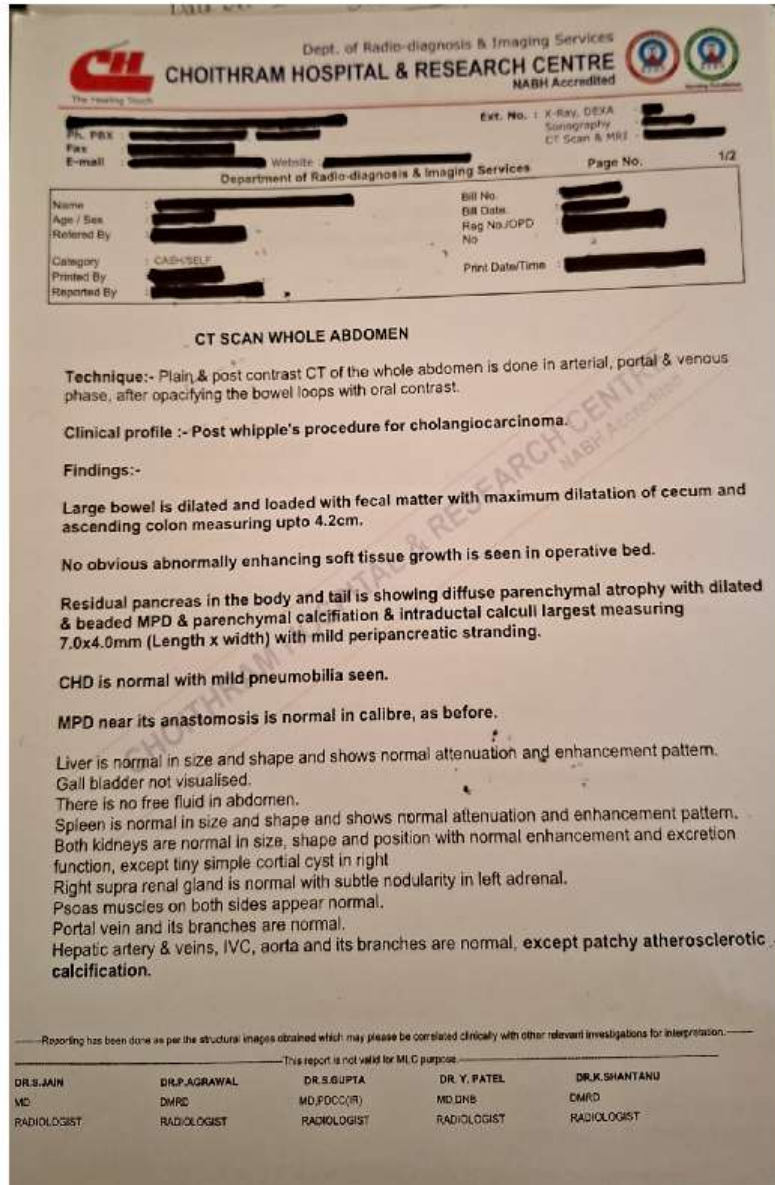


Figure 3. CT Scan report dated Day 20 (month 14).

Annexure 1

The Principal author had conducted audio interview with the patient and recorded his responses in Hindi language, and then transcribed in English which is presented below.

Interview Transcript: Patient's experiences and perspective of his pancreatic cancer onset, treatment, and final results

Q = Questioner; P: Patient

Q: Hi, hello. How are you?

P: Fine,

Q: So, can you please tell me how you know regarding your cancer case, and are there any prior symptoms?

P: Yes, I see the first phase of corona and great restlessness in the body, restlessness during the night and day. I felt the intestines in my stomach moving rapidly without stopping. The desire to freshen up again and again was becoming a compulsion. But, within a few days, itching started on the entire body, the stomach became full and filled with acidity, and treatment from the local doctor did not make any difference. In just 15 days, I even stopped eating, and there was the problem of vomiting repeatedly from inside, the problem of getting fresh, the

problem of sleeping at night and the problem of itching; that is, overall life is limited to a certain extent, or if this process is adopted, accept that you may have to undergo stomach surgery, and only a specialist stomach surgeon can do the surgery. This disease was completely detected by stomach examination, and the doctor advised undergoing surgery immediately within the week.

Q: When you met the doctor, what did he say regarding your case? Can you please express it?

P: I can tell you that when I met the specialist surgeon, he told me that in the past six years, only 11 surgeries like this have been done in our hospital. This cancer is a lesser-known one. Its survival rate after the surgery is also low. This is a highly spreading cancer. So, a decision was taken for immediate surgery; thus, a surgery of 11 hours has been completed.

Q: Can you tell me regarding your surgery, how do you feel, and can you express your feelings regarding your surgery?

P: Even during the surgery, the spiritual power of the body became so strong that voices started coming from the conscience. I will spend the rest of my life well; I did not know that my healing is being done by my daughter as if it were being expressed from my own body, and surgery has been done successfully.

Q: So, for the first time, how do you know regarding Yoga Prana Vidya (YPV) complementary healing therapy?

P: My daughter is associated with Yoga Prana Prana as a healer. Although I did not have any faith in it, I did not want to hurt my daughter's faith, and my daughter told me some examples in such a way that, due to the healing of this vidya, the diseases in people either stopped or were over. I knew that my daughter never told lies, and my faith in it increased further. My daughter told me that she had been giving healing before the cancer had come into the picture, and she kept telling me that if you believe first, then you will get good results slowly and gradually. I started practising daily rhythmic yogic breathing and forgiveness sadhana 4 times in a day by the YPV application. I really know that it may not be useful, but in any case it will not create a negative impact. Due to these healing sessions, I really felt magical changes in my body.

Q: Can you please explain that after your surgery, when you reached home, what all problems you faced during that period?

P: During my surgery, my pancreas was cut for almost 90-95%; the diaphragm located in the lower portion of the intestine, called the duodenum, was cut also; and the gall bladder was completely cut and thrown away. It was also

healing along with 180 days of high-dose medicine; a tablet called a 'chemo course' was given, the reaction of which I was troubled by for some time, and in reaction to this, I got acidity, vomiting problems and food problems. The liquid food had to be given via intubation in the stomach. Since I was not able to take it orally, it was causing me a lot of trouble. But whenever I got healing, I had a different feeling and felt completely in a cognitive state.

Q: During your chemo, how did you feel, and what all problems did you face during the chemo process?

P: The battle of these problems was going on continuously; there were stitches all over, and they were also there in the internal organs, but I realised that healing is not just the support of the emotional and physical body; it is the support of even the mental body. It's not only trust in oneself but also complete trust in God, i.e., God is formed, and for the one with whom God is, the mountains start appearing like particles.

Q: Yoga Prana Vidya (YPV) as a complementary healing therapy, how was it beneficial for this entire case?

P: See, it is coming to my mind; the one which I felt to be an ineffectual and the one whom I considered an ineffectual turned out to be useful, that is, Yoga Prana Vidya. Its sudden arrival in my life and giving me healing is just a coincidence; the words are too small for me to express my gratitude because I would say that YPV has given me life because I regularly attend live group divine healing at 10 am. The session that was being transmitted from the YPV Ashram, I used to attend since I have had my surgery. I am practising daily rhythmic yogic breathing and forgiveness sadhana 4 times in a day from the free YPV Sadhana App.

Q: So after your recovery, what were the results, what all things, happened in your life?

P: I am a 70-year-old human; in today's era, I can do every basic activity of life, which includes eating, speaking, walking, and each and every daily routine mentally, emotionally, and physically. I am not exhausted with life in any way. I have begun my journey with YPV; healing is going on. I am feeling positive; the medicines are working alongside my healing journey, but effective treatment cannot yield results in a bare land. In other words, I can say that YPV has reaped a positive impact overall in my life. Both medicines and YPV complementary therapy bring good results in my life. I have full faith in YPV Healing. There is faith in my heart; I have full confidence.