

Comparative Analysis of Conventional, Cephalometric, and Radiographic Methods for Determination of Vertical Dimension of Occlusion: A Cross-Sectional Study in Central Chhattisgarh Population

Baby Jaman^{1*}, Sanjeev Singh², Saumya Sharma³, Shweta Singh⁴, Avinash Kumar⁵, Aviraj Gill⁶
^{1,2,3,4,5,6}Department of Prosthodontics, Maitri College of Dentistry and Research Centre, Durg, Chhattisgarh, India

Corresponding Author

Dr Baby Jaman, Department of Prosthodontics, Maitri College of Dentistry and Research Centre, Durg, Chhattisgarh, India, Email Id : babyjaman872@gmail.com

ABSTRACT

Accurate determination of vertical dimension of occlusion (VDO) is essential for functional, esthetic, and biomechanical success in prosthetic rehabilitation. Conventional clinical methods often depend on operator skill, while imaging methods aim to provide more objective and reproducible measurements. This study compared the accuracy and reliability of Vernier caliper measurements, cephalometric analysis, and intermental foramen distance (IMFD) on panoramic radiographs for VDO determination in a Central Chhattisgarh population. In a cross-sectional study, 160 dentate adults aged 25–40 years were enrolled. VDO was measured clinically with a calibrated caliper, via lateral cephalograms, and panoramic radiographs (IMFD). Data were analyzed using Pearson's correlation, Bland–Altman plots, and regression models. Mean VDO was 62.86 ± 5.68 mm. Cephalometric and panoramic IMFD analyses are reliable alternatives to caliper measurement for VDO. Cephalometry offers slightly greater accuracy, but panoramic IMFD is practical where cephalograms are less accessible.

Keywords: Vertical Dimension of Occlusion (VDO), Cephalometric Analysis, Panoramic Radiography, Intermental Foramen Distance (IMFD)

How to cite this article: Baby Jaman, Sanjeev Singh, Saumya Sharma, Shweta Singh, Avinash Kumar, Aviraj Gill (2026). Comparative Analysis of Conventional, Cephalometric, and Radiographic Methods for Vertical Dimension of Occlusion Determination: A Cross-Sectional Study in Central Chhattisgarh Population. *International Journal of Drug Delivery Technology*; 2026;16(8s): 977-979; DOI: 10.25258/ijddt.16.8s.109

INTRODUCTION

Vertical dimension of occlusion (VDO) is defined as the facial distance between specific maxillary and mandibular reference points in occlusion. It affects esthetics, speech, mastication, occlusal balance, TMJ function, and comfort¹. Incorrect VDO can compromise facial appearance, denture acceptance, chewing efficiency, and TMJ health. Reliable VDO measurement is critical in dentate and edentulous rehabilitations². Traditionally, clinical soft-tissue or anthropometric reference points are used but vary due to tissue compressibility and postural changes³. Imaging methods like cephalometry and panoramic radiography use stable skeletal landmarks to reduce subjectivity². Fayad et al. showed that intermental foramen distance (IMFD) on panoramic radiographs can predict VDO in an Egyptian cohort⁴. However, investigations in Indian populations, particularly central regions such as Chhattisgarh, are scarce. This study compares clinical caliper, cephalometric, and panoramic IMFD methods, proposing regression models tailored for the Central Chhattisgarh population,

considering ethnic and lifestyle influences on craniofacial morphology.

Materials and methods

Study Design and Participants

This cross-sectional investigation was undertaken between December 2024 and February 2025 at Maitri College of Dentistry and Research Centre, Durg, India. We included 160 dentate subjects (74 males, 86 females; age range 25–40 years) who met strict eligibility criteria: completed permanent dentition with posterior stops, Class I occlusal relation, no history of occlusal wear, orthodontic treatment, temporomandibular joint pathology, or congenital craniofacial anomalies. Facial asymmetry was also an exclusion criterion. By focusing on this carefully chosen population, measurement reliability was optimized and external confounders minimized.

Sample Size Determination

Using G*Power software, an expected standard deviation of 0.526 and a confidence interval of 95% yielded a minimum sample size of 120. Considering potential attrition or radiographic errors, recruitment was extended to 160 participants, thereby ensuring adequate power.

Measurement Protocols

- **Clinical Caliper Measurement:** VDO was clinically measured using a calibrated digital Vernier caliper between subnasale and menton. Subjects were seated upright with lips relaxed and teeth in centric occlusion, ensuring reproducibility.
- **Cephalometric Analysis:** Standardized lateral cephalograms were taken and ANS–menton distance measured manually on traced radiographs with fixed magnification parameters.
- **Panoramic Radiographic Analysis:** Digital panoramic radiographs were obtained using a Sirona Orthophos XG machine at standardized exposure parameters (76 kV, 11 mA, 12 seconds). IMFD was measured between the distal borders of bilateral mental foramina using SIDEXIS 4 software. Calibration was done using the known mesiodistal width of maxillary central incisors to account for image magnification.

Statistical Analysis

Data were analyzed using IBM SPSS v20. Descriptive measures (mean, SD, range) were calculated. Agreement between techniques was checked via Bland–Altman plots, and correlations examined through Pearson’s coefficient. Regression equations were generated to predict VDO from radiographic measurements. Significance was set at $p < 0.05$.

Results

Descriptive statistics for 160 valid cases, revealed a mean clinical VDO of 62.86 ± 5.68 mm. Gender differences were evident: males (66.75 ± 4.27 mm) averaged markedly higher than females (59.55 ± 4.50 mm). Cephalometric analyses showed a similar gender trend: males averaging 67.26 ± 4.58 mm, and females 59.70 ± 5.56 mm, with overall mean 63.17 ± 6.37 mm. Panoramic IMFD values followed suit: males (67.10 ± 4.53 mm), females (60.26 ± 4.53 mm), overall (63.40 ± 5.66 mm).

Correlation was strong between clinical VDO and LAT CEPH ($r = 0.952$) and between VDO and IMFD ($r = 0.937$), both statistically significant ($p < 0.001$). The regression formulas derived were:

- $VDO = 0.84 \times LAT\ CEPH + 9.21$ mm
- $VDO = 0.94 \times IMFD + 3.24$ mm

Error analysis revealed negligible differences: root mean squared error 0.123 cm. Inter- and intra-examiner reliability was high ($\kappa = 0.86$ and 0.79 respectively), reflecting

consistency. Bland–Altman plots confirmed close agreement with only minimal proportional bias.

Variables	N	Minimum	Maximum	Mean	Std. Deviation	
VDO	Total	159	50.00	73.00	62.86	5.68
	Male	73 (45.91%)	53.50	73.00	66.75	4.27
	Female	86 (54.09%)	50.00	68.00	59.55	4.50
LAT CEPH	Total	159	50.00	73.00	63.17	6.37
	Male	73	52.50	73.00	67.26	4.58
	Female	86	50.00	72.00	59.70	5.56
IMFD	Total	159	50.00	75.00	63.40	5.66
	Male	73	54.00	75.00	67.10	4.53
	Female	86	50.00	71.50	60.26	4.53

Table 1. Mean and standard deviation of VDO in mm, LAT CEPH in mm and IMFD in mm

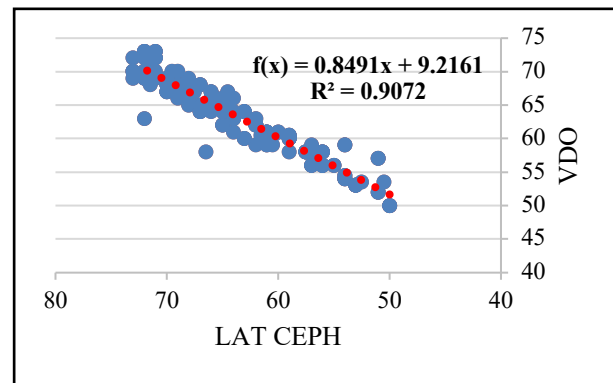


Figure 7. Linear regression analysis between VDO and LAT CEPH

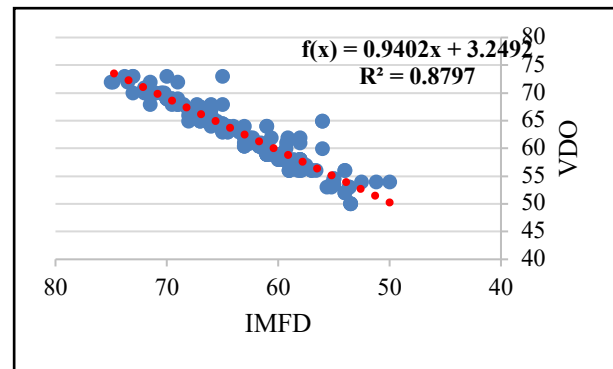


Figure 8. Linear regression analysis between VDO and IMFD

Discussion

Establishing an accurate vertical dimension of occlusion (VDO) remains a clinical challenge. Conventional caliper methods, though simple and inexpensive, are plagued by intra- and inter-operator variation, limiting reproducibility, as noted by Goldstein et al.² and Mosier et al.³. Radiographic techniques, particularly lateral cephalometry using landmarks such as ANS and menton, offer more stability by minimizing muscle tone influence. Despite drawbacks like added radiation, cost, operator dependency,

and magnification errors², Chamanthi et al.⁵ affirmed its superior accuracy compared to clinical methods.

Panoramic radiographs present a valuable alternative. Fayad et al.⁴ correlated intermental foramina distance (IMFD) with VDO in Egyptians, while Mohamed et al.⁶ validated similar findings in Indian cohorts. Our study also showed cephalometric correlations ($r = 0.952$) only marginally higher than IMFD ($r = 0.937$), consistent with Jeong et al.⁷. Nejaime et al.⁸ further supported the reproducibility of mental foramen measurements in Brazilians, though methodological differences explain slight cross-study variations.

Anthropometric approaches—facial height against finger or ear length—have been tested by Preetha et al.⁹ and Al-Jewair¹⁰, but population-specific biological variations reduce universal reliability. Cross-cultural analyses affirm that cephalometric and radiographic formulas must be ethnicity-specific. Sheikhi et al.¹¹ highlighted that CBCT and panoramic IMFD provided consistent results among Iranian subgroups, reinforcing global applicability.

Overall, radiographic modalities remain robust alternatives to caliper-based VDO assessment. While cephalometry is slightly superior, panoramic IMFD offers a practical, widely available method. As Alhajj¹² recommends, combining radiographic and clinical assessments enhances precision, particularly in complex rehabilitations or edentulous cases.

Limitations

The study included only younger adults with class I occlusion, excluding older and malocclusion cases. Though panoramic radiographs were standardized, minor magnification errors could occur. The research was limited to Central Chhattisgarh, so craniofacial variations in other Indian regions require broader validation.

CONCLUSION

Cephalometric and panoramic IMFD methods correlate well with caliper-based VDO measurements. Cephalometry is slightly more precise, but panoramic IMFD is practical, reproducible, and accessible. Regression models offer localized reference values; however, future validation across malocclusion classes, edentulous groups, and varied populations is needed.

REFERENCE

1. Chantler J, Strading M, Strauss F, Ioannidis A, Naenni N. Importance of an Evaluation Phase When Increasing the Occlusal Vertical Dimension: A Systematic Review. *J Esthet Restor Dent*. 2025 Mar;37(3):669-689. doi: 10.1111/jerd.13331

2. Goldstein G, Goodacre C, MacGregor K. Occlusal Vertical Dimension: Best Evidence Consensus Statement. *J Prosthodont*. 2021;30(S1):12–19. DOI: 10.1111/jopr.13315

3. Mosier M, et al. Digital and analog vertical dimension measurements: a clinical observational study. *Int J Prosthodont*. 2021;34(4):419–427. DOI: 10.11607/ijp.7270

4. Fayad MI, Elborae MO, Mahmoud II, et al. A novel formula for estimating the vertical dimension of occlusion using panoramic radiography. *BMC Oral Health*. 2024;24:917. DOI: 10.1186/s12903-024-04614-x

5. P C, G H, N R, et al. Determining Vertical Dimension in Edentulous Patients Through Cephalometric Evaluation: A Cross-Sectional Study. July 29, 2025; *Cureus* 17(7): e88959. DOI: 10.7759/cureus.88959

6. Mohamed HE, et al. Digital panoramic radiography analysis of mental foramen position and interforaminal distance in an Indian sample. *J Clin Diagn Res*. 2023;17(1):ZC19–ZC22. doi: 10.4103/0975-1475.186365

7. Jeong S, Kim S, Lim SH, Yu SK. A study of correlations between cephalometric measurements in Koreans with normal occlusion by network analysis. *Sci Rep*. 2024 Apr 26;14(1):9660. doi: 10.1038/s41598-024-60410-1

8. Nejaime Y, et al. Comparison of distance and symmetry in the mental foramen obtained in situ and in radiographic images of Brazilians. *Odontol Clín-Cient*. 2013;12(4):269–72. ISSN 1677-3888

9. Preetha S, et al. Relationship of ear, finger, and occlusal vertical dimension – An anthropometric study in the Indian population. *J Indian Prosthodont Soc*. 2022;22(2):182–187. doi: 10.4103/jips.jips_313_20

10. Al-Jewair T, Marwah S, Preston CB, Wu Y, Guan Y. Correlation between craniofacial structures, anthropometric measurements, and nasopharyngeal dimensions in black adolescents. *Int Orthod*. 2021;19(1):96–106. doi:10.1016/j.ortho.2021.01.002

11. Sheikhi M, et al. Mental foramen position measured by CBCT and panoramic radiography in Iranian patients. *Radiol Med*. 2021;126(1):168–74. DOI: 10.1155/2016/5821048

12. Alhajj MN. Literature review: Methods and accuracy for VDO measurement. *Eur J Prosthodont Restor Dent*. 2021;29(2):64–72. DOI: 10.7759/cureus.93987